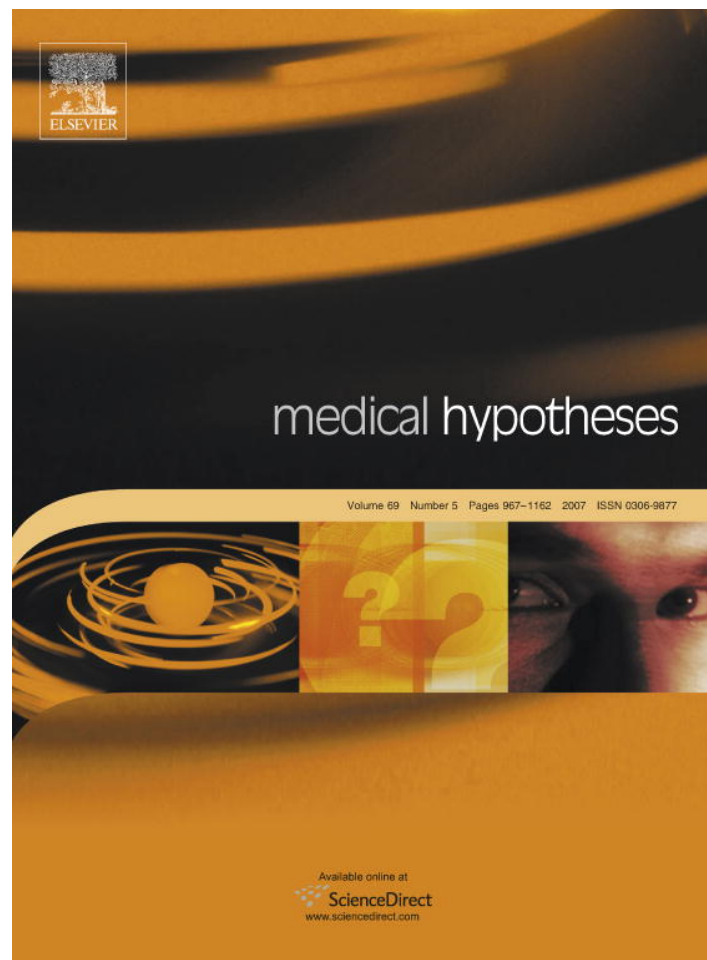


Provided for non-commercial research and education use.
Not for reproduction, distribution or commercial use.



This article was published in an Elsevier journal. The attached copy is furnished to the author for non-commercial research and education use, including for instruction at the author's institution, sharing with colleagues and providing to institution administration.

Other uses, including reproduction and distribution, or selling or licensing copies, or posting to personal, institutional or third party websites are prohibited.

In most cases authors are permitted to post their version of the article (e.g. in Word or Tex form) to their personal website or institutional repository. Authors requiring further information regarding Elsevier's archiving and manuscript policies are encouraged to visit:

<http://www.elsevier.com/copyright>



ELSEVIER

Sulcus nervi dorsalis penis: Site of origin of Alcock's syndrome in bicycle riders?

O. Naňka^{a,*}, J. Šedý^{a,b,c}, L. Jarolím^d

^a *Institute of Anatomy, 1st Faculty of Medicine, Charles University, U Nemocnice 3, 128 00 Prague 2, Czech Republic*

^b *Institute of Experimental Medicine, ASCR, Prague, Czech Republic*

^c *Center for Cell Therapy and Tissue Repair, Department of Neuroscience, 2nd Medical Faculty, Charles University, Prague, Czech Republic*

^d *Department of Urology, 2nd Medical Faculty and University Hospital Motol, Charles University, Prague, Czech Republic*

Received 29 January 2007; accepted 31 January 2007

Summary This article introduces a hypothesis that the pudendal nerve compression syndrome, also known as the Alcock's syndrome in long-time duration bicycle riders might be caused by an irritation of the dorsal nerve of penis in a groove on the inferior ramus and the anterior surface of pubis, previously described by authors as the sulcus nervi dorsalis penis. Alcock's syndrome in bicycle riders has been characterized as a prolonged glans and penile insensitivity, genital numbness and an erectile dysfunction. Although no anorectal pain or disturbance of the bulbocavernosus reflex has been reported in these patients, we assume it cannot be caused by a compression of the pudendal nerve in pudendal (Alcock's) canal, hence by a compression of the dorsal nerve of penis in the sulcus nervi dorsalis penis. In future, if clinical studies confirm our hypothesis, it might be more sophisticated to evaluate this syndrome apart from the Alcock's syndrome and term it the dorsal nerve compression syndrome rather than the Alcock's syndrome.

© 2007 Elsevier Ltd. All rights reserved.

Introduction

The pudendal nerve originates from the sacral plexus. It enters the perineum through the lesser sciatic foramen and courses through the ischioanal fossa and then through the pudendal canal (canalis pudendalis or Alcock's canal) that is formed by the duplication of the obturator fascia on the lateral

wall of ischioanal fossa [1–3]. The pudendal nerve gives rise to the inferior rectal nerve, the perineal nerve and the dorsal nerve of penis. The dorsal nerve of penis further continues anteriorly and reaches the inferior ramus of pubis and subsequently courses along the inferior border and anterior surface of body of the pubis, in close contact with a pubic bone in the sulcus nervi dorsalis penis [4,5]. Inferior to the pubis, the dorsal nerve of penis courses proximal to the insertion of the cavernous body and further between the cavernous body and the anterior surface of pubis to the dorsum

* Corresponding author. Tel.: +420 2 2496 5758; fax: +420 2 2496 5770.

E-mail address: ondrej.nanka@lf1.cuni.cz (O. Naňka).

penis. Here, the dorsal nerve of penis branches and innervates the penile shaft and glans [4,5].

Alcock's syndrome, also known as the pudendal nerve compression syndrome or pudendal canal syndrome, has been described as an irritation of the pudendal nerve in the pudendal or Alcock's canal [1,2,6]. The complete syndrome presents with anal incontinence, pain and/or hypo- or hyperesthesia of the perineum (perineodynia, vulvodinia, proctalgia), genital numbness (numbness of perineum, penis and scrotum), urinary incontinence and sexual problems in males, such as impotence, difficulty to achieve orgasm and altered sensation of ejaculation [1,2,7]. The etiology of the Alcock's syndrome is not always clear, but is often possible to find a compression (biking, long-time sitting), stretching (descending perineum, previous surgery, delivery) or trauma of the pudendal nerve in Alcock's canal in the history of the patient [1–3,8]. This syndrome is often treated surgically by a pudendal canal decompression, but the results are not always satisfactory [9].

In 1979, Goodson was the first who described the Alcock's syndrome in bicycle riders as a prolonged irritation of the pudendal nerve resulting in a decreased glandular and penile sensitivity, genital numbness and erectile dysfunction [10]. After that, several authors reported similar findings in their male patients [8,11–14]. In these cases, clinical examination of the patients, radiographic imaging of the pelvis and spine and complementary MRI excluded skeleton abnormalities, neurological disturbances, posttraumatic haematoma, osteitis pubis, bacterial prostatitis, injury of the pudendal nerve and its branches or other signs of traumatic, vascular, inflammatory and tumor-associated causes [8,10–14].

Peddaling while sitting on a slim hard saddle and being constantly subjected to a repetitive impacts are thought to generate an extreme perineal pressure, which indirectly compresses the pudendal nerve and exposes it to a repetitive trauma [7]. If the site of origin of the Alcock's syndrome in long-distance bicycle riders occurs in the pudendal canal or under the subpubic space has frequently been described as a topic of controversy and extensively discussed [7,12–14].

The hypothesis

Our hypothesis assumes that the clinical signs of a sub group of patients with the symptoms of the Alcock's syndrome are caused by an overuse injury in cyclists – a repetitive prolonged pressure of the

nose of the saddle against the site where the dorsal nerve of penis runs adjacent to the ventromedial border of the ischiopubic ramus – in the sulcus nervi dorsalis penis, previously described by our group of authors [4,5]. Here, the dorsal nerve of penis is covered only by a thin mass of fibrous tissue and thus vulnerable to a compression [4,5]. The depth of the sulcus could probably serve as a protective factor in the development of the Alcock's syndrome in bicycle riders.

If verified in future, we propose the name of this syndrome to be the dorsal nerve compression syndrome rather than the pudendal or Alcock's syndrome.

Evaluation of the hypothesis

Why compression of the nerve

In the development of a compression neuropathy, both mechanical and ischemic factors are involved [2,15]. The dorsal nerve of penis is surrounded by the pubic bone (sulcus nervi dorsalis penis), fibers of the suspensory ligament of penis and the ischiocavernosus body [4,5,16], tight structures, that could be causative for the compression neuropathy. In addition, a long-time forward leaning of the cyclist could be involved in the ischemic part of the development of the dorsal nerve compression neuropathy. Moreover, the gliding movements during cycling expose the dorsal nerve to a repetitive trauma [7]. Experimental studies suggest that the greater the duration and the amount of pressure, the more significant is the neural dysfunction [15]. In addition, the severity of the neural damage is dictated mainly by the duration of the pressure [7,15], which corresponds to a long-time leaning of the cyclist. Moreover, a recent experimental nerve compression studies revealed an etiology of the nerve compression includes other factors – multiple changes in the intraneural microcirculation and fiber structure, impairment of an axonal transport and increased vascular permeability [7,15]. The role of these factors is enhanced in a region of the hard bony sulcus nervi dorsalis penis.

Why not the trunk of the pudendal nerve

Current papers describe the etiology of Alcock's syndrome as a compression of the pudendal nerve in the pudendal canal [1,9]. Branches of the pudendal nerve include the inferior rectal nerve, the perineal nerve and the dorsal nerve of penis.

Inferior rectal nerve supplies the rectum and no sensory or motor problems are described in Alcock's syndrome in bicycle riders [7,12–14]. Perineal nerve supplies the perineum and the bulbocavernosus muscle. Immediately after leaving the canal, it enters the bulbocavernosus muscle, where it passes between the ischiocavernosus and bulbocavernosus muscles [17]. Whereas hypesthesia or anesthesia is a major sign of the Alcock's syndrome in bicycle riders, there are no reports of paresis of the bulbocavernosus muscle [7,12–14]. Thus, the clinical signs of the Alcock's syndrome in long-distance bicycle riders are showing the trunk of the pudendal nerve, running in the pudendal canal, cannot be impaired in these patients.

Why not the pudendal canal

Several authors, who are describing the Alcock's syndrome in bicycle riders (but without any sign of an anorectal or a perineal pain) often conclude the etiology of the syndrome as a compression of the pudendal nerve in the pudendal canal [1,11]. The pudendal canal is but covered by a thicker mass of fat than the inferior border of a pubic body, which would protect the nerve [1,4,5]. In addition, if a compression occurs in the pudendal canal, an irritation/damage of the pudendal artery and vein might also be expected. However, haematoma or other signs of the vessel damage are not symptoms of the Alcock's syndrome. In addition, an erectile dysfunction might occur in the Alcock's syndrome, but is rather due to the loss of sensory information from the dorsal nerve of penis than an irritation and/or damage of the dorsal artery of penis.

Why the dorsal nerve of penis

The only nerve supplying the glans penis and thus causative of a decreased glandular and penile sensitivity and probably also a genital numbness is the clearly sensory dorsal nerve of penis [17,18]. Thus, the Alcock's syndrome can be caused only by an irritation or the damage of the dorsal nerve of penis.

For the proper erectile function, the normal function of the dorsal nerve of penis is important, to lead the information of an excitation of glans and skin of the penis into the central nervous system [17]. However, only very few reports are describing the erectile dysfunction in the Alcock's syndrome patients [19], indicating it is not a standard constituent of the Alcock's syndrome picture.

The role of vessels

The role of vessels cannot be underestimated. Cycling in the upright-seated position compresses the dorsal penile arteries in the perineum and consequently decreased a penile blood flow by approximately 70% [12]. Conversely, the cycling in a reclining position, in which the perineum is not compressed, did not alter the penile perfusion [7]. Andersen and Bowim showed that the ischemia of less than 6 h, leading to a nerve conduction block can be rapidly reversible, although if the ischemic period is extended to 8 h, the recovery may take weeks [20].

The hypoxemia of the penis causes a corporal connective tissue synthesis, apoptosis of trabecular smooth muscle cells and penile fibrosis. The loss of the trabecular tissue along with a deposition of the connective tissue results in an impaired penile expandability which may cause a permanent erectile dysfunction due to a venoocclusive dysfunction [7,21].

Nayal et al. evaluated the blood supply to the penis during bicycling [22]. Mean value (SD) of the transcutaneous penile oxygen partial pressure at the glans of penis decreased after 3 min of cycling from a mean value of 61.4 (7.4)–19.4 (4.2) mmHg [22].

However, no case of the Alcock syndrome revealed a permanent erectile dysfunction. Thus, the compression of vascular network of the dorsal nerve of penis and its temporary hypoperfusion of the dorsal nerve of penis are present in the Alcock's syndrome in bicycle riders rather than the ischemia of a trabecular smooth muscles, penile fibrosis or venoocclusive dysfunction.

Why under the pubis

The subpubic arch is an anatomical site with little fibrous tissue [23]. The dorsal nerve of penis runs from the perineum to the dorsal surface of penis through the subpubic region, adjacent to the pubic bone, in the sulcus nervi dorsalis penis [4,5]. Direct pressure of a hard, narrow and upward-tilted nose of the saddle against the perineum and the symphysis, further provoked by a forward leaning of the cyclist, probably pinches the dorsal nerves of penis at the point where they emerge below the pubis. During cycling, the major body weight of the cyclist lies on the subpubic region, thus increasing the pressure on the dorsal nerve of penis against the pubic bone [4,5,7,19].

The pressure of the saddle against the subpubic arch can lead to the development of a firm,

non-painful nodule in a subpubic area - the perineal nodular induration, also called the 'accessory testicle' or 'biker's nodule' [24,25]. The development of this benign non-tumorous affection positively correlates with a long-term bicycling of professional or amateur bicycle riders. Histologically, the perineal nodular induration is characterized by a central pseudocystic formation surrounded by a dense fibrous tissue showing the diapedesis of erythrocytes. There are no evidences these nodules develop on a basis of the bursa or an inflammatory process [24,25]. The occurrence of the perineal nodular indurations further supports the hypothesis of a nerve damage in the subpubic region.

Why in sulcus nervi dorsalis penis

Dorsal nerve of penis runs in the whole course of the sulcus nervi dorsalis penis. Mean length of the sulcus on an inferior ramus of the pubis is 15.8 mm, mean length on an anterior surface of the pubis is 21.3 mm [4,5]. Thus, the part of the dorsal nerve which runs in a close proximity to the pubic bone is approximately 27 mm long. We can speculate that the sulcus nervi dorsalis penis developed phylogenetically by an interaction of a bone and nerve sheaths to lead the dorsal nerve of penis through the subpubic space to the dorsum penis.

We have shown the depth of the sulcus nervi dorsalis penis varies between 0 and 2 mm [4,5]. The depth of the sulcus nervi dorsalis penis is probably the most important factor in the development of the Alcock's syndrome in bicycle riders; the deeper the sulcus is the higher level of a protection of the dorsal nerve of penis occurs. The sulcus nervi dorsalis penis would thus be a protective factor in the development of the Alcock's syndrome in long-distance bicycle riders.

Other cognate syndromes

Pudendal nerve entrapments are sources of an intractable perineal pain [26–28]. Desensitization of the penile dorsum and an erectile dysfunction have not been described in these cases; thus, we hypothesize that the perineal and inferior rectal nerves are affected during their course in the inferior half of the pudendal canal and not by a compression of the dorsal nerve in the sulcus of the pubic bone. In addition, these cases are in accordance with causes other than the bicycle riding [3,26–28].

Consequences of the hypothesis and discussion

The idea of a nerve compression under the subpubic arch in patients with the Alcock's syndrome has been proposed by several authors [8,10,11]. However, to our knowledge, no relevant clinical study focusing on a site of the course of dorsal nerve of penis in the sulcus nervi dorsalis penis has been made. Recently, Hruby et al. described 3 cm long "tight osteofibrotic canal" under the subpubic space, where the dorsal nerve of penis can be compressed [16]. However, this study was not supported by any clinical data or dissection of patient with Alcock's syndrome.

The Alcock's syndrome in long-distance bicycle riders can be recognized as a bicycle-related overuse injury [29]. It has been characterized by a glans and penile insensitivity, genital numbness and erectile dysfunction [11,19]. Our hypothesis assumes the glans and penile insensitivity and the genital numbness are probably caused by a compression of the dorsal nerve of penis in the sulcus nervi dorsalis penis. Conversely, in etiopathogenesis of an erectile dysfunction of these patients, the vascular component can also be involved [19].

To avoid the development of a 'dorsal nerve compression syndrome', bicycle rider should probably lower the nose of the saddle to decrease the pressure against a subpubic region and replace the hard narrow seat with a soft and wider one to spread the pressure of the seat on a wider part of the perineum. However, too wide seat may put more pressure on the sciatic nerve and cause its damage [30].

Correcting the handlebars or the height of the saddle, tipping the nose of the saddle to produce a more horizontal, or even downward pointing position, and attention to the design of the saddle may be the only required precautions [22]. Also, the cyclist should take a frequent pauses during the long-term cycling to avoid the ischemic damage of the dorsal nerve and the development of erectile dysfunction [20]. However, the incidence of an erectile dysfunction found in bicycle riders was not as high as might be expected [14]. The study by Taylor et al. found no significant difference in the incidence of an erectile dysfunction in bicycle riders vs. non-bicycle riders [13].

The 'dorsal nerve compression syndrome' must be distinguished from the pudendal nerve entrapment syndrome, chronic perineal pain syndromes of other syndromes such as the hypertrophy of

the muscles of the pelvic floor, prostatitis, epididymitis, testicular torsion, carcinoma of the prostate, inflammatory processes of the pelvis, hip pain of different etiology, levator ani syndrome, coccygodynia, proctalgia fugax or traumatic urethritis with hematuria and dysuria, posttraumatic haematoma, osteitis pubis, neurological disturbances or previous traction on the orthopaedic table [3,11,26–29,31,32], because a compression of the dorsal nerve of penis in the sulcus nervi dorsalis penis could be treated conservatively, without any surgical treatment, as described previously [8,10–14].

The 'dorsal nerve compression syndrome' is not the only compression syndrome occurring in the bicycle riders. Prolonged pressure of hands of the cyclist on the handlebars and the position of the wrists may cause a compression neuropathy of the deep palmar branch of the ulnar nerve in the canal of Guyon in wrist, resulting in a numbness and tingling in the fourth and fifth finger and/or weakness on abduction and adduction of the fingers or adduction of the thumb [29]. The compression of the median nerve, known as the carpal tunnel syndrome can also occur, but rarely [29].

The major message from our hypothesis is to help the surgeon ascertain the potential site of origin of the Alcock's syndrome in bicycle riders presenting with the loss of a glans sensitivity and an erectile dysfunction and to make the diagnosis of this syndrome easier. To evaluate our hypothesis, the differences between the compression of a pudendal nerve in the pudendal canal (i.e. the pudendal or Alcock's syndrome) vs. the compression of the dorsal nerve of penis in the sulcus nervi dorsalis penis (i.e. the dorsal nerve compression syndrome?) and their surgical vs. conservative treatment should be studied in clinical trials in future.

References

- [1] Shafik A, Doss SH. Pudendal canal: surgical anatomy and clinical implications. *Am Surg* 1999;65:176–80.
- [2] Shafik A. Pudendal canal syndrome: a cause of chronic pelvic pain. *Urology* 2002;60:199.
- [3] Hough DM, Wittenberg KH, Pawlina W, et al. Chronic perineal pain caused by pudendal nerve entrapment: anatomy and CT-guided perineural injection technique. *Am J Roentgenol* 2003;181:561–7.
- [4] Šedý J, Naňka O, Walro JM, Belišová M, Jarolím L. Sulcus nervi dorsalis penis/clitoridis: anatomic structure and clinical significance. *Eur Urol* 2006;50:1079–85.
- [5] Šedý J, Naňka O, Walro JM, Špačková J, Jarolím L. Sulcus nervi dorsalis penis/clitoridis: new marker of sexual dimorphism of pubis. *Čes Urol* 2006;1:48–54.
- [6] Shafik A. Pudendal canal syndrome. Description of a new syndrome and its treatment. Report of 7 cases. *Coloproctology* 1991;13:102–10.
- [7] Leibovitch I, Mor Y. The vicious cycling: bicycling related urogenital disorders. *Eur Urol* 2005;47:277–8.
- [8] Amarenco G, Lanoe Y, Perrigot M, Goudal H. A new canal syndrome: compression of the pudendal nerve in Alcock's canal or perineal paralysis of cyclists. *Presse Med* 1987;16:399.
- [9] Beco J, Klimov D, Bex M. Pudendal nerve decompression in perineology: a case series. *BMC Surg* 2004;4:15.
- [10] Goodson JD. Pudendal neuritis from biking. *N Engl J Med* 1981;304:365.
- [11] Oberpenning F, Roth S, Leusmann DB, van Ahlen H, Hertle L. The Alcock syndrome: temporary penile insensitivity due to compression of the pudendal nerve within the Alcock canal. *J Urol* 1994;151:423–5.
- [12] Sommer F, König D, Graft C, et al. Impotence and genital numbness in cyclists. *Int J Sports Med* 2001;22:410–3.
- [13] Taylor JA, Kao TC, Albertsen PC, Shabsigh R. Bicycle riding and its relationship to the development of erectile dysfunction. *J Urol* 2004;172:1028–31.
- [14] Dettori JR, Koepsell TD, Cummings P, Corman JM. Erectile dysfunction after a long-distance cycling event: associations with bicycle characteristics. *J Urol* 2004;172:637–41.
- [15] Mackinnon SE. Pathophysiology of nerve compression. *Hand Clin* 2002;18:231–41.
- [16] Hruby S, Ebmer J, Dellon L, Aszmann OC. Anatomy of pudendal nerve at urogenital diaphragm – new critical site for nerve entrapment. *Urology* 2005;66:949–52.
- [17] Yang CC, Bradley WE. Somatic innervation of the human bulbocavernosus muscle. *Clin Neurophysiol* 1999;110:412–8.
- [18] Yang CC, Bradley WE. Peripheral distribution of the human dorsal nerve of the penis. *J Urol* 1998;159:1912–7.
- [19] Cherington M. Hazards of bicycling: from handlebars to lightning. *Sem Neurol* 2000;20:247–53.
- [20] Andersen KV, Bowim G. Impotence and nerve entrapment in long distance amateur cyclists. *Acta Neurol Scand* 1997;95:233–40.
- [21] Nehra A, Goldstein I, Pabby A, et al. Mechanisms of venous leakage: a prospective clinicopathological correlation of corporeal function and structure. *J Urol* 1996;156:1320–9.
- [22] Nayal W, Schwarzer U, Klotz T, Heidenreich A, Engelmann U. Transcutaneous penile oxygen pressure during bicycling. *BJU Int* 1999;83:623–5.
- [23] Akman Y, Liu W, Li YW, Baskin LS. Penile anatomy under the pubic arch: reconstructive implications. *J Urol* 2001;166:225–30.
- [24] Kohler P, Utermann S, Kahle B, Hartschuh W. Biker's nodule – perineal nodular induration of the cyclist. *Hautarzt* 2000;51:763–5.
- [25] Somerhausen NS, Geurde B, Couvreur Y. Perineal nodular induration: the 'third testicle of the cyclist', and underrecognized pseudotumour. *Histopathology* 2003;42:615–6.
- [26] Robert R, Prat-Pradal D, Labat JJ, et al. Anatomic basis of chronic perineal pain: role of the pudendal nerve. *Surg Radiol Anat* 1998;20:93–8.
- [27] Robert R, Labat JJ, Bensignor M, et al. Decompression and transposition of the pudendal nerve in pudendal neuralgia: a randomized controlled trial and long-term evaluation. *Eur Urol* 2005;47:403–8.

- [28] Ramsden CE, McDaniel MC, Harmon RL, Renney KM, Faure A. Pudendal nerve entrapment as source of intractable perineal pain. *Am J Phys Med Rehabil* 2003;82:479–84.
- [29] Thompson MJ, Rivara FP. Bicycle-related injuries. *Am Fam Physician* 2001;63:2007–114.
- [30] Kita J. The unseen danger. *Bicycling* 1997;38:68–73.
- [31] O'Brien KP. Sports urology: the vicious cycle. *N Engl J Med* 1981;304:1367–8.
- [32] Goldet R, Kerdraon J, Amarenco G. Traction on the orthopedic table and pudendal nerve injury. Importance of electrophysiologic examination. *Rev Chir Orthop Reparatrice Mot* 1998;84:523–30.

Available online at www.sciencedirect.com

