Ondřej Naňka

Institute of Anatomy

KOSTI A KLOUBY DOLNÍ KONČETINY

BONES AND JOINTS OF LOWER EXTREMITY

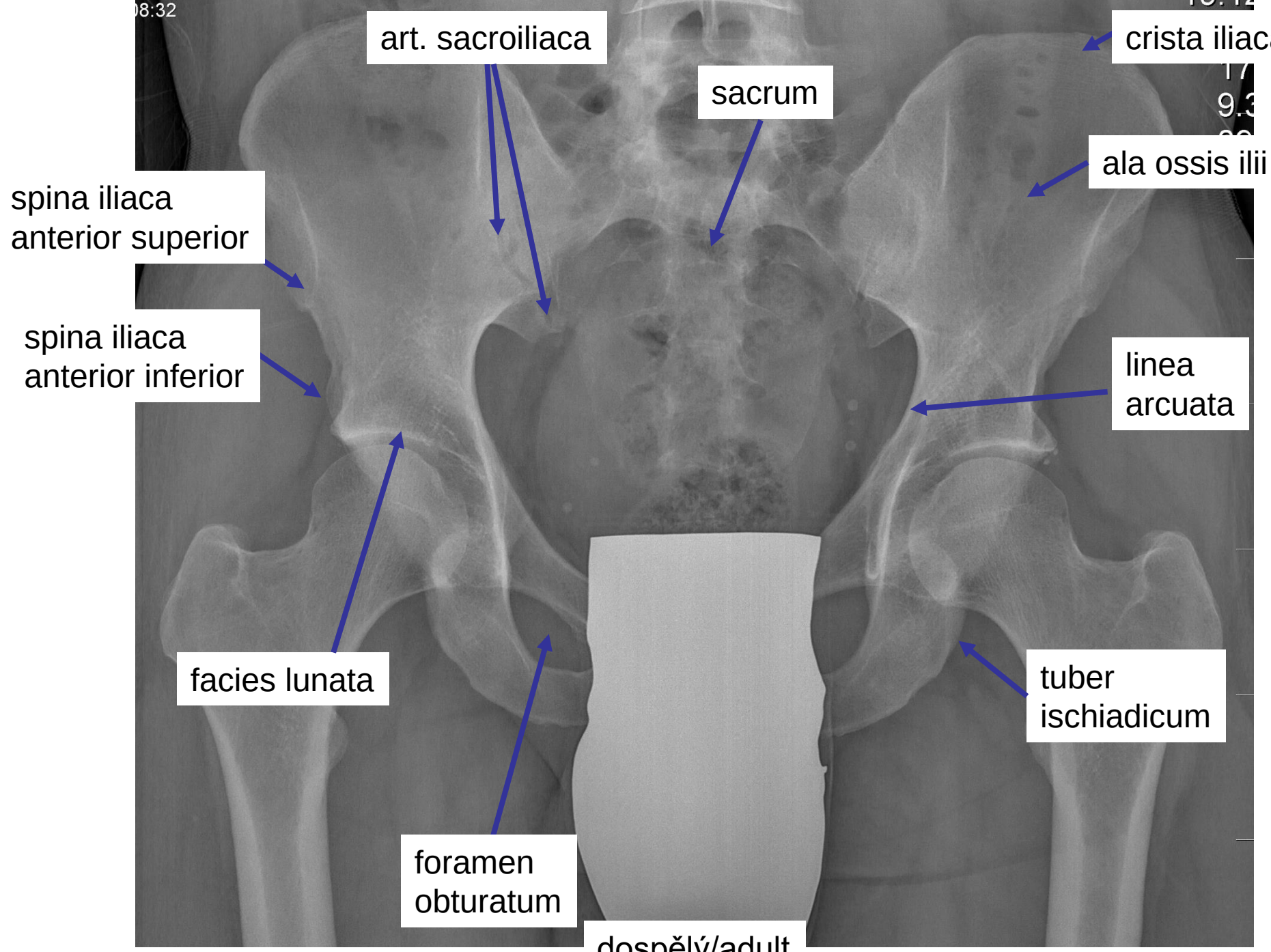
art. sacroiliaca
crista iliaca
sacrum
ala ossis ilii
spina iliaca anterior superior
spina iliaca anterior inferior
linea arcuata
facies lunata
tuber ischiadicum
foramen obturatum
dospělý/adult

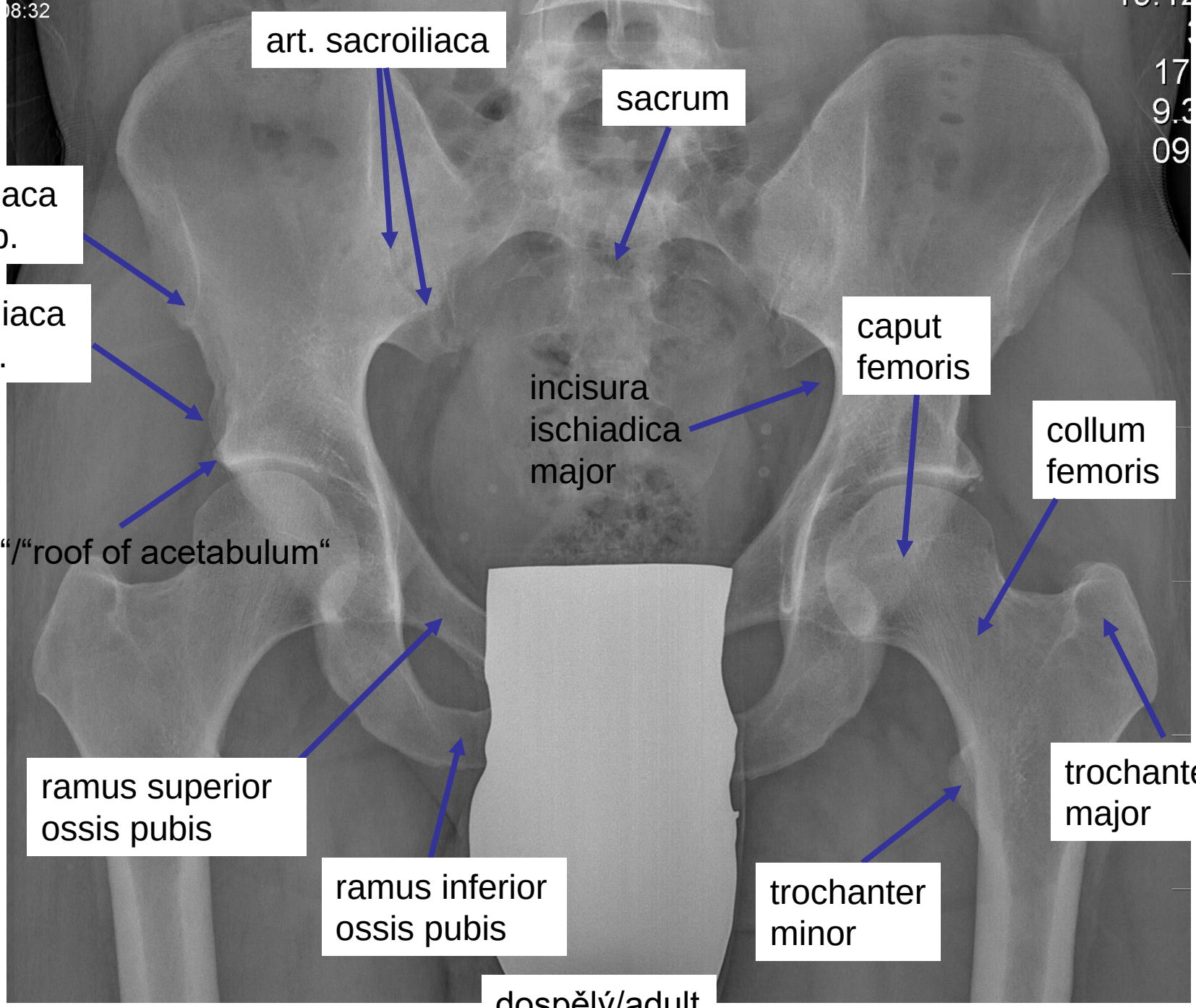
art. sacroiliaca
sacrum
spina iliaca ant. sup.
spina iliaca ant. inf.
incisura ischiadica major
caput femoris
collum femoris
„stříška“/“roof of acetabulum“
ramus superior ossis pubis
ramus inferior ossis pubis
trochanter minor
trochanter major
dospělý/adult

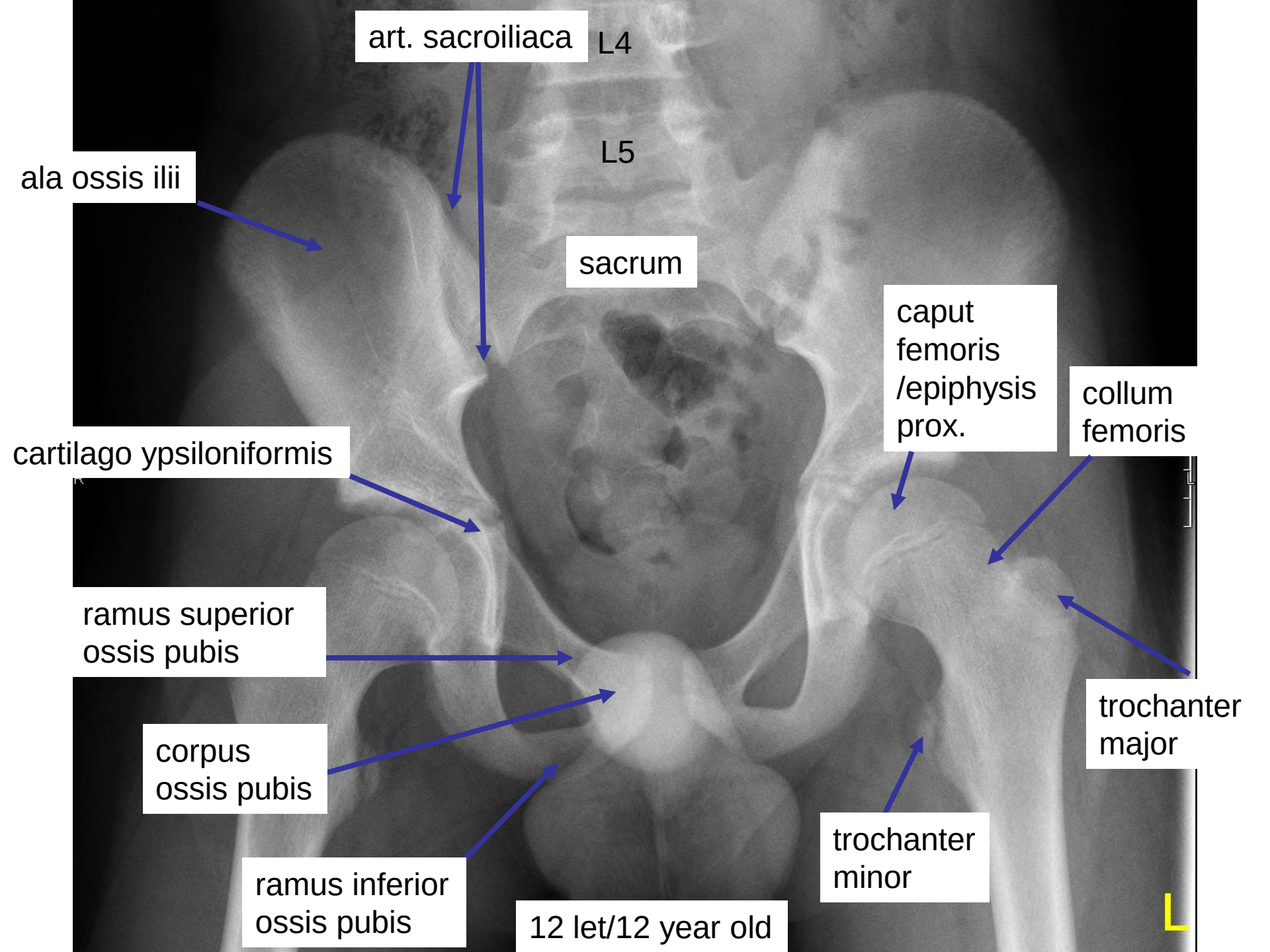
art. sacroiliaca
L4
L5
ala ossis ilii
sacrum
caput femoris /epiphysis prox.
collum femoris
cartilago ypsiloniformis
ramus superior ossis pubis
trochanter major
corpus ossis pubis
trochanter minor
ramus inferior ossis pubis
12 let/12 year old
L

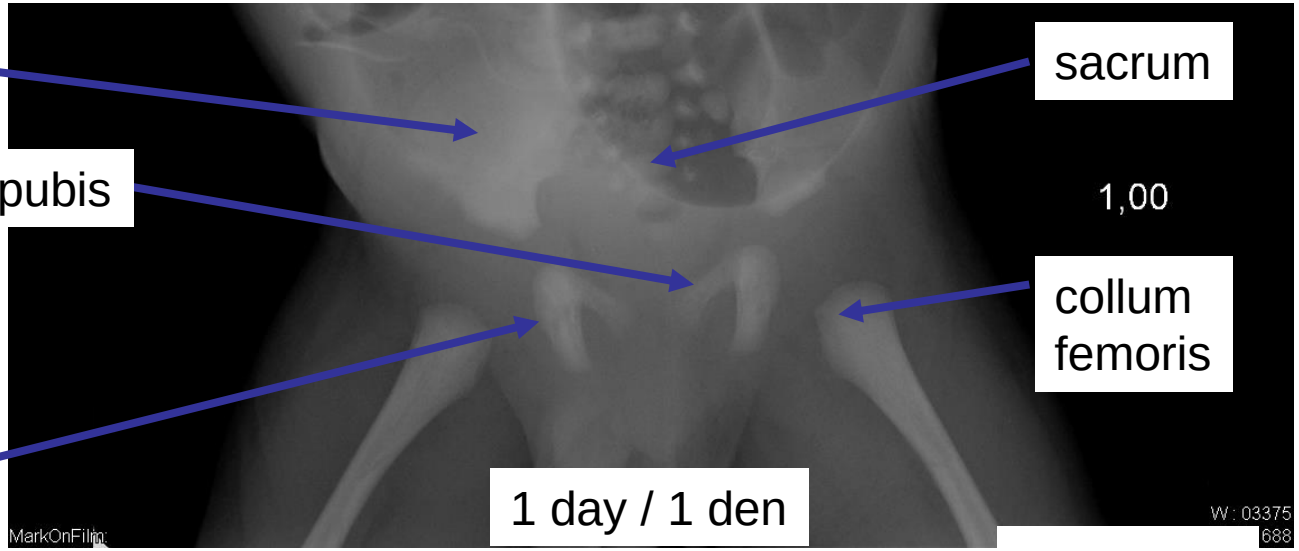
ala ossis ilii
sacrum
os pubis
1,00
collum femoris
os ischii
1 day / 1 den
MarkOnFilm
W : 03375
688

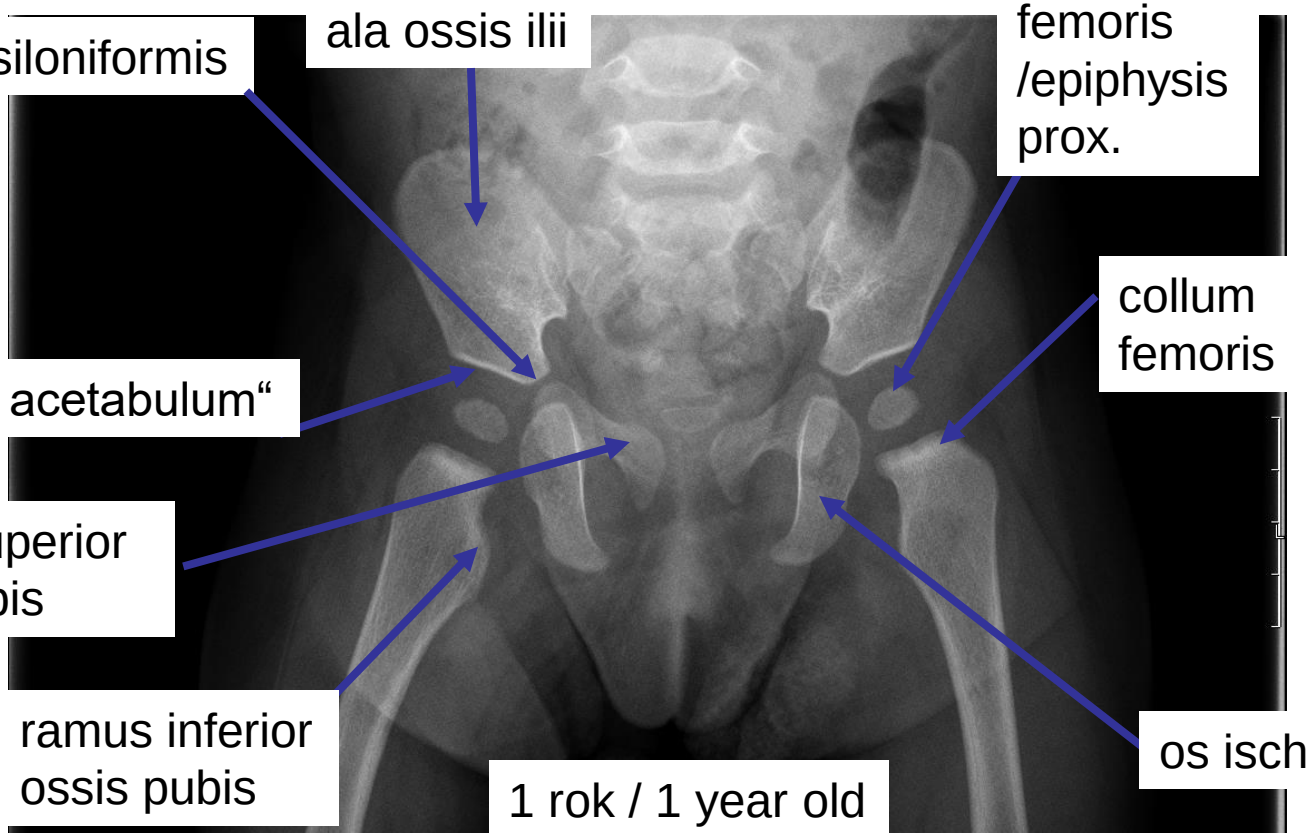
cartilago ypsiloniformis
ala ossis ilii
caput femoris /epiphysis prox.
collum femoris
„stříška“/“roof of acetabulum“
ramus superior ossis pubis
ramus inferior ossis pubis
os ischii
1 rok / 1 year old

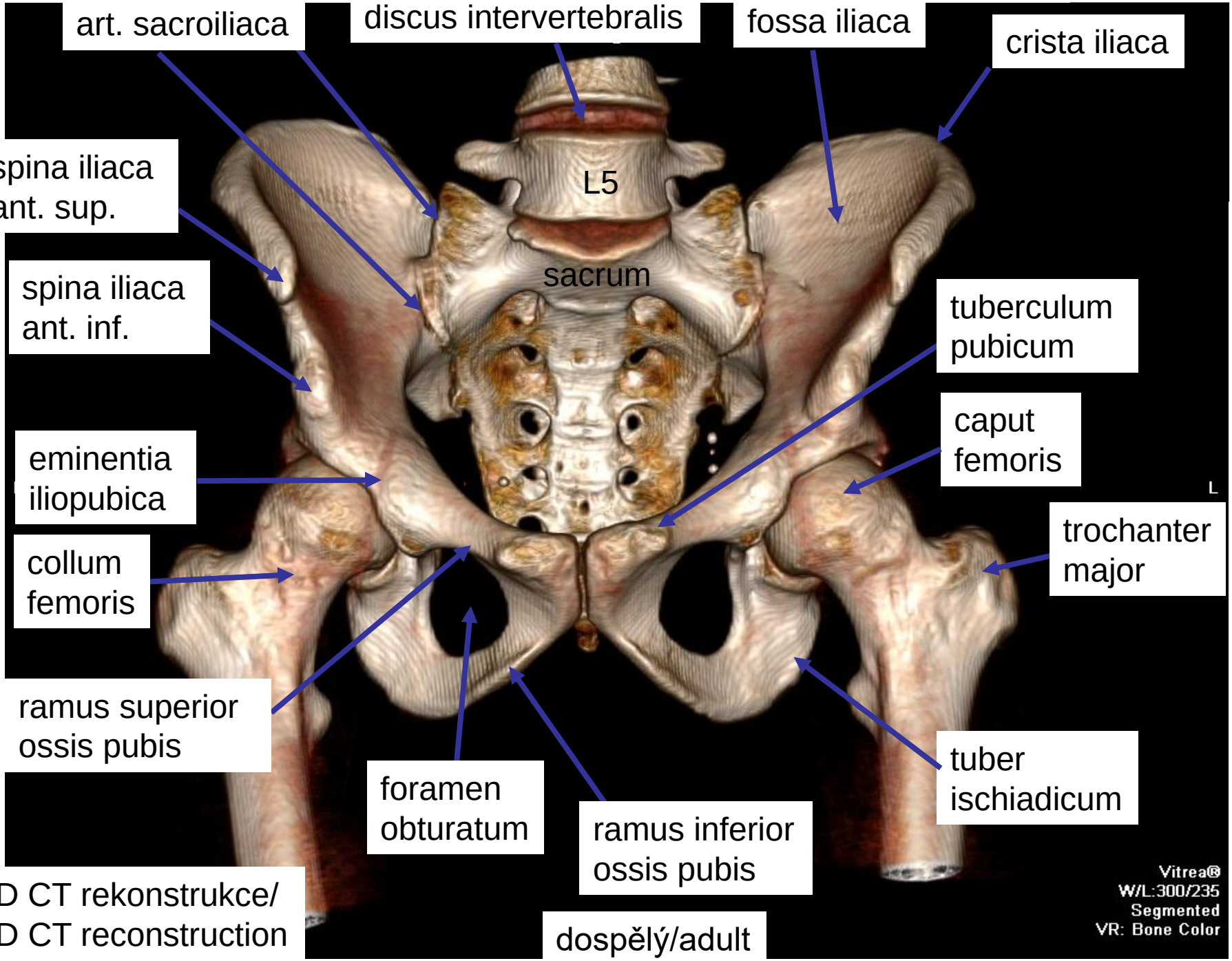

3D CT rekonstrukce/
3D CT reconstruction

dospělý/adult

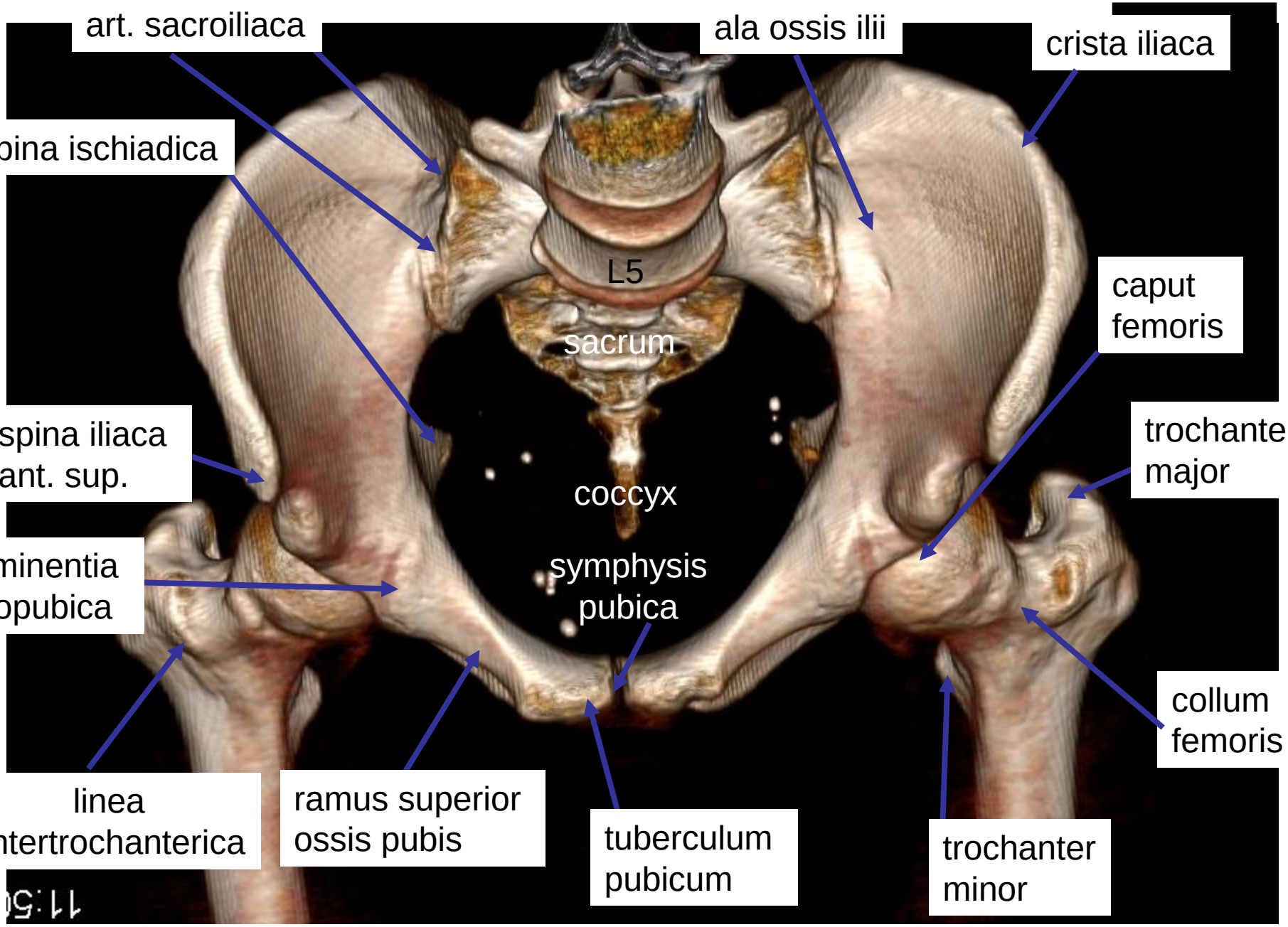

dospělý/adult

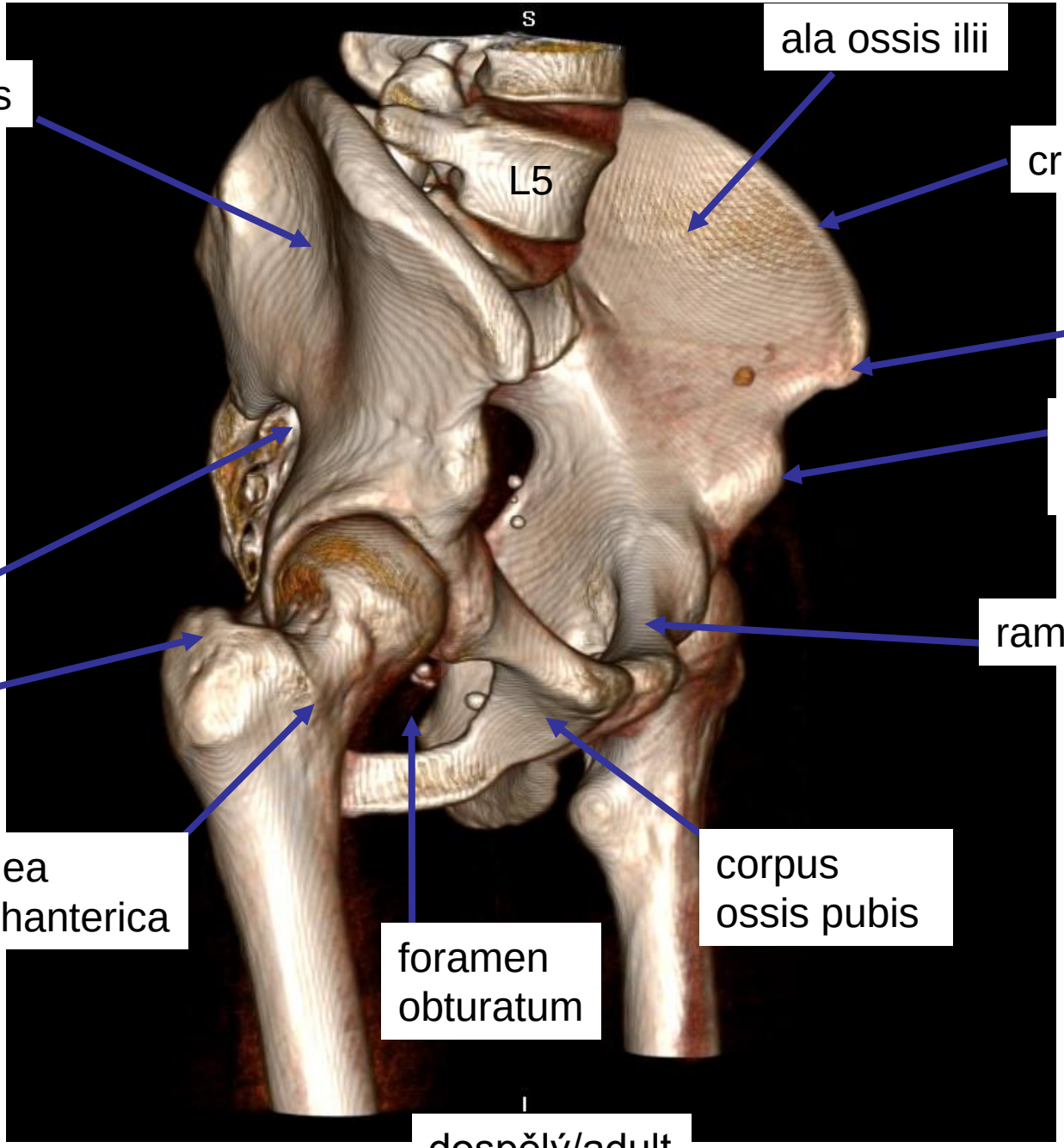

facies glutealis

ala ossis ilii

crista iliaca

spina iliaca ant. sup.

spina iliaca ant. inf.

incisura ischiadica major

ramus superior

trochanter major

linea intertrochanterica

foramen obturatum

corpus ossis pubis

dospělý/adult

Aditus pelvis

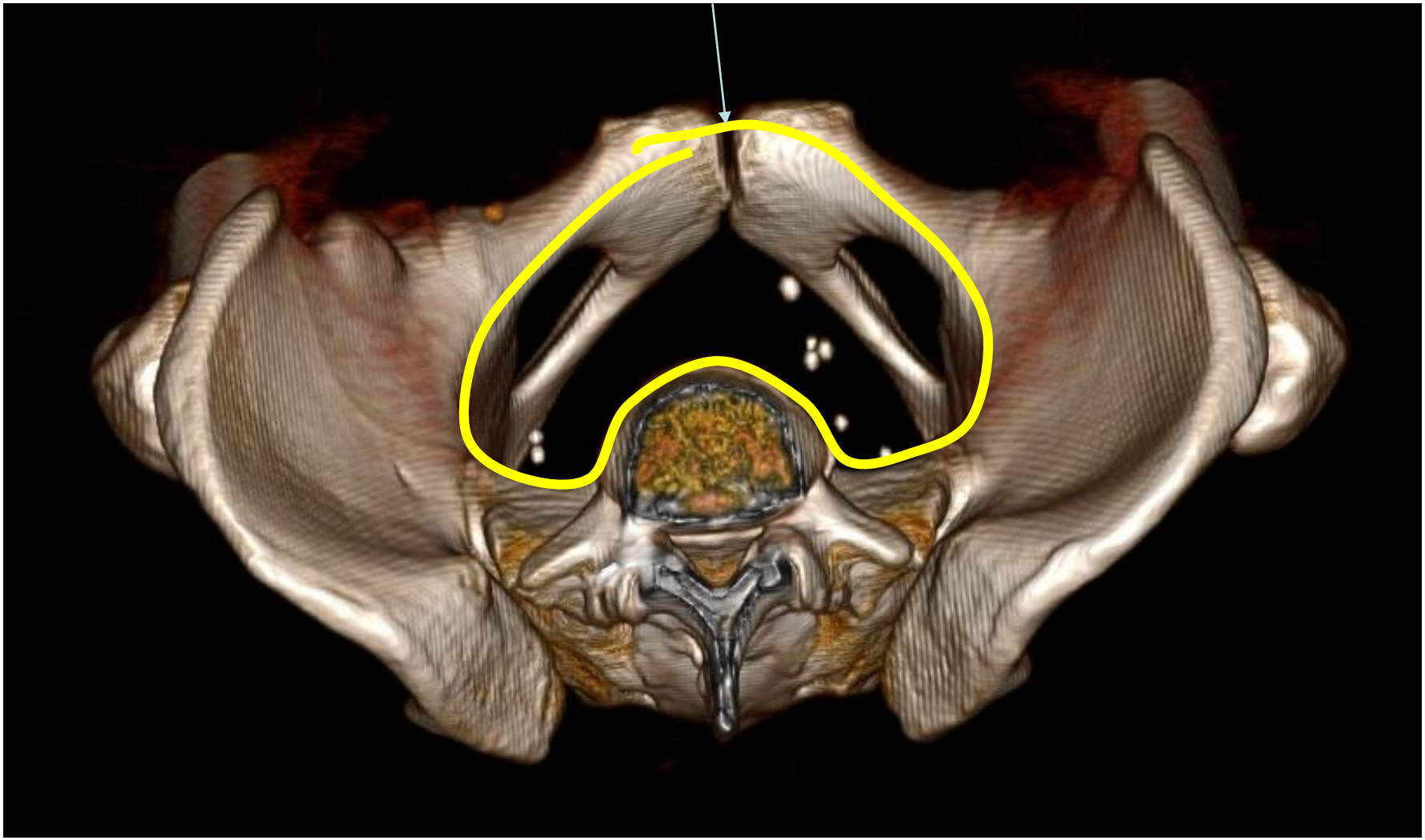

dospělý/adult

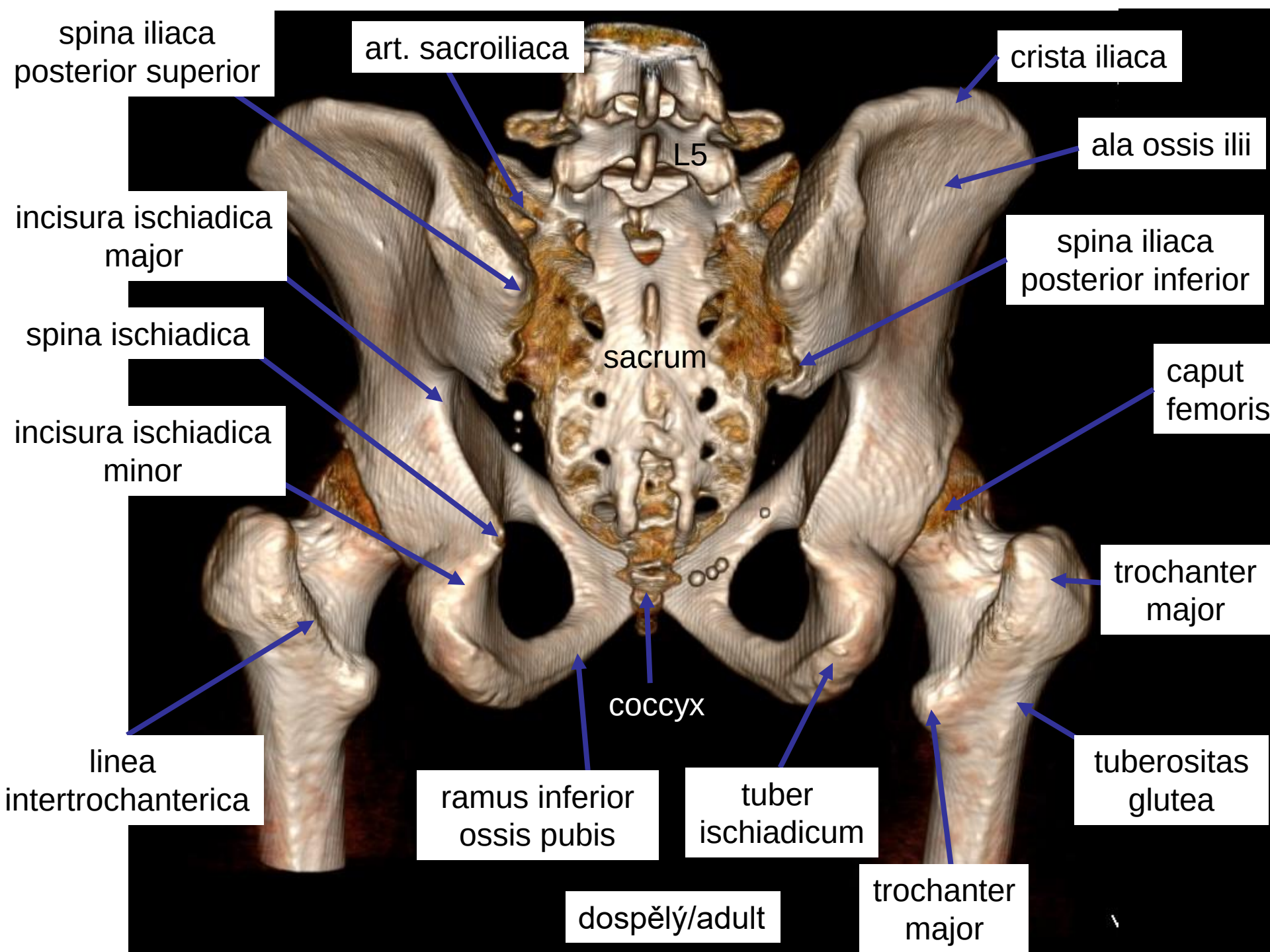
spina iliaca posterior superior
art. sacroiliaca
crista iliaca
L5
ala ossis ilii
incisura ischiadica major
spina iliaca posterior inferior
spina ischiadica
sacrum
caput femoris
incisura ischiadica minor
trochanter major
coccyx
linea intertrochanterica
ramus inferior ossis pubis
tuber ischiadicum
tuberositas glutea
trochanter major
dospělý/adult

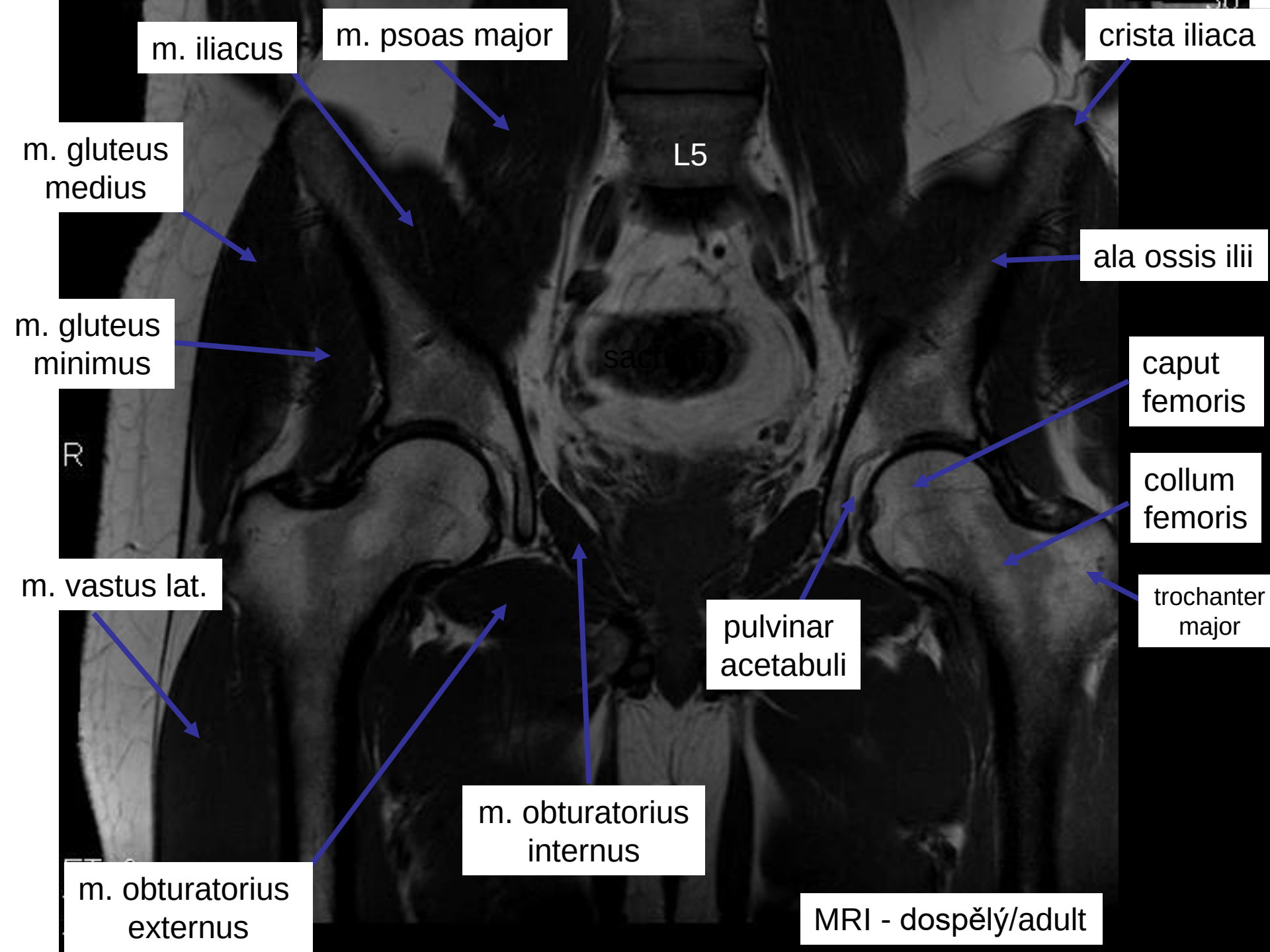
m. iliacus
m. psoas major
crista iliaca
L5
m. gluteus medius
ala ossis ilii
m. gluteus minimus
caput femoris
R
collum femoris
m. vastus lat.
trochanter major
pulvinar acetabuli
m. obturatorius internus
m. obturatorius externus
MRI - dospělý/adult

Fr. pertrochanterica femoris l. sin.

dospělý/adult

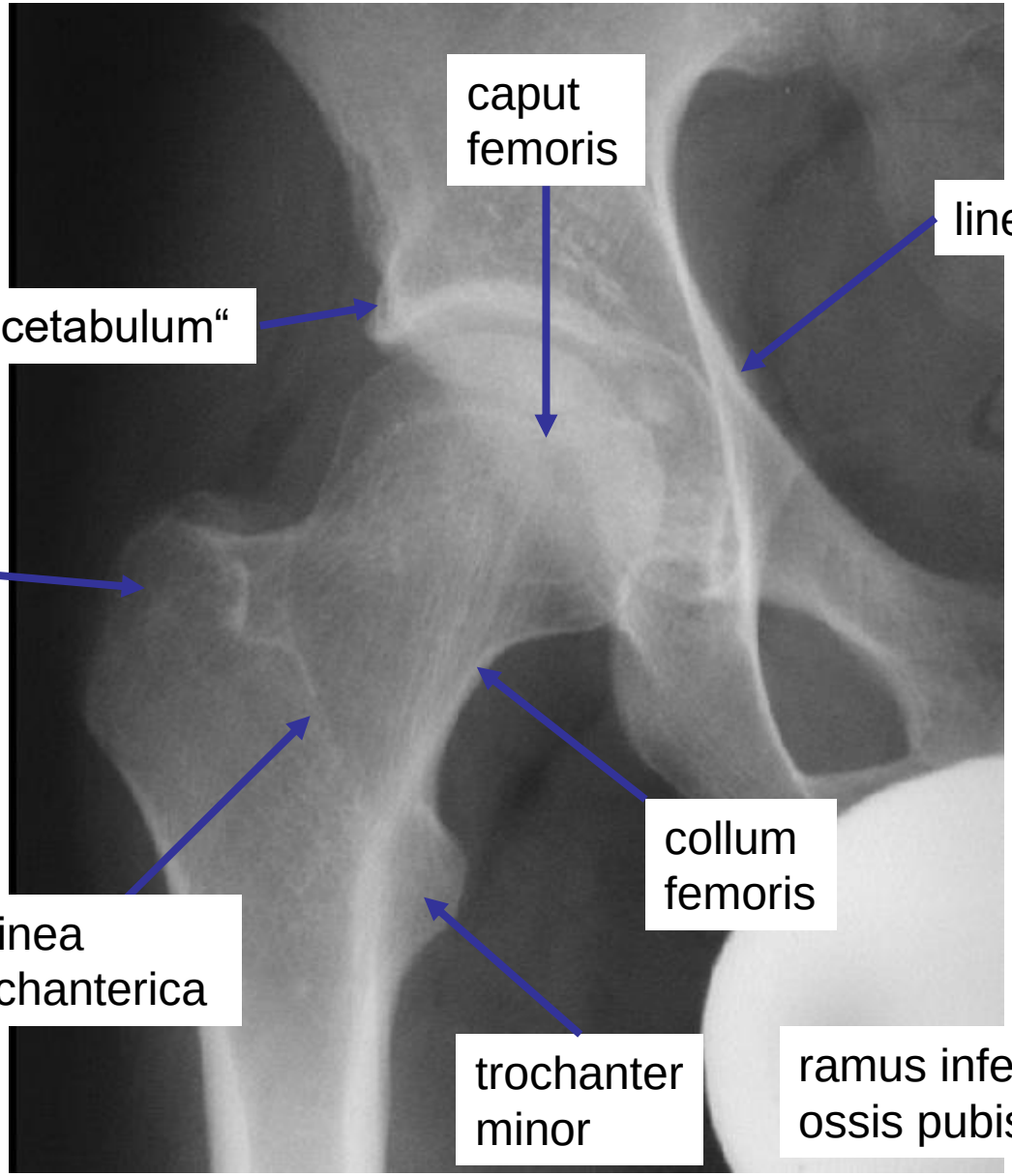

dospělý/adult

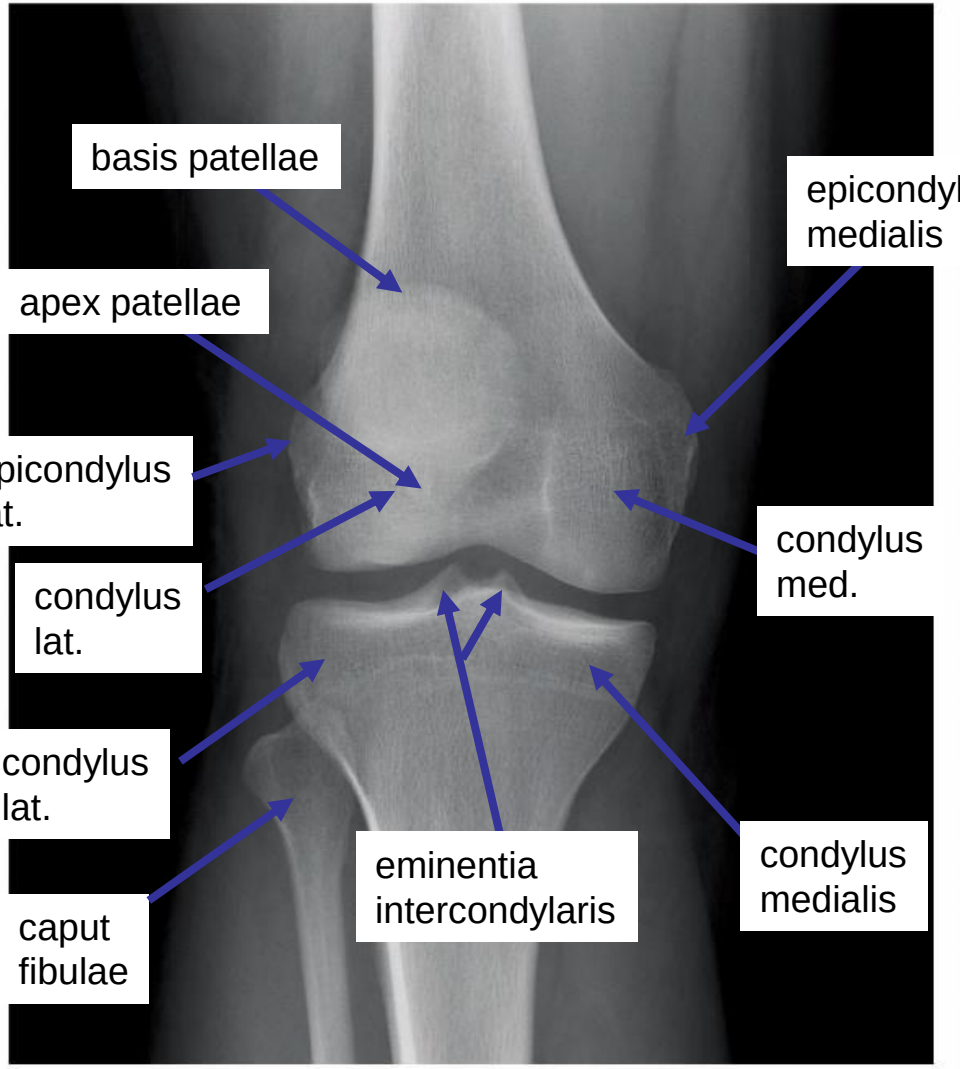

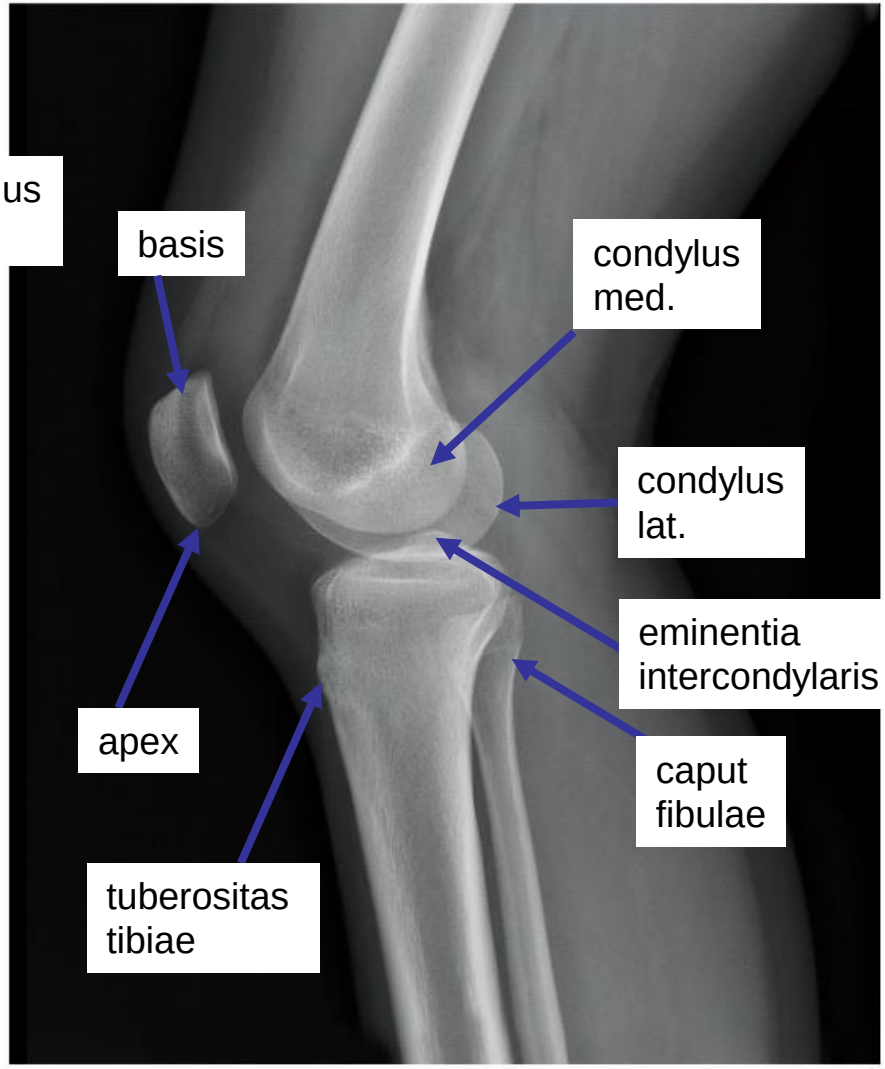

dospělý/adult

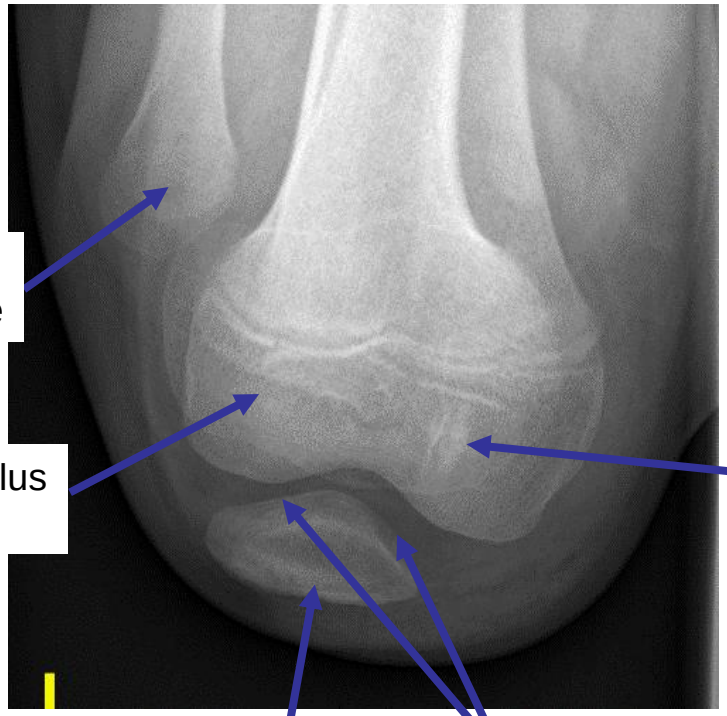
caput fibulae
condylus lat.
condylus med.
patella
facies articularis

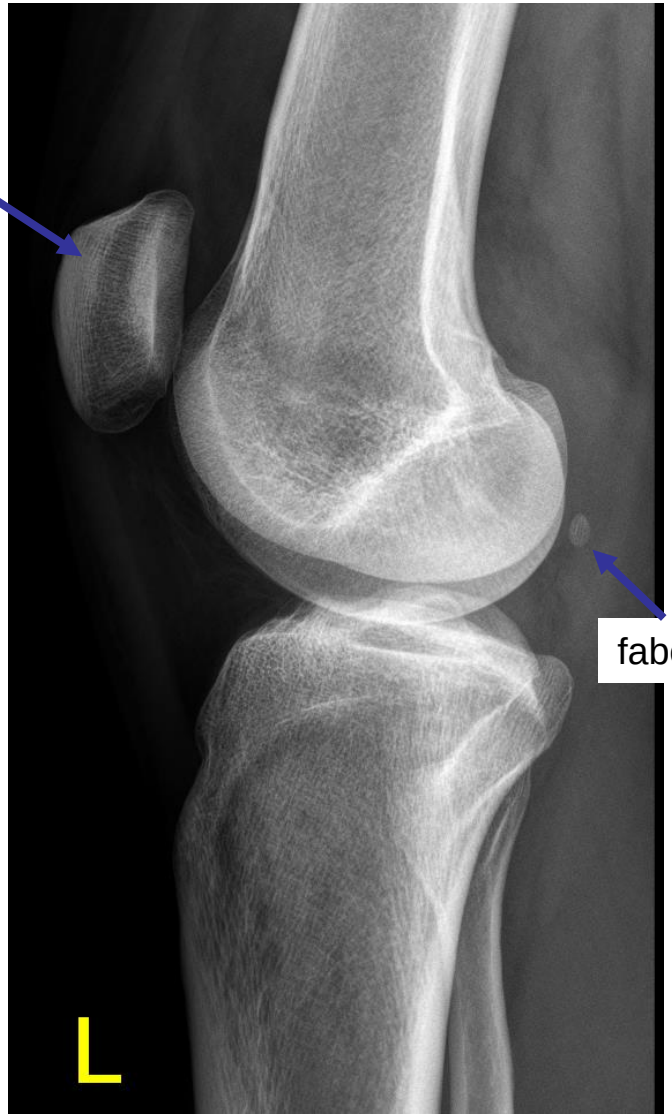
patella
fabella
L

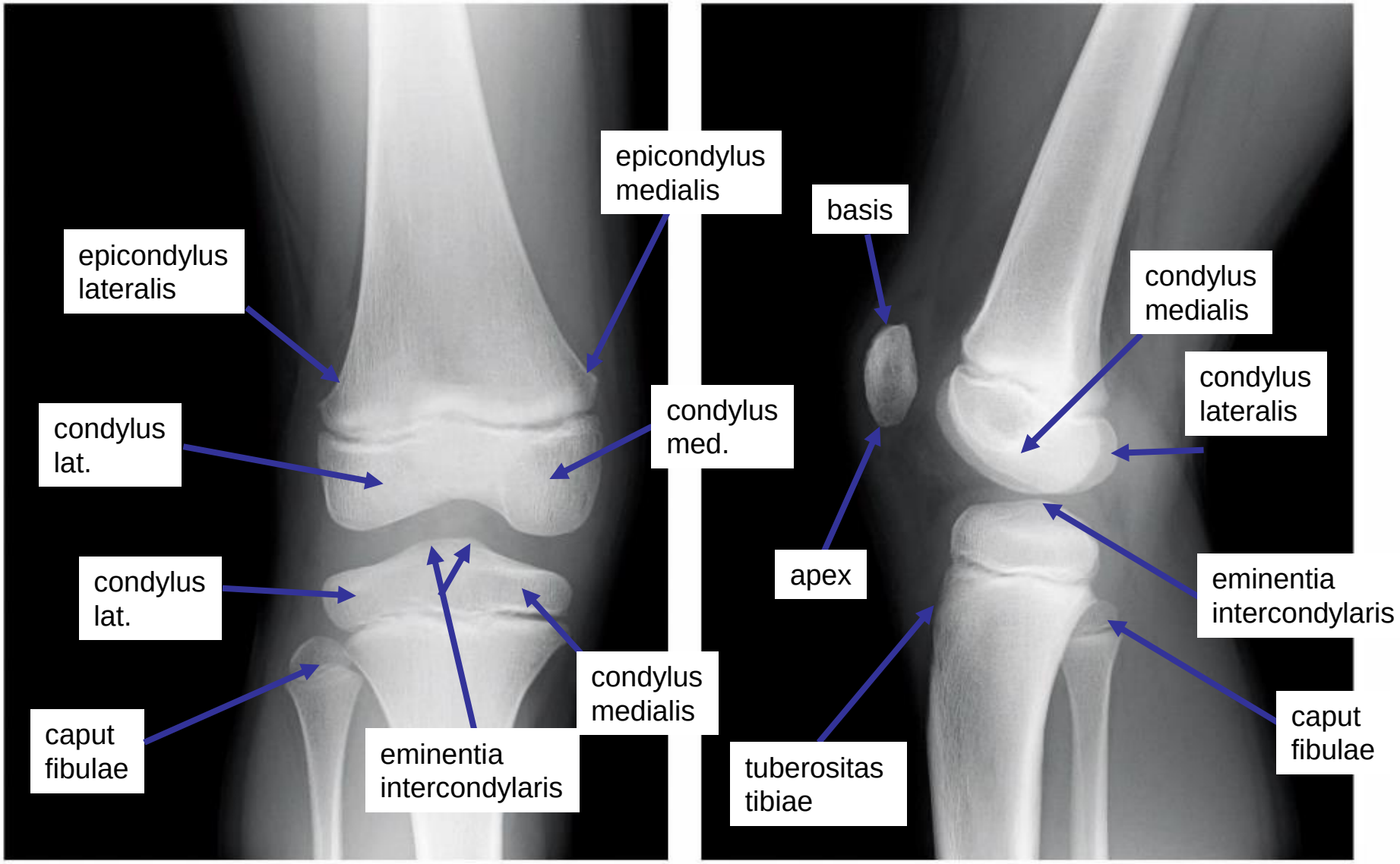

dítě 8 let / 8 years old

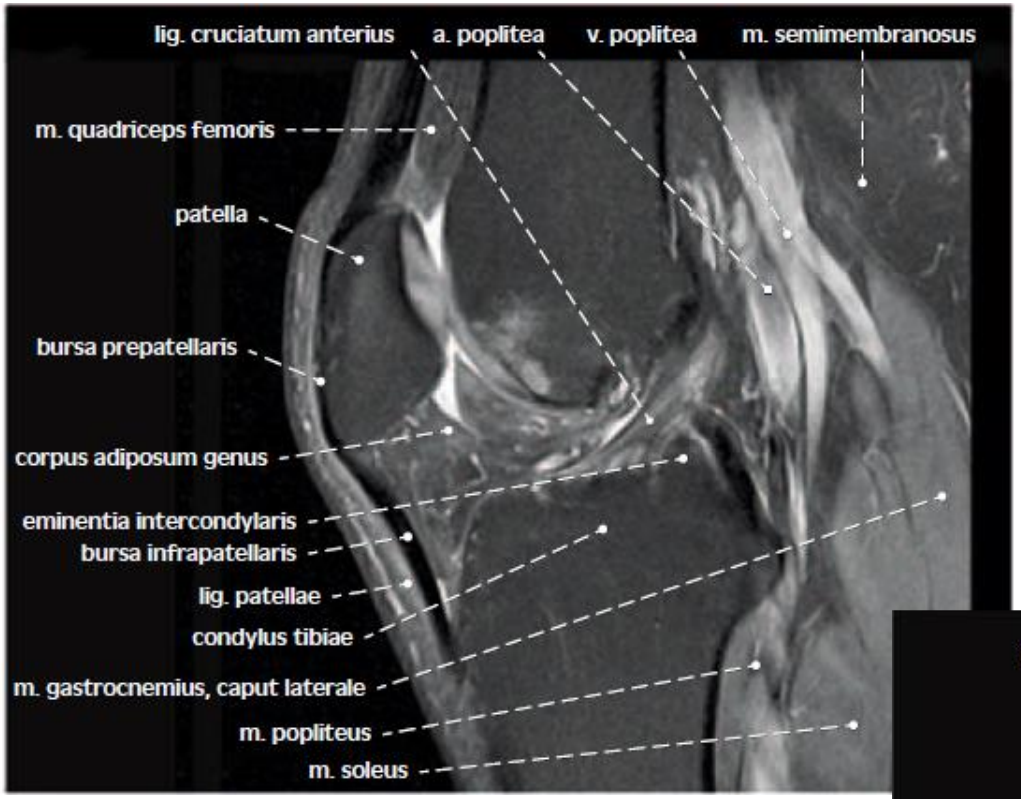
lig. cruciatum anterius
a. poplitea
v. poplitea
m. semimembranosus
m. quadriceps femoris
patella
bursa prepatellaris
corpus adiposum genus
eminentia intercondylaris
bursa infrapatellaris
lig. patellae
condylus tibiae
m. gastrocnemius, caput laterale
m. popliteus
m. soleus

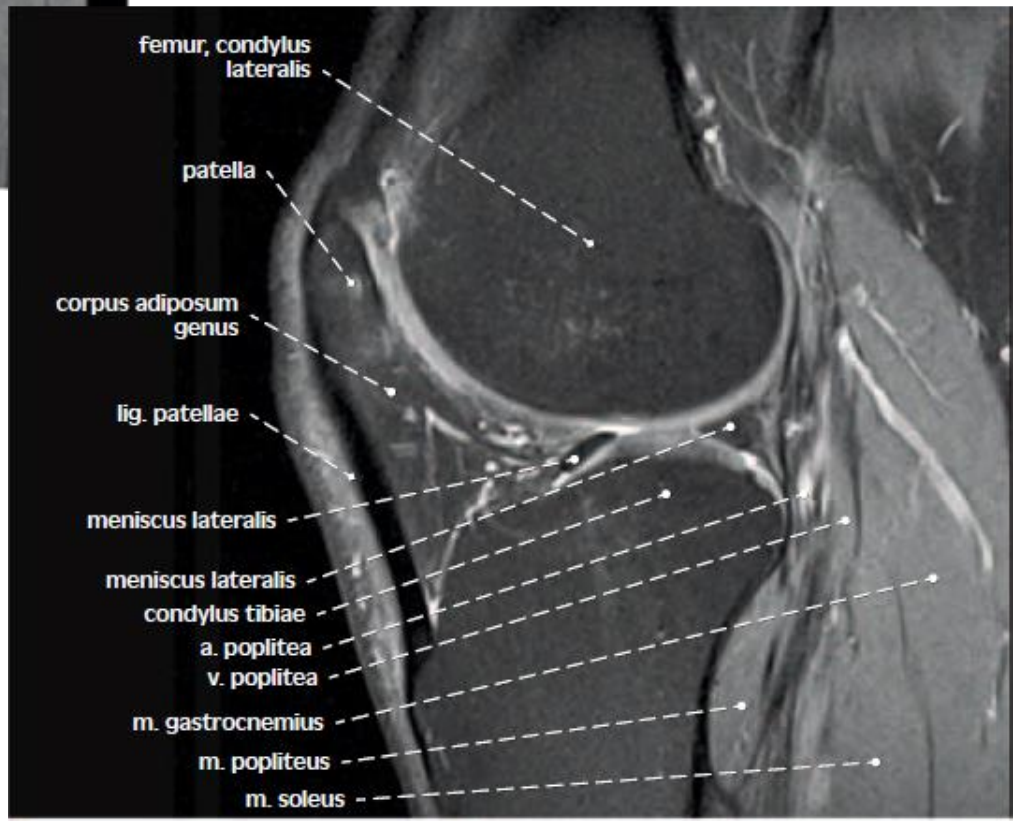
femur, condylus lateralis
patella
corpus adiposum genus
lig. patellae
meniscus lateralis
meniscus lateralis
condylus tibiae
a. poplitea
v. poplitea
m. gastrocnemius
m. popliteus
m. soleus

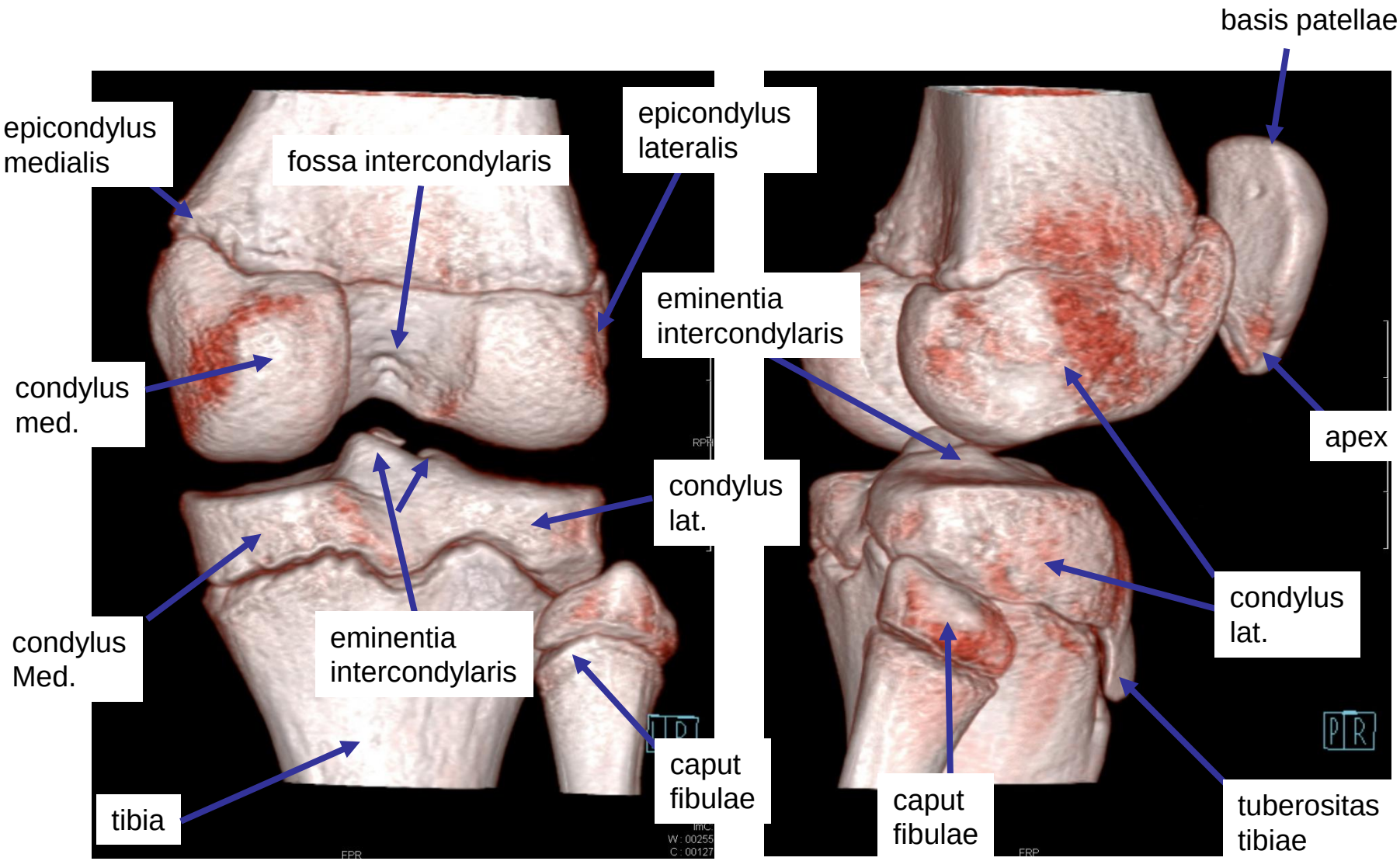

dítě 8 let / 8 years old

Fr. patellae dislocata

dospělý/adult

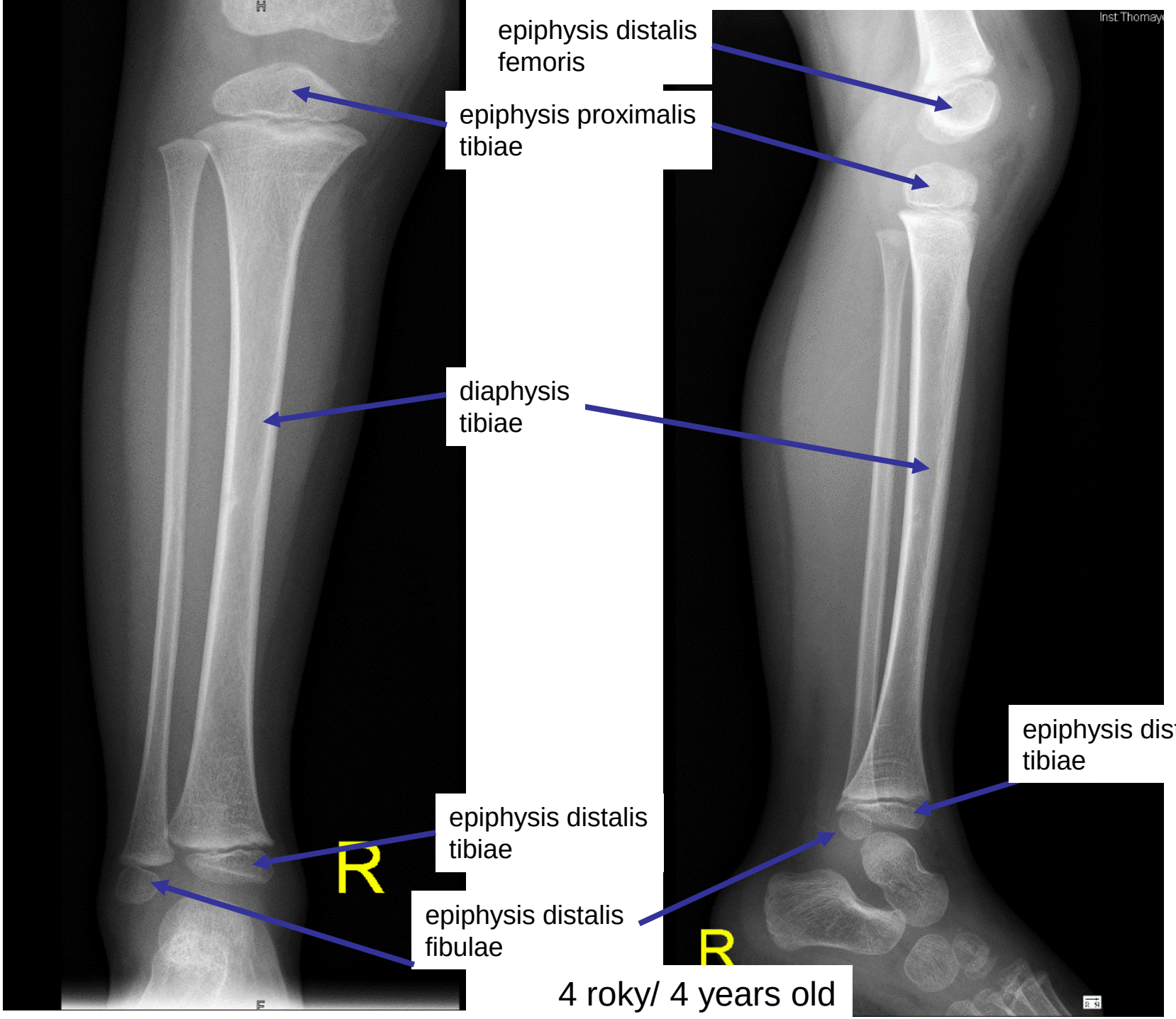

4 roky/ 4 years old

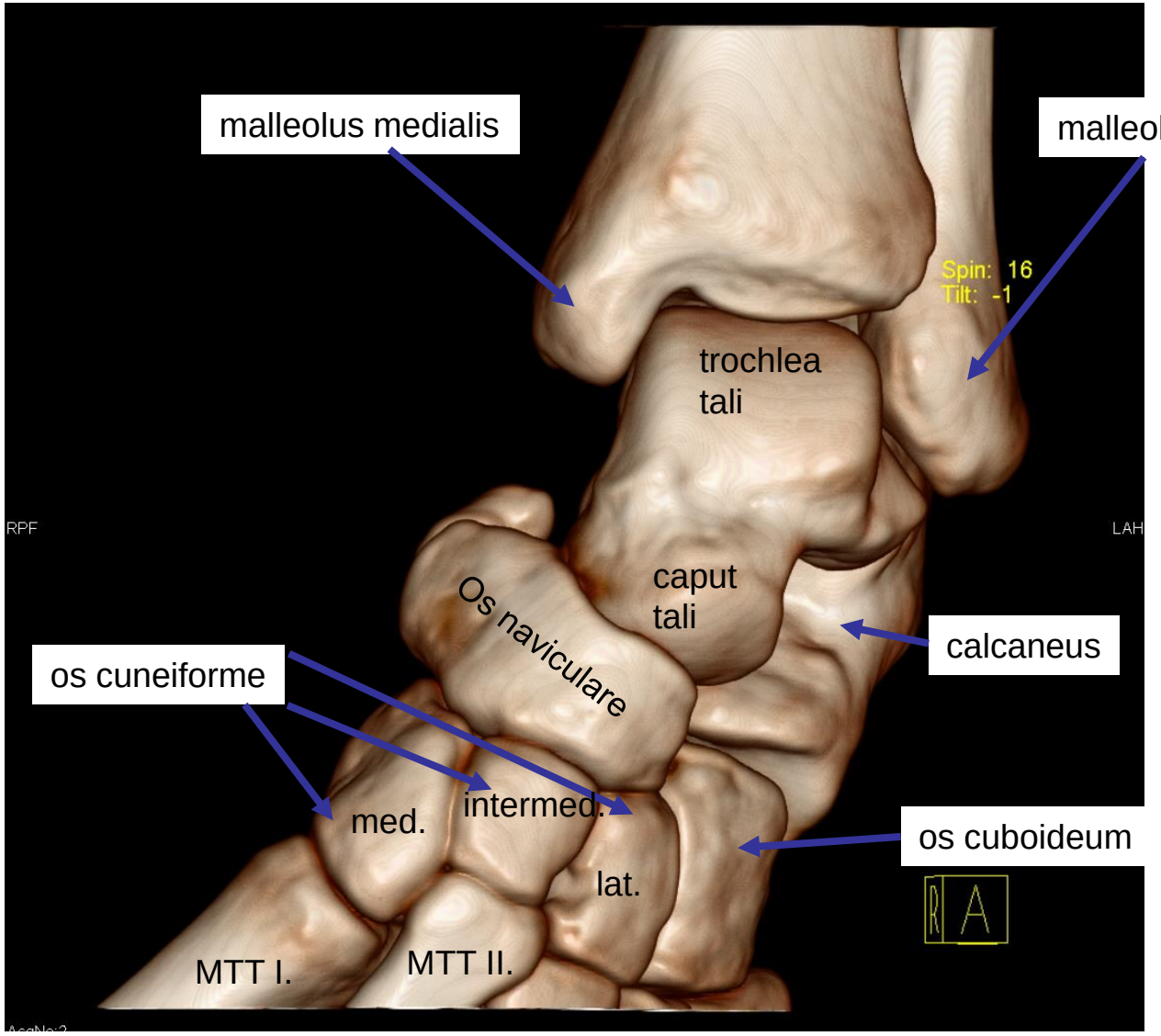

dospělý/adult

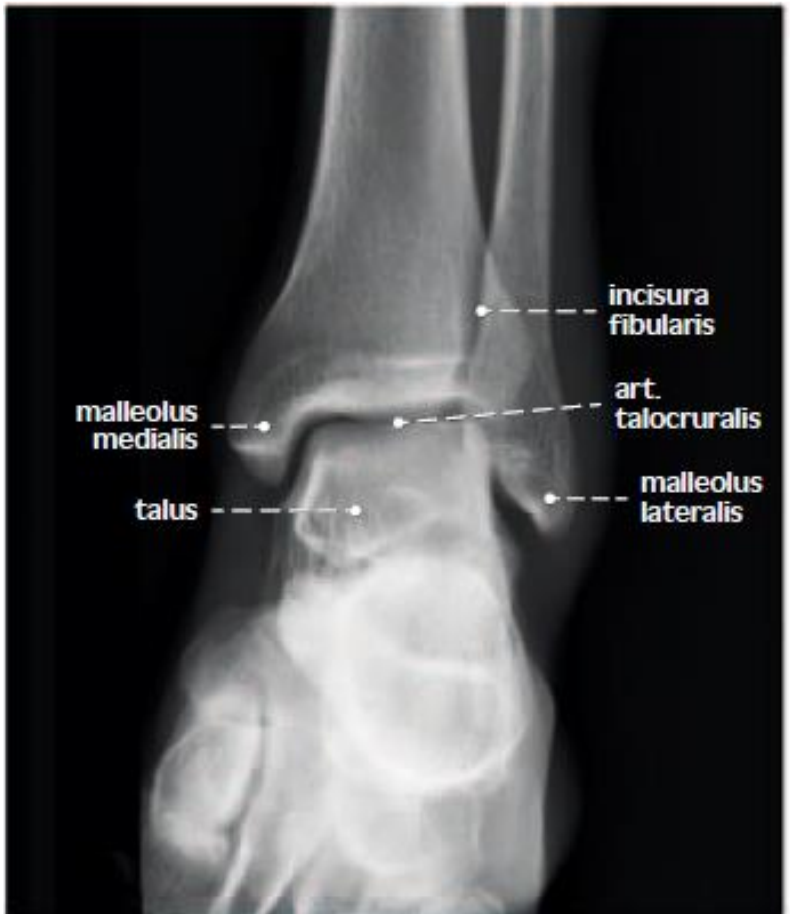

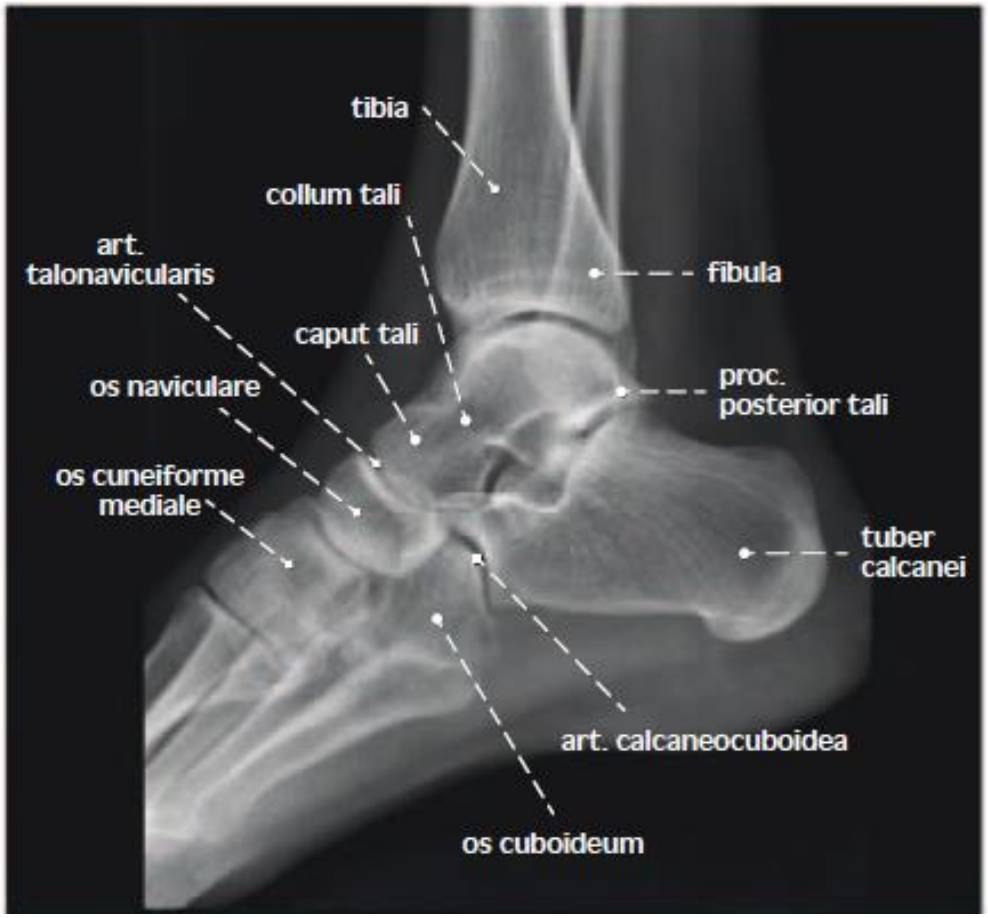

dospělý/adult

Fr. malleoli medialis tibiae dislocata

dospělý/adult

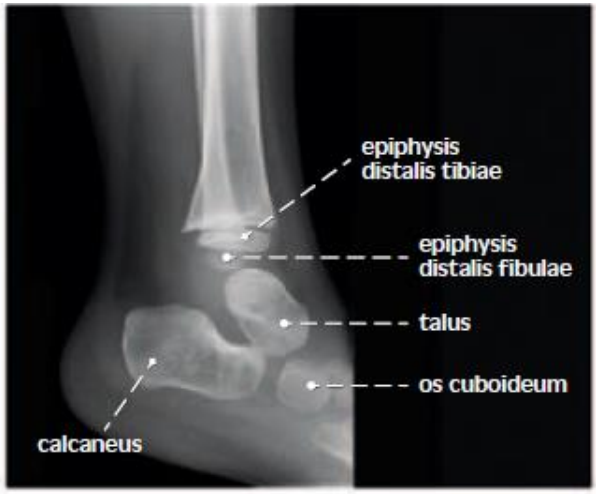

3 roky + 9 měsíců/ 3 years and 9 months

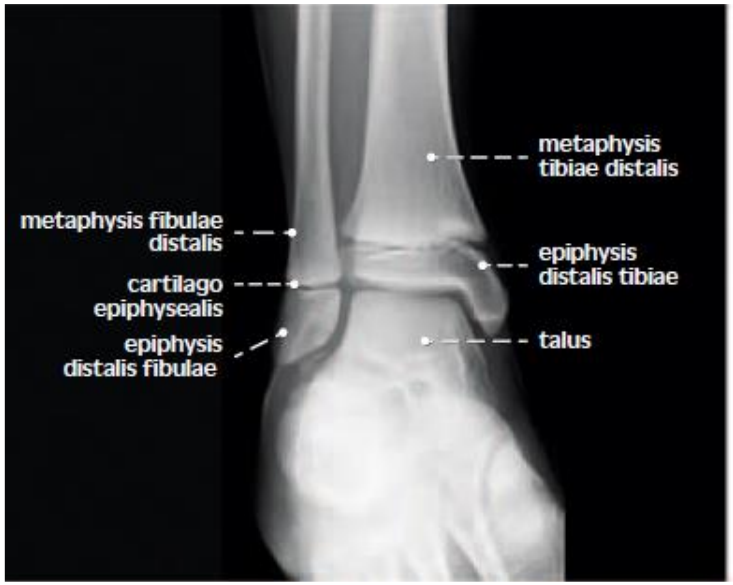

10 let/ 10 years

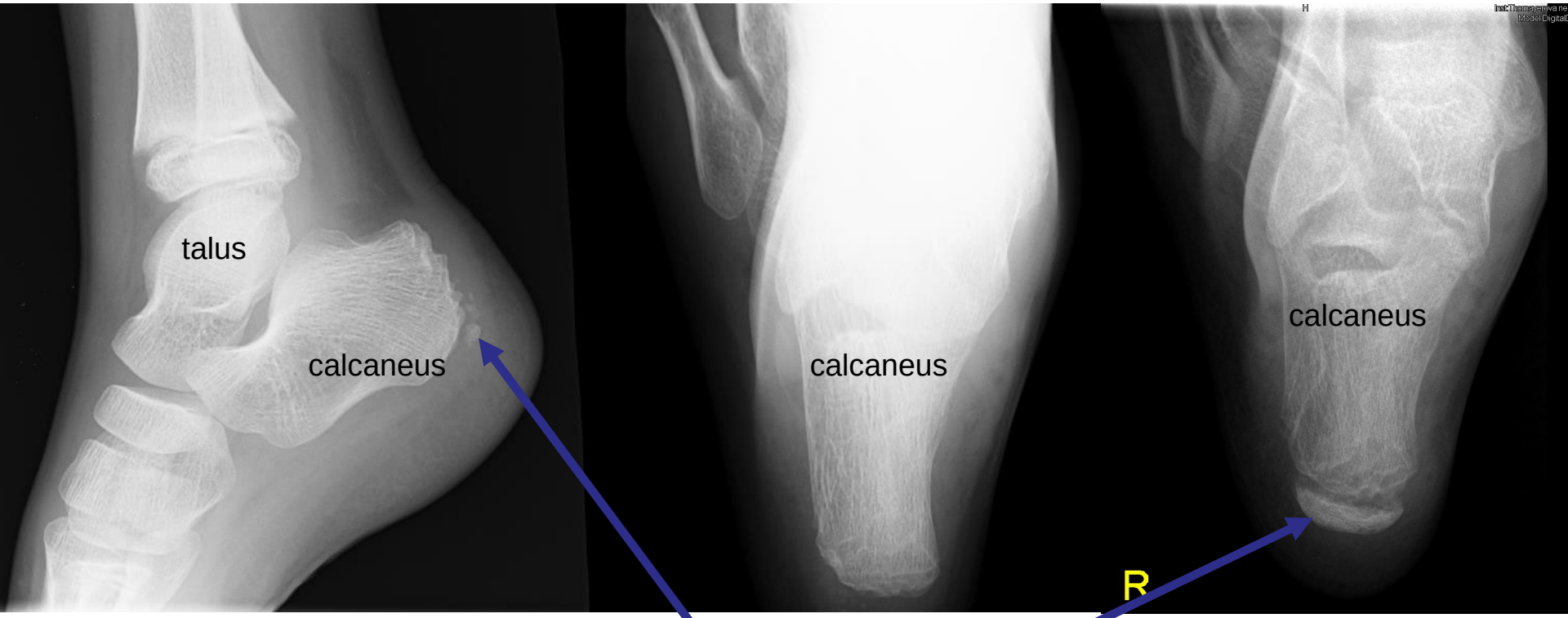

apophysis calcanei

dětský věk/ childhood

phalanx distalis
phalanx media
phalanx proximalis
os sesamoideum med.
os sesamoideum lat.
metatarsus I
os cuneiforme intermed.
os cuneiforme med.
os cuneiforme lat.
os cuboideum
os naviculare
talus
malleolus lateralis
malleolus medialis
phalanx distalis
phalanx media
caput
corpus
basis
caput
os sesamoideum med.
os sesamoideum lat.
corpus
os cuneiforme med.
basis
tuberositas ossis metatarsi V
os cuneiforme lat.
os cuneiforme intermed.
os cuboideum
os naviculare
sinus tarsi
calcaneus
talus

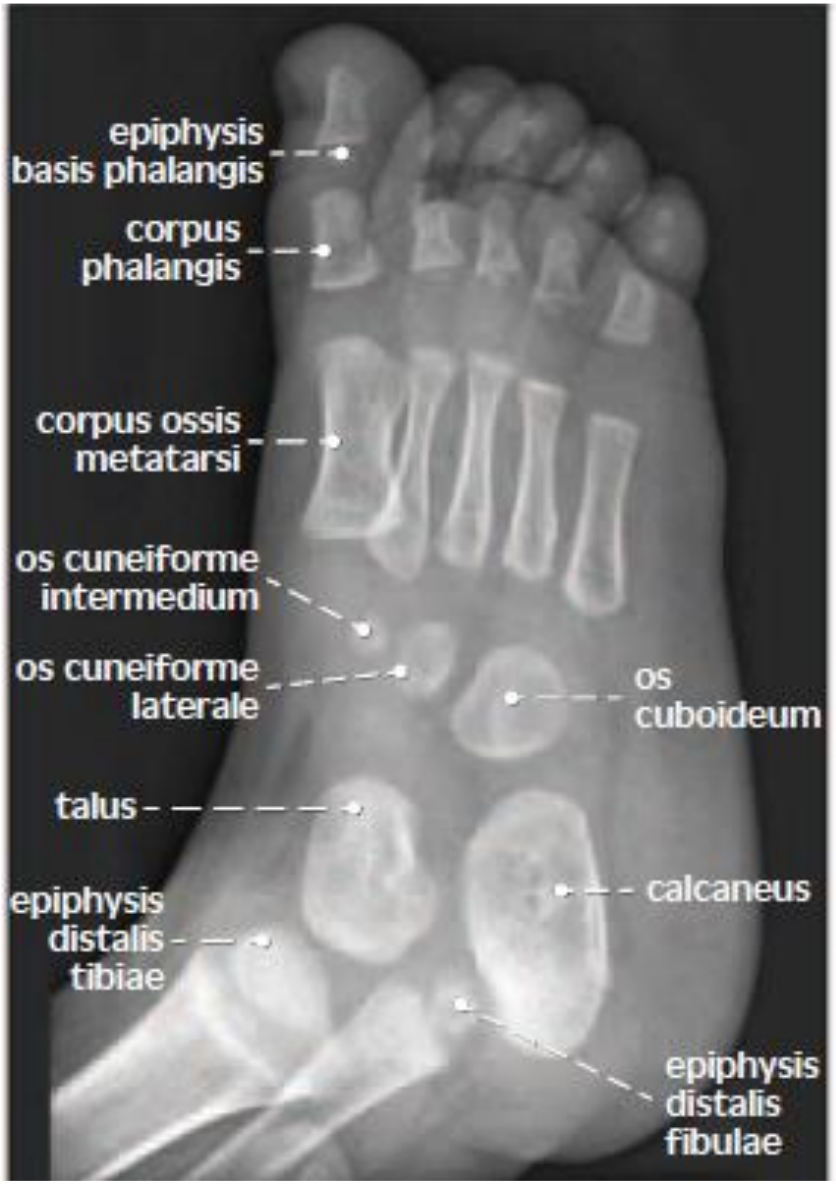

lateral view (boy, 1 year and 4 months)

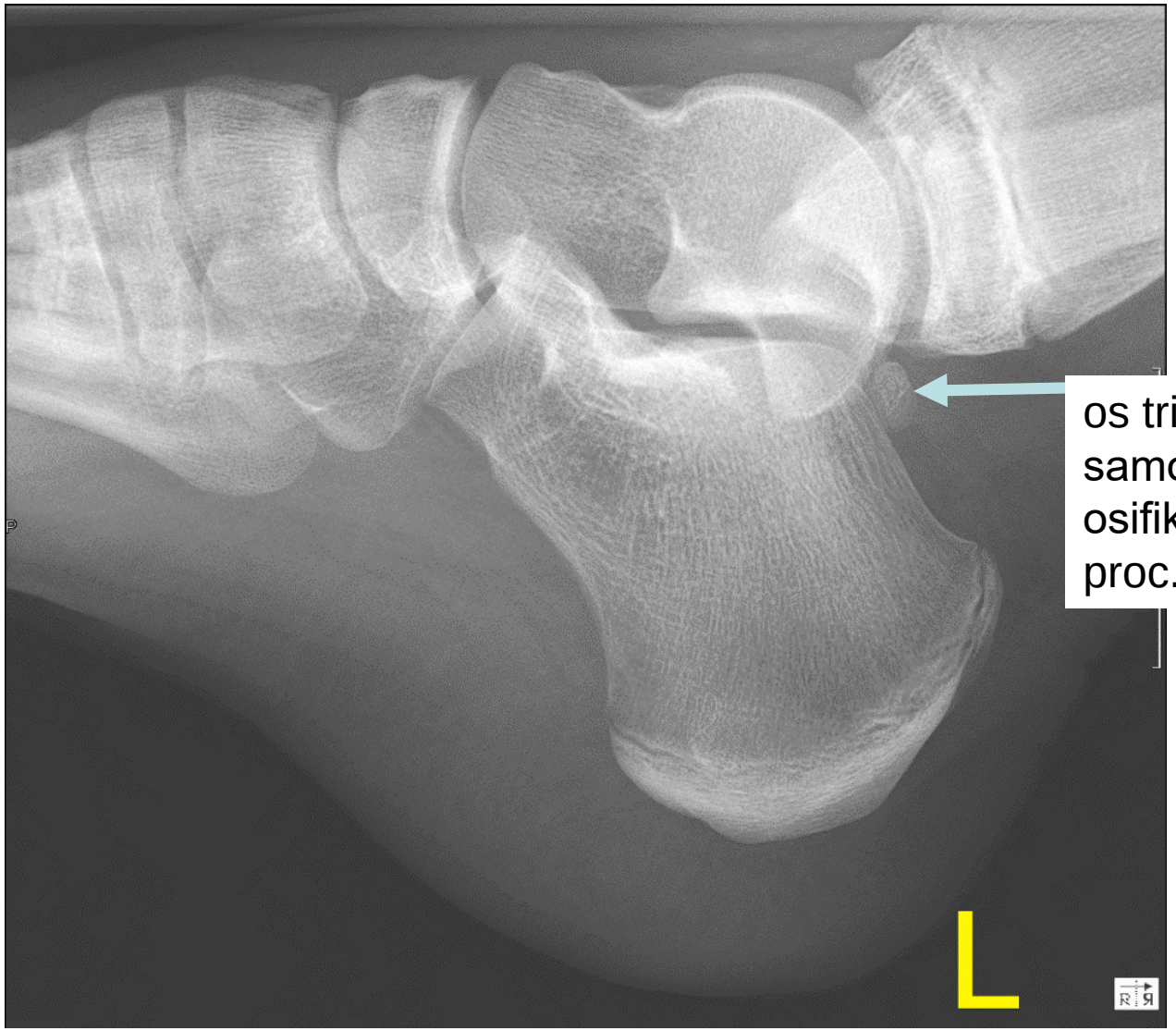

11 let / 11 years old

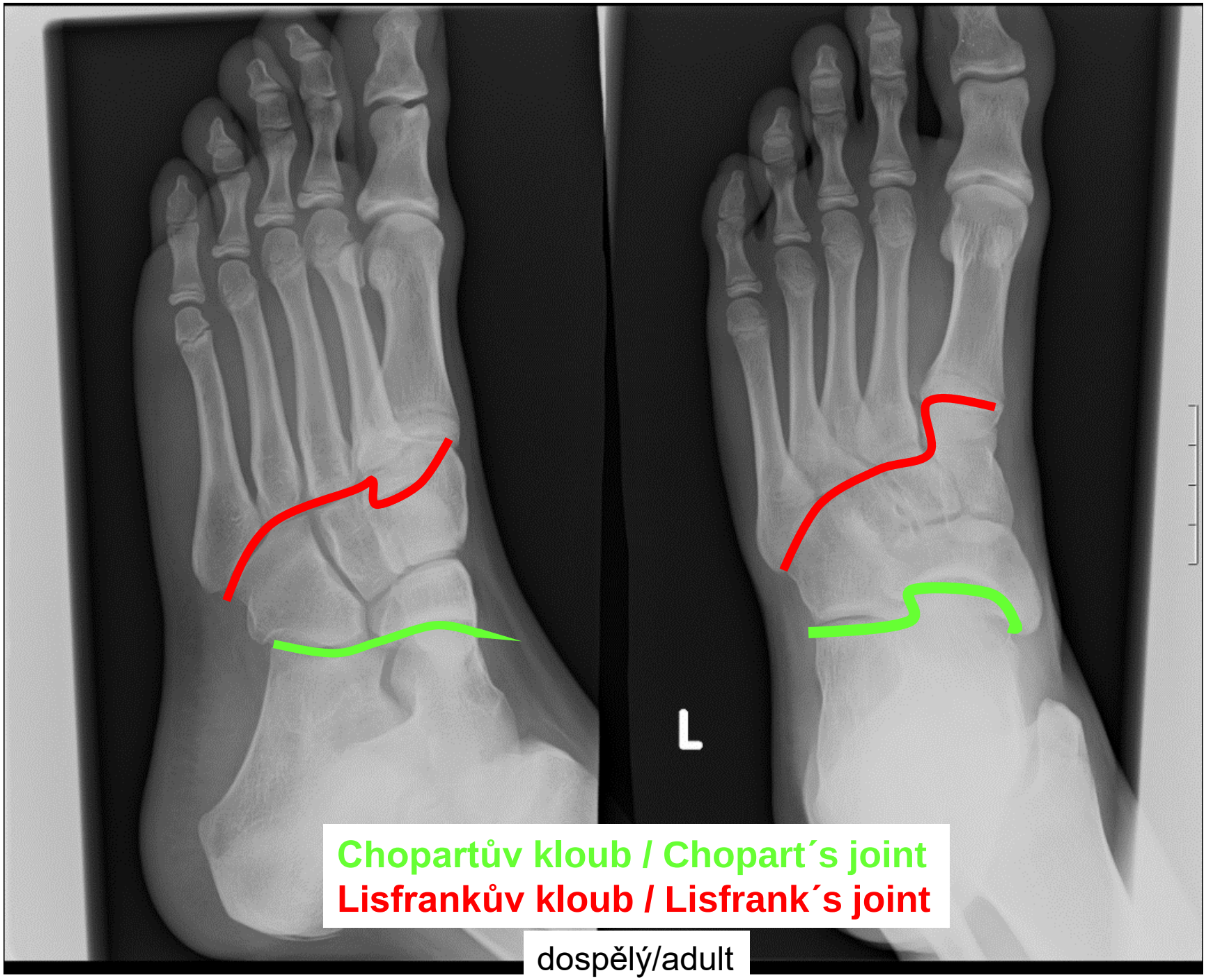
L
Chopartův kloub / Chopart´s joint
Lisfrankův kloub / Lisfrank´s joint
dospělý/adult

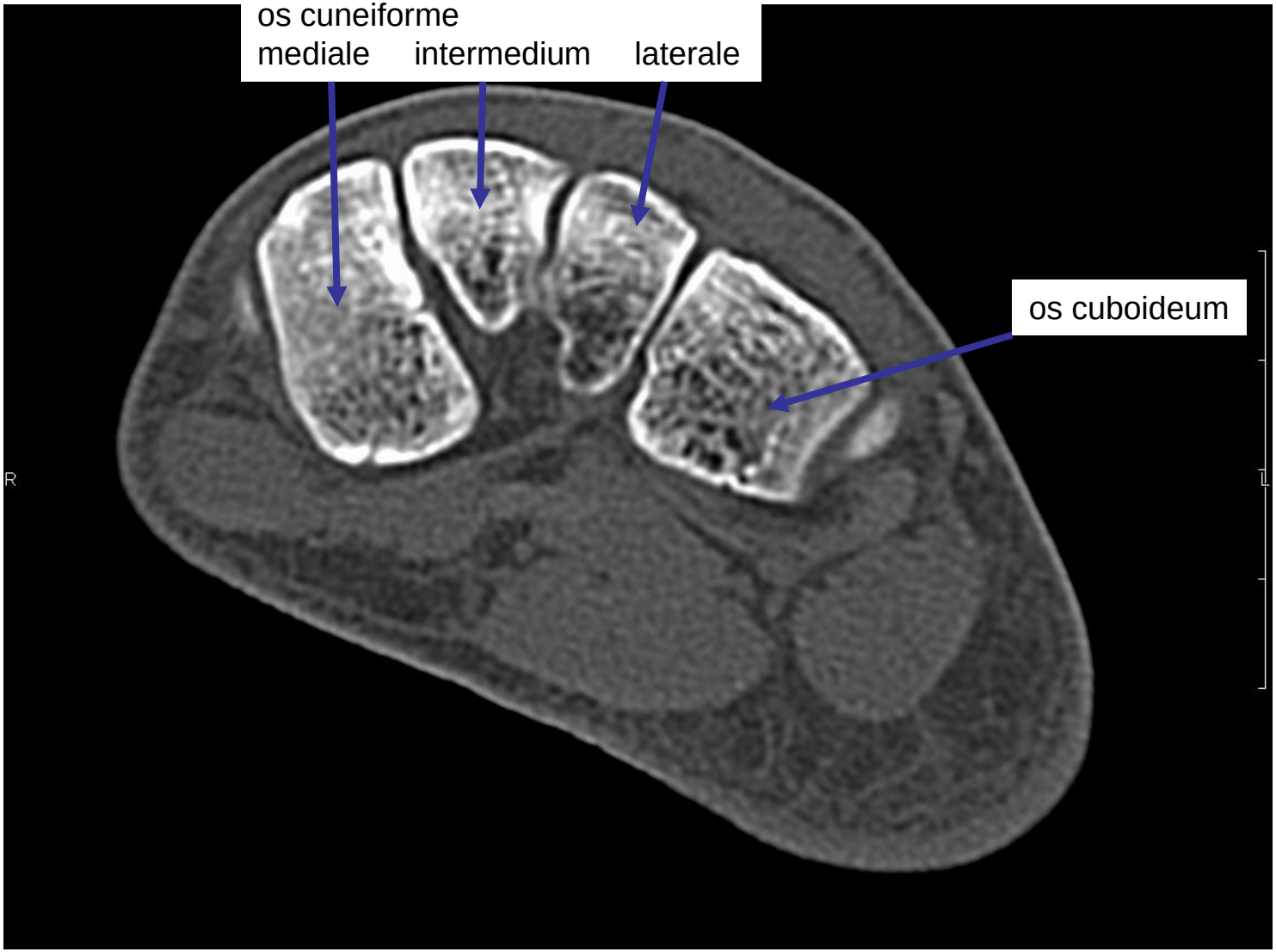

MRI dospělý/adult