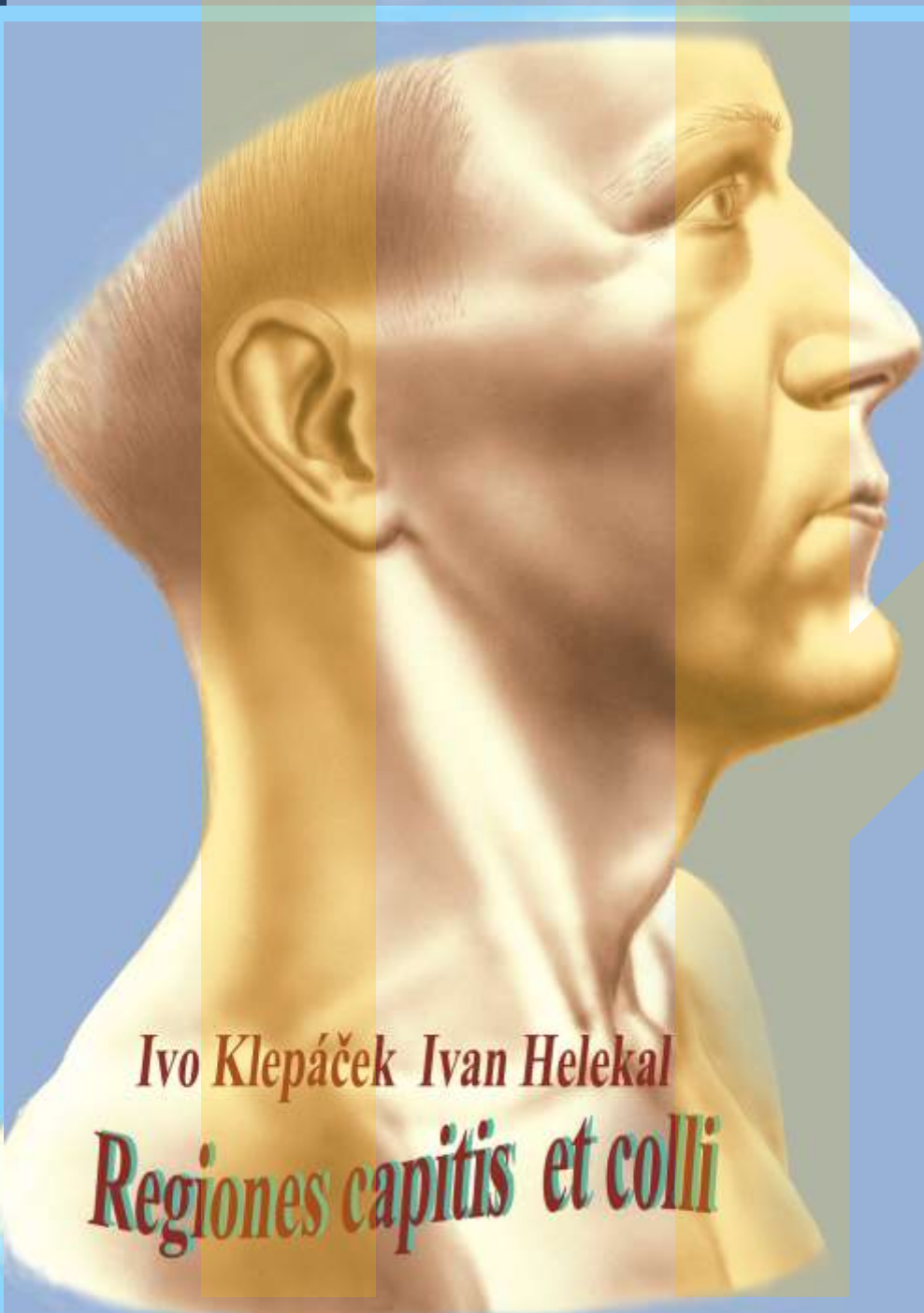




Hlava head
Krk Neck

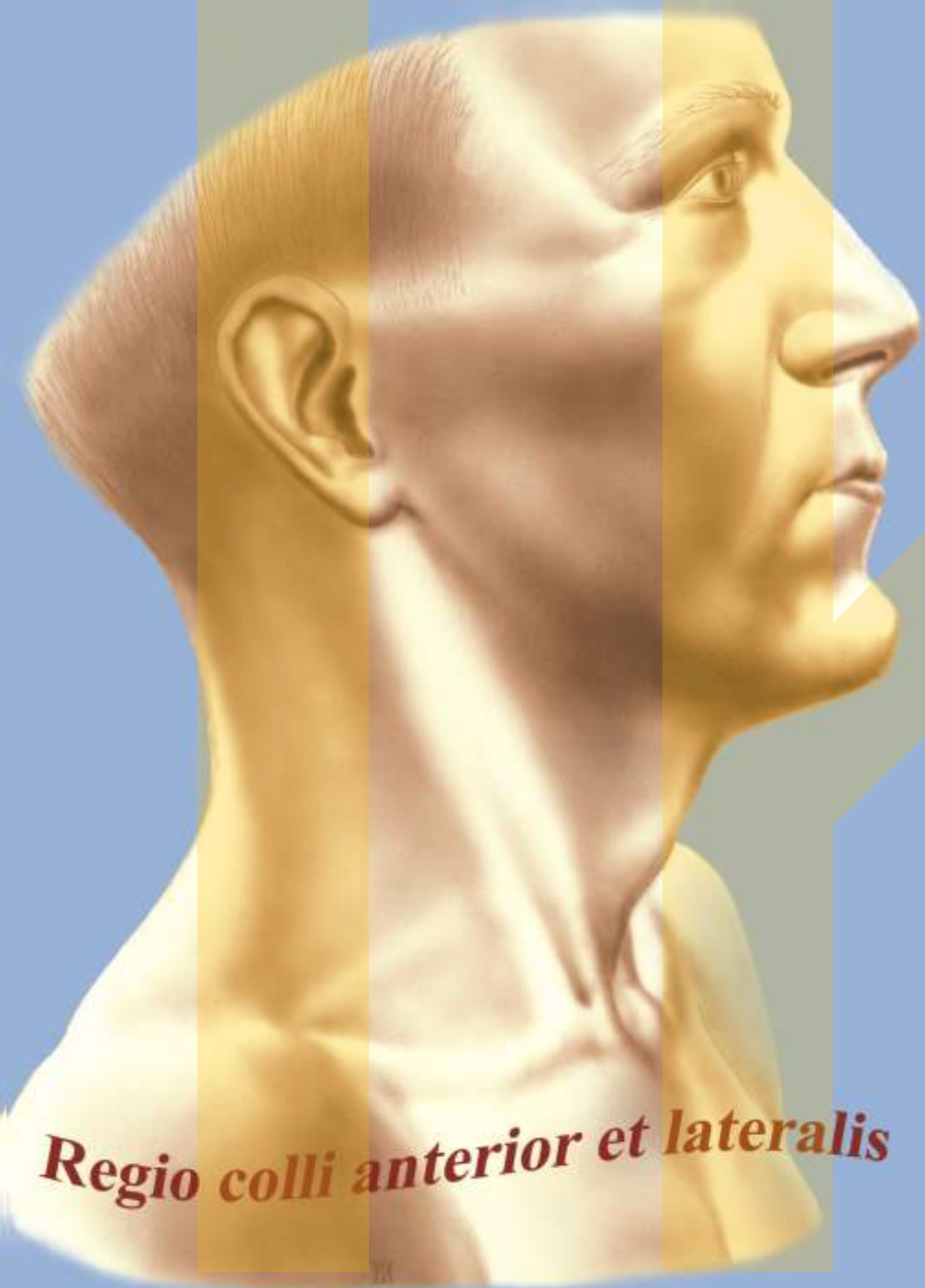
topografie
topography

Ivo Klepáček

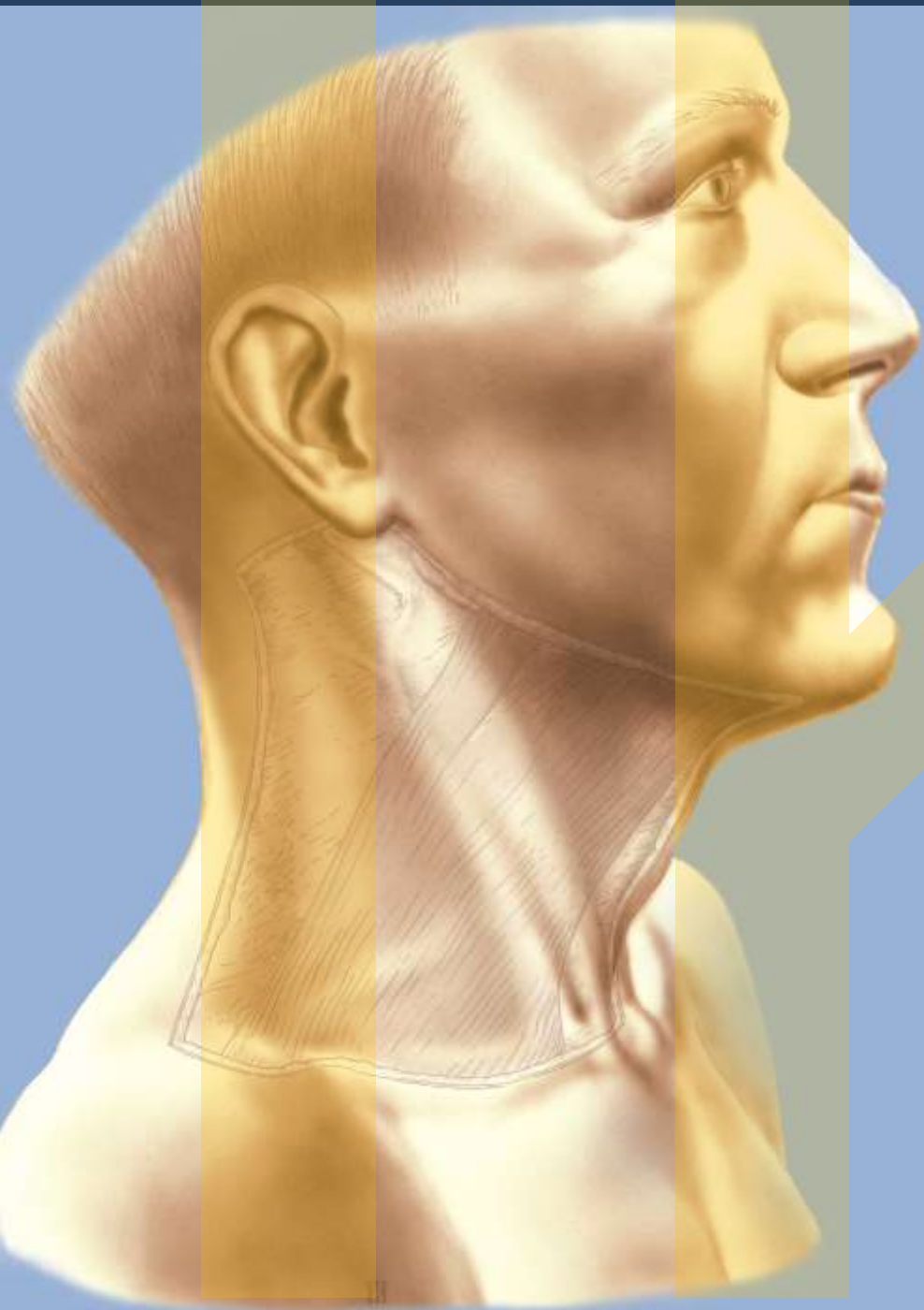


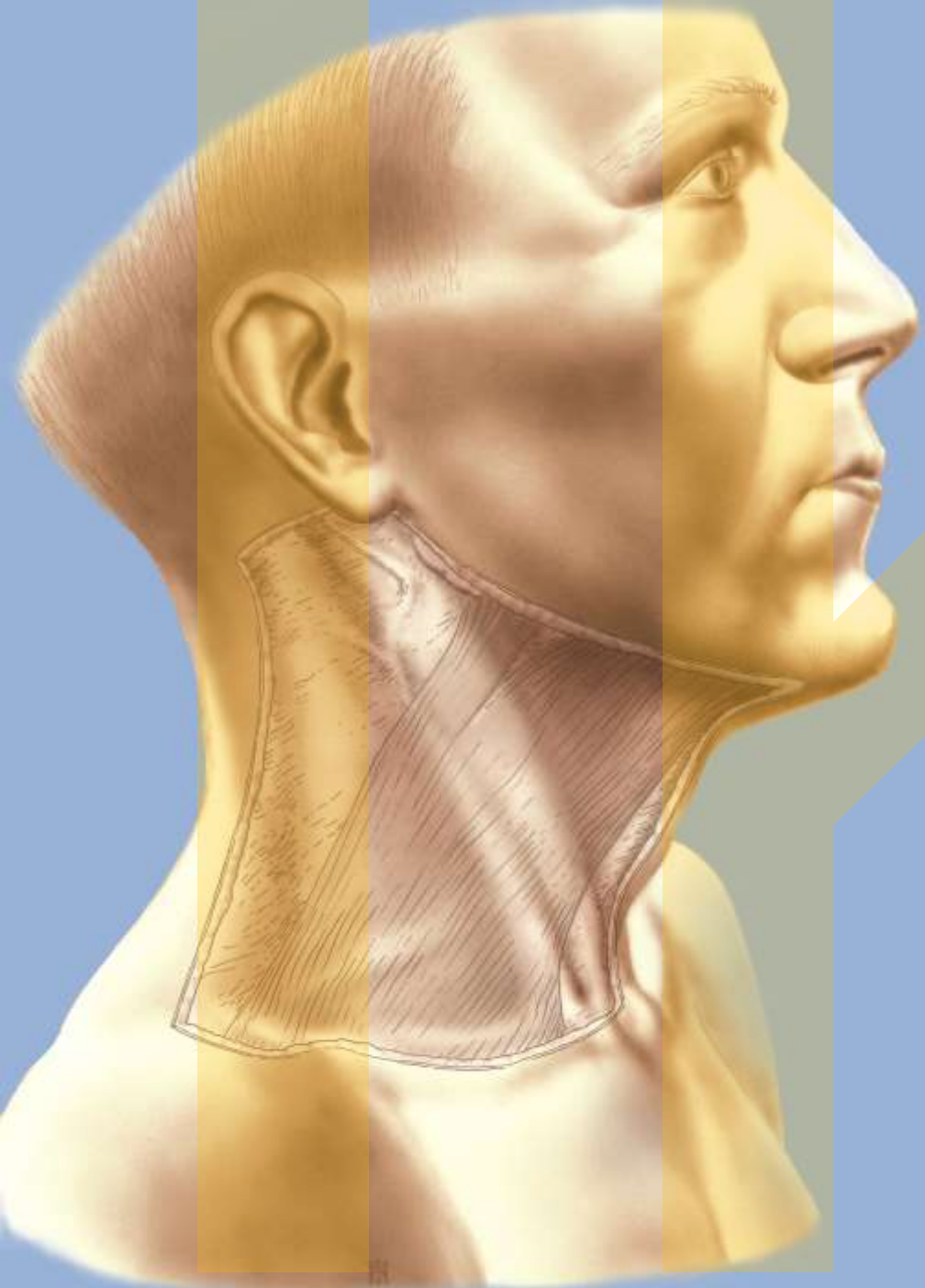
Ivo Klepáček Ivan Helekal

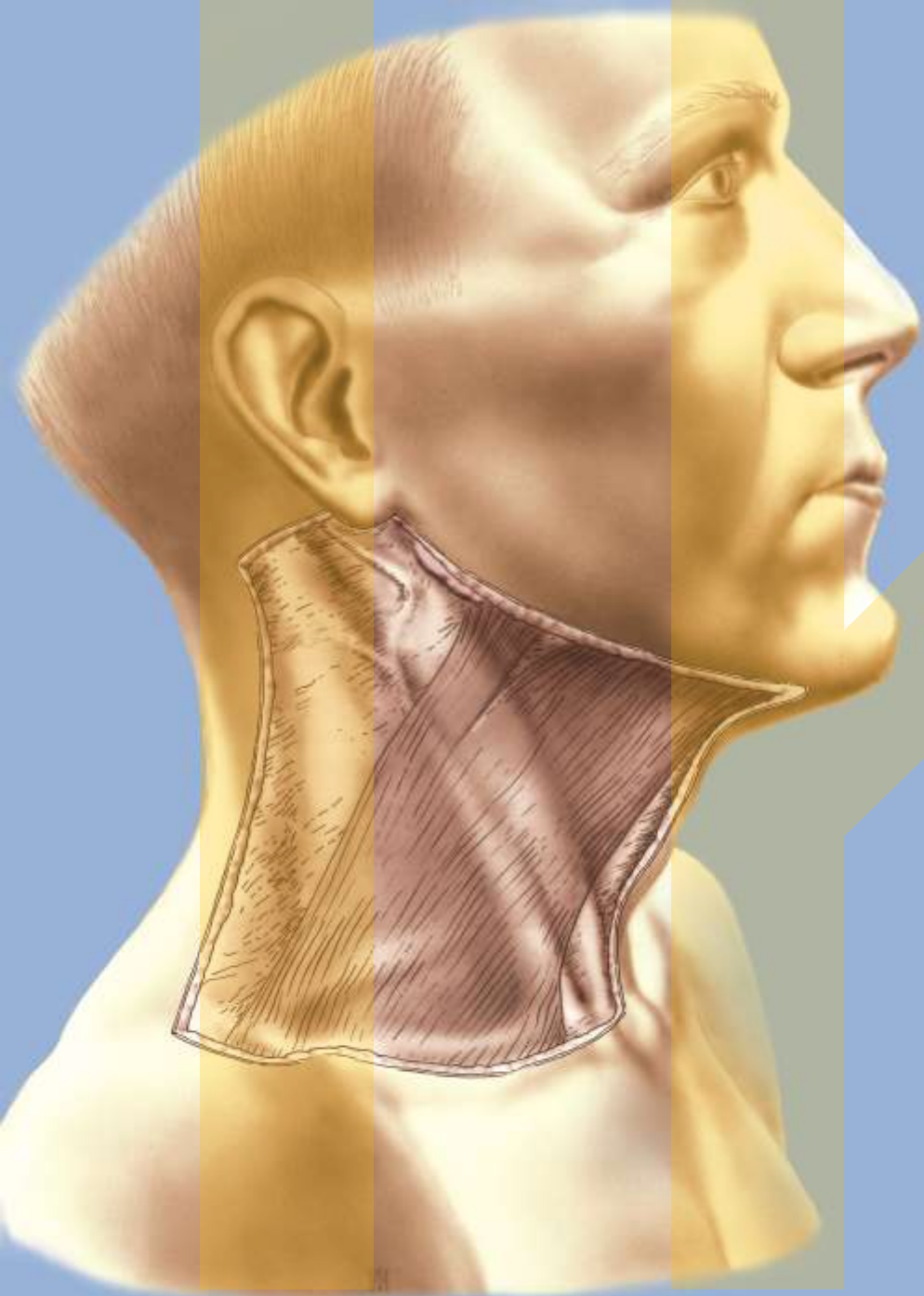
Regiones capitis et colli

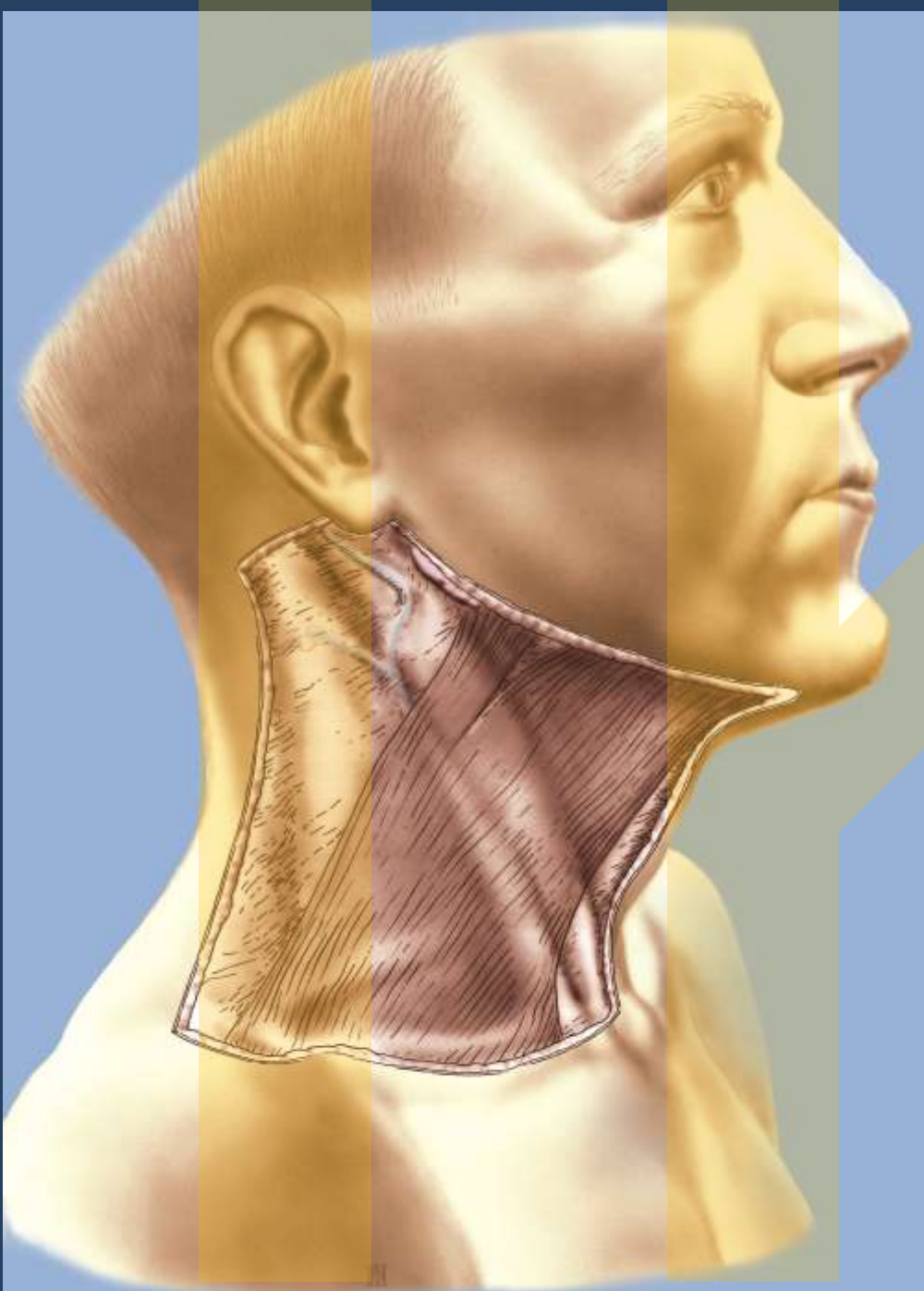


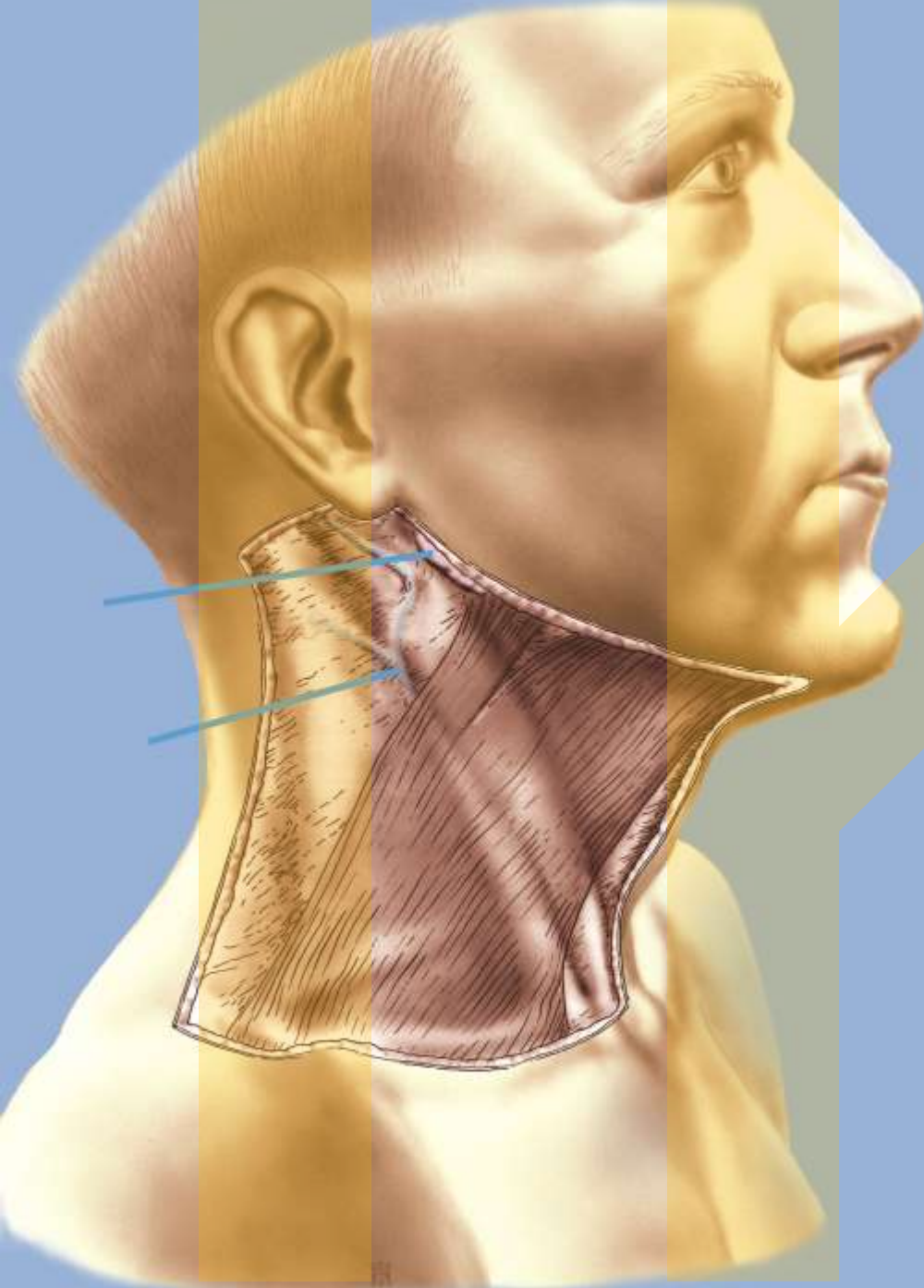
Regio colli anterior et lateralis

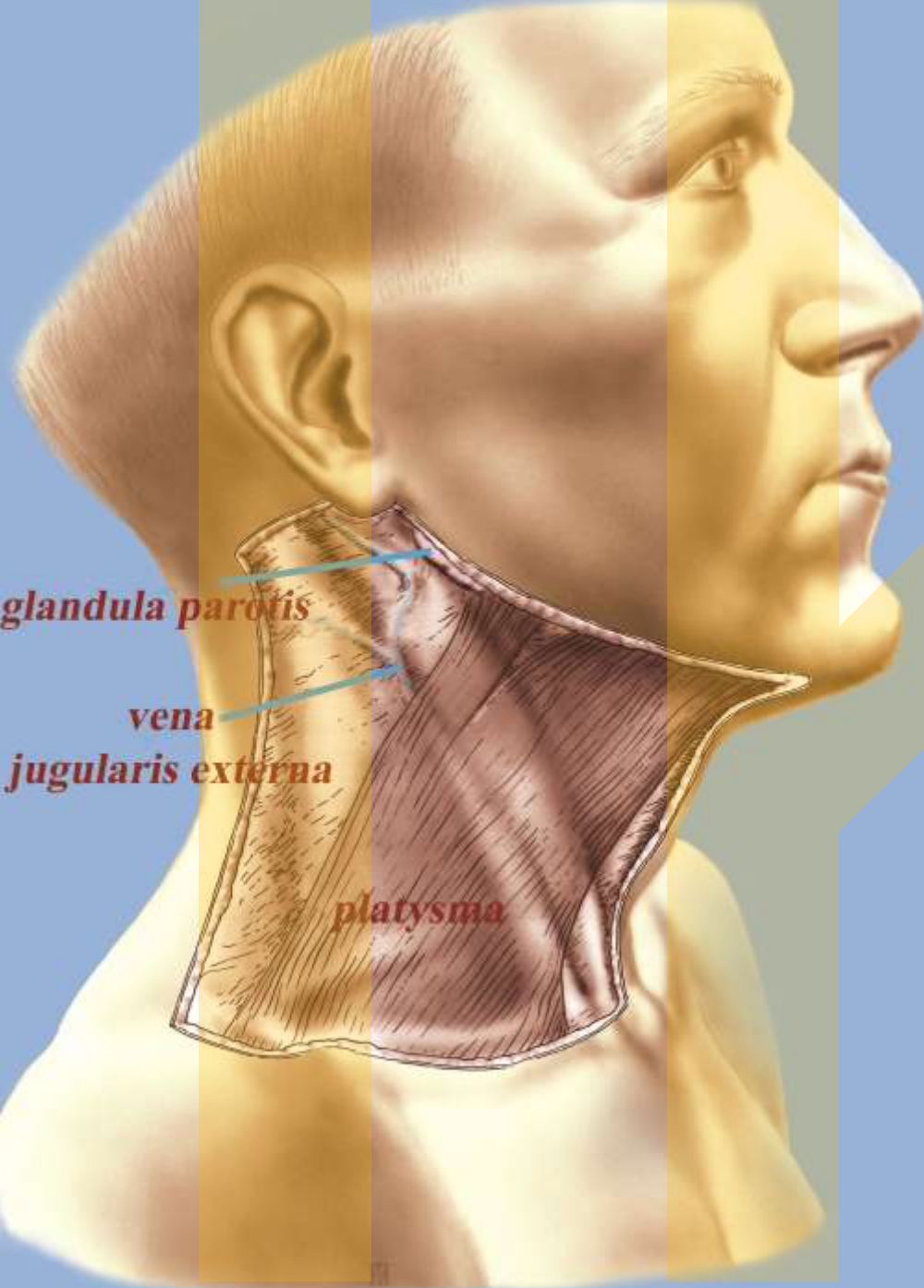


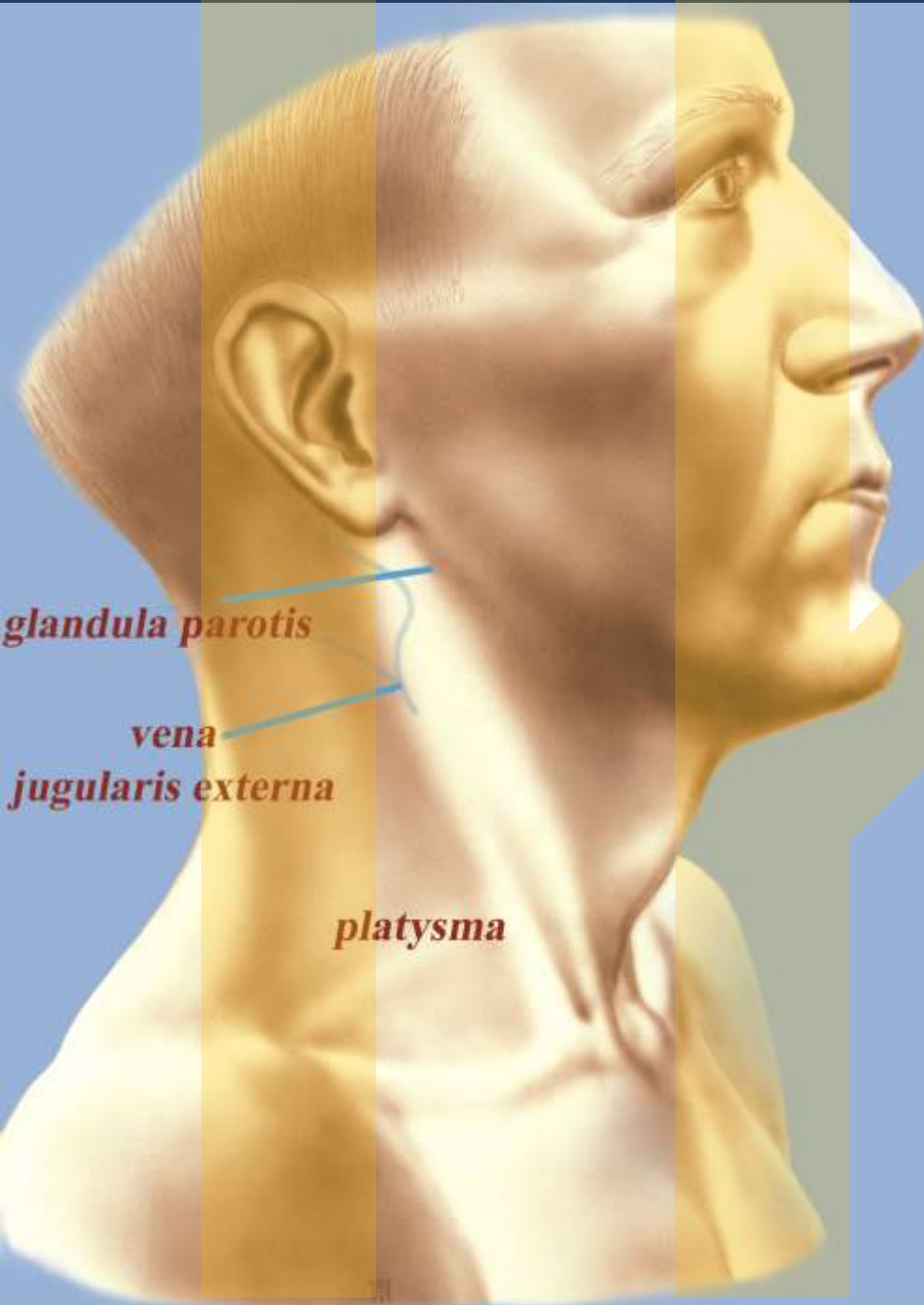








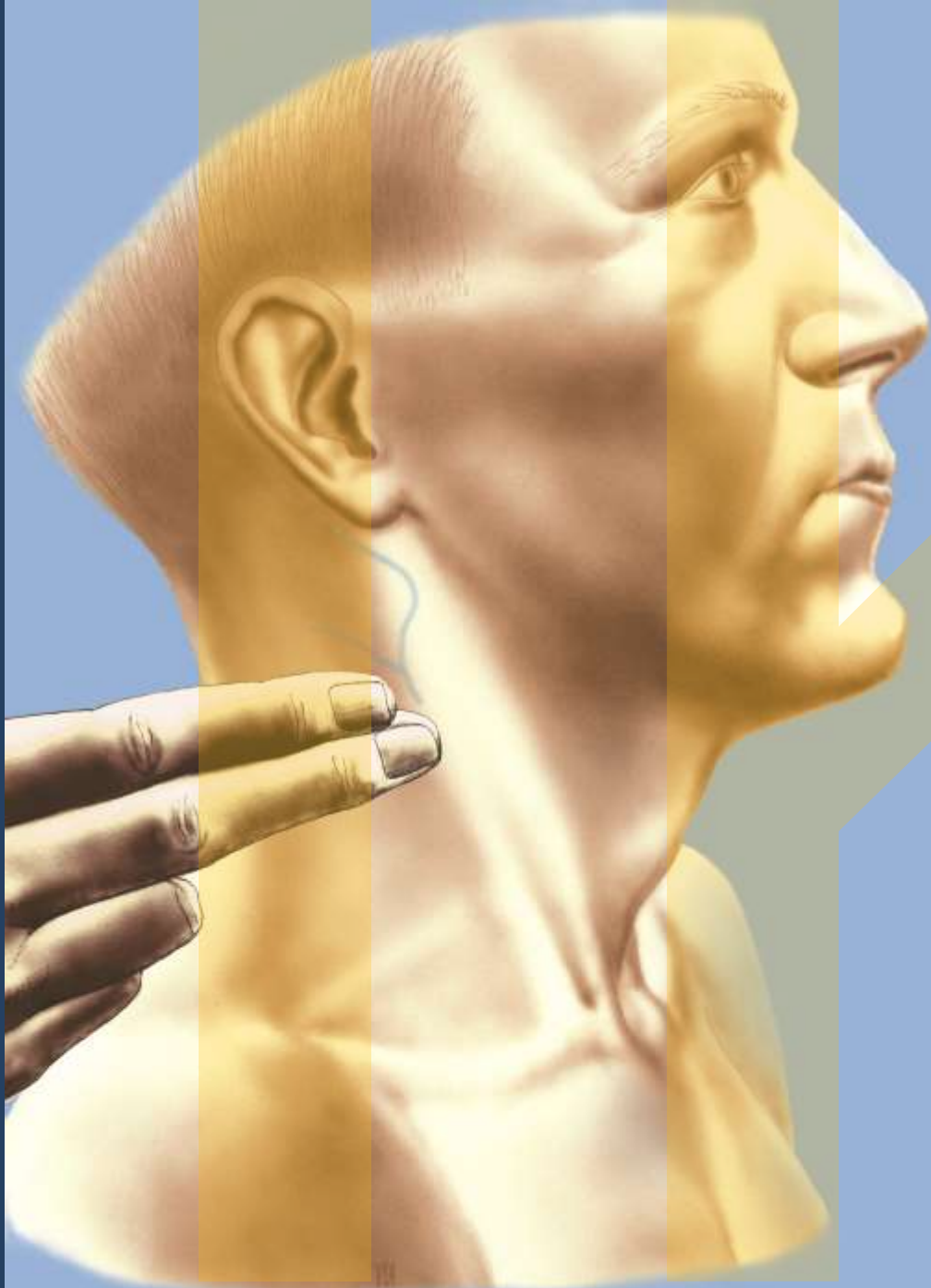


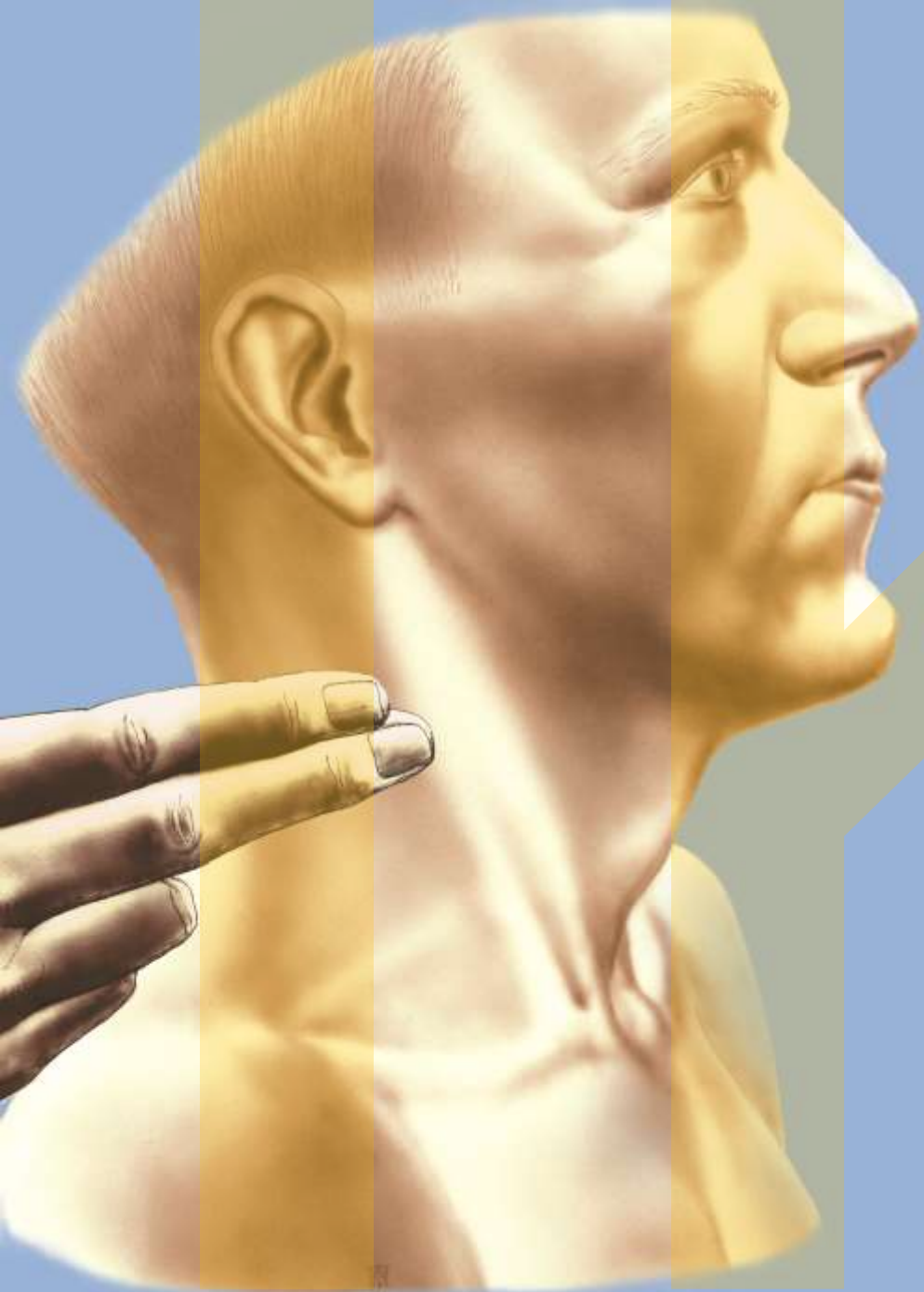

glandula parotis

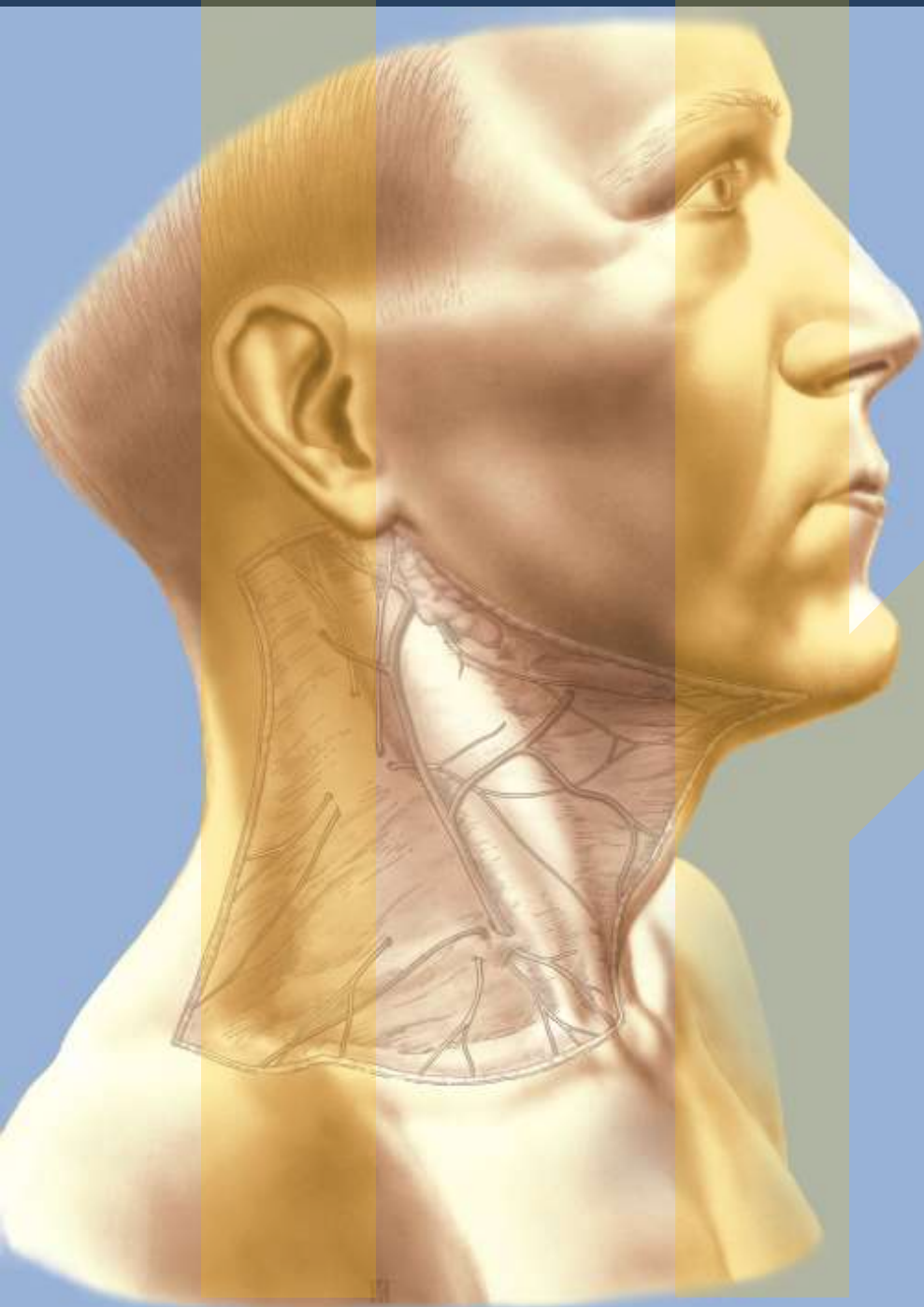
*vena
jugularis externa*

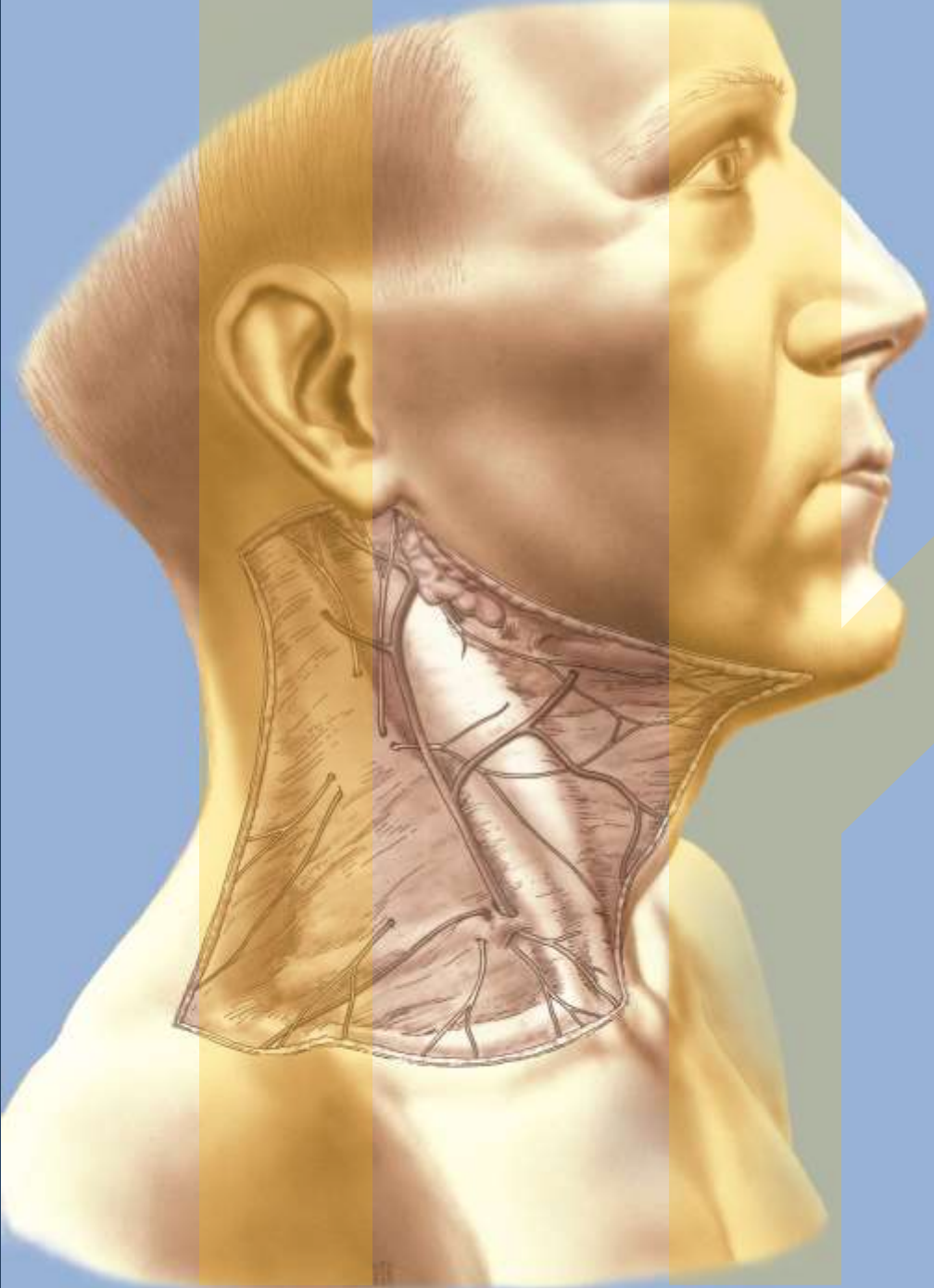
platysma

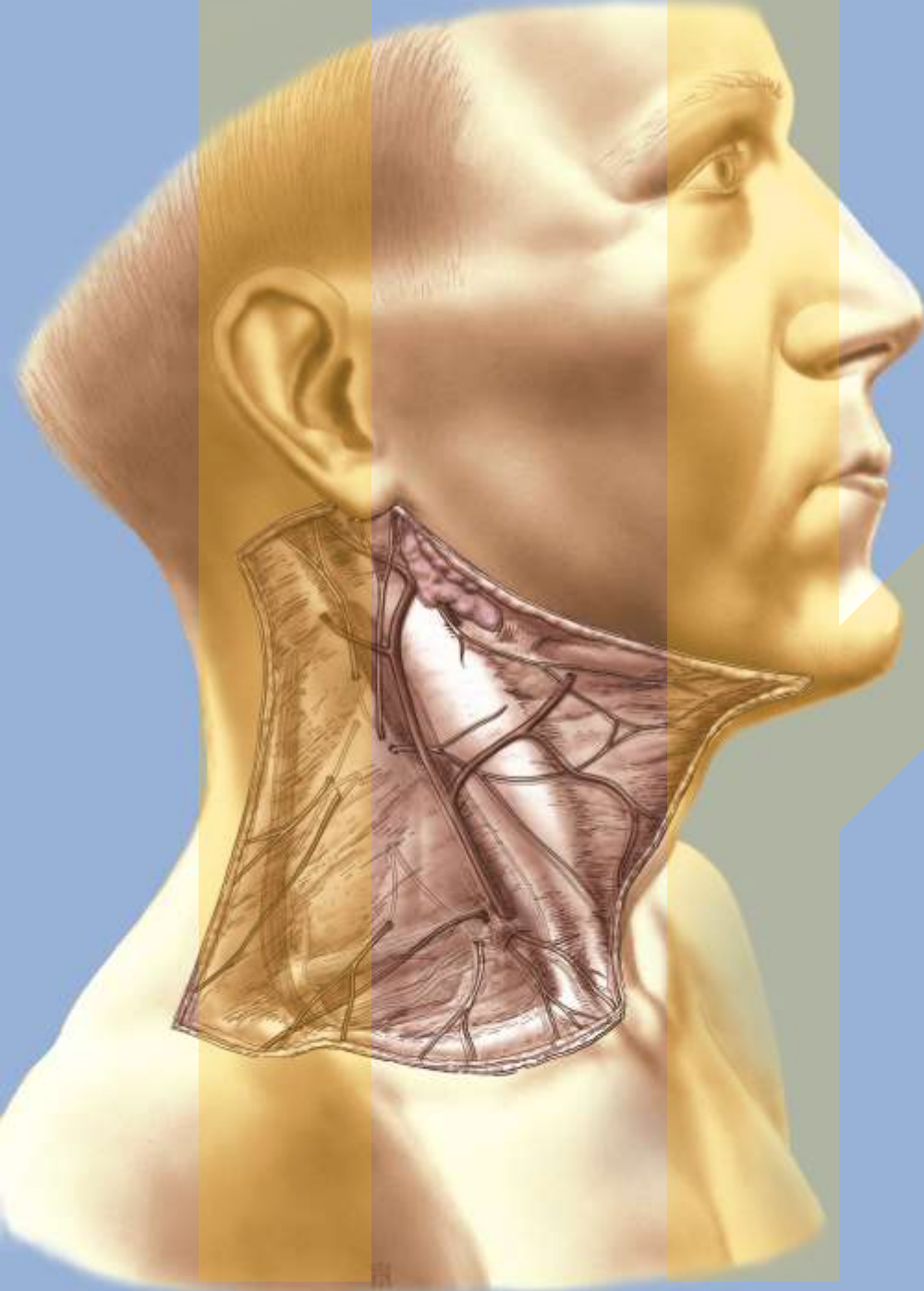


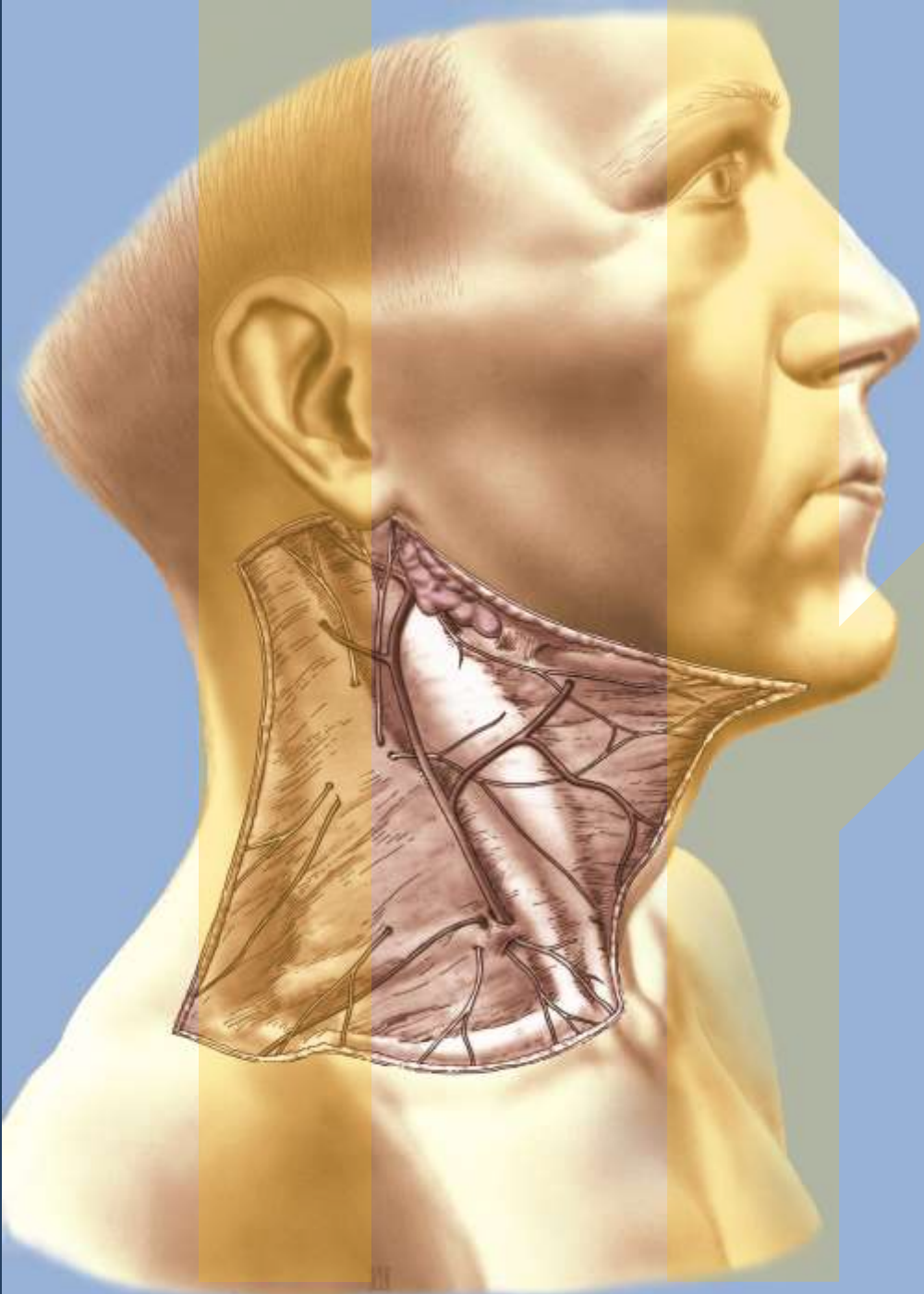


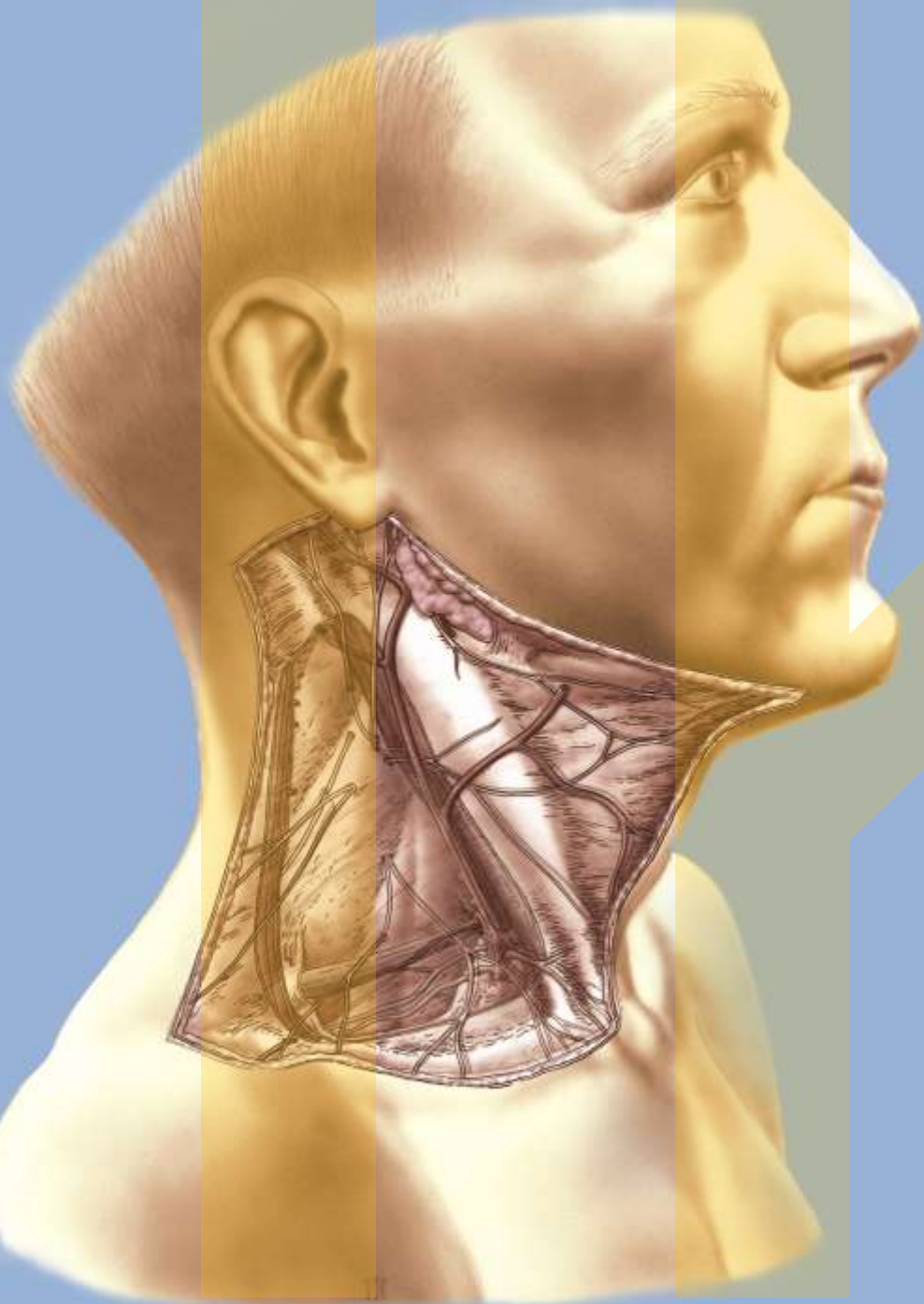


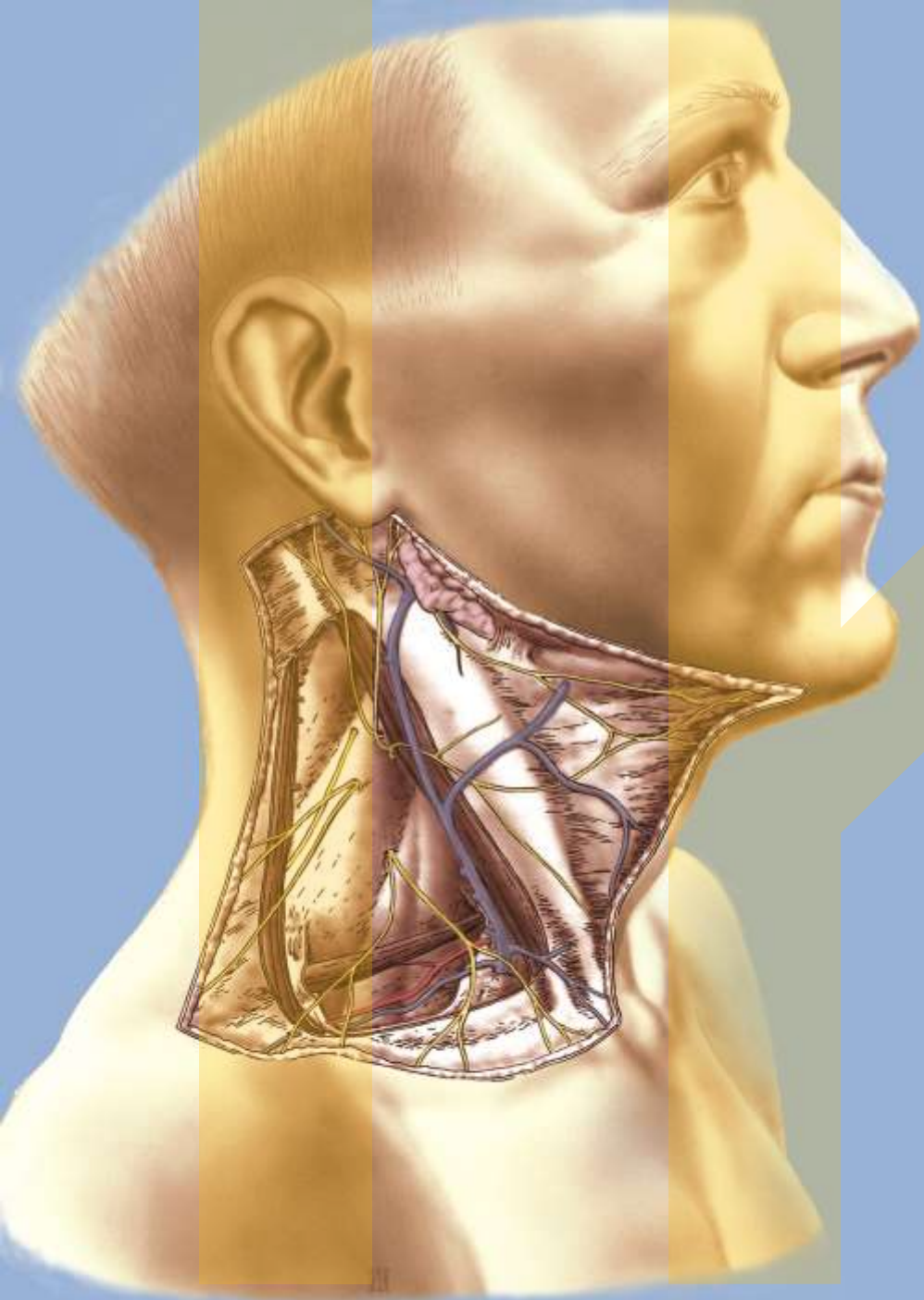


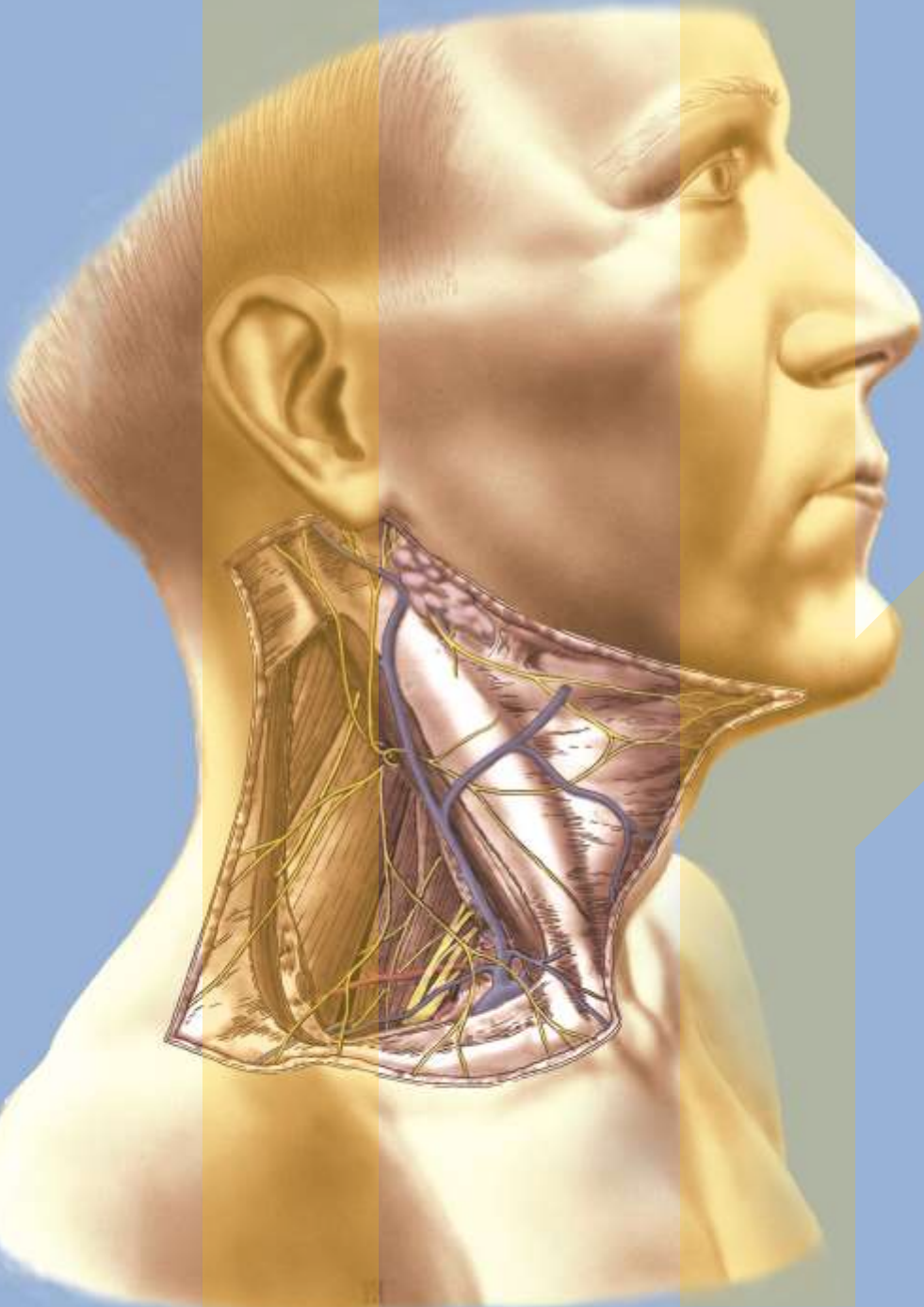


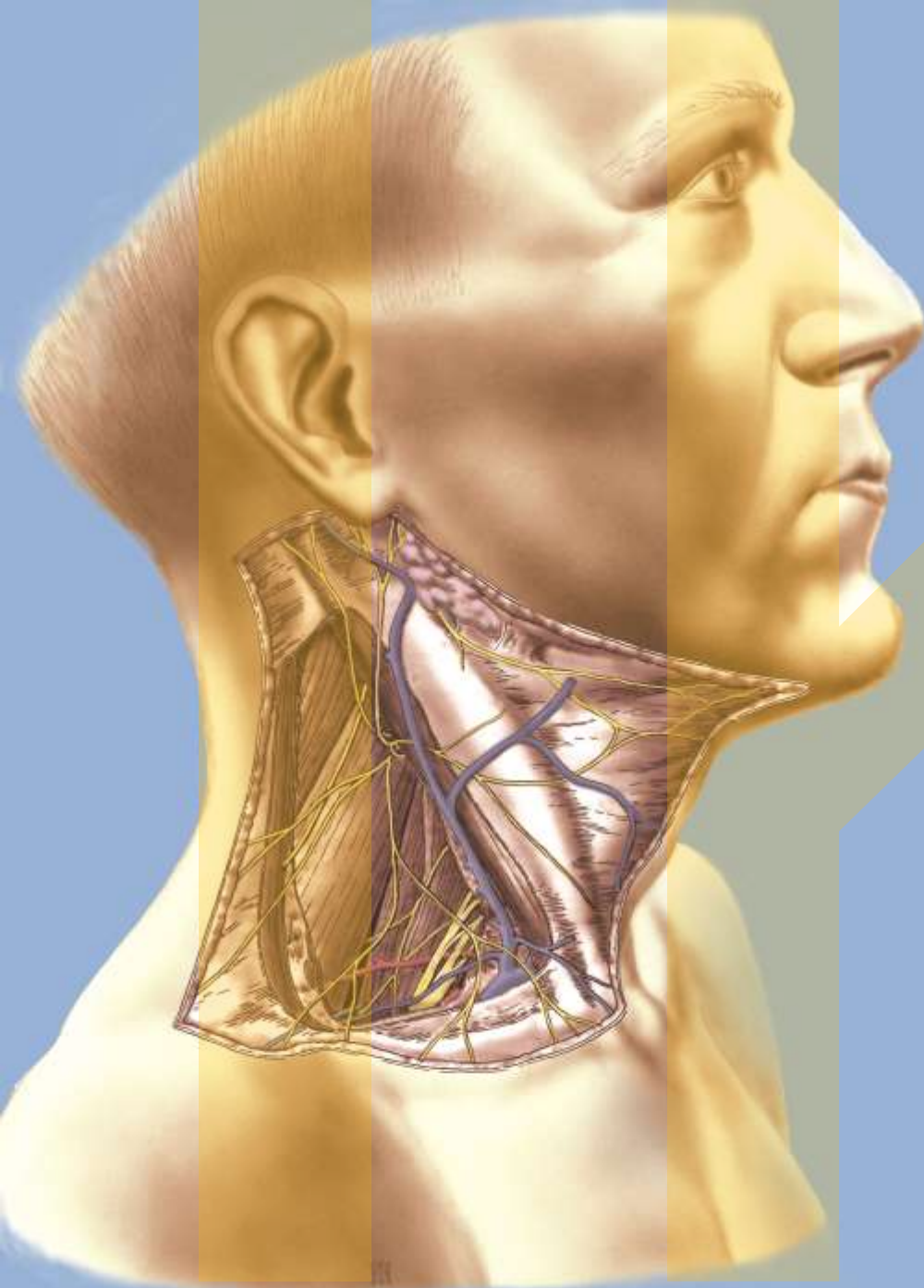


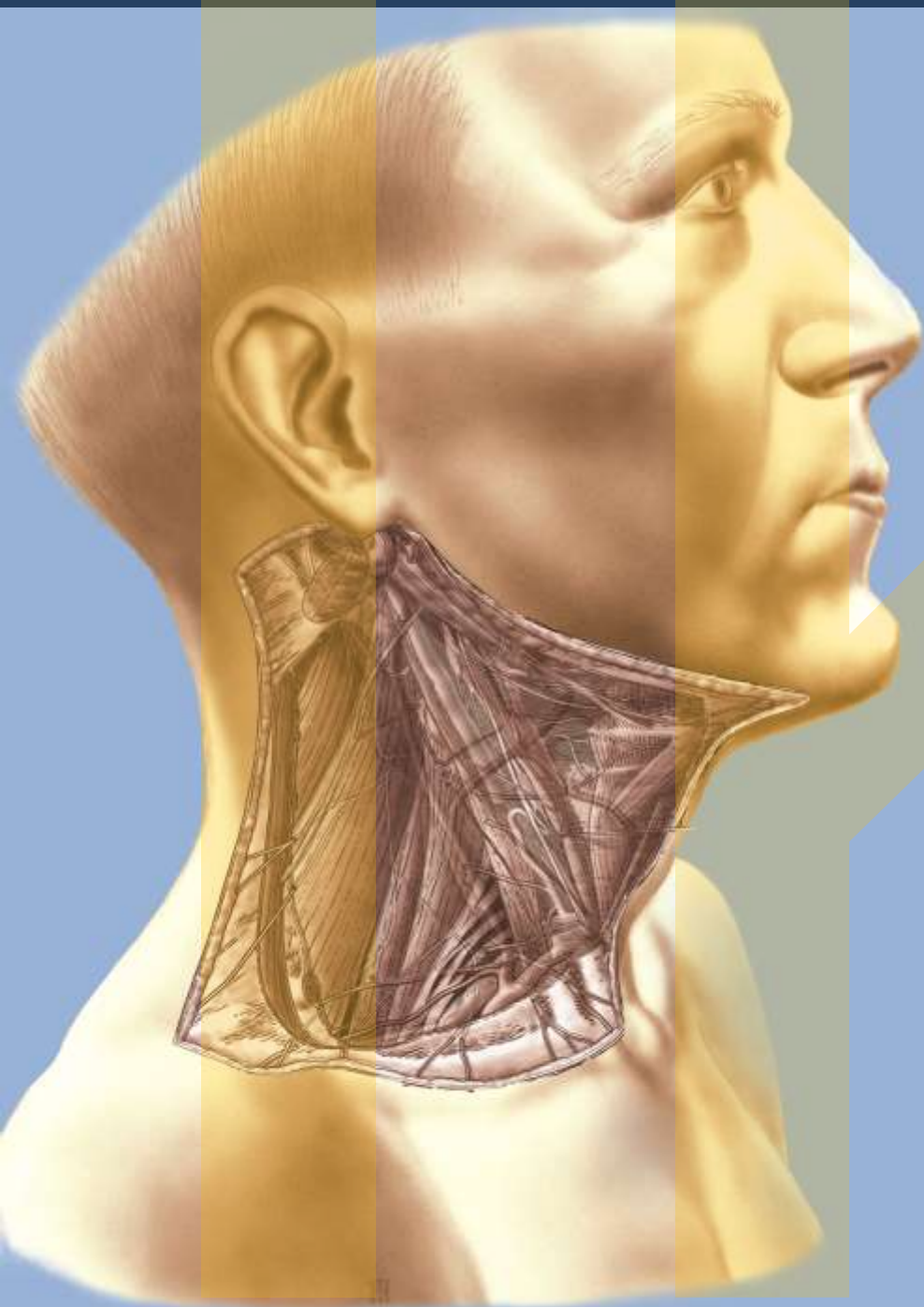


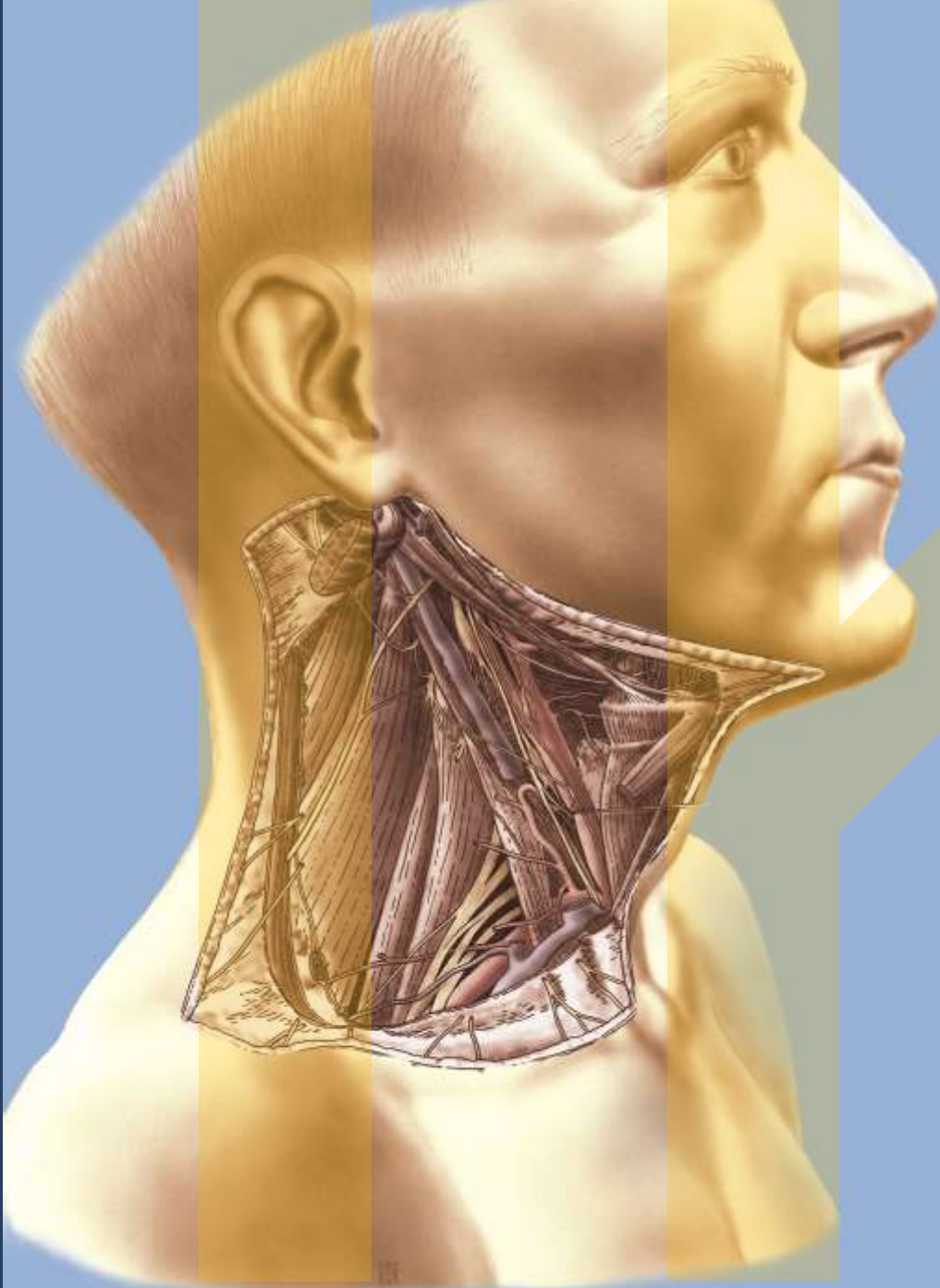


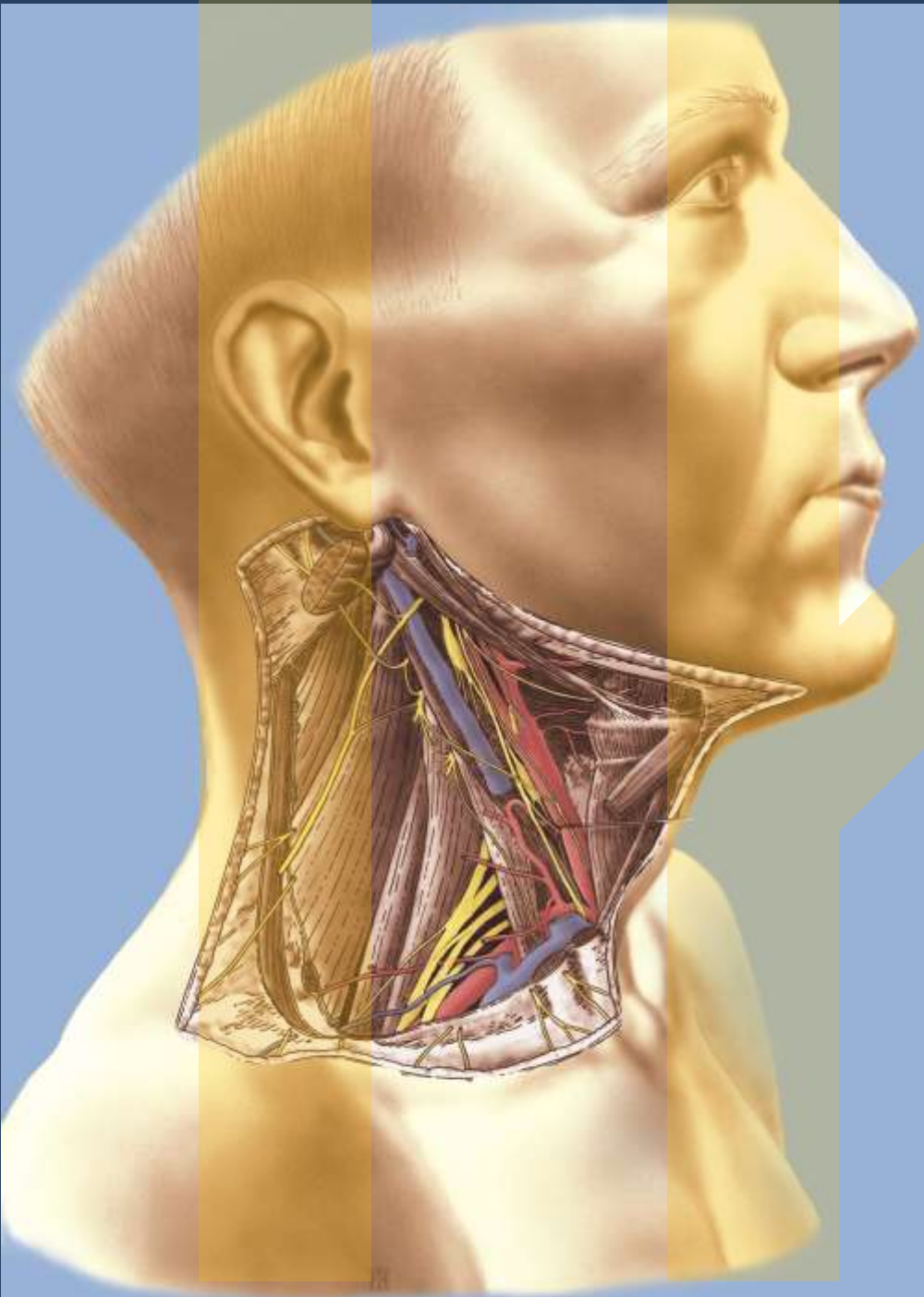


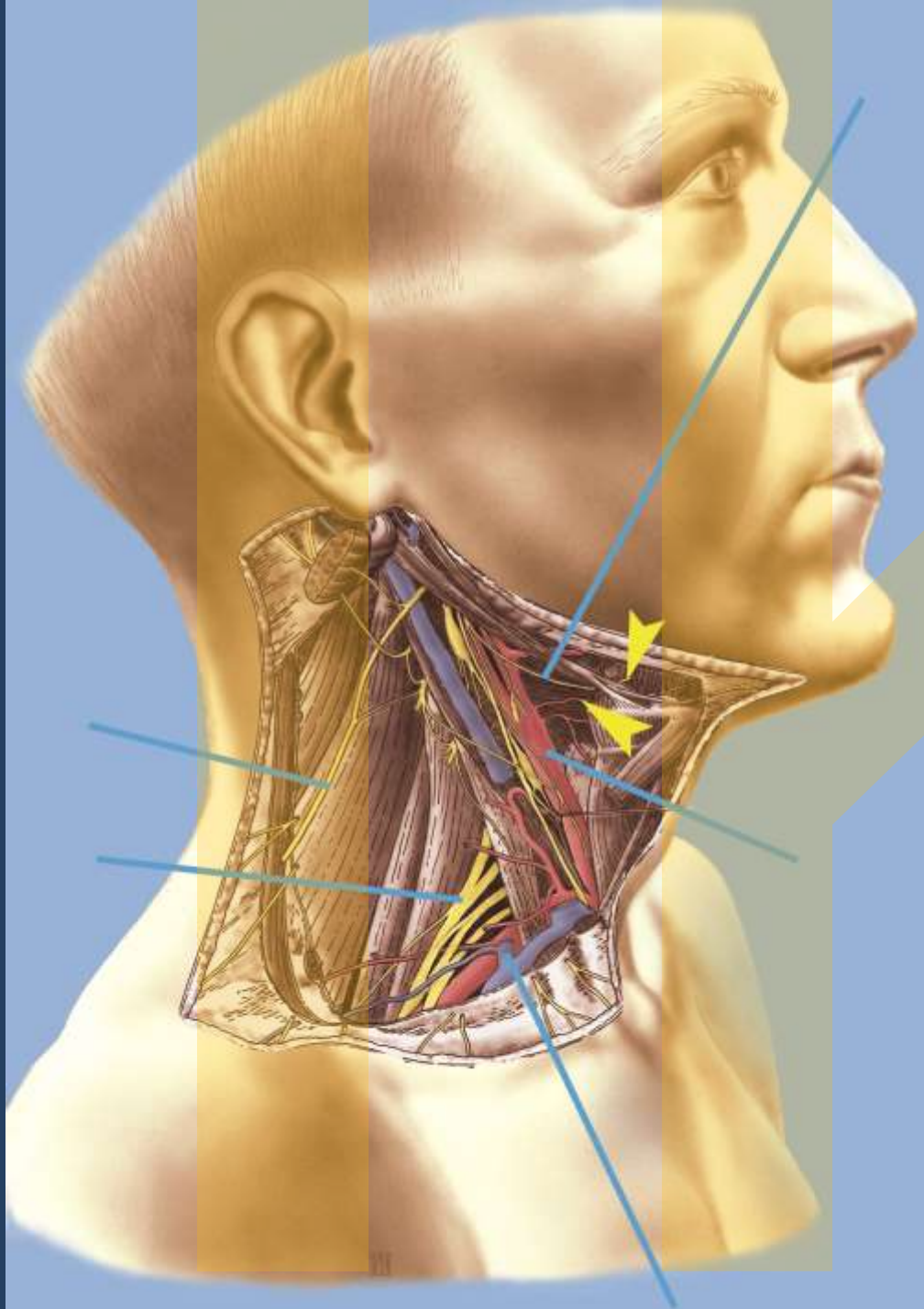


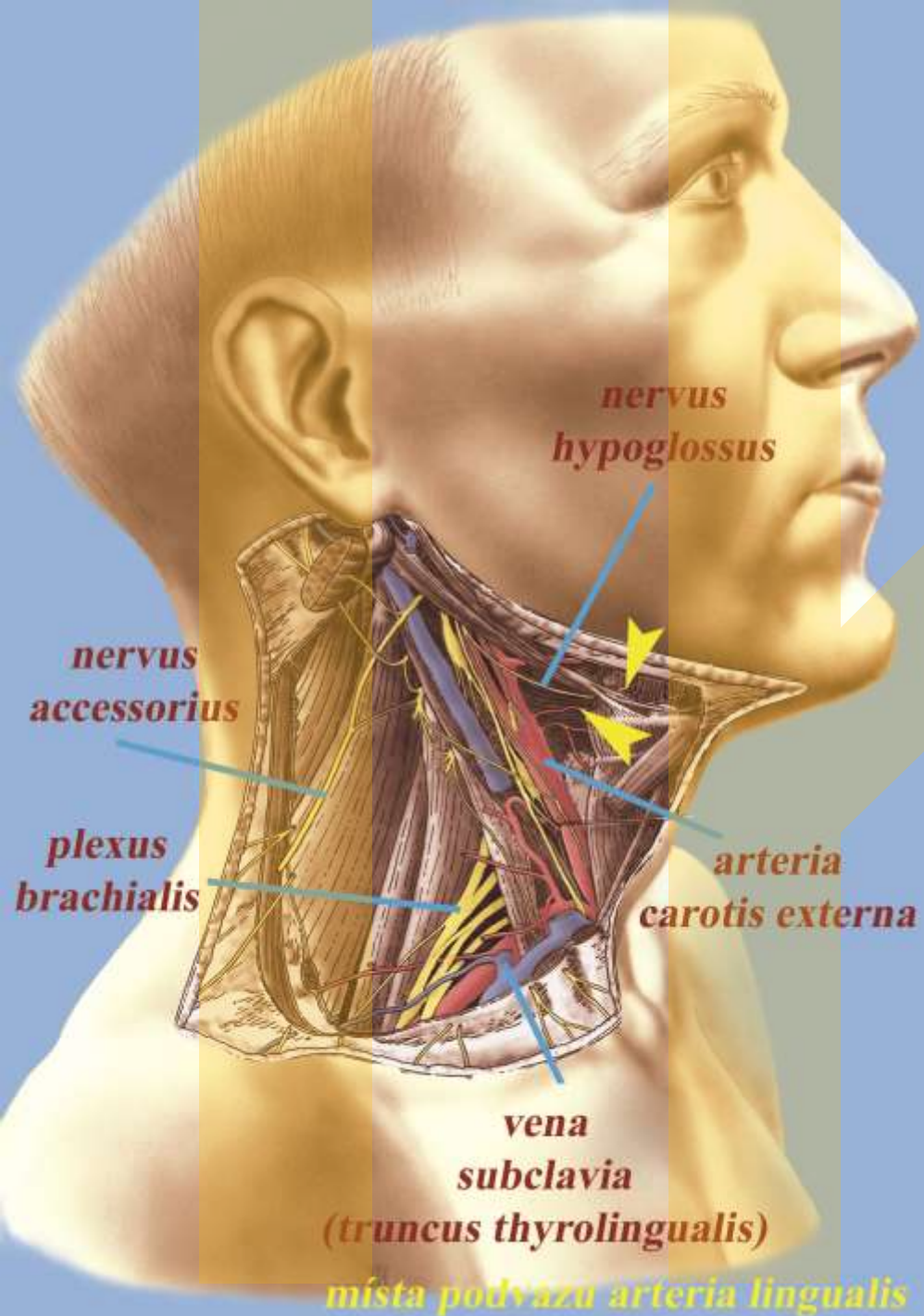


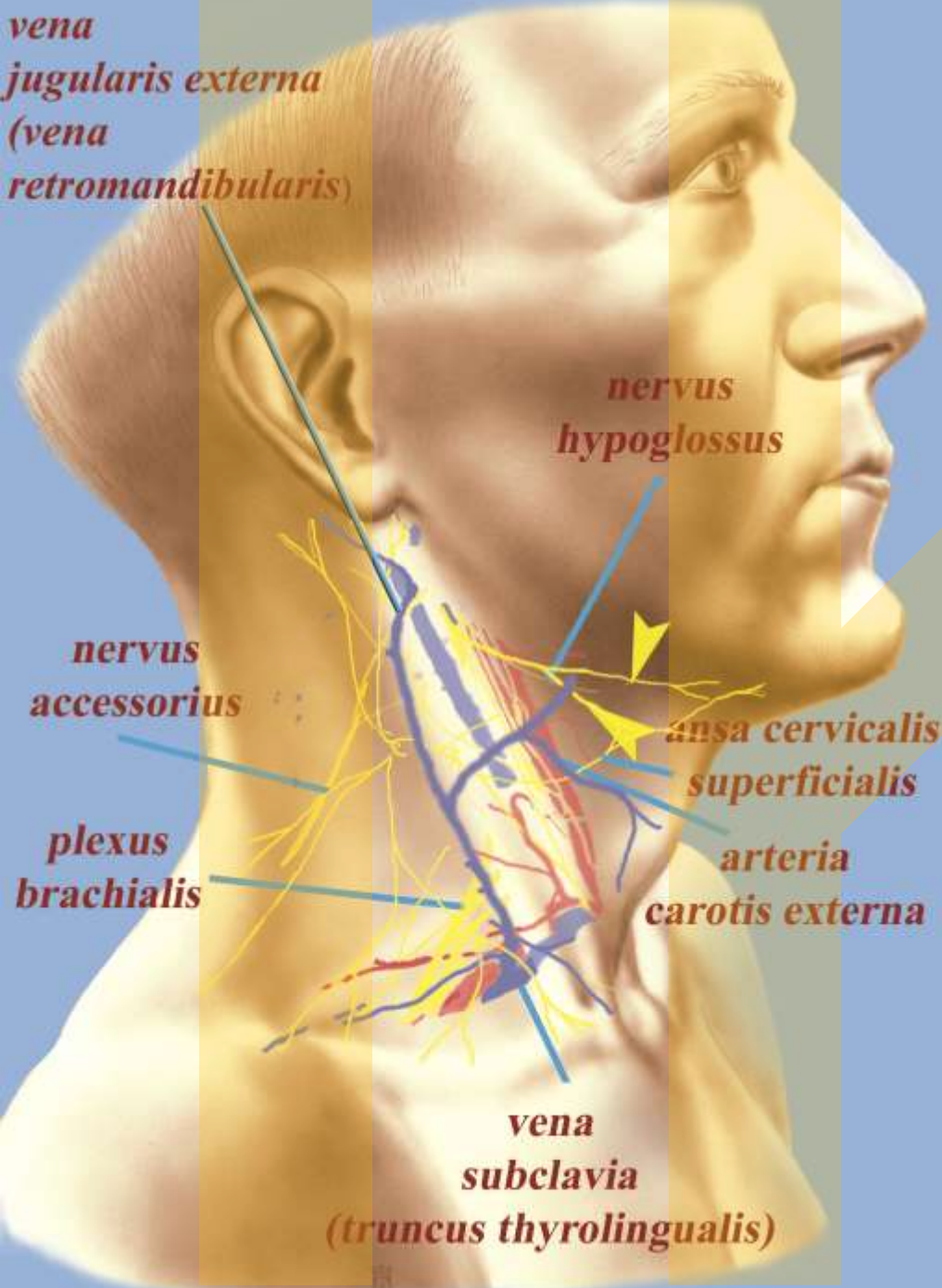


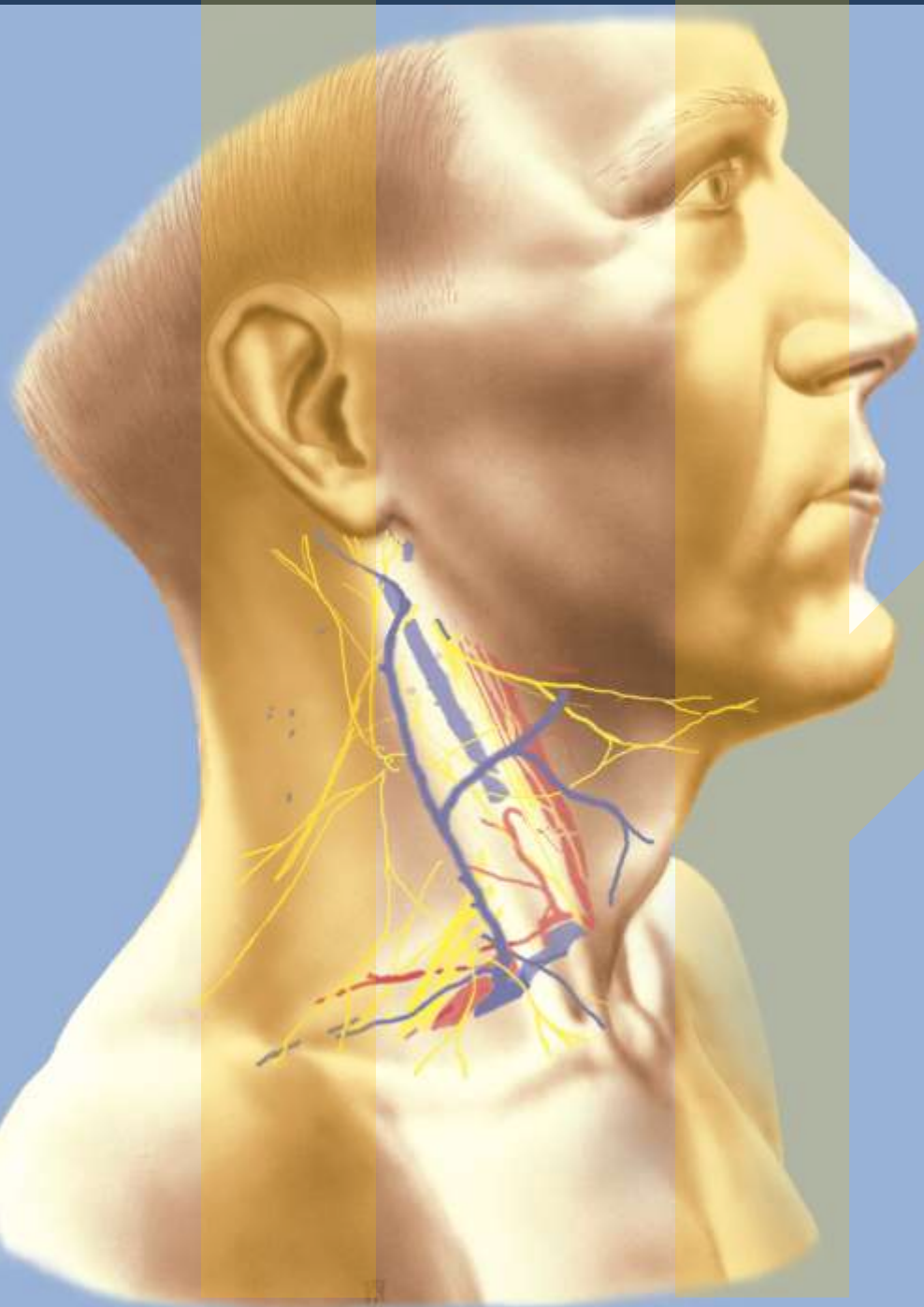


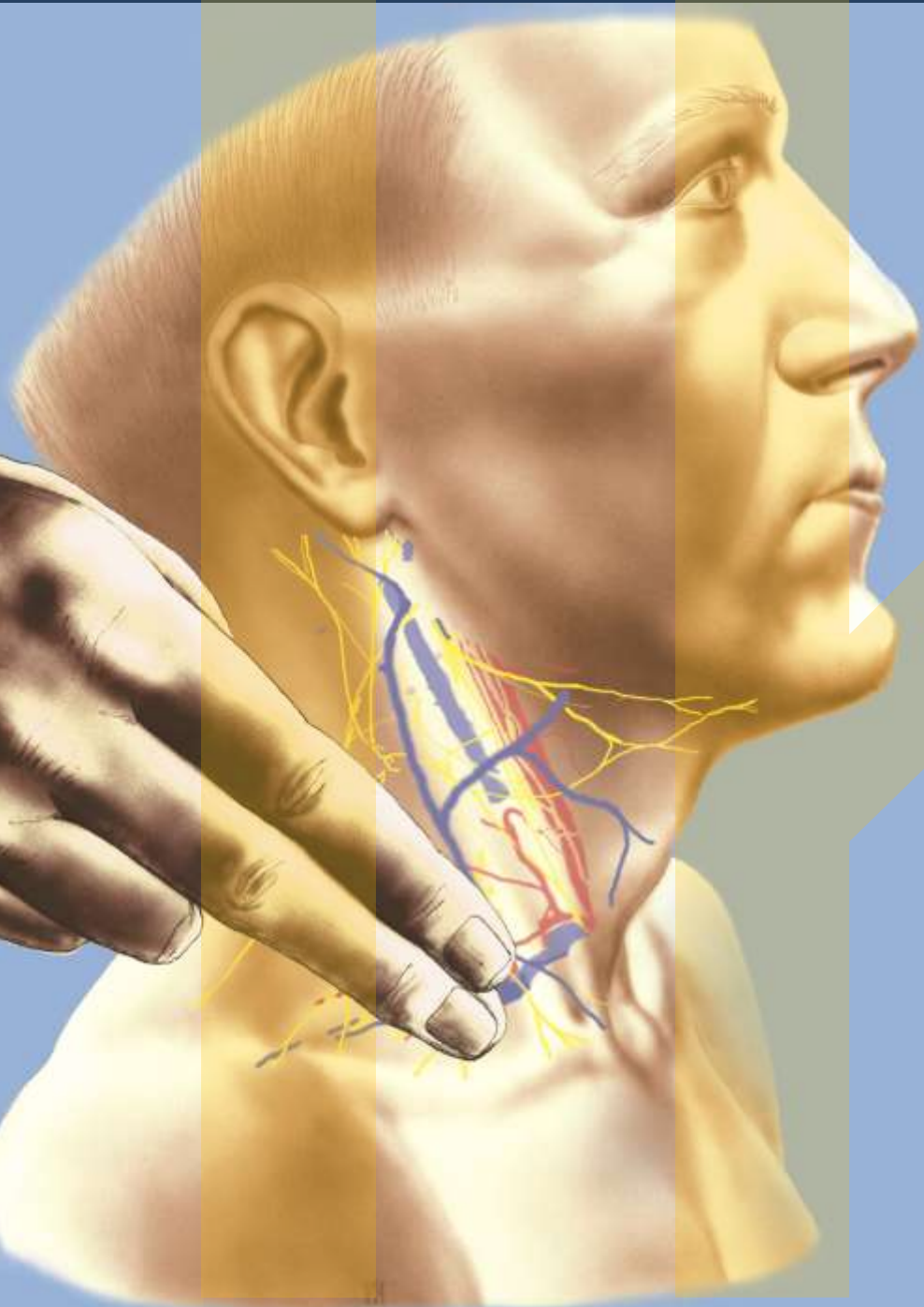


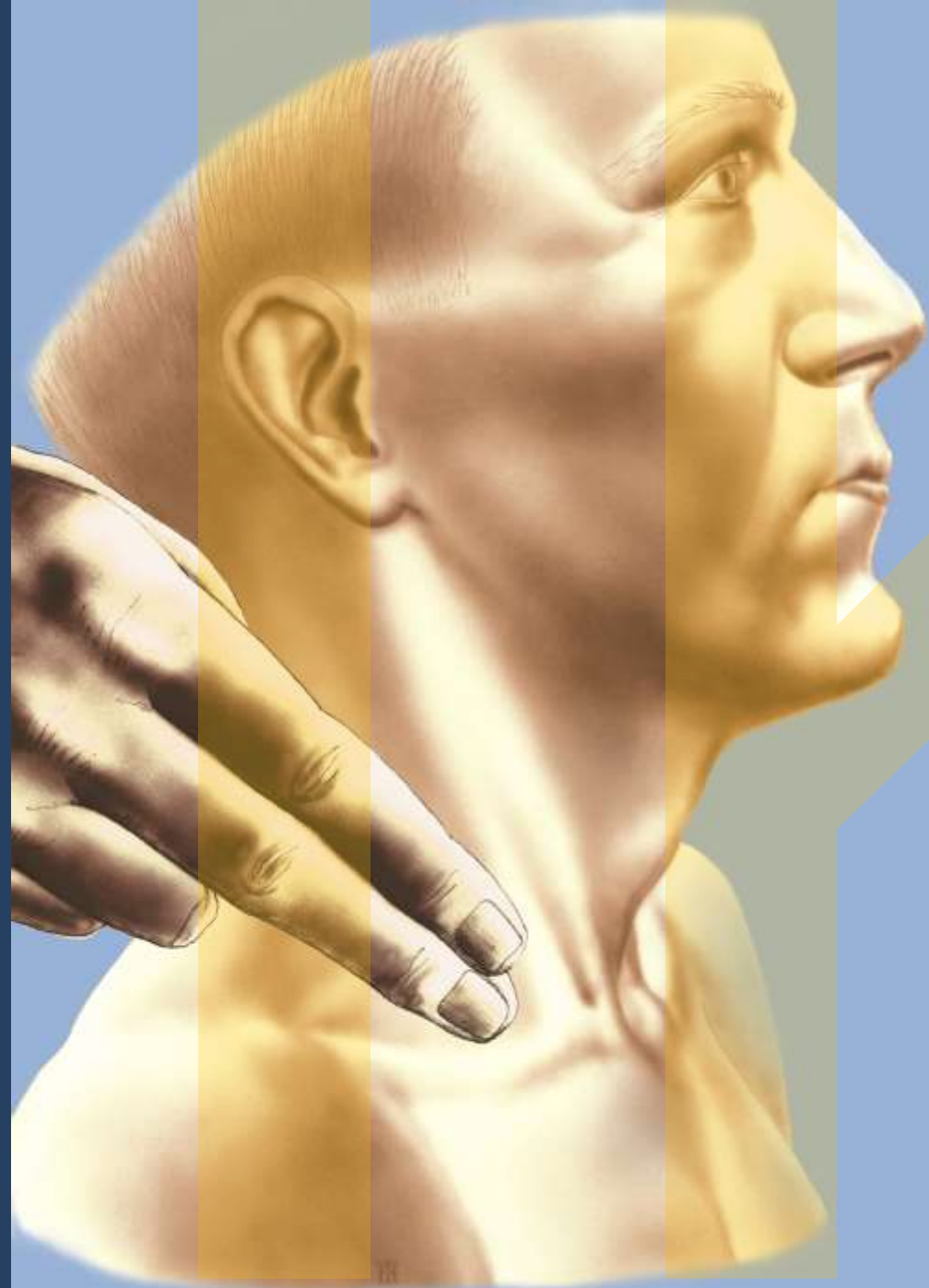

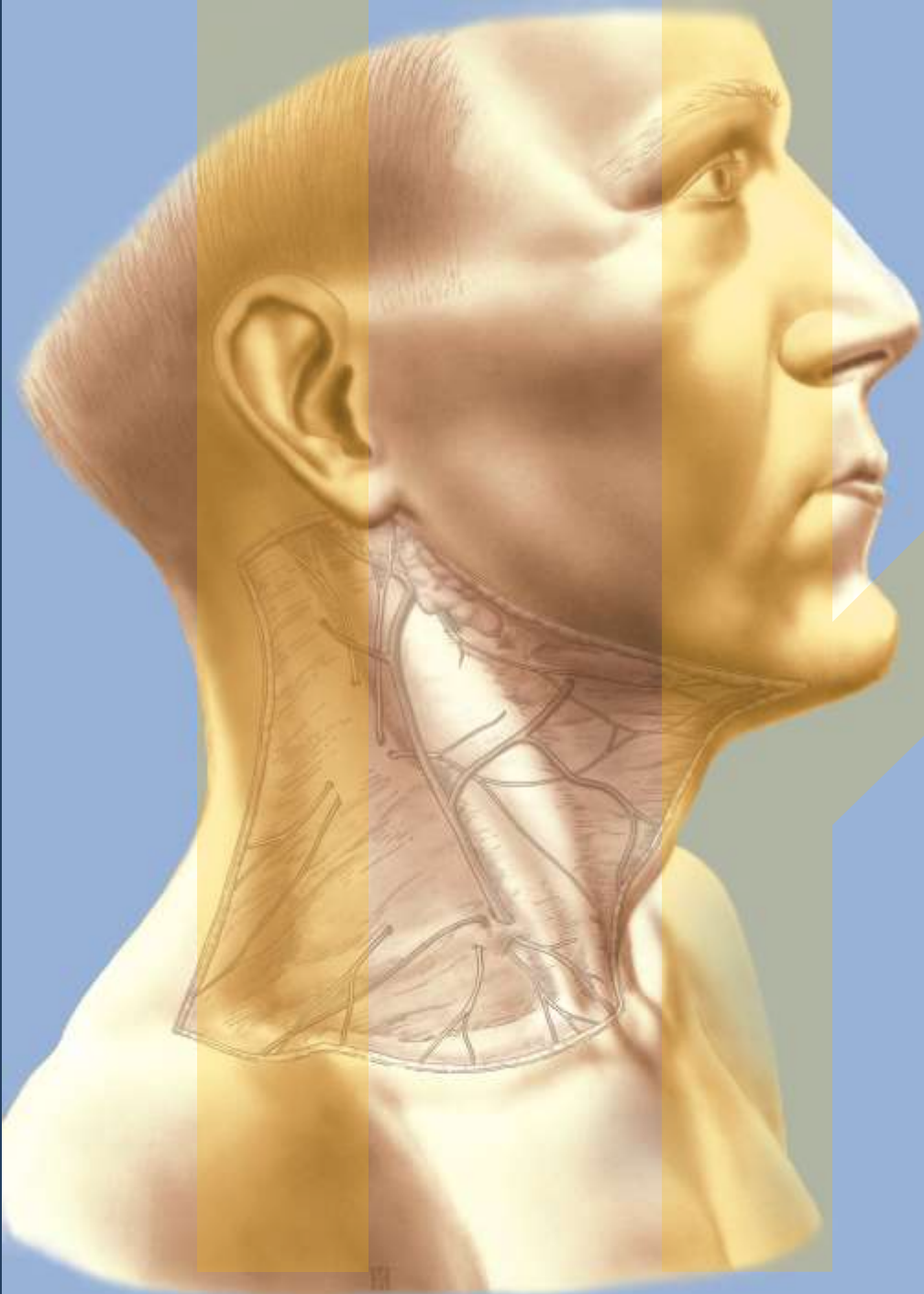


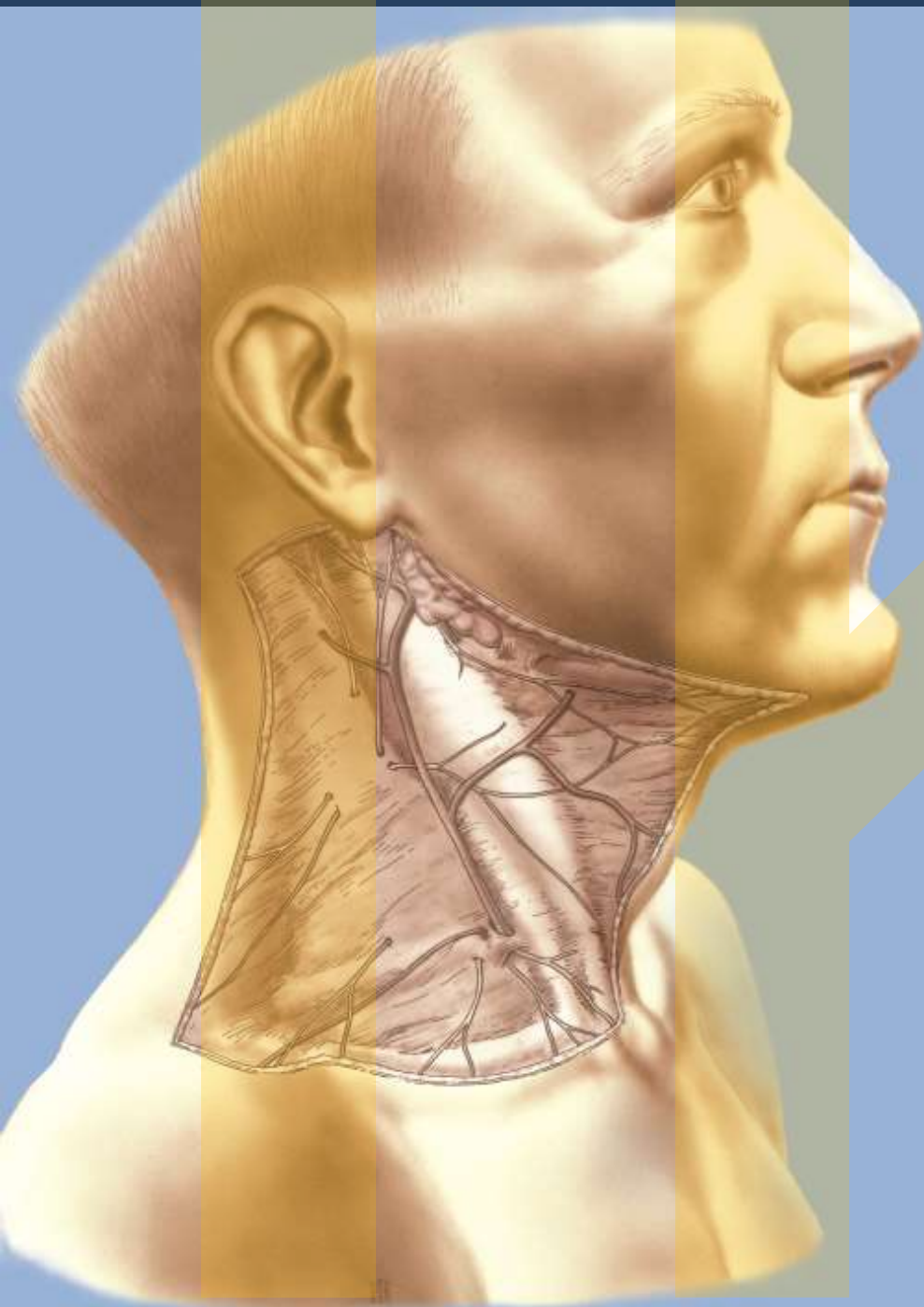




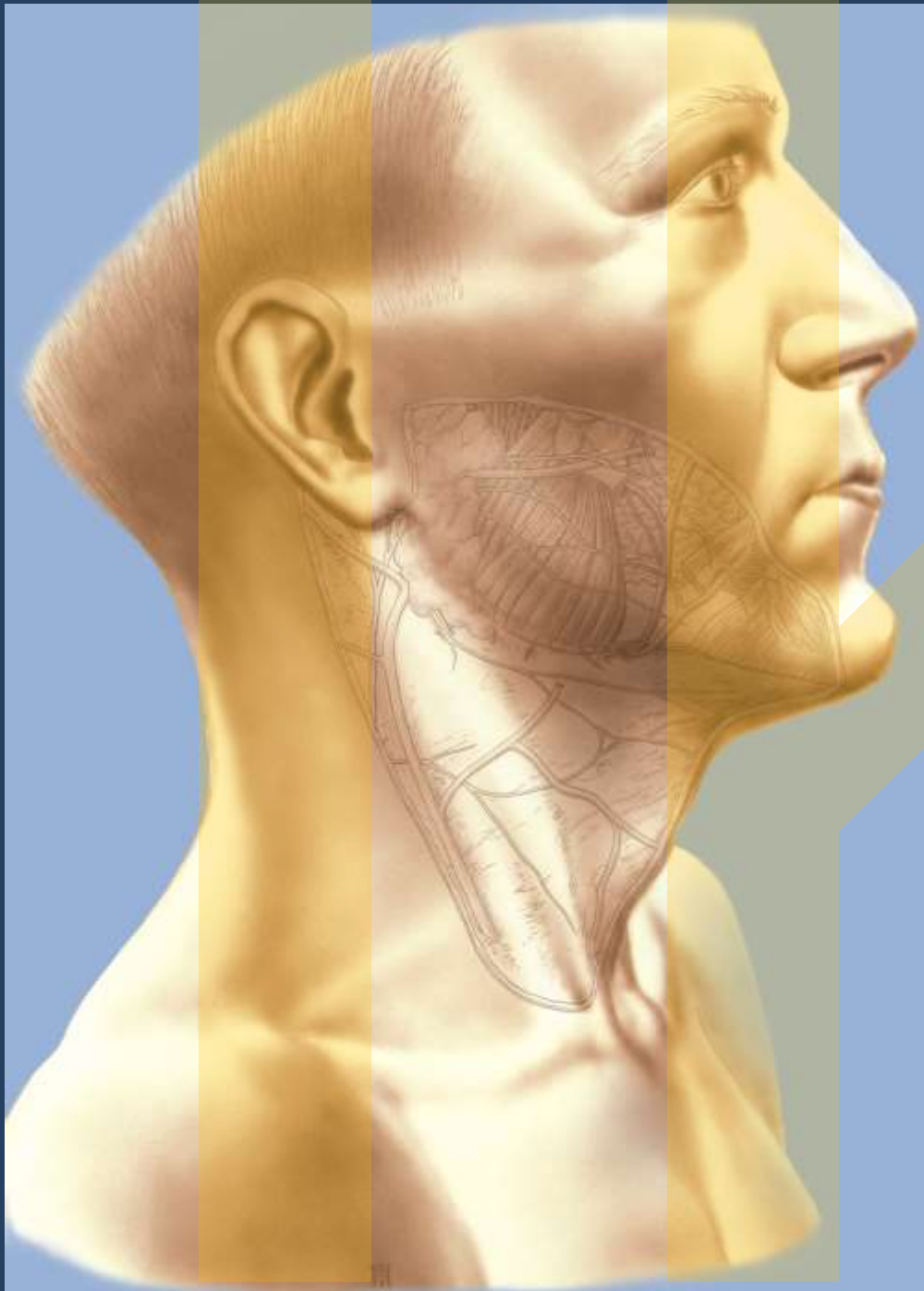


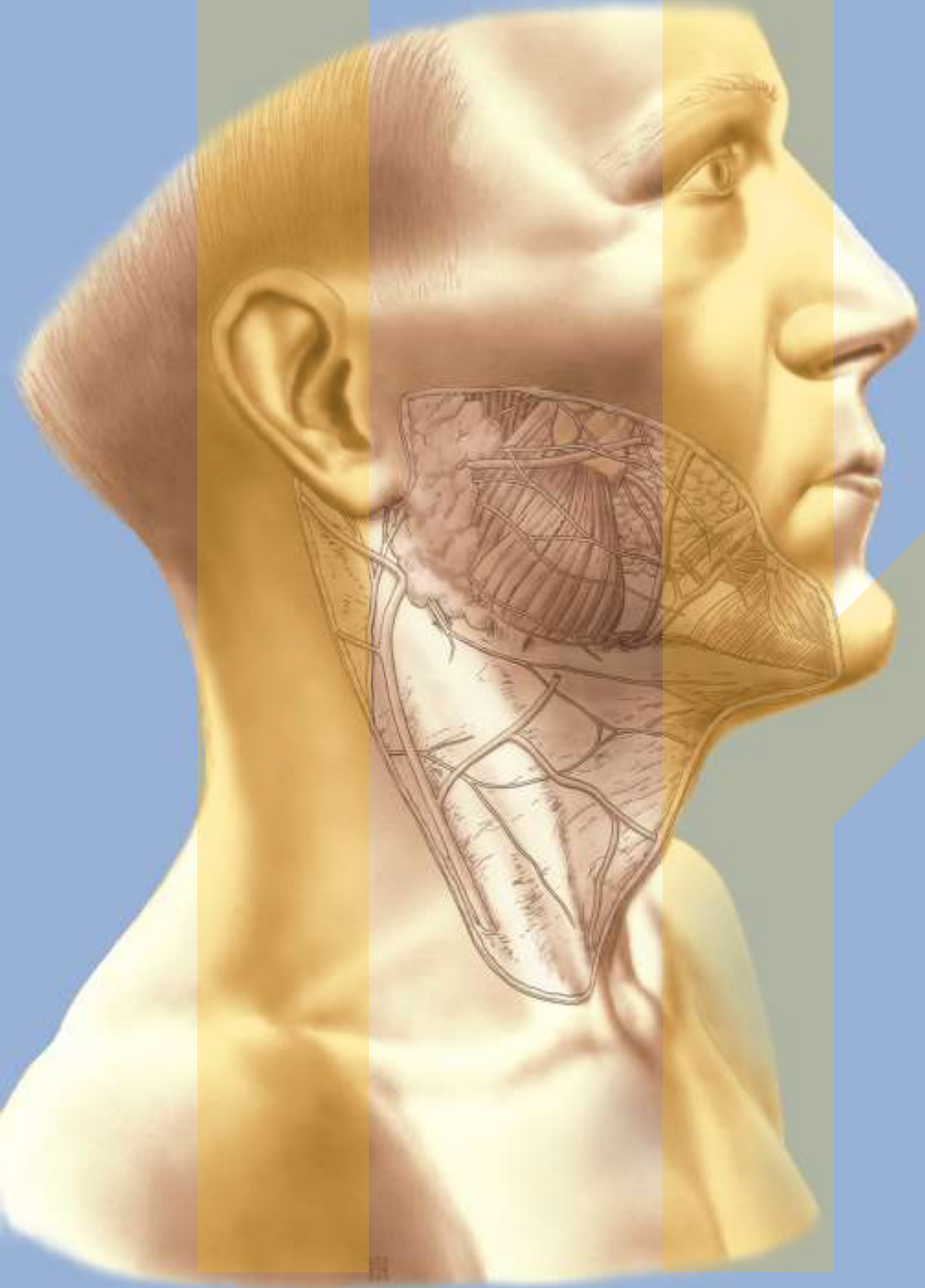


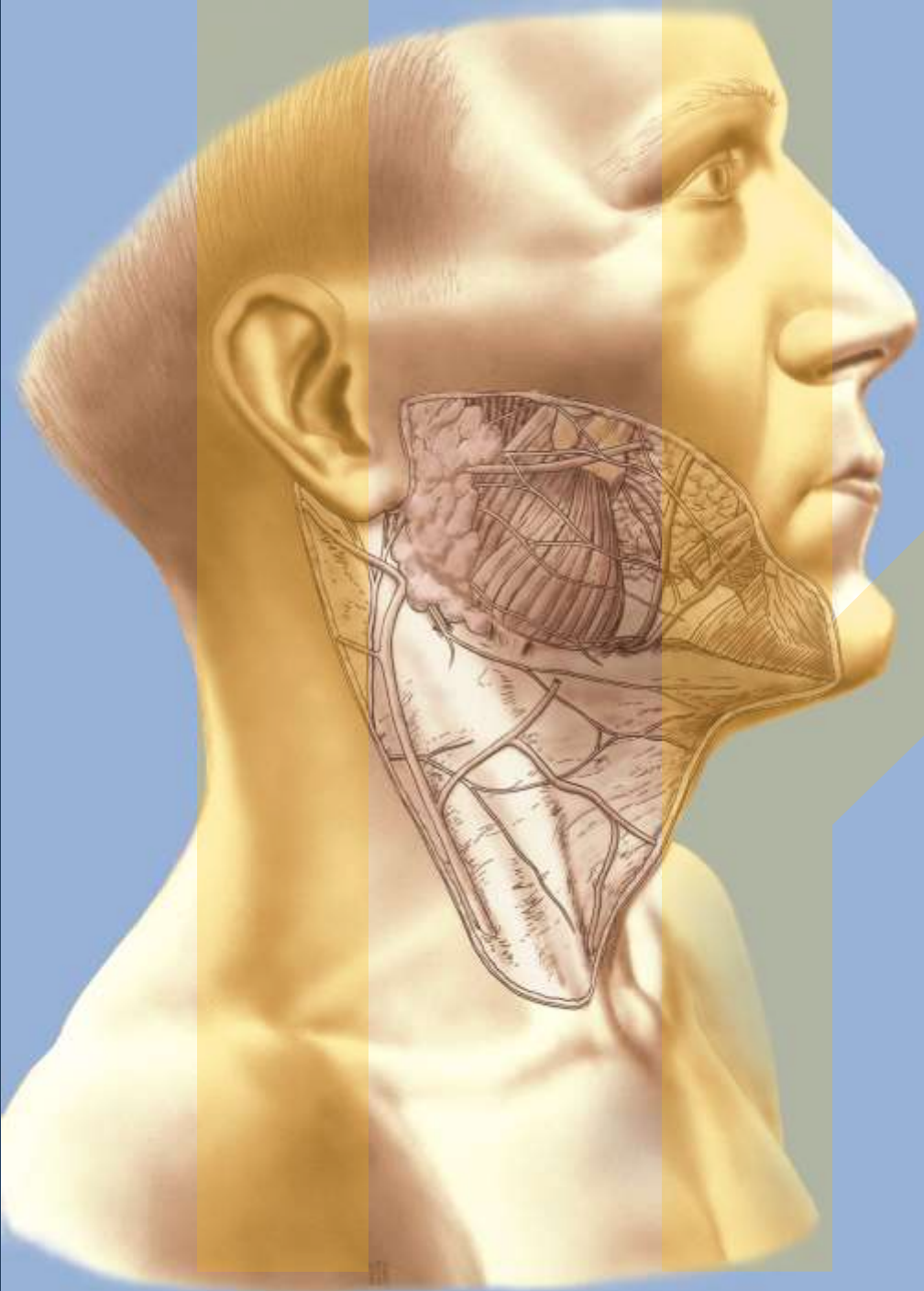


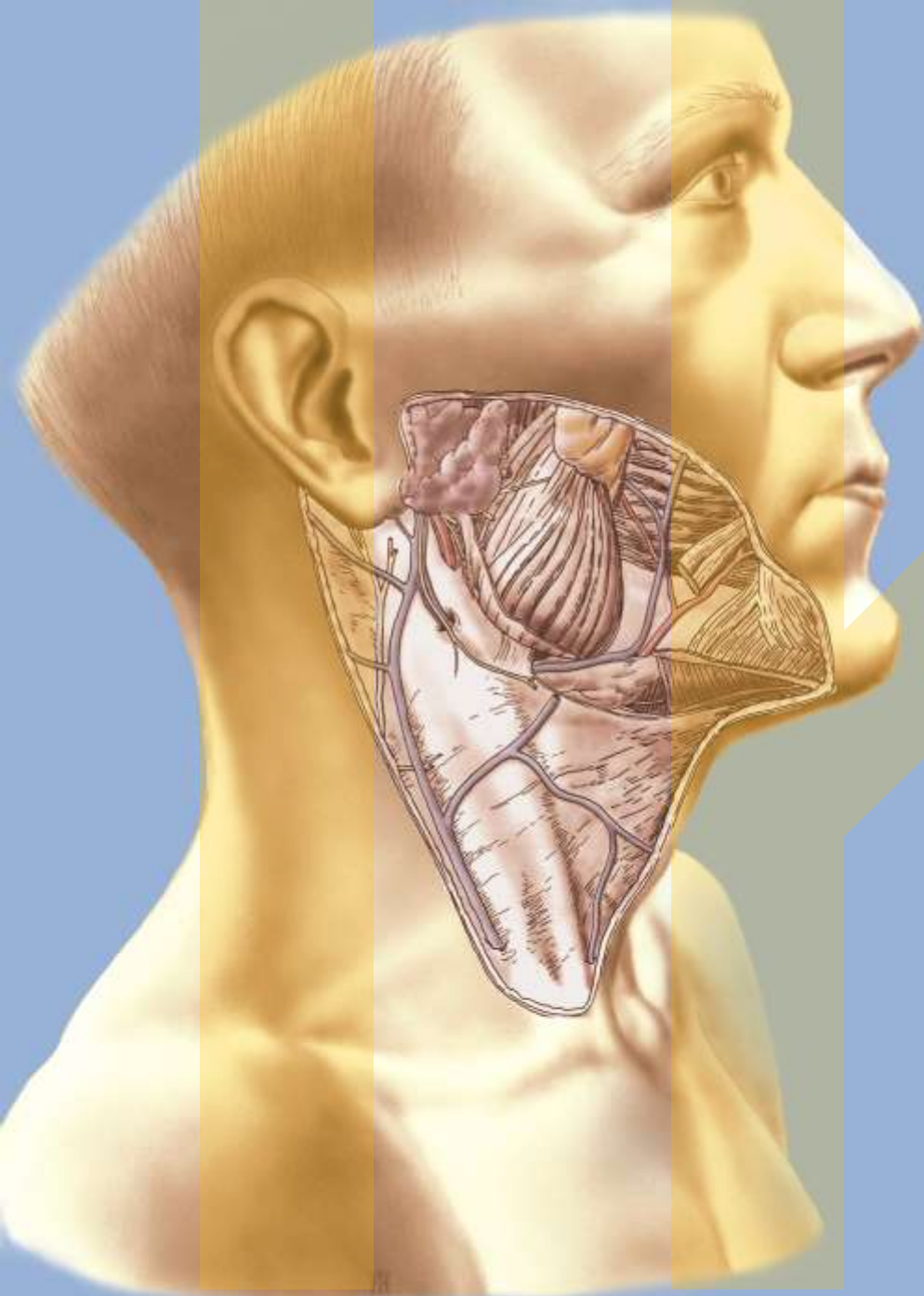


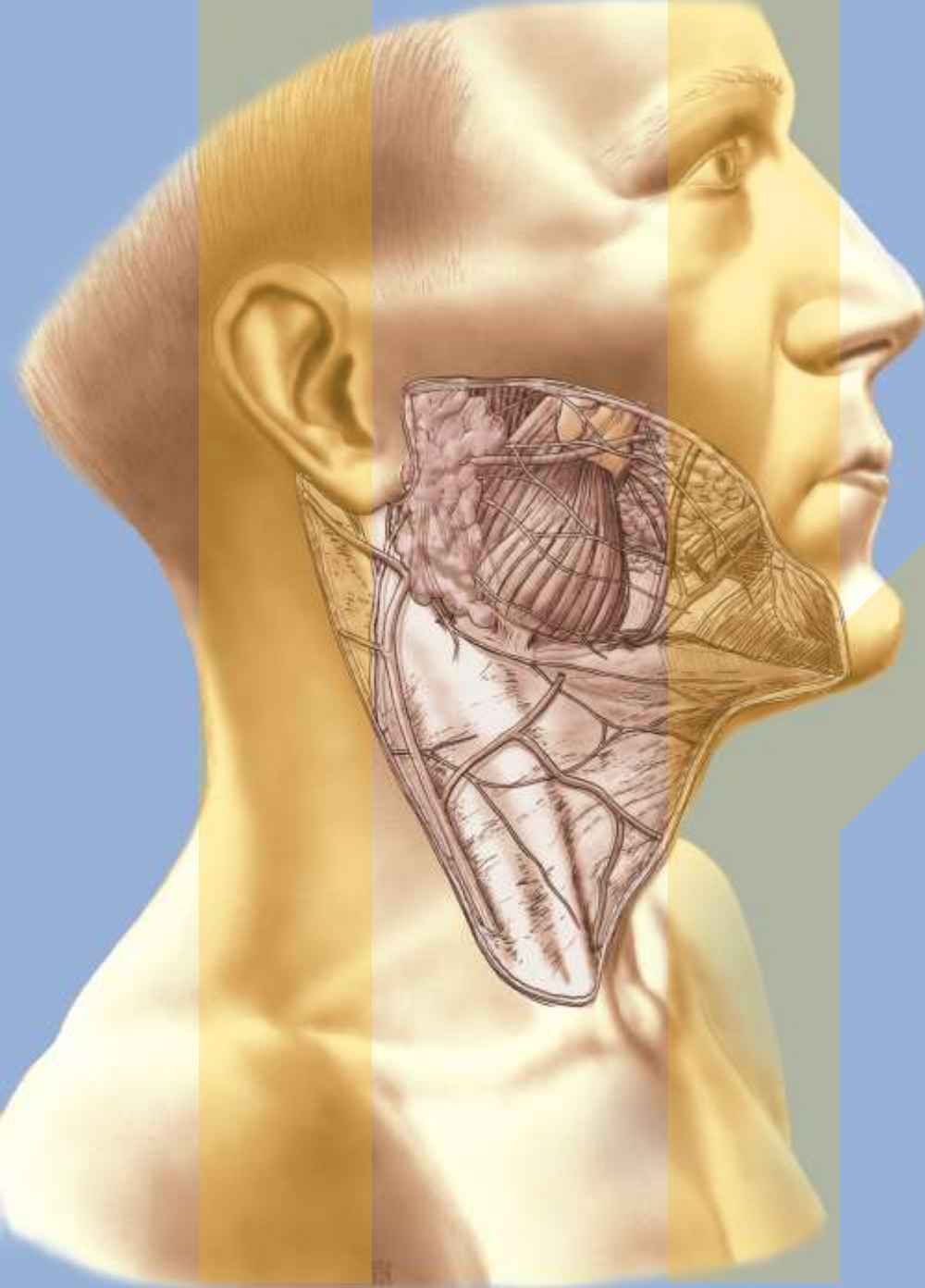


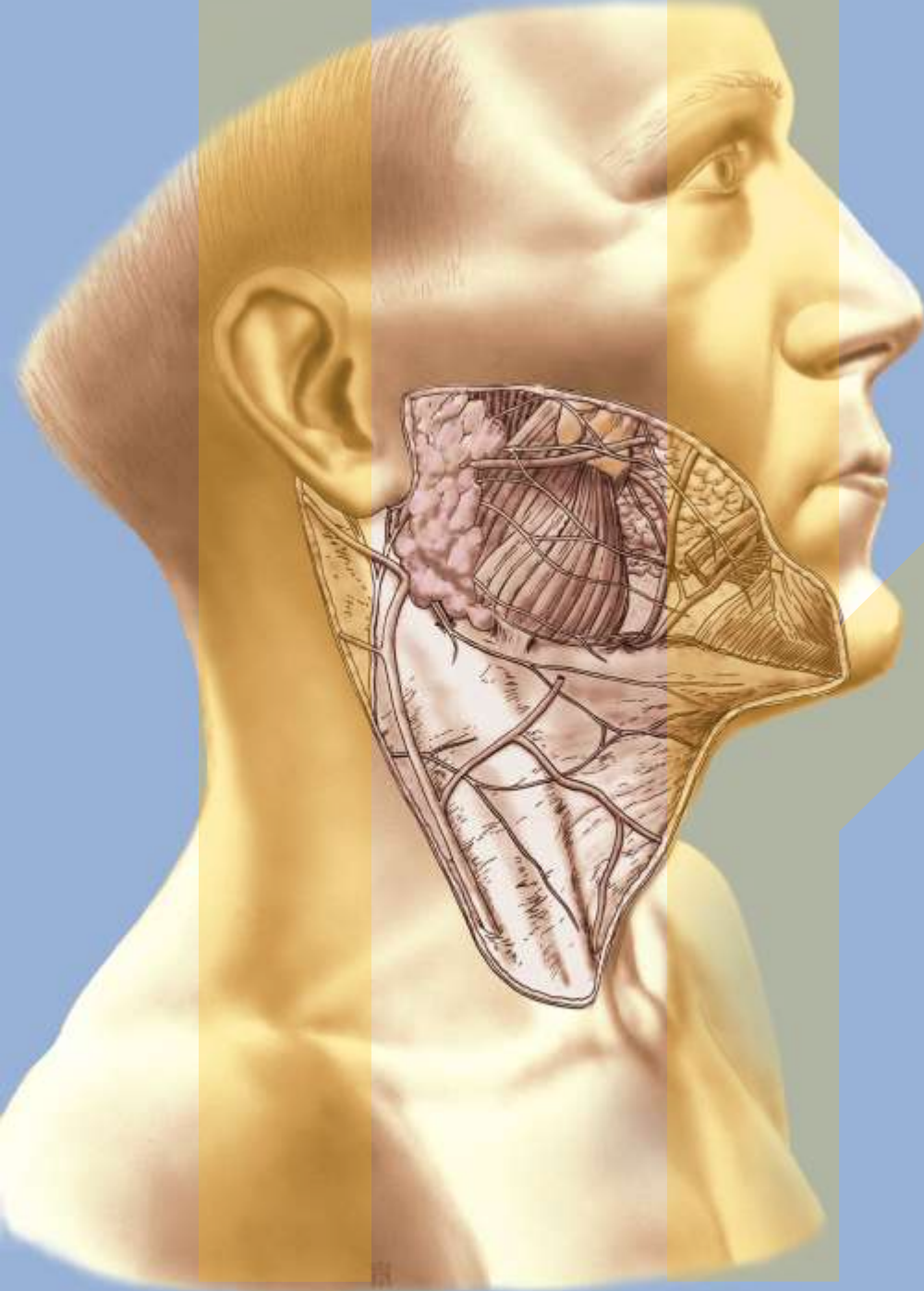


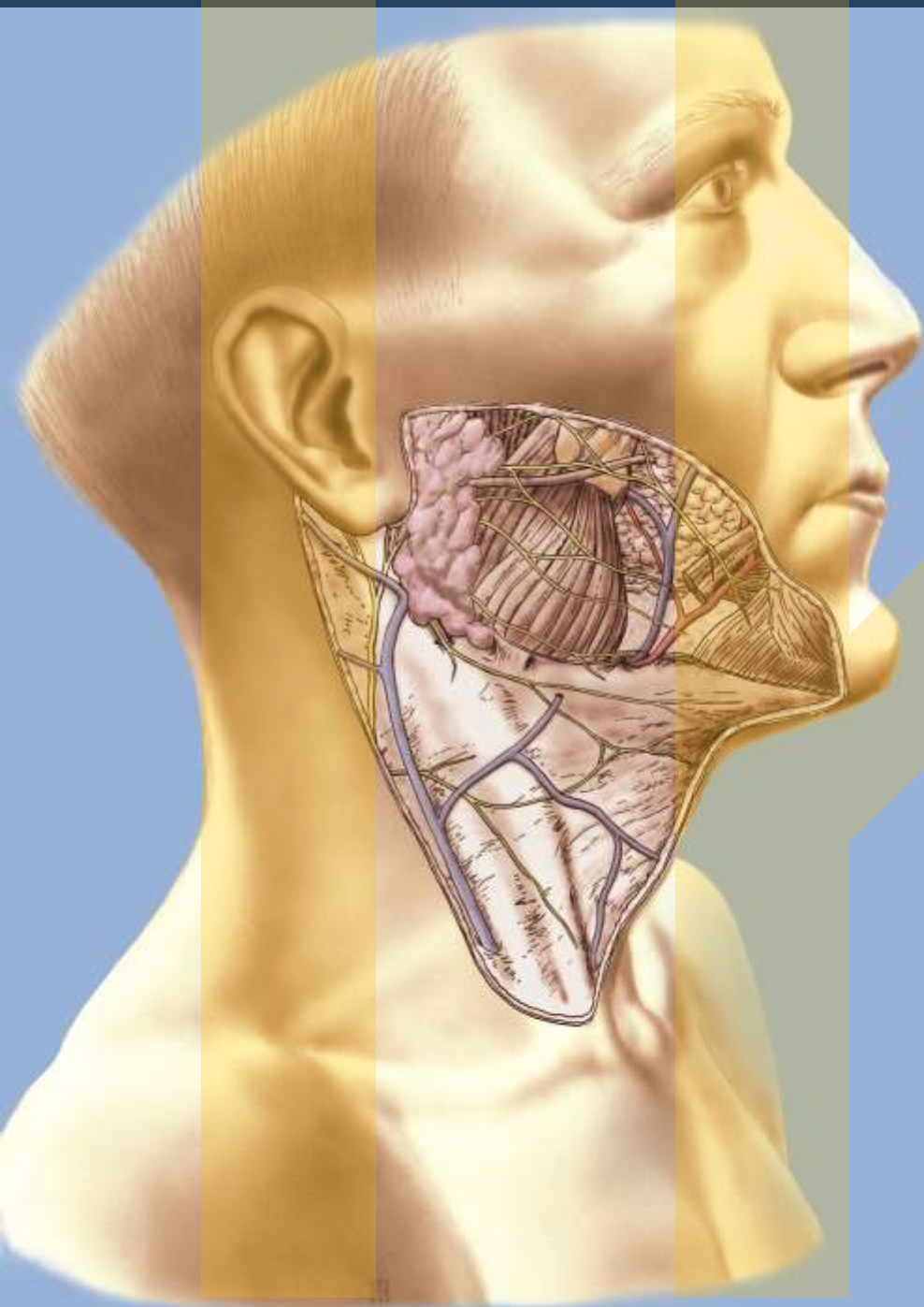


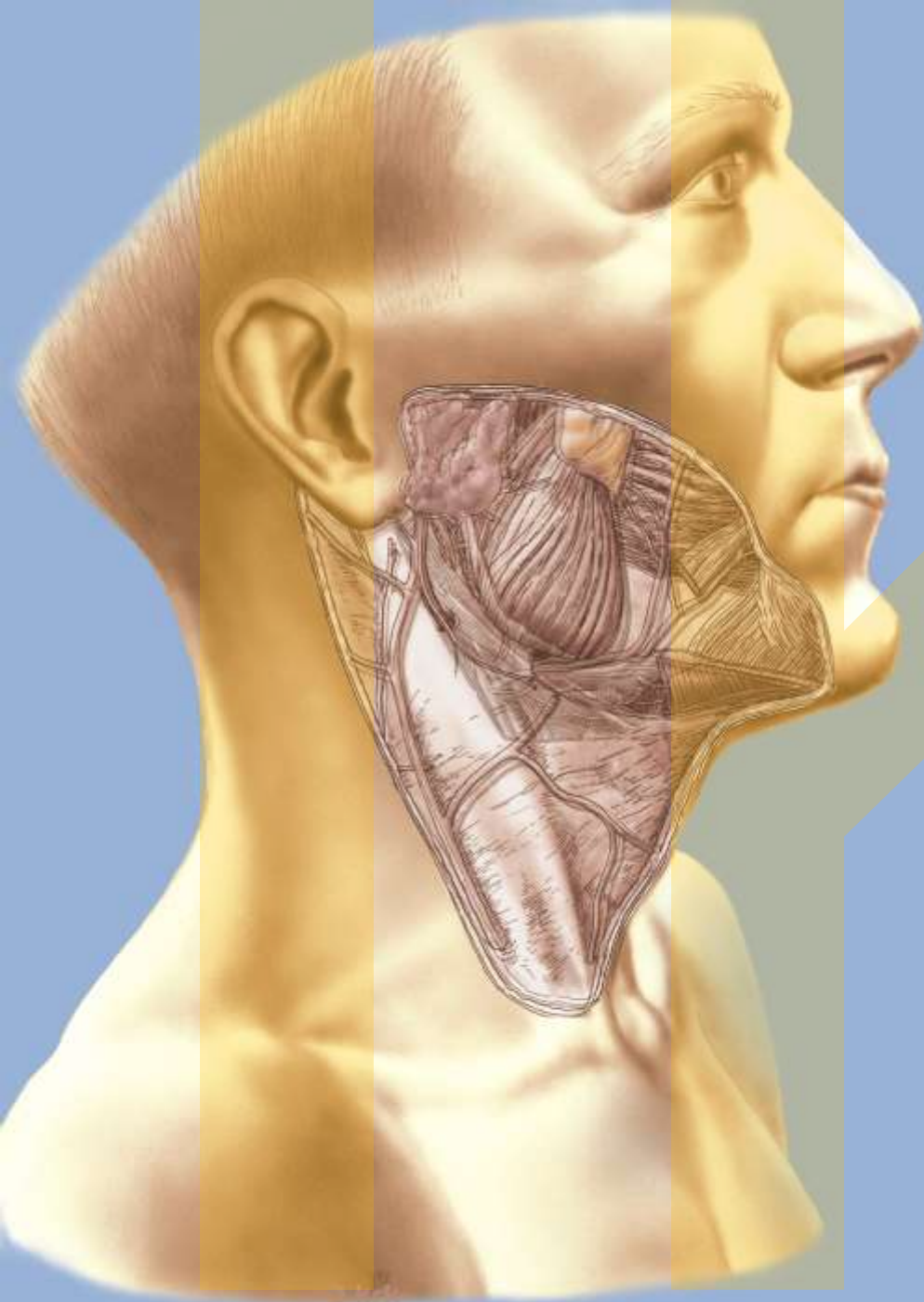


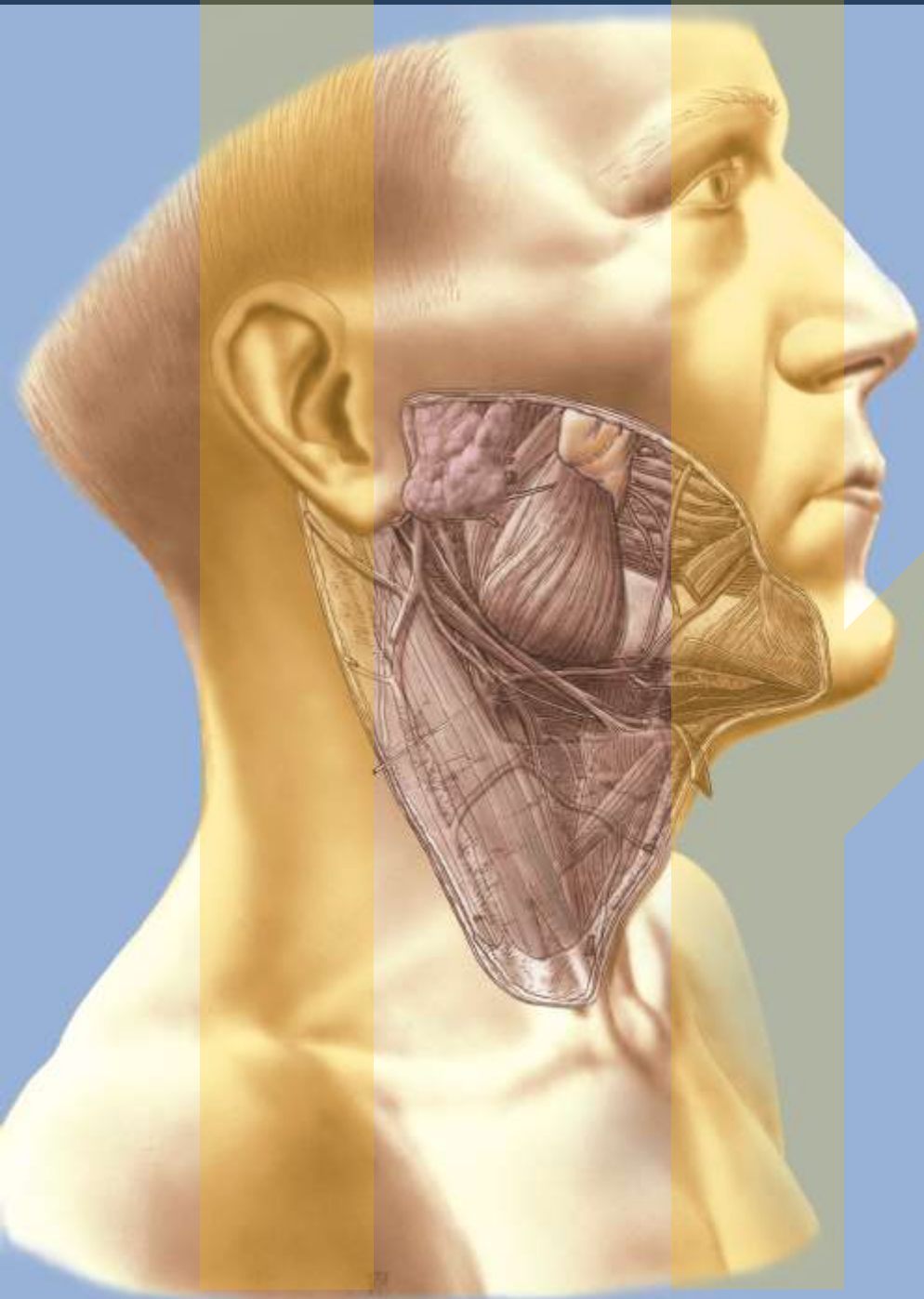


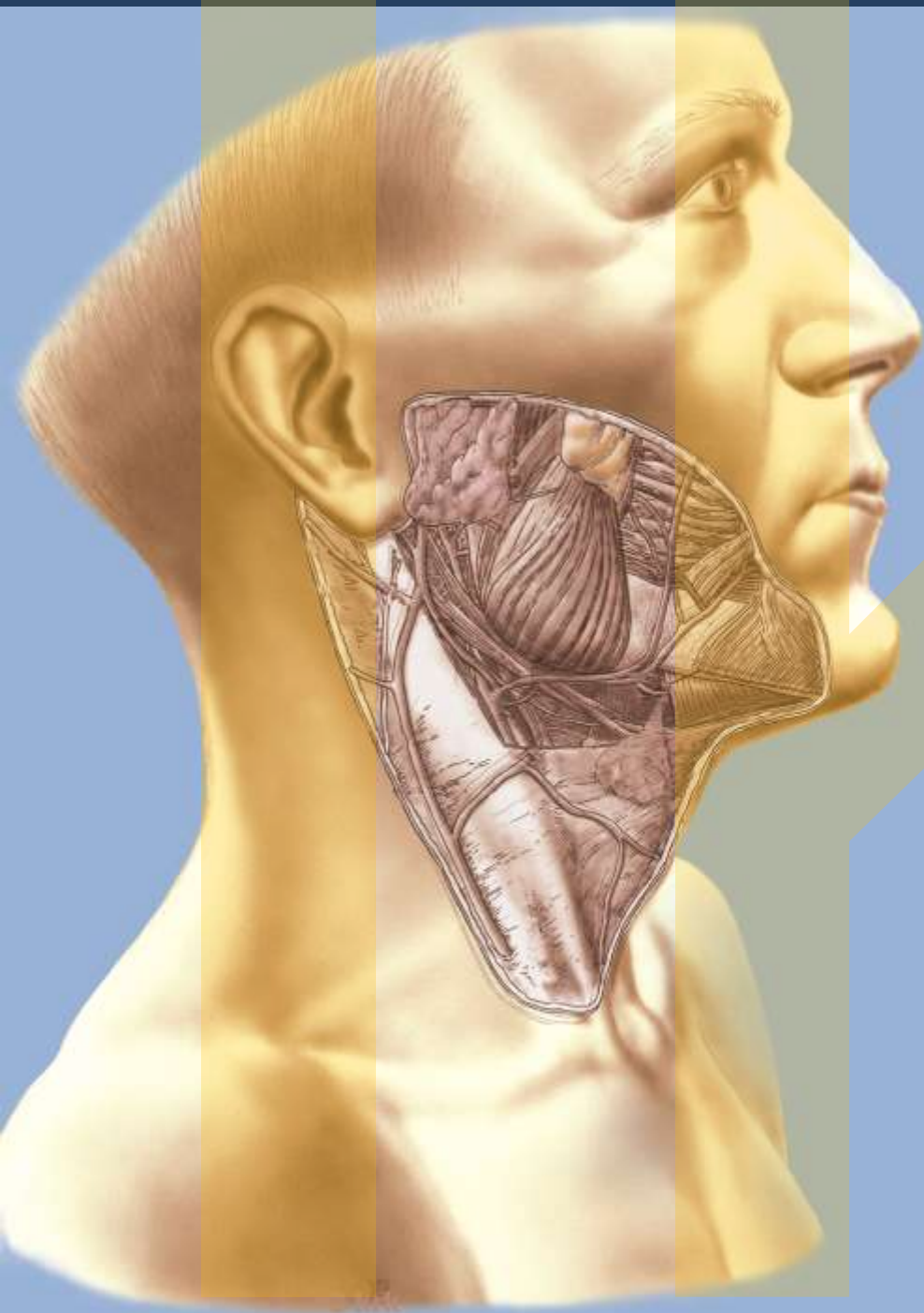


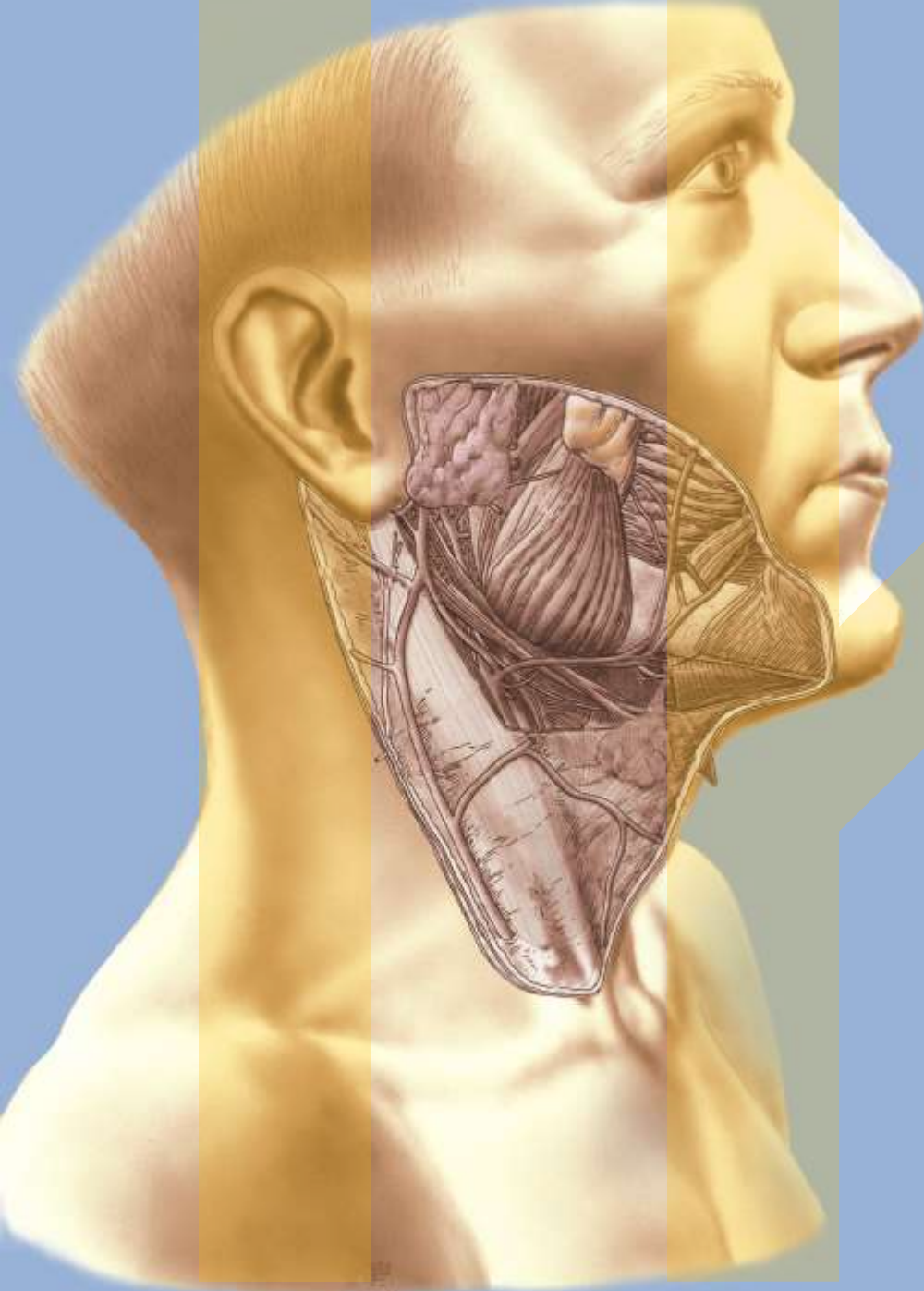


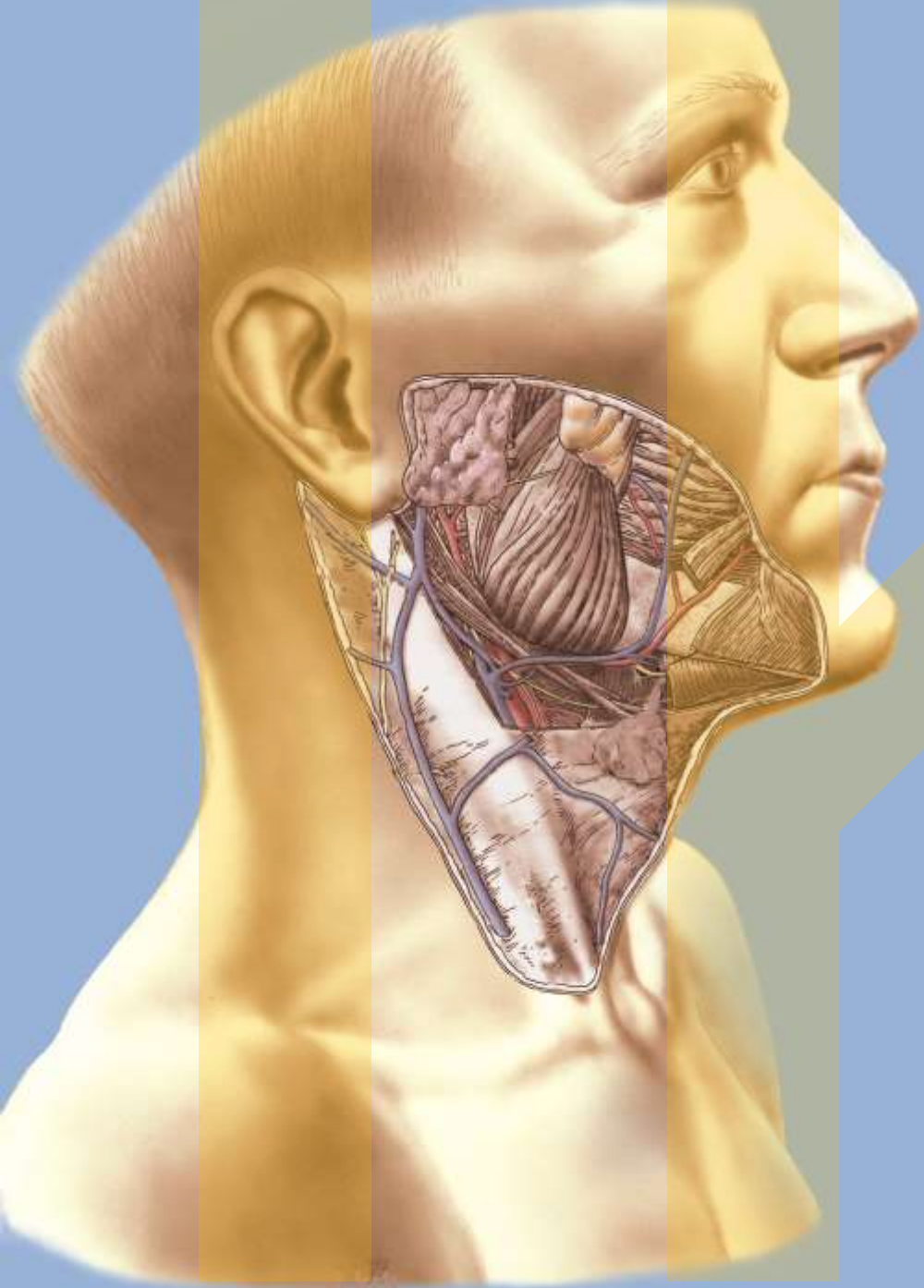


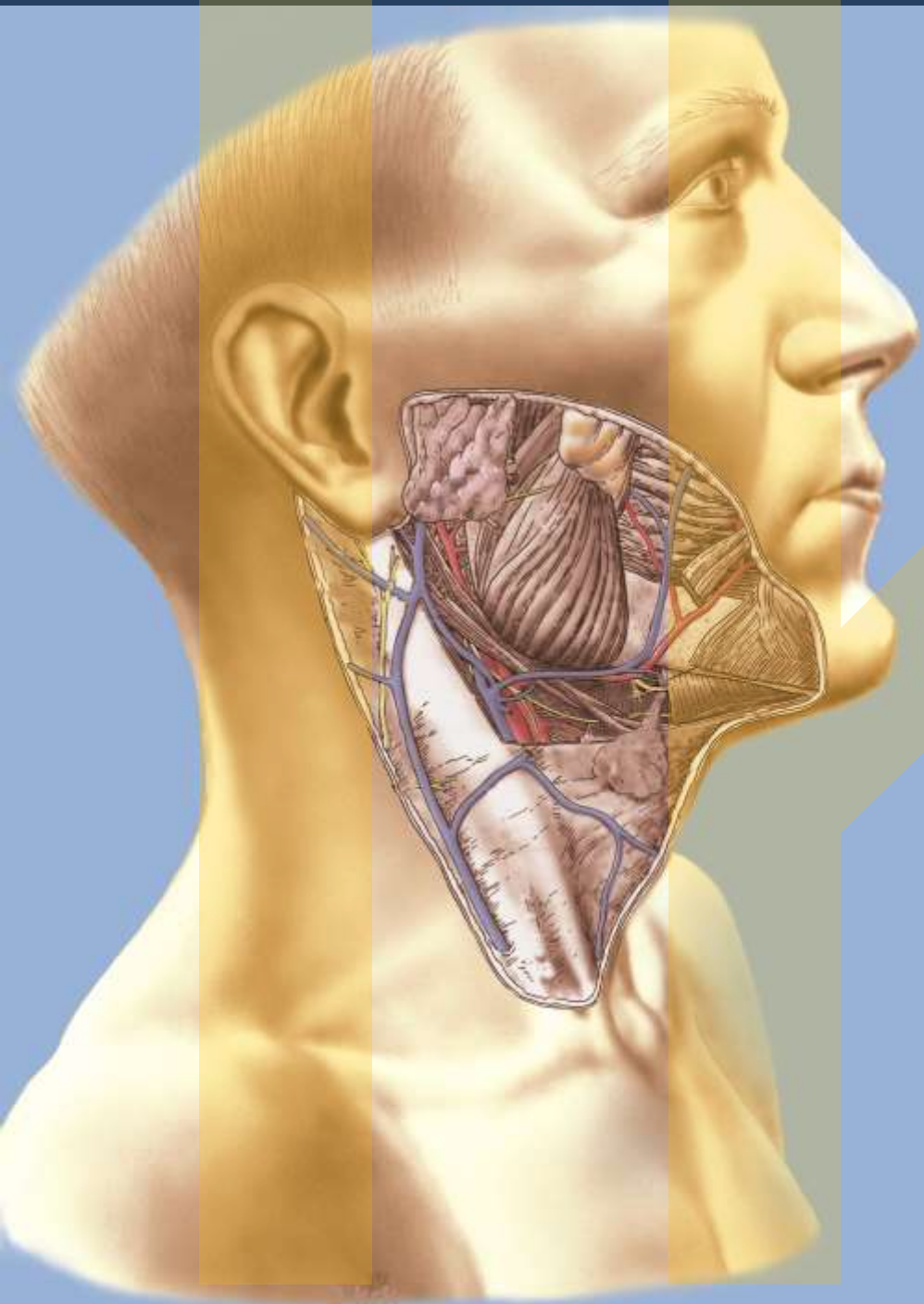


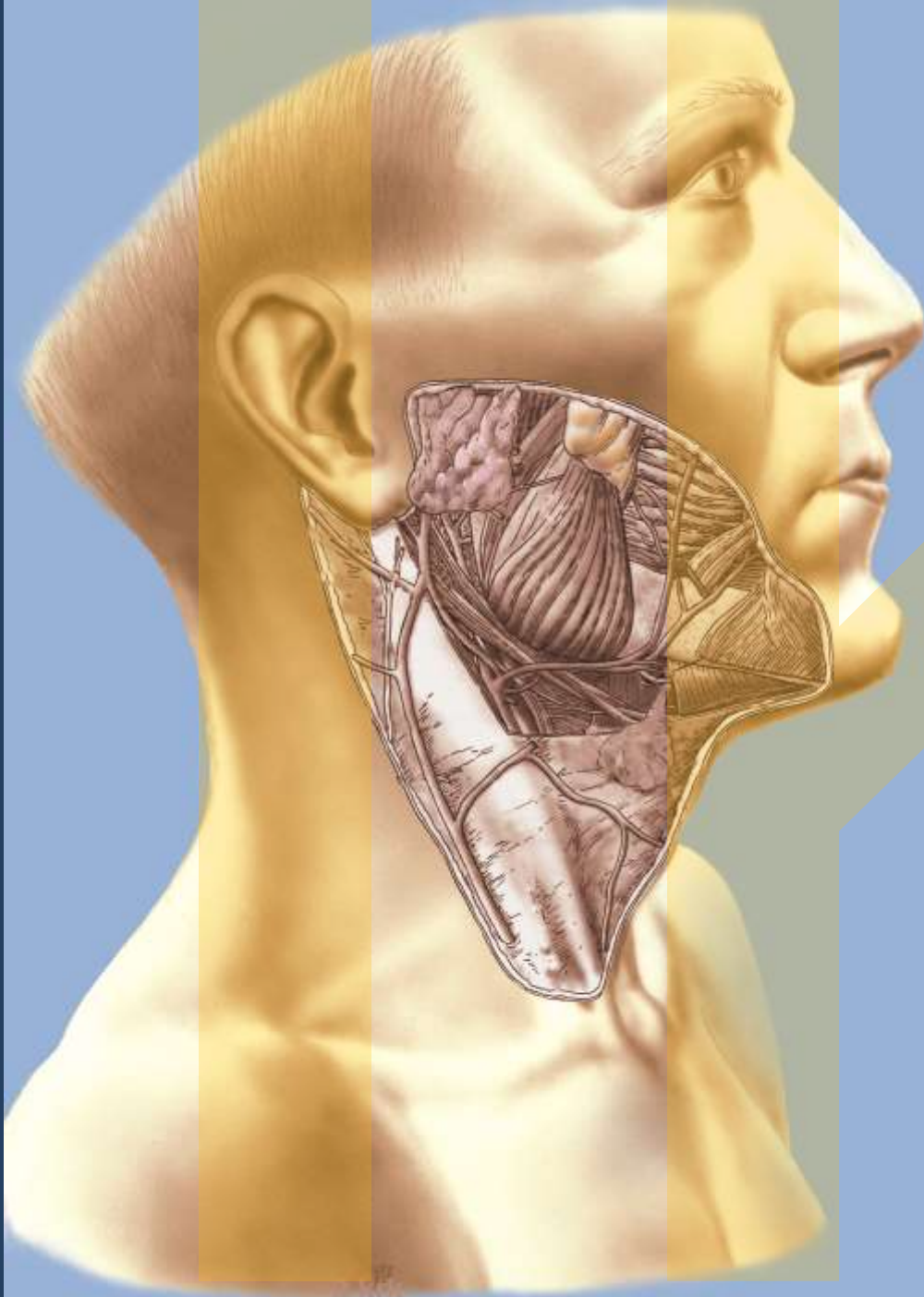


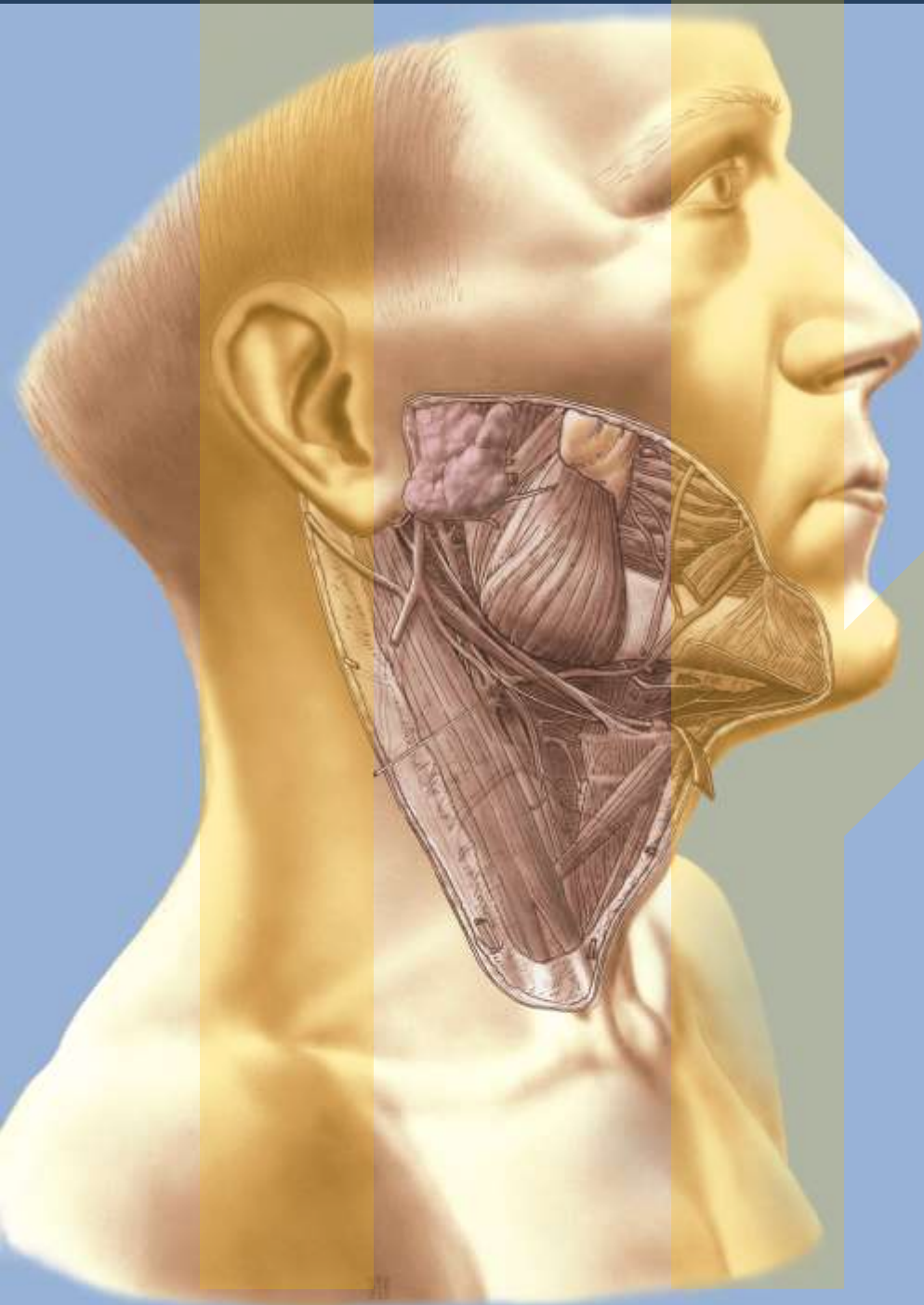


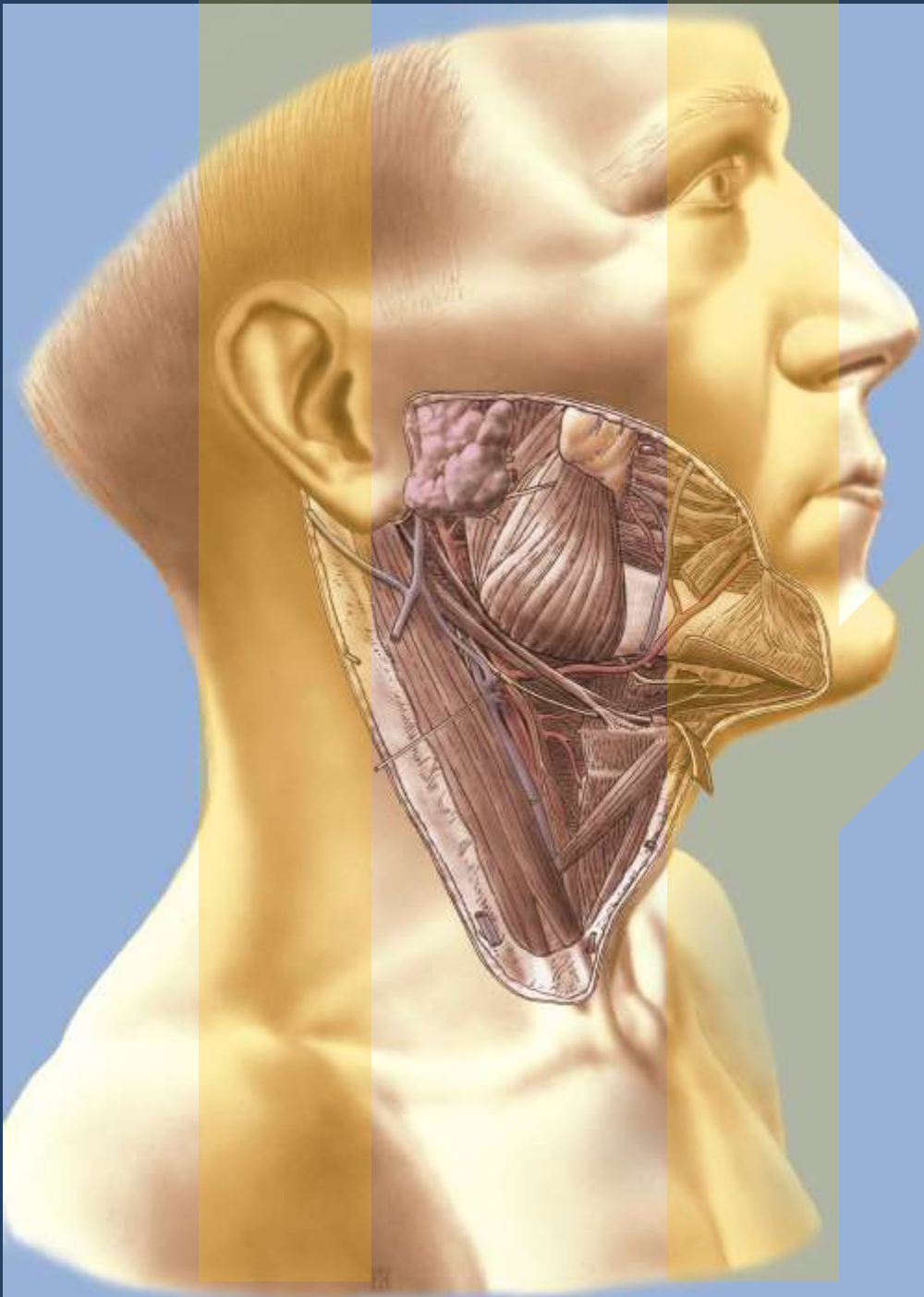


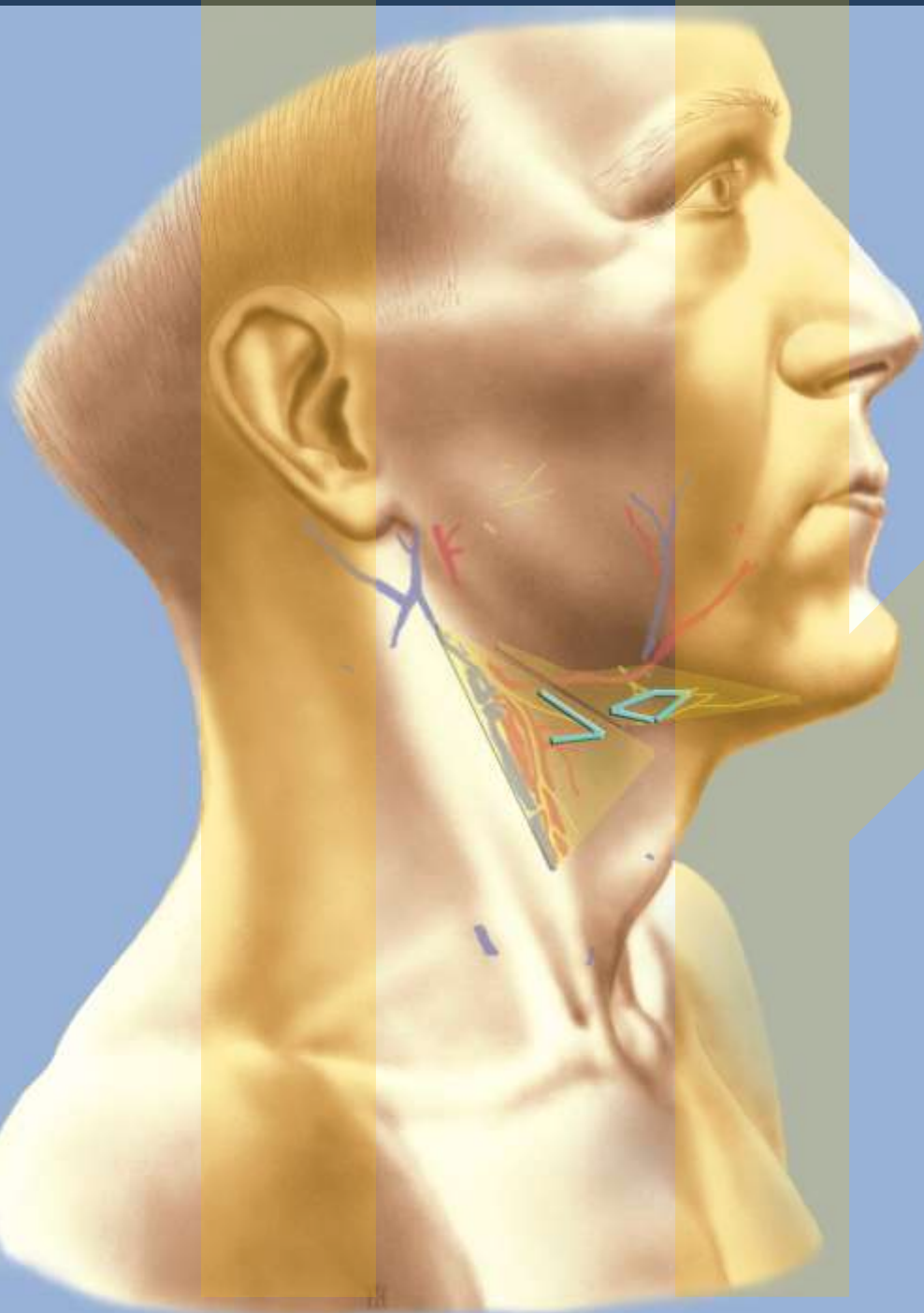



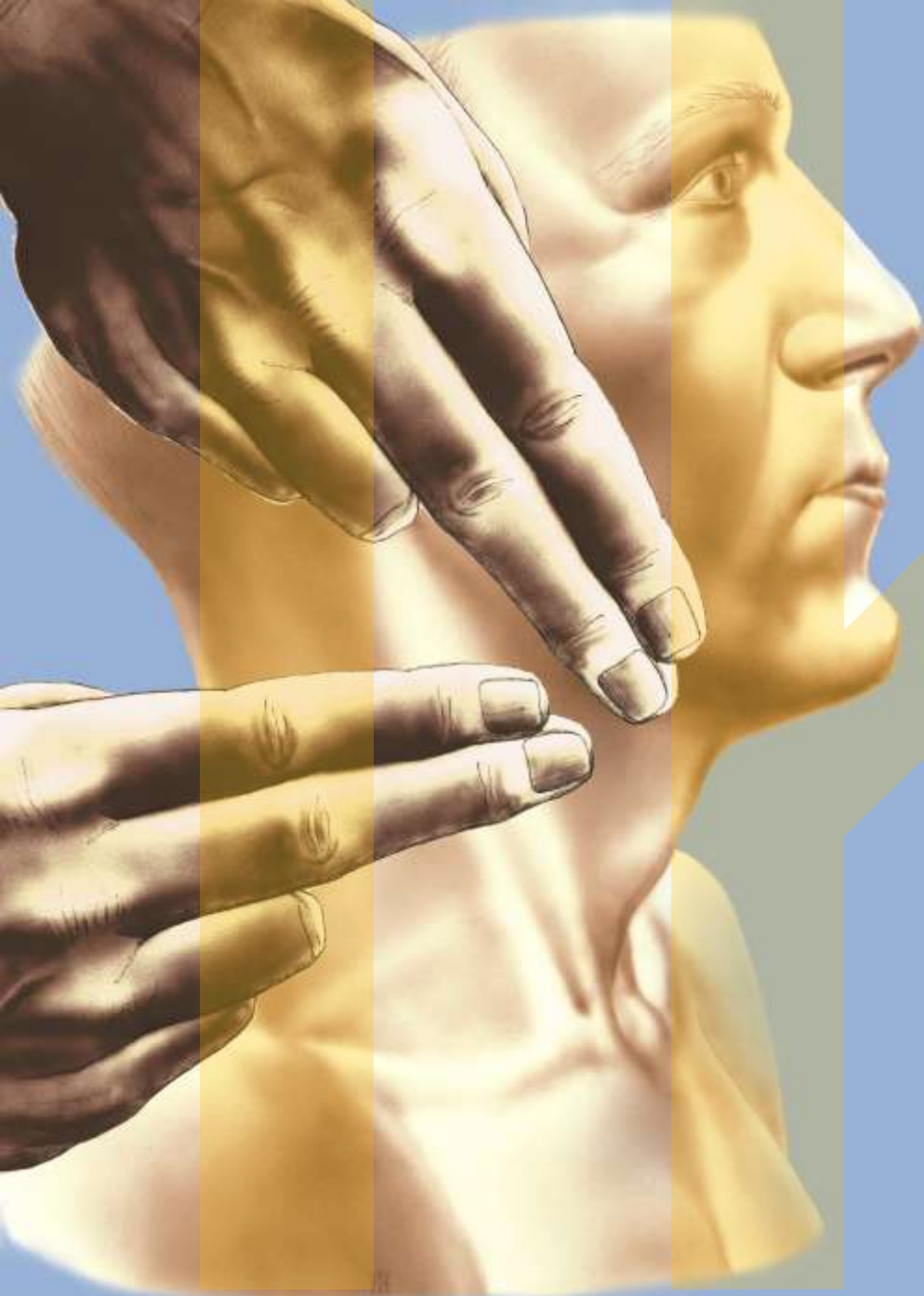
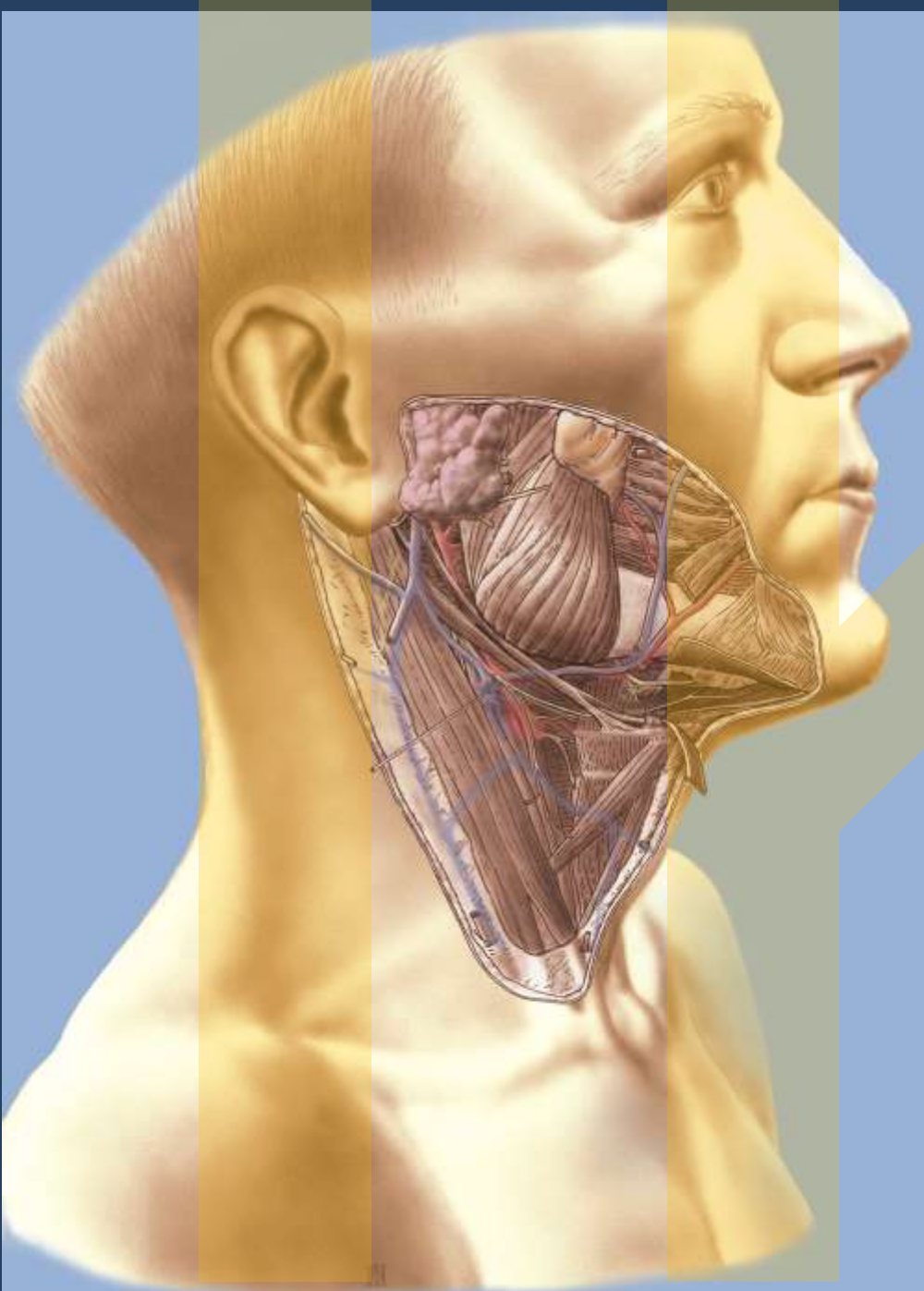


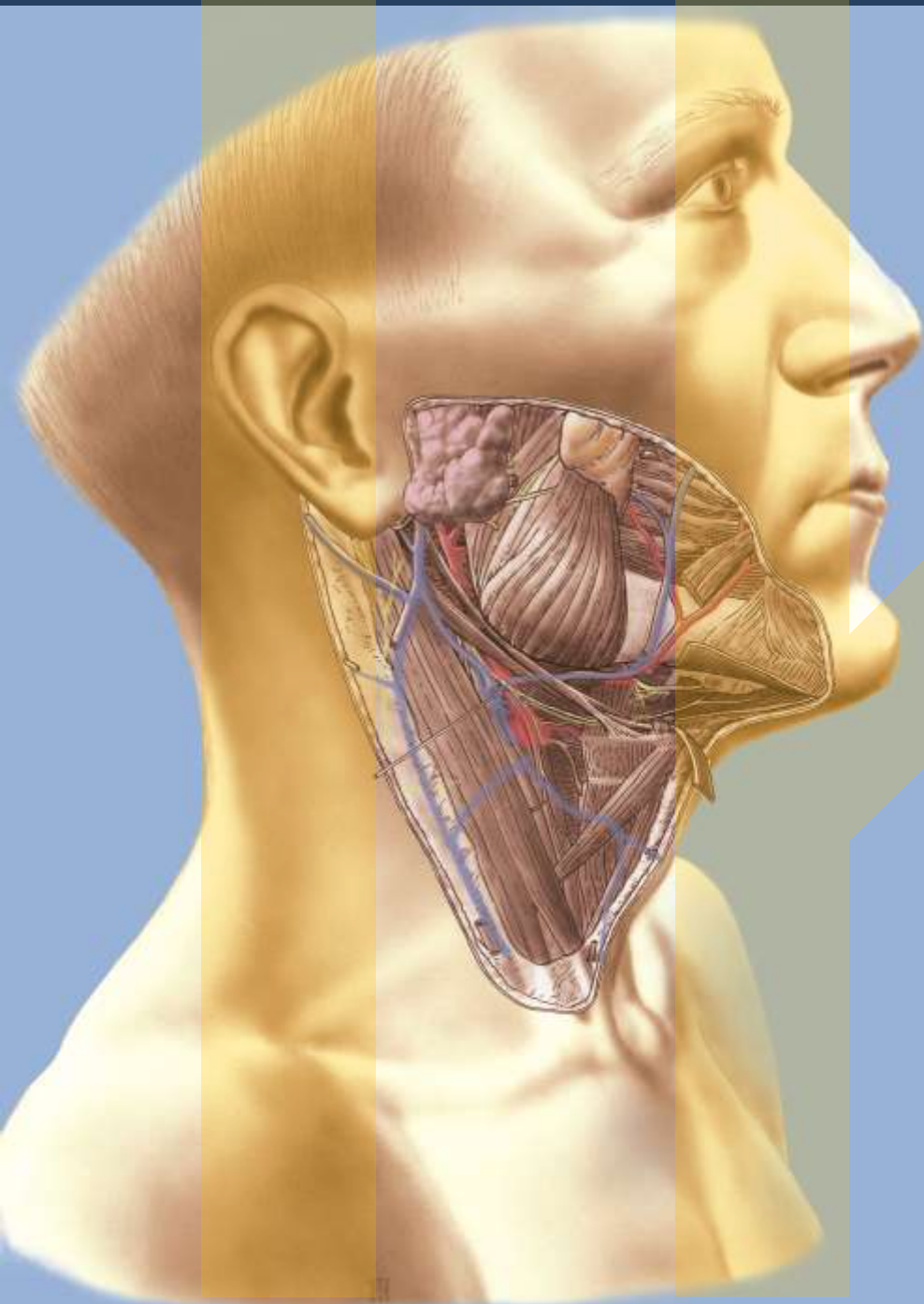


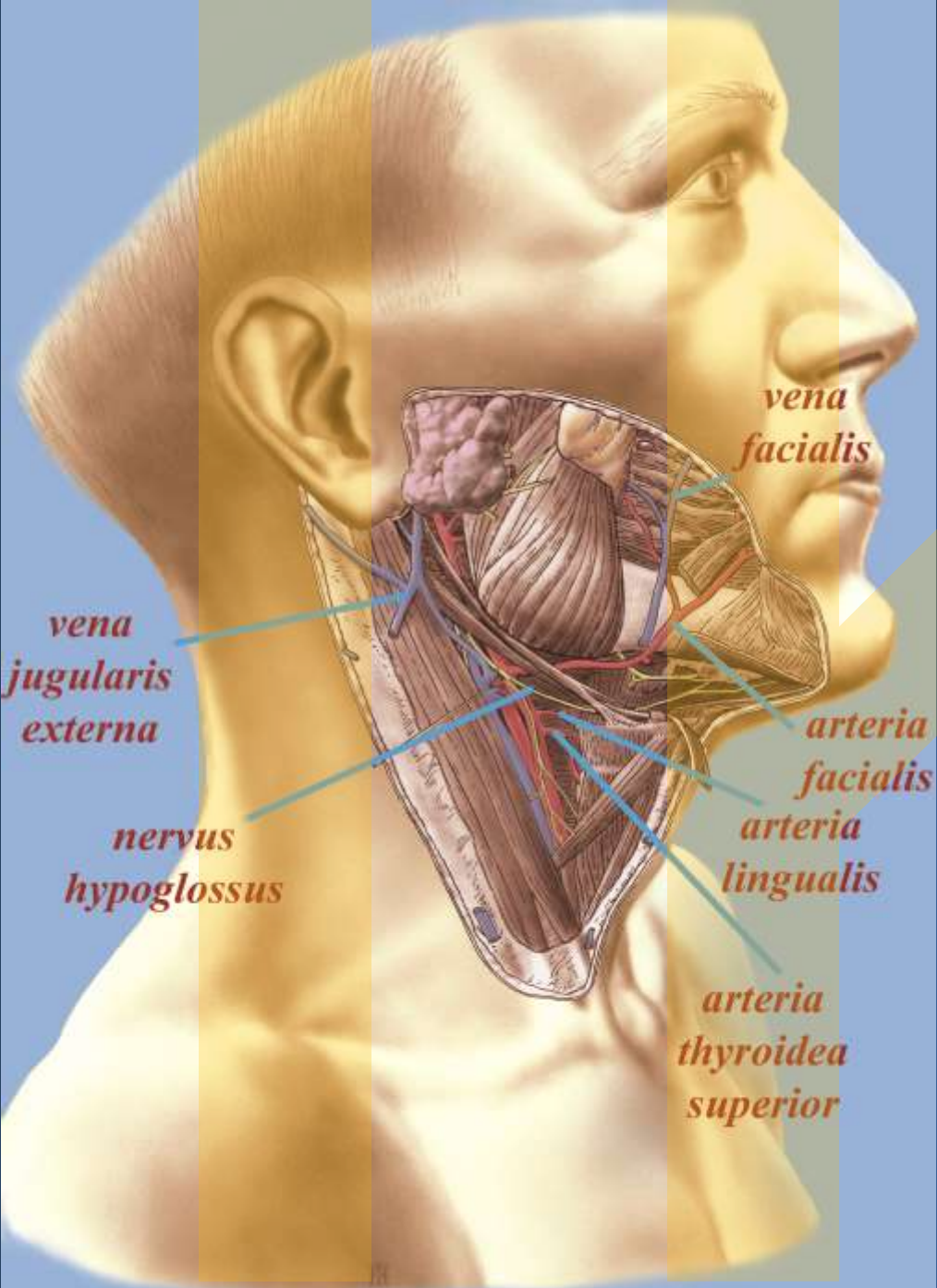












*vena
facialis*

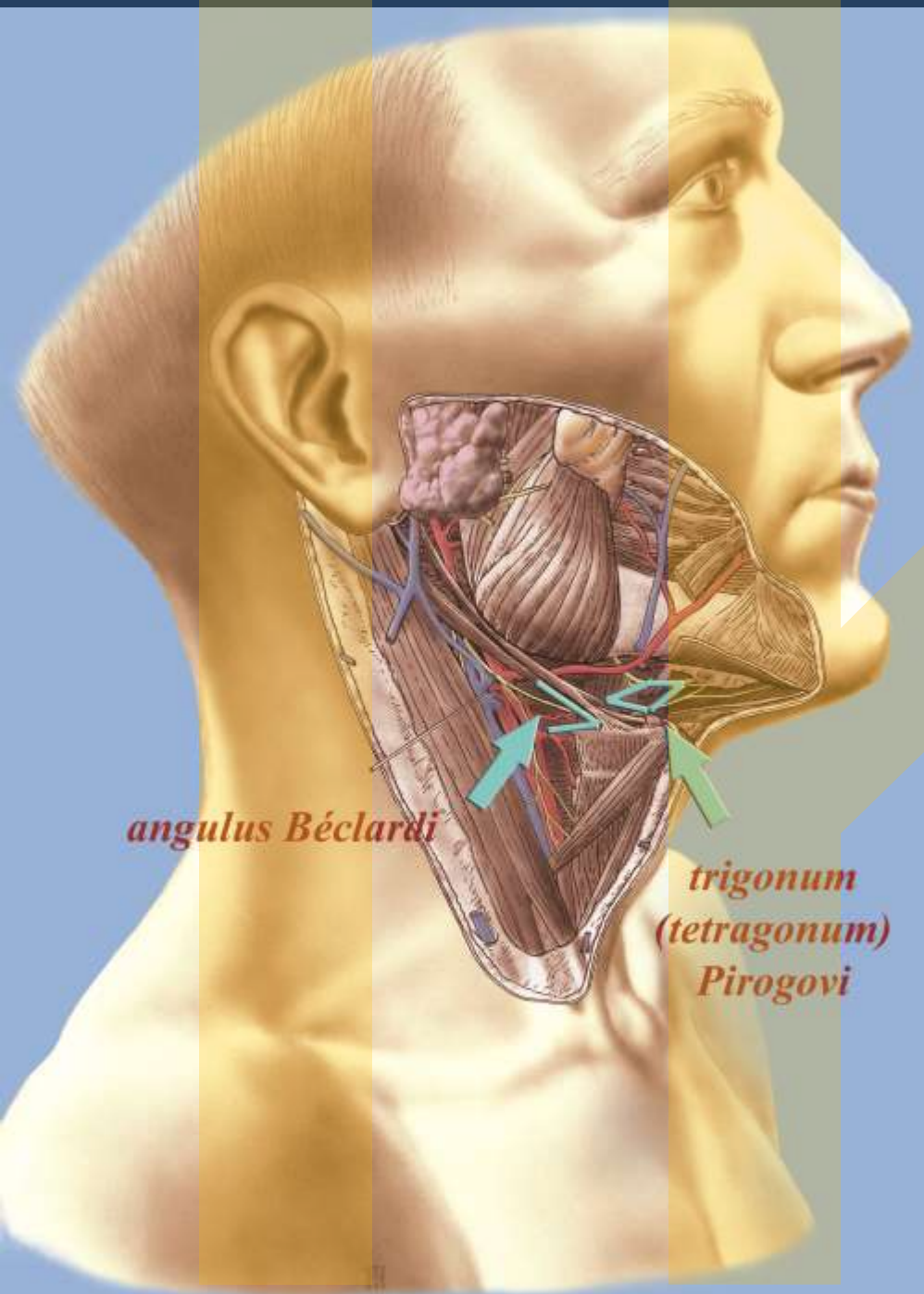
*vena
jugularis
externa*

*nervus
hypoglossus*

*arteria
facialis*

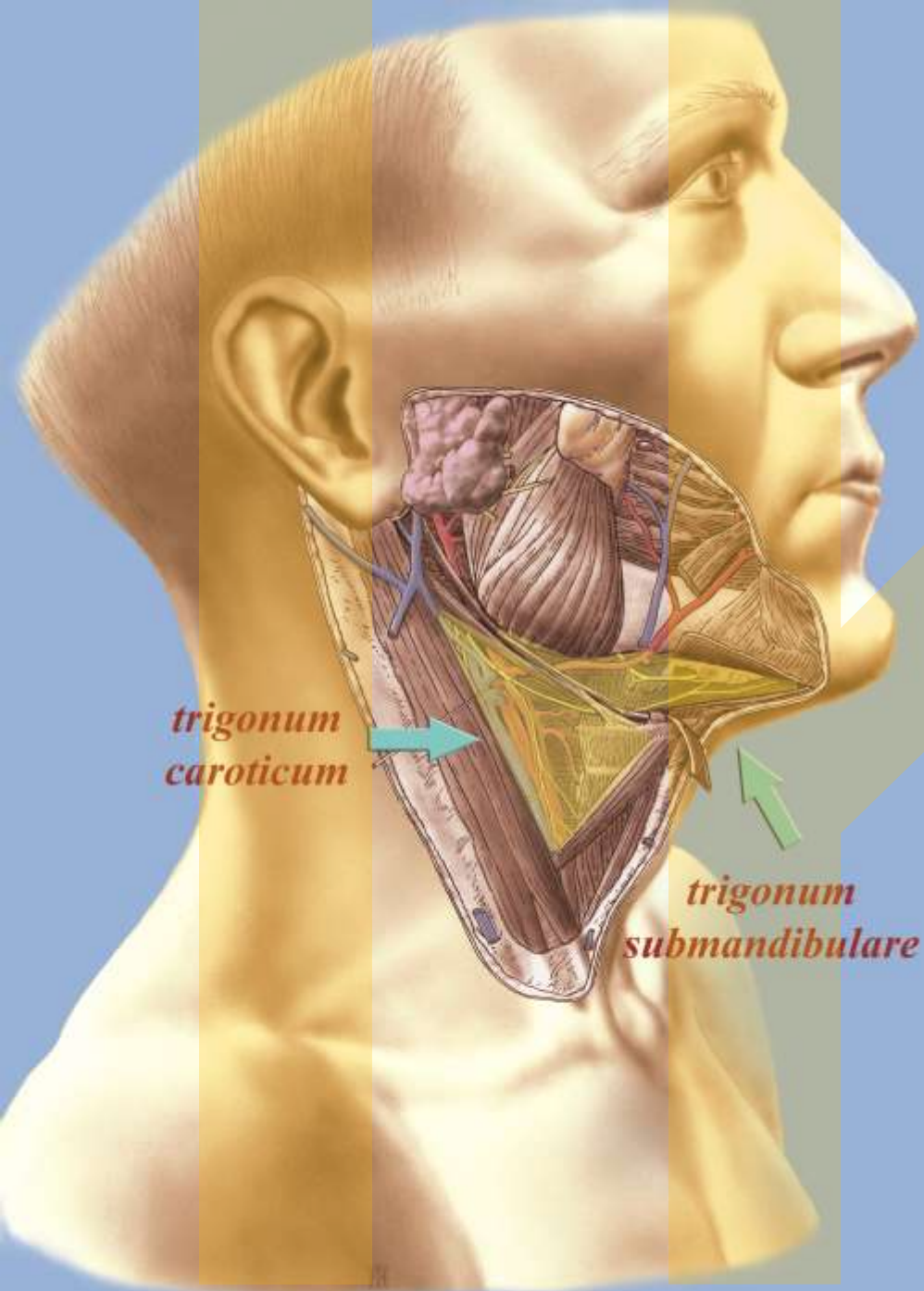
*arteria
lingualis*

*arteria
thyroidea
superior*



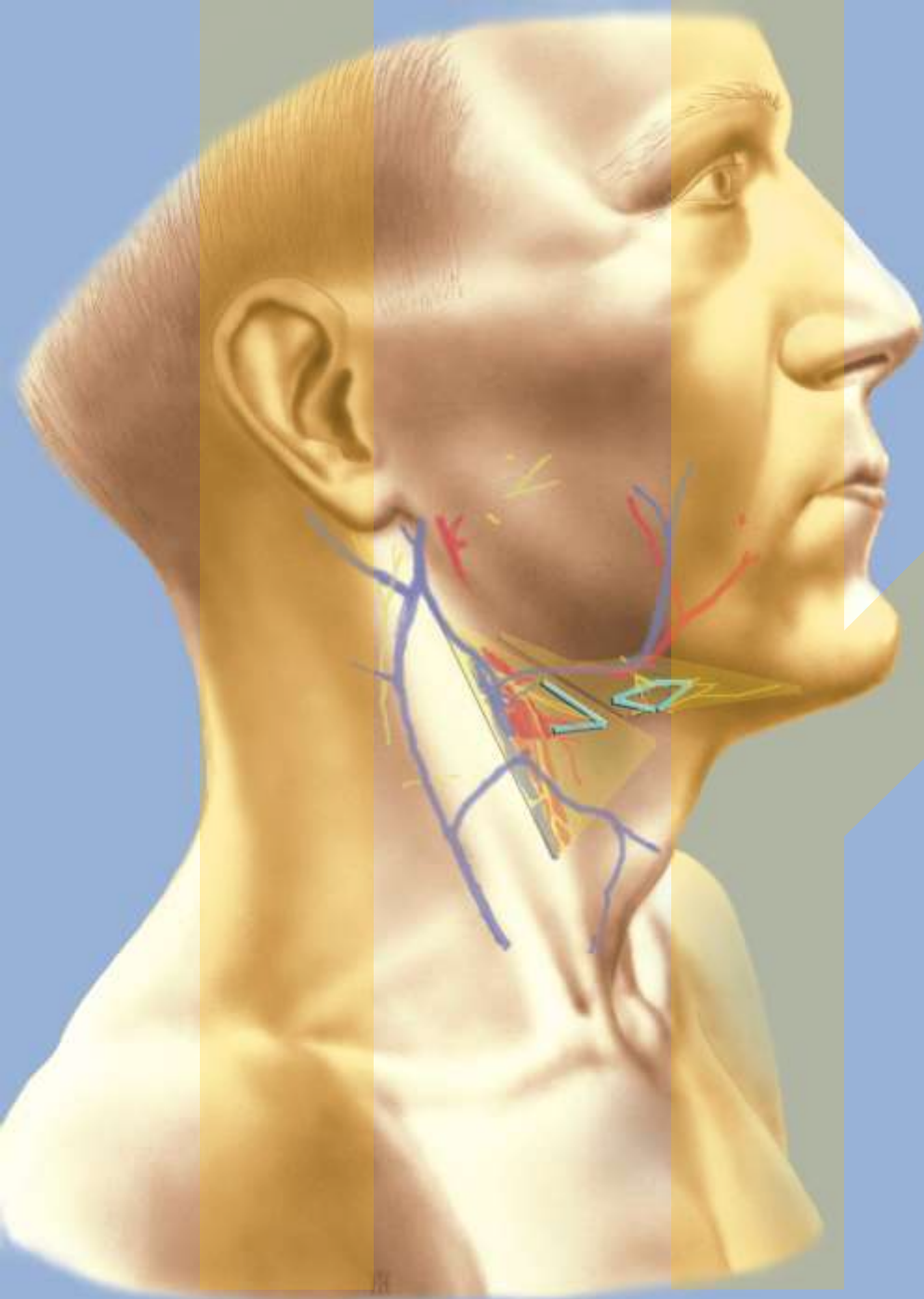
angulus Béclardi

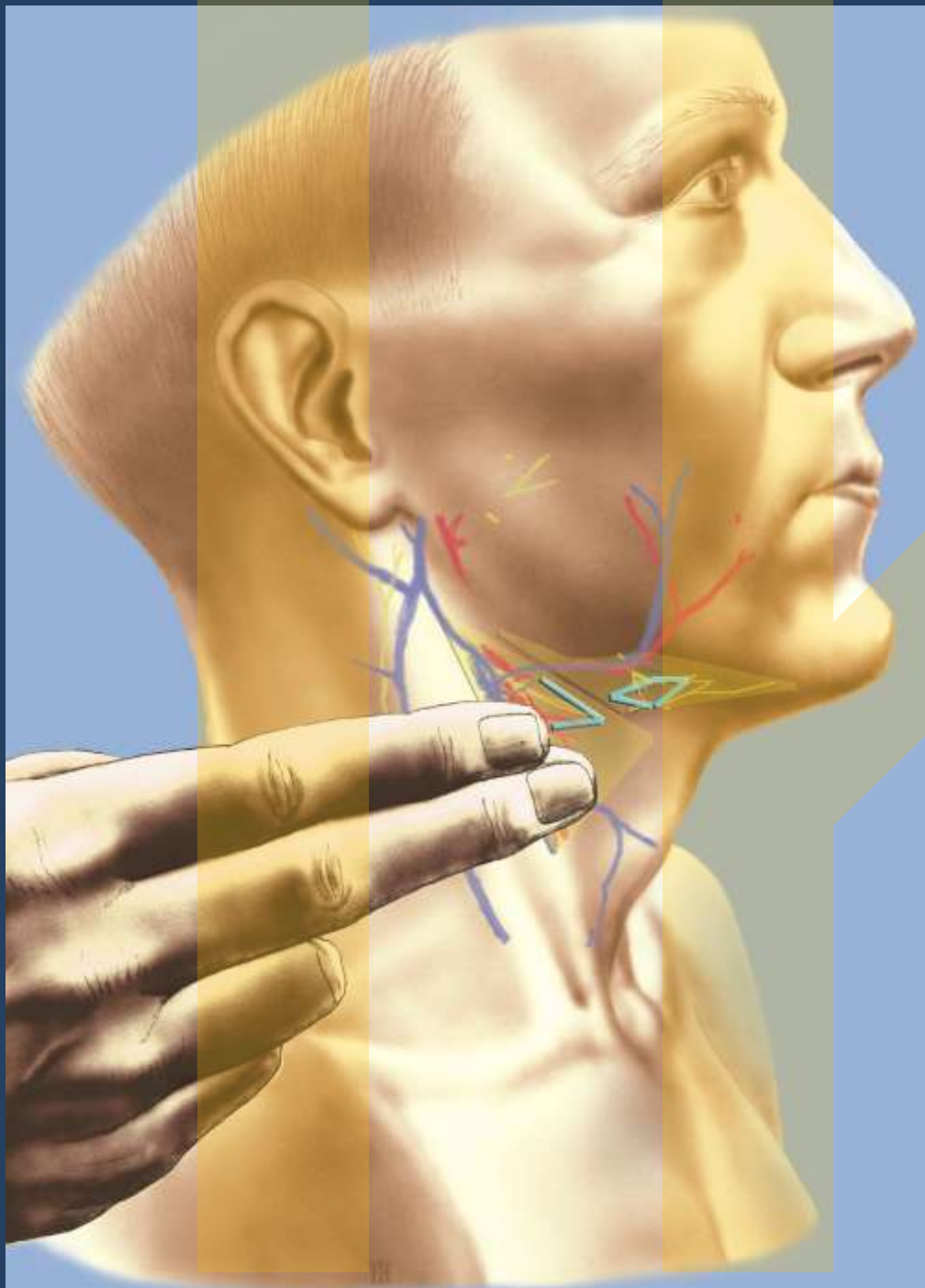
*trigonum
(tetragonum)
Pirogovi*

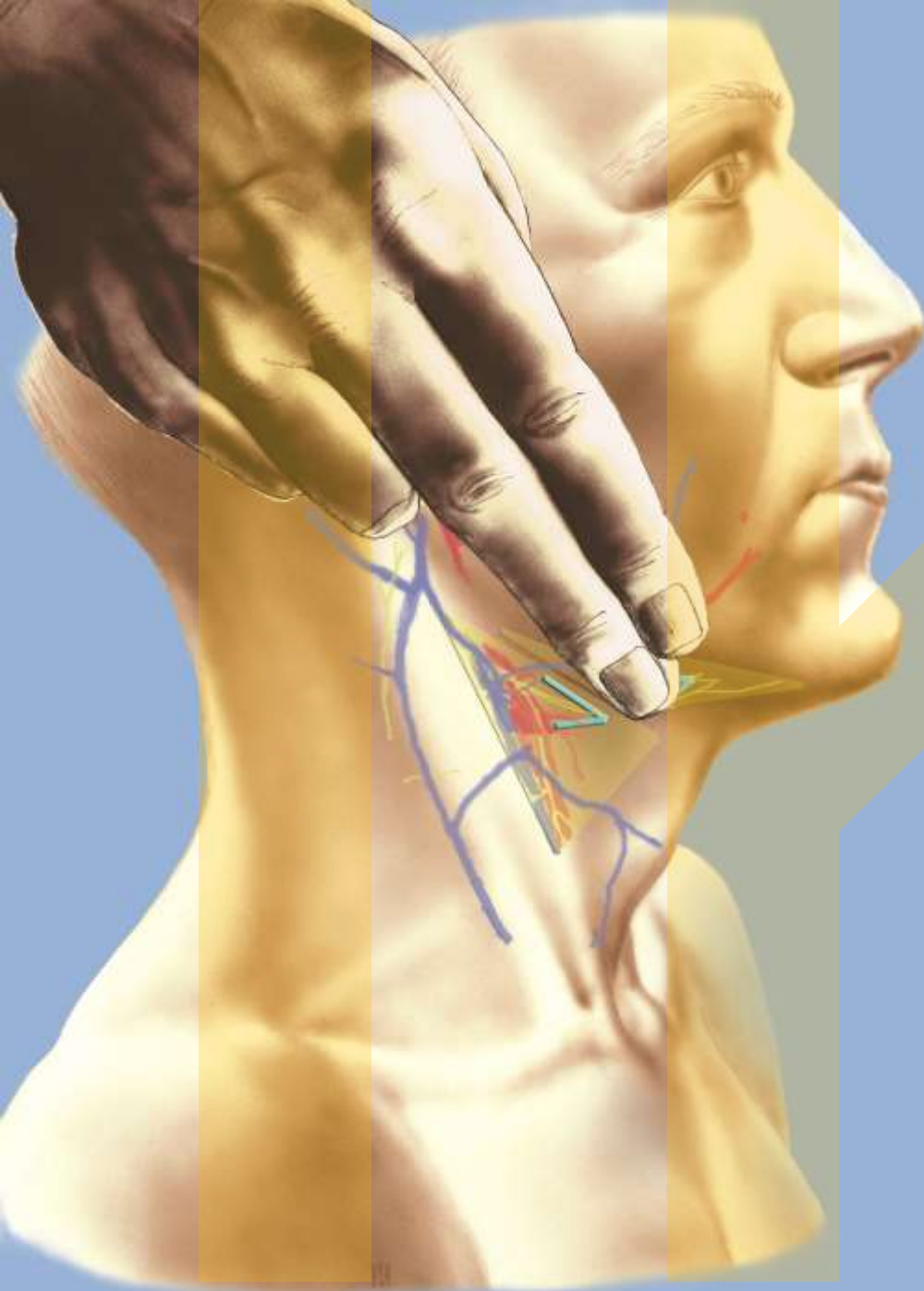


*trigonum
caroticum*

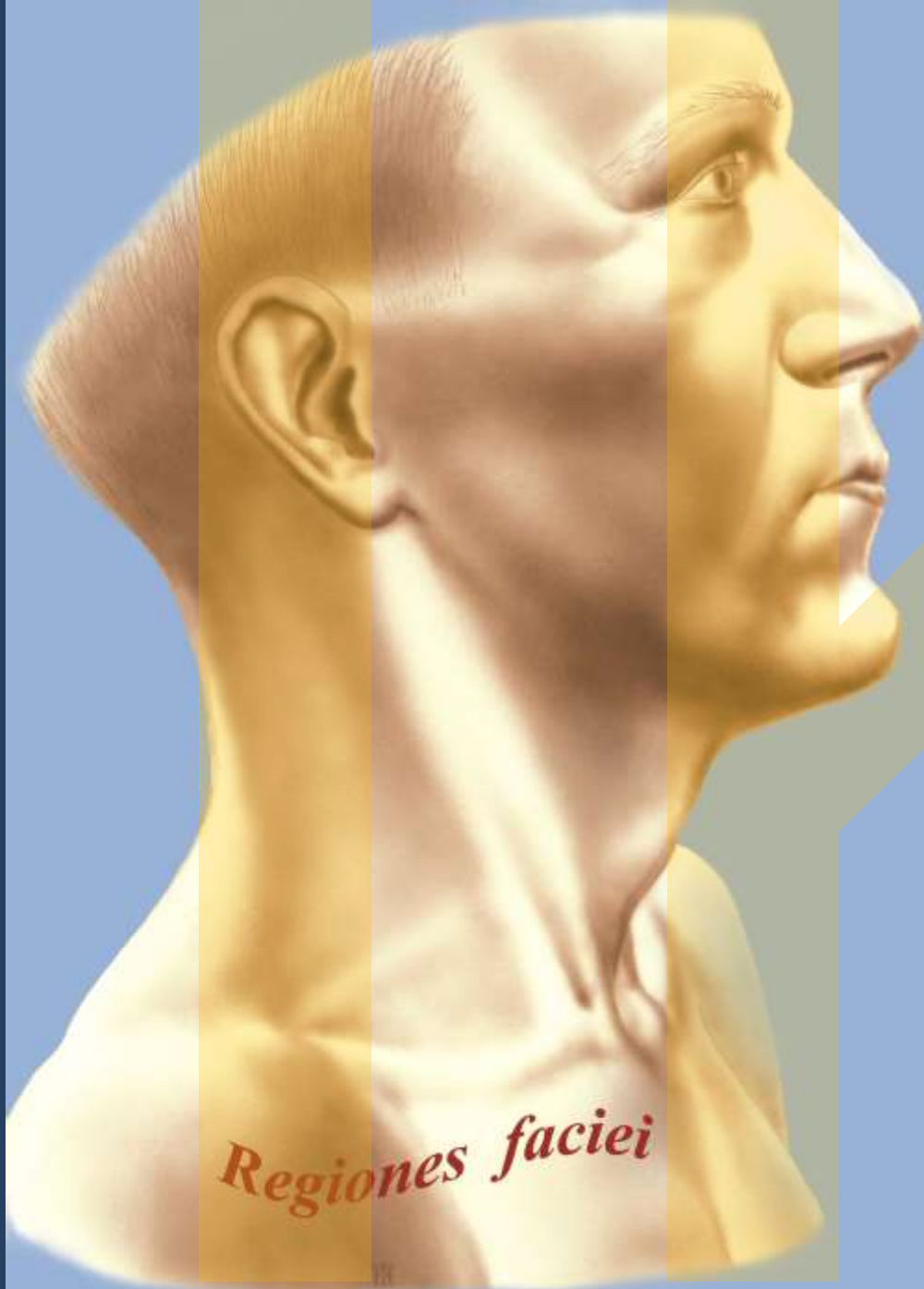
*trigonum
submandibulare*











Regiones faciei

