

Principy Principles

Maxilla roste pomalu mandibula déle
low growth growth for longer time

Fyziologická mírná anteriorotace
anteriorotation

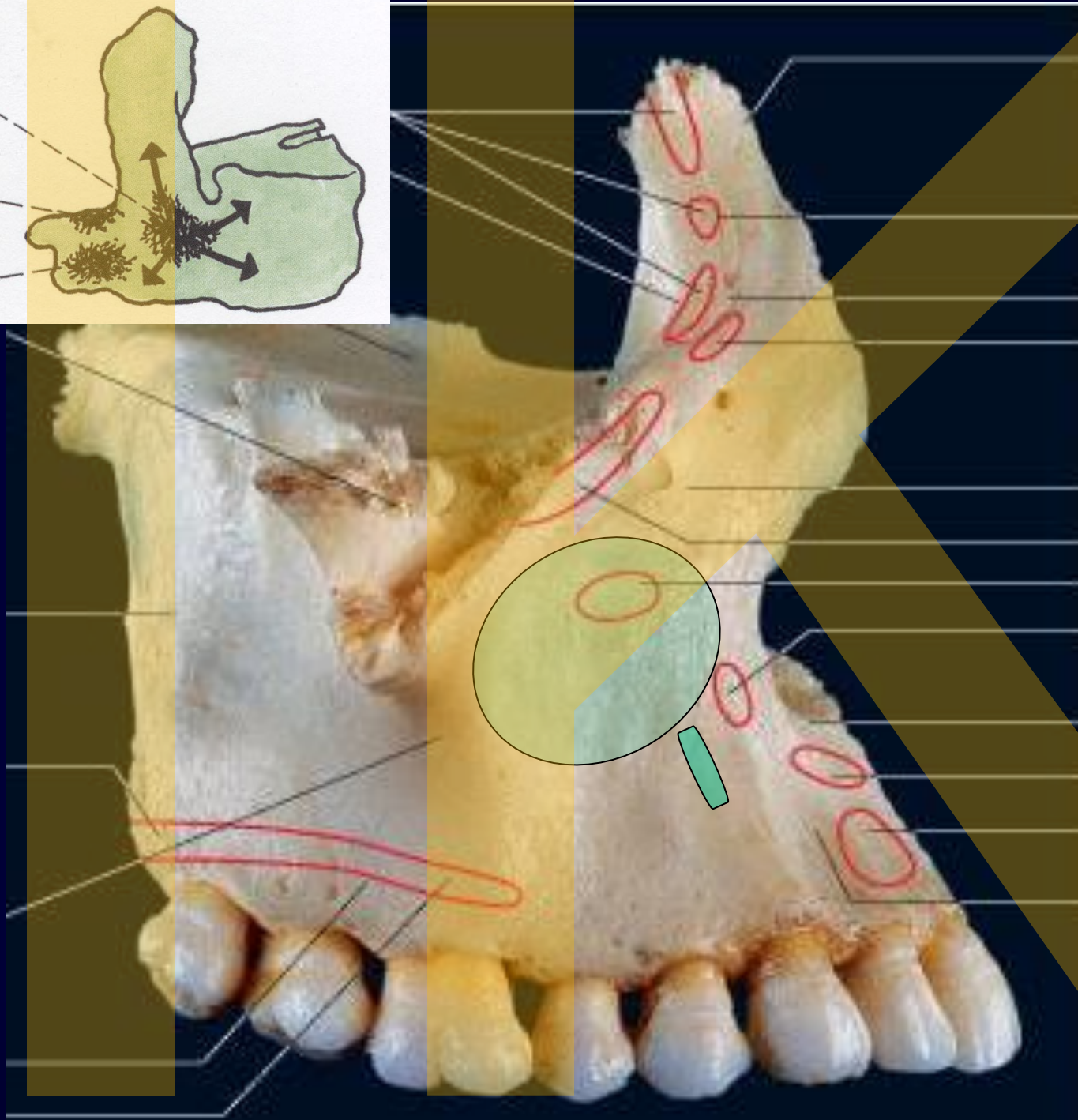
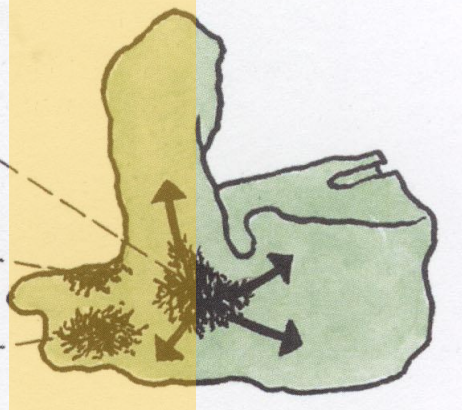
Totální rotace ve vztahu k okolí) (true rotation in
relation to surrounding structures)

Rotace uvnitř matrix (apparent rotation)


1. 6.T.F.


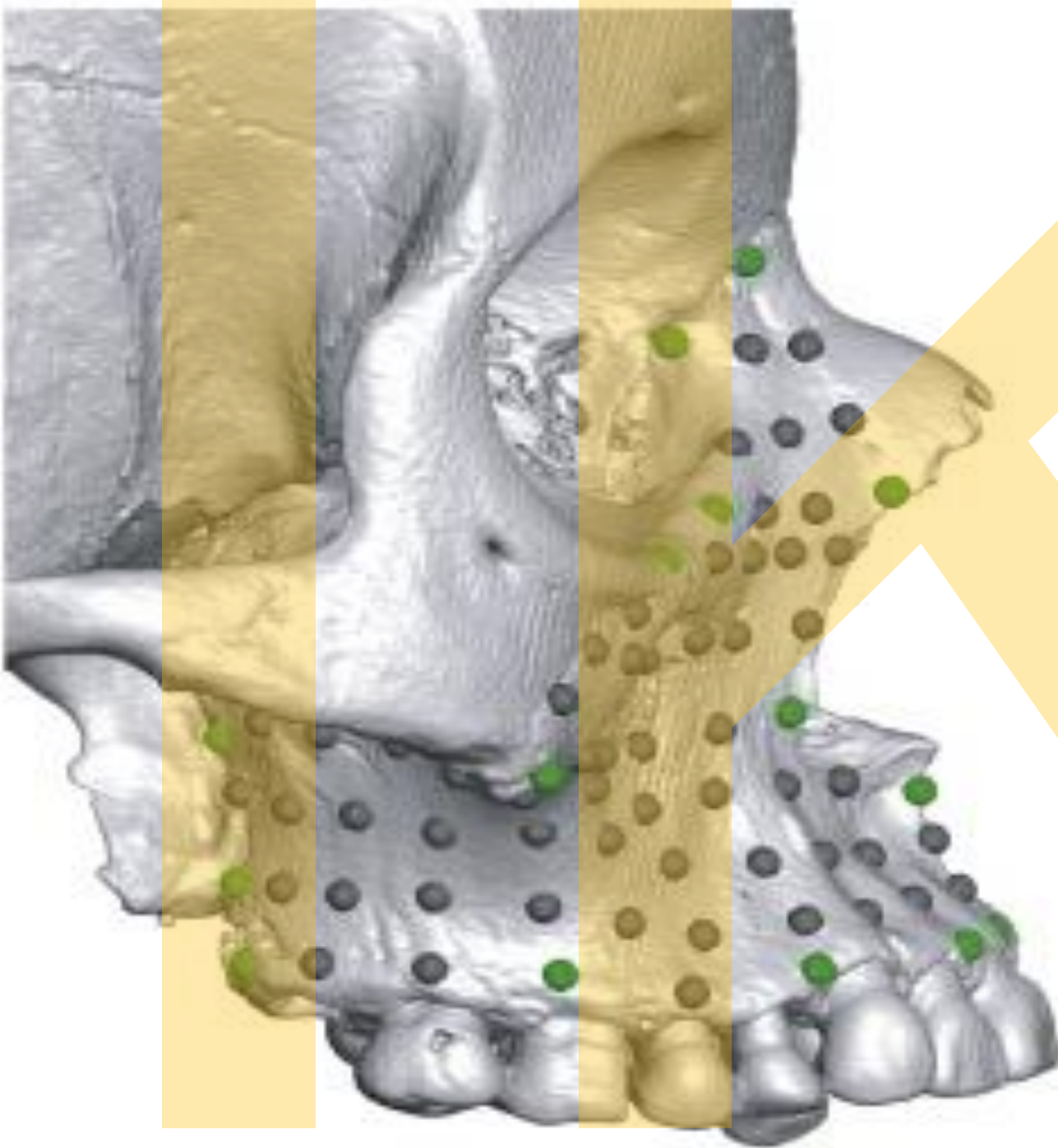
3. 7.T.F.

2. 7.T.F.

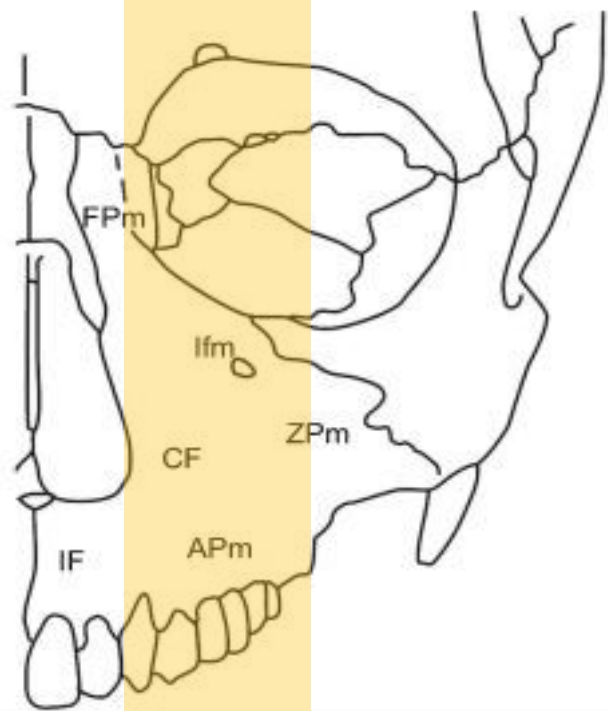


Svaly se neupínají do fossa canina !!



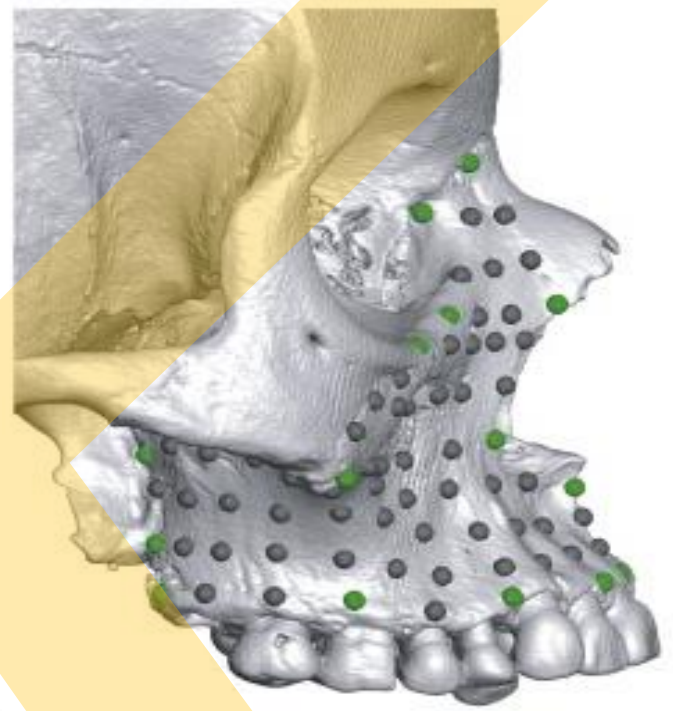


a) Anatomical regions analyzed



b) Geometric morphometric methods

landmarks
semilandmarks



c)

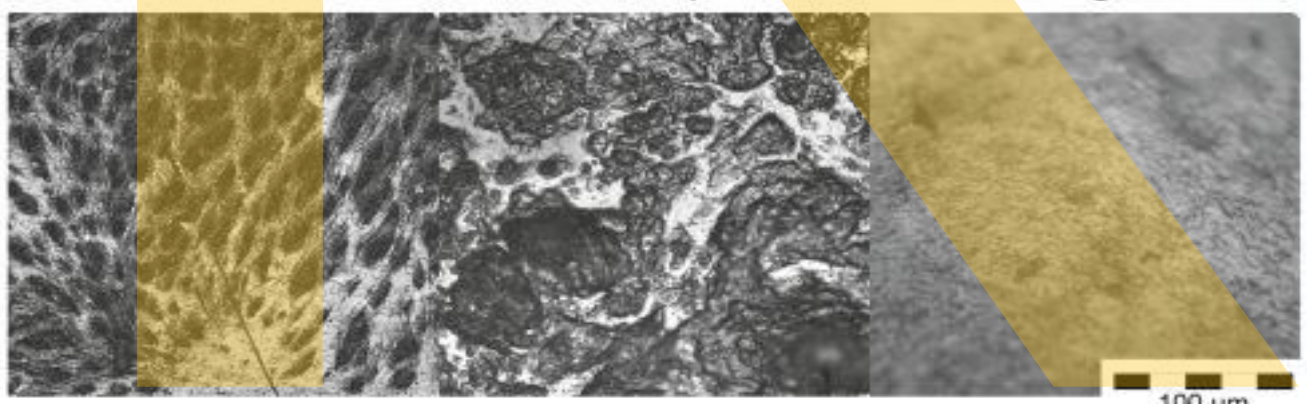

Histological record

Coated cast

Bone formation

Bone resorption

No histological data



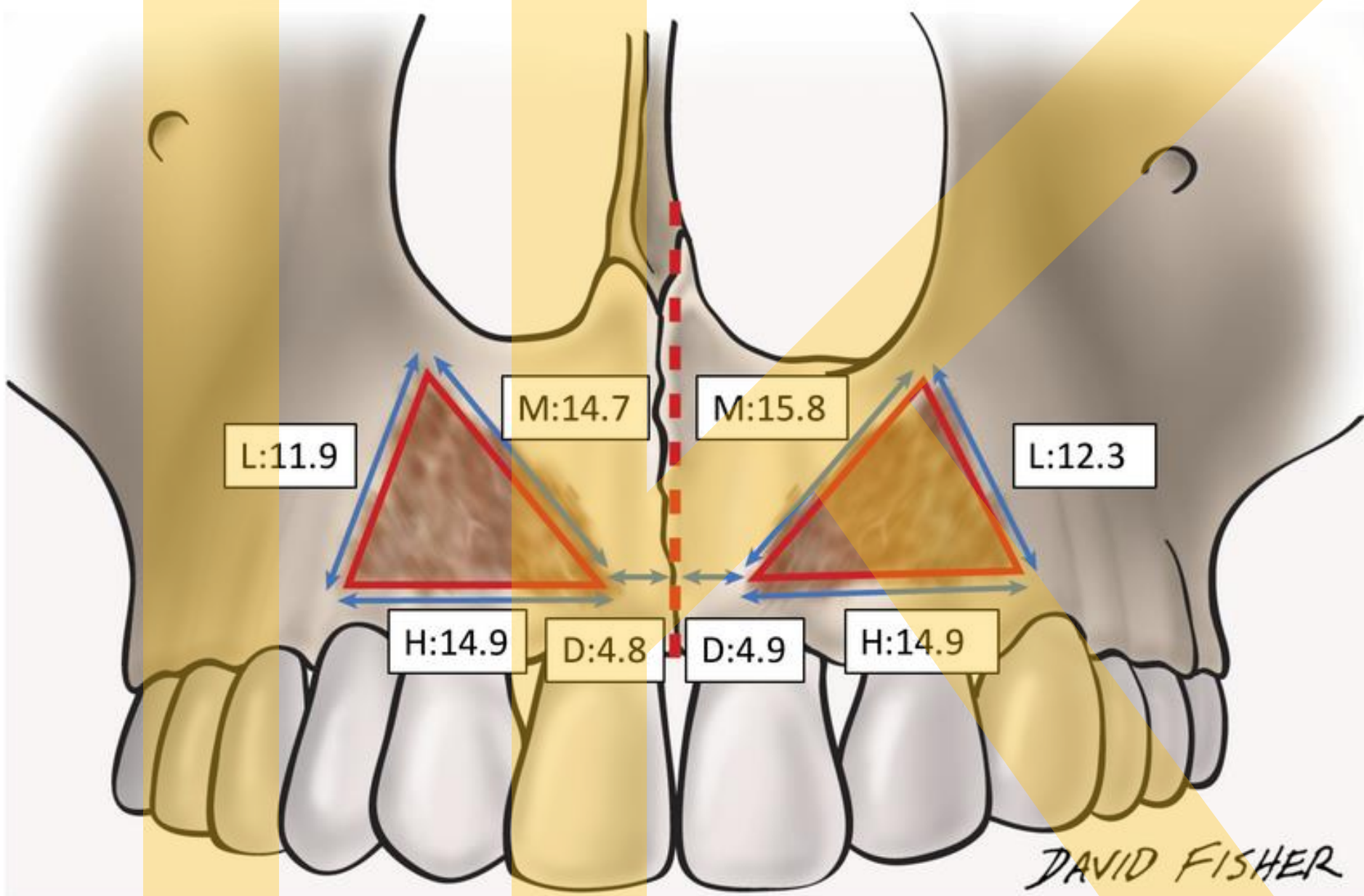
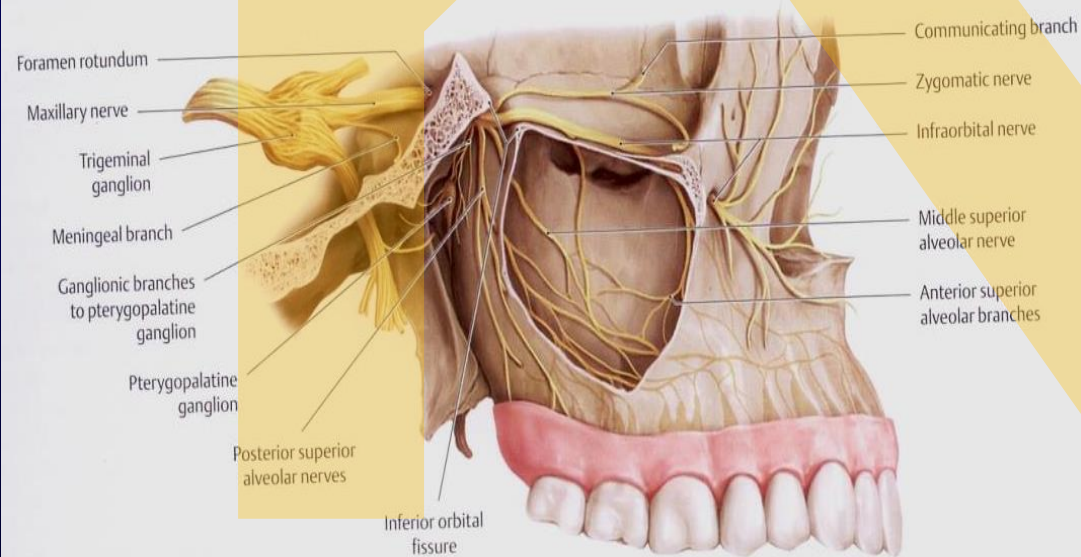
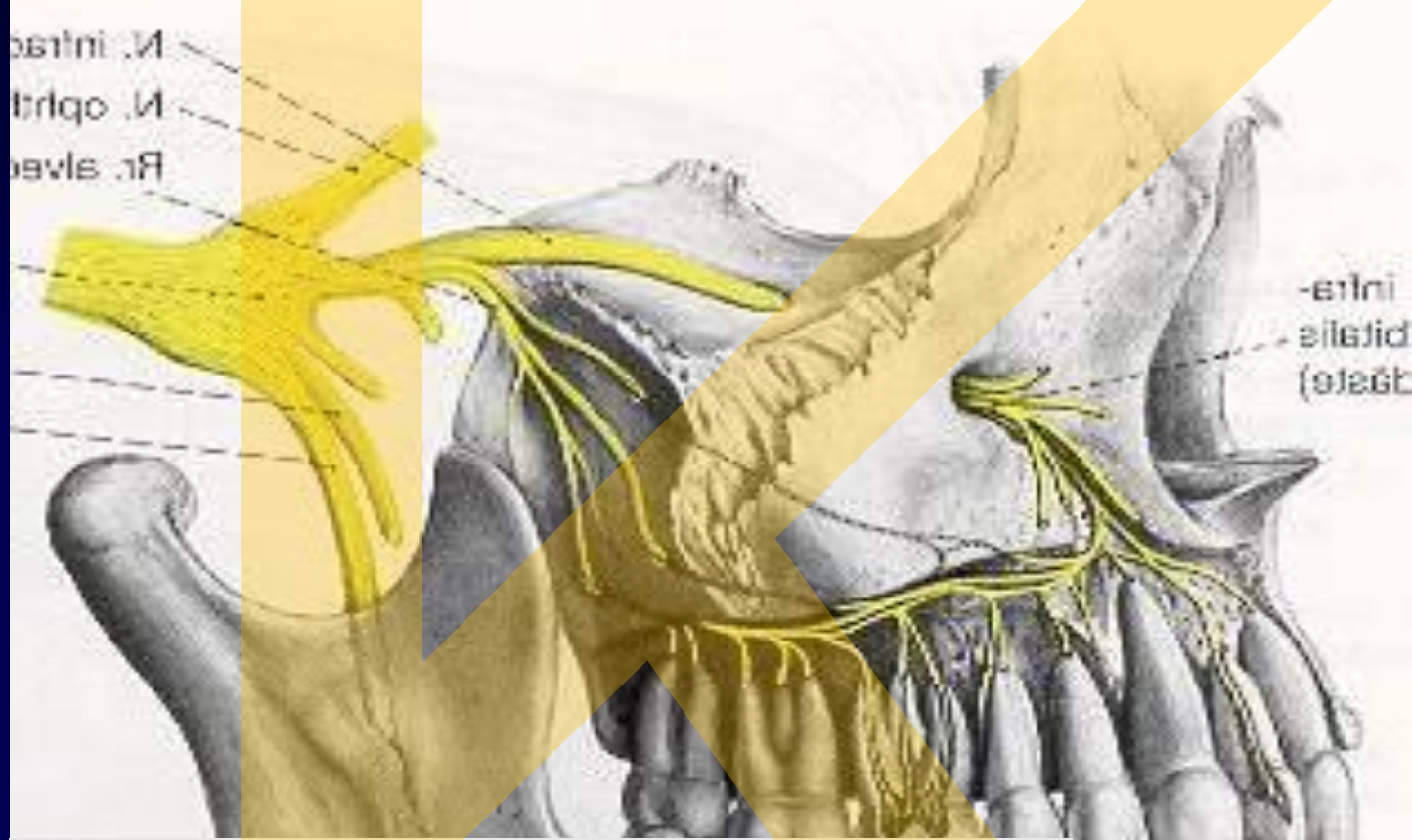

Figure 7: The measurement of the distance and circumference of the bony attachment. D: the distance from mid-line to innermost part of the bony attachment, H: length of horizontal part, L: length of lateral part, M: length of medial part (mm).

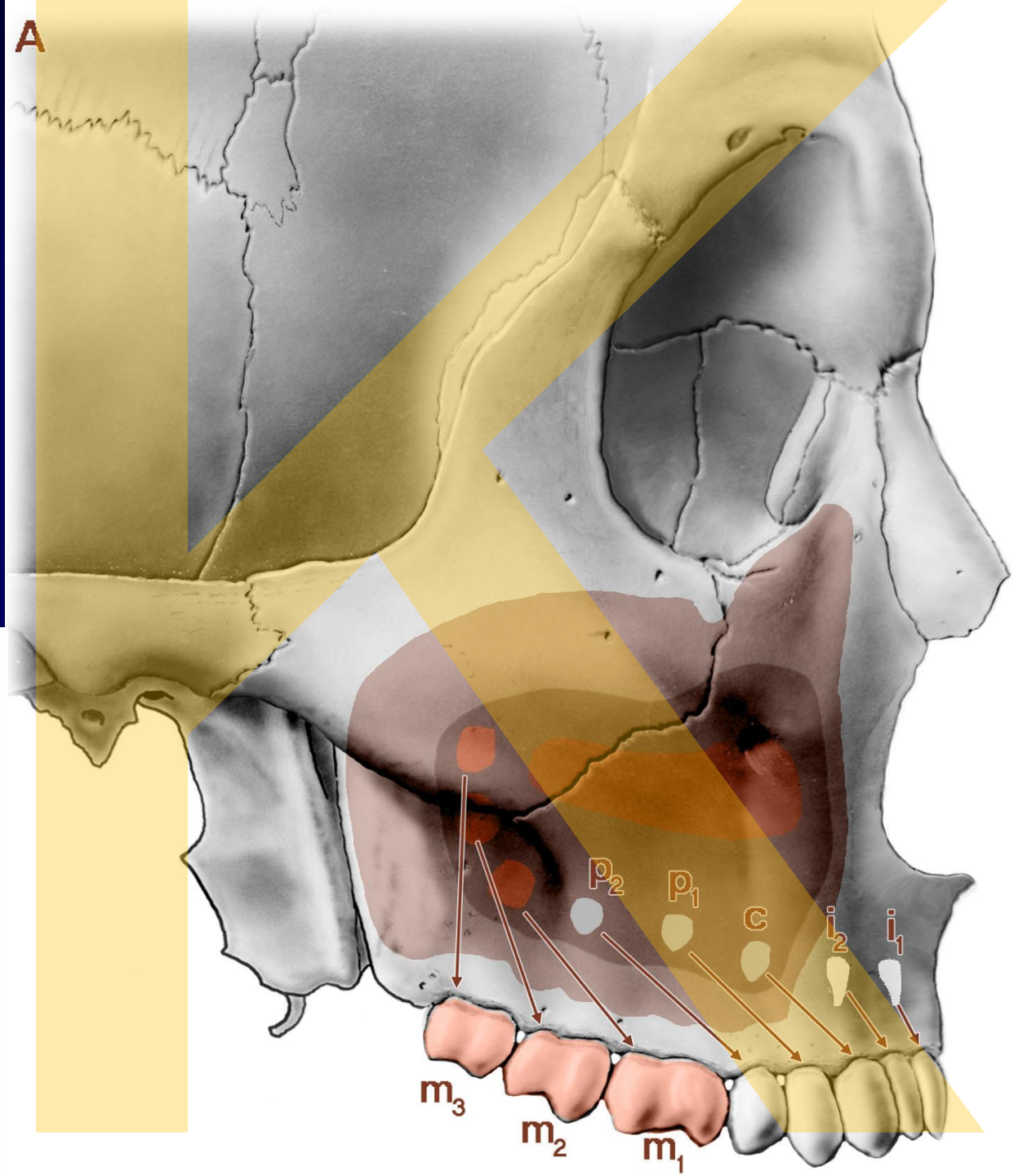
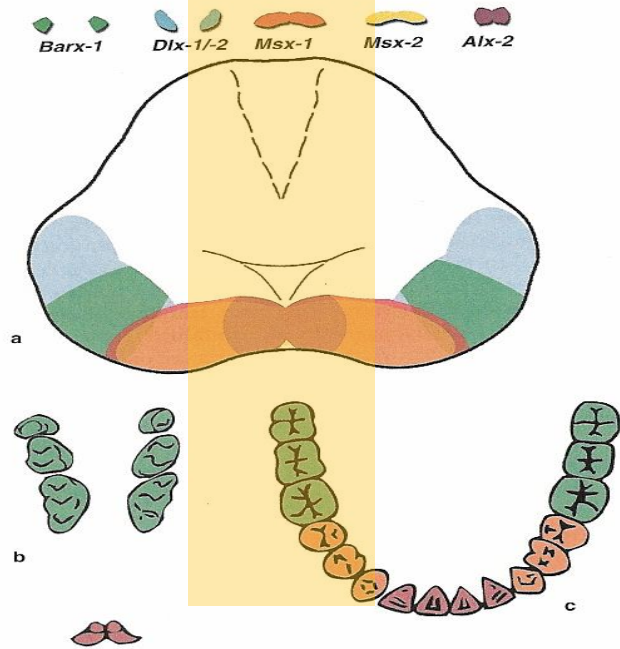
V₂

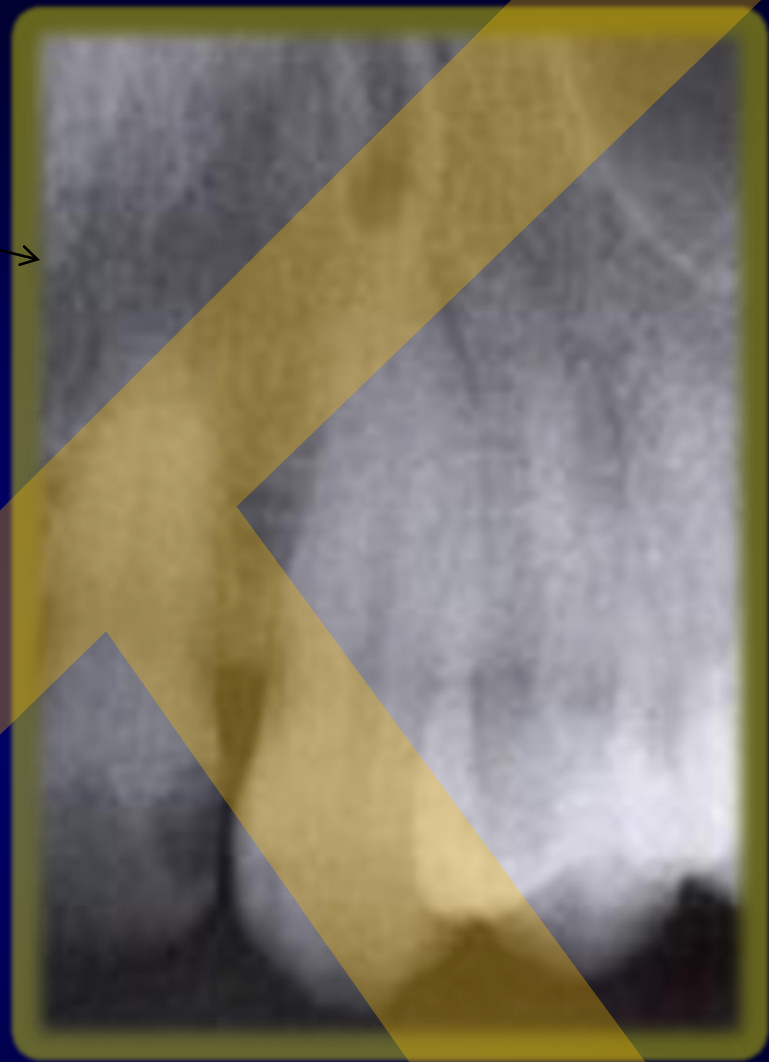
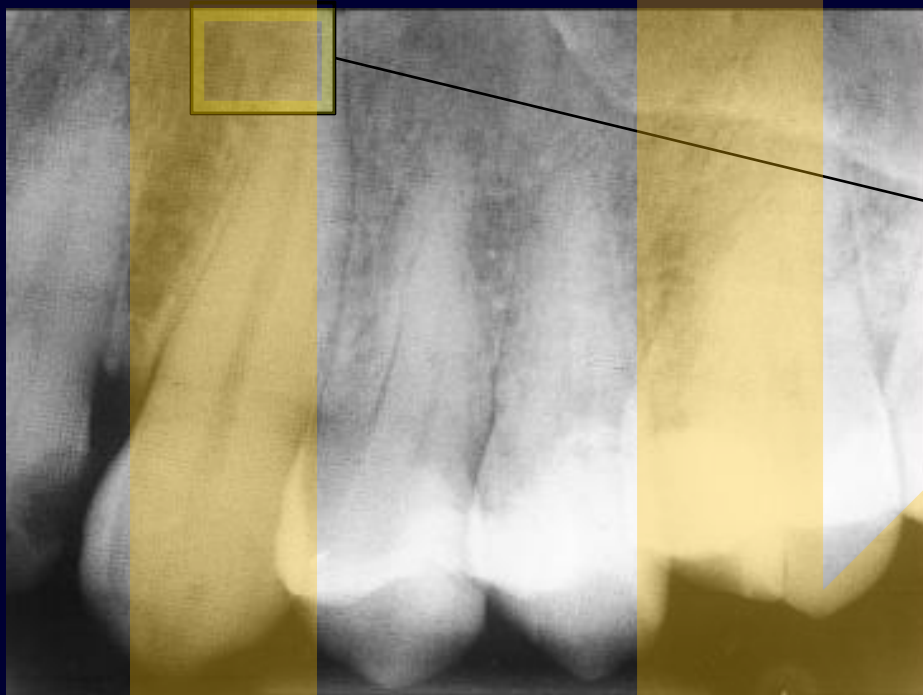


canalis sinuosus (Pardanaudi)

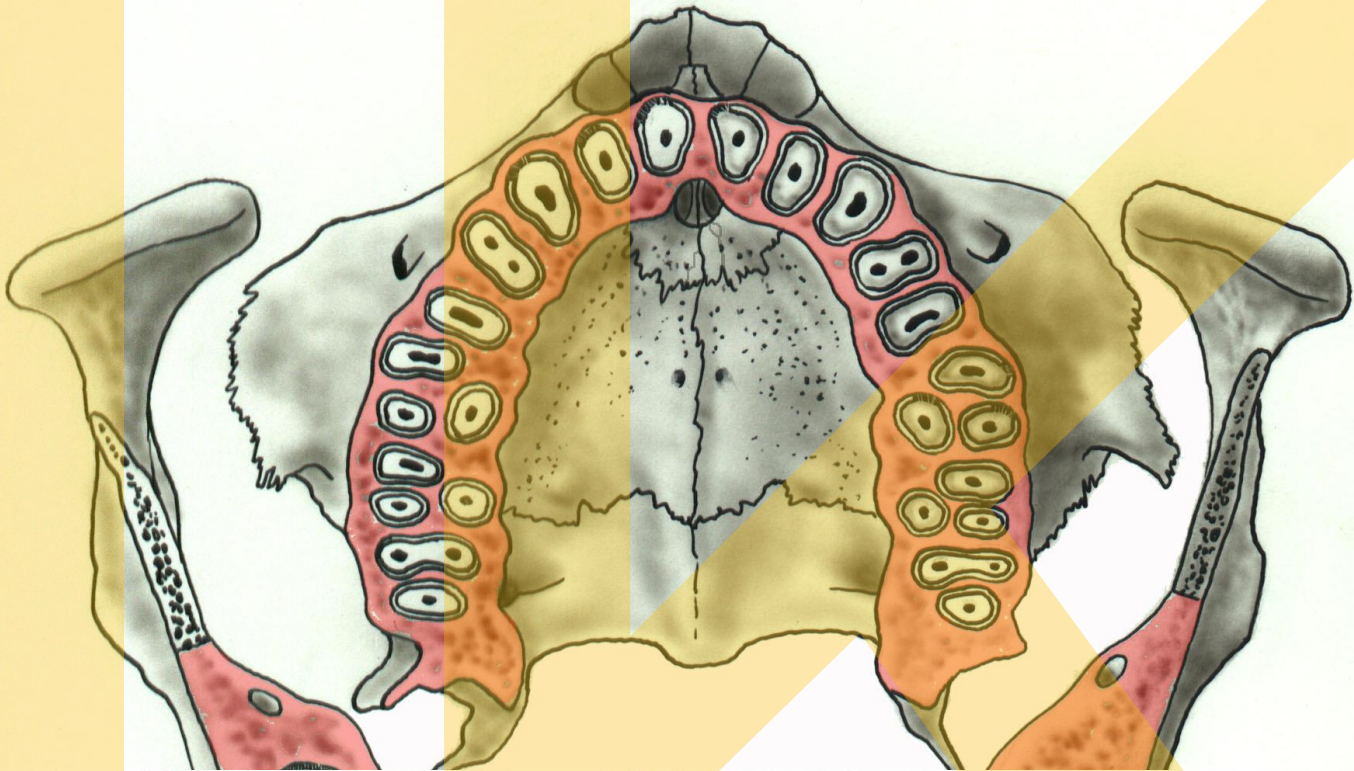
náhradní zuby
doplňkové zuby

'spare' teeth
complementary
teeth

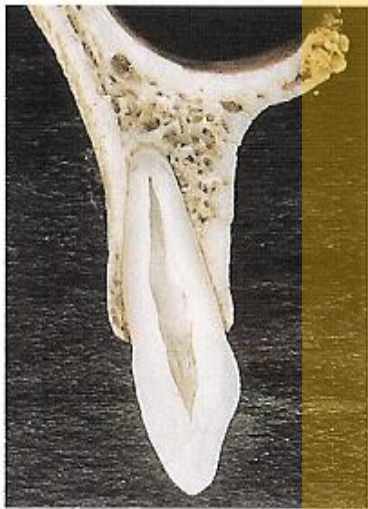



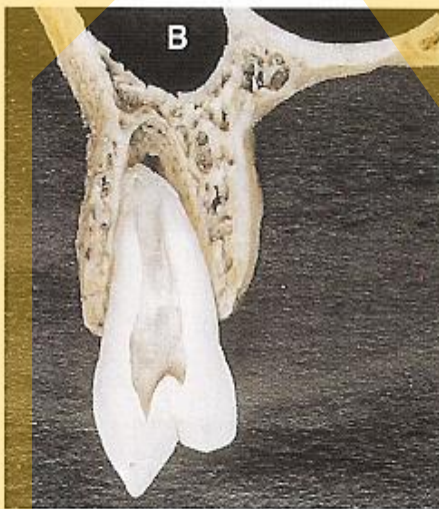
*A M Shelley, V E Rushton & K Horner:
Canalis sinuosus mimicking a periapical inflammatory lesion
British Dental Journal 186, 378 - 379 (1999) Published online: 24 April 1999*



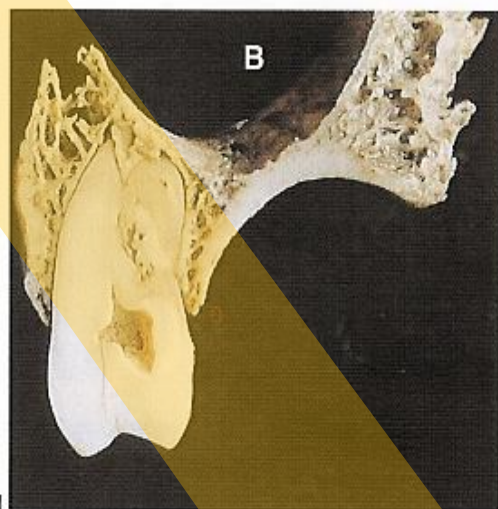
a



b



c



d

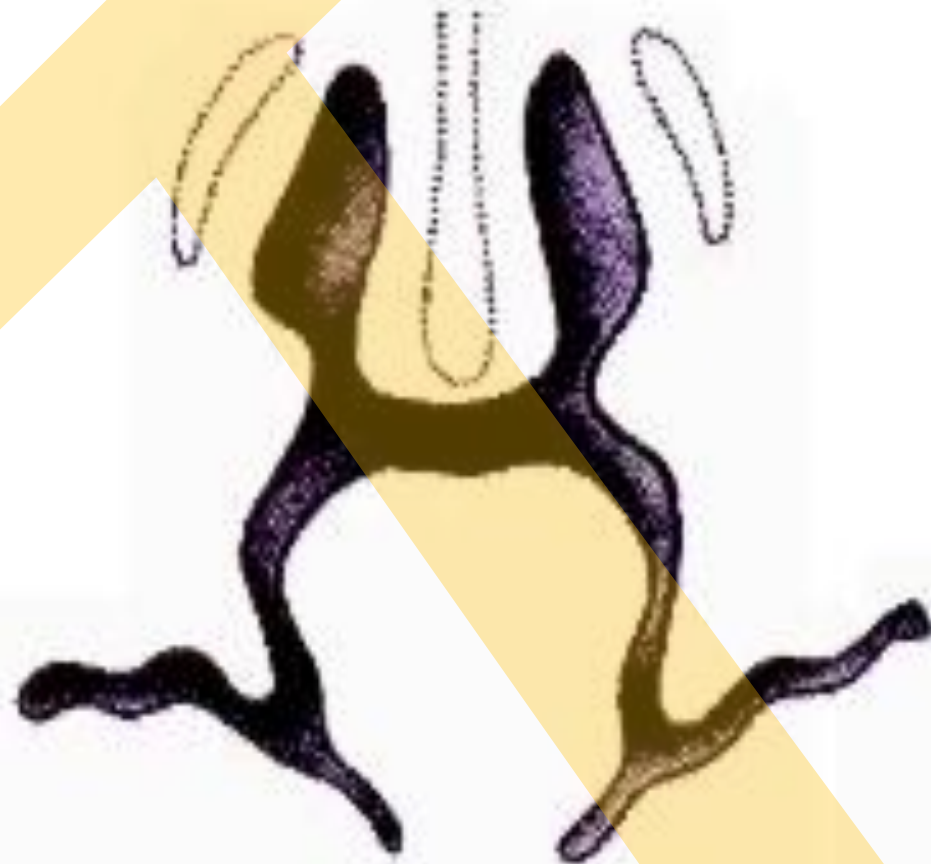
Utváření sekundárního patra

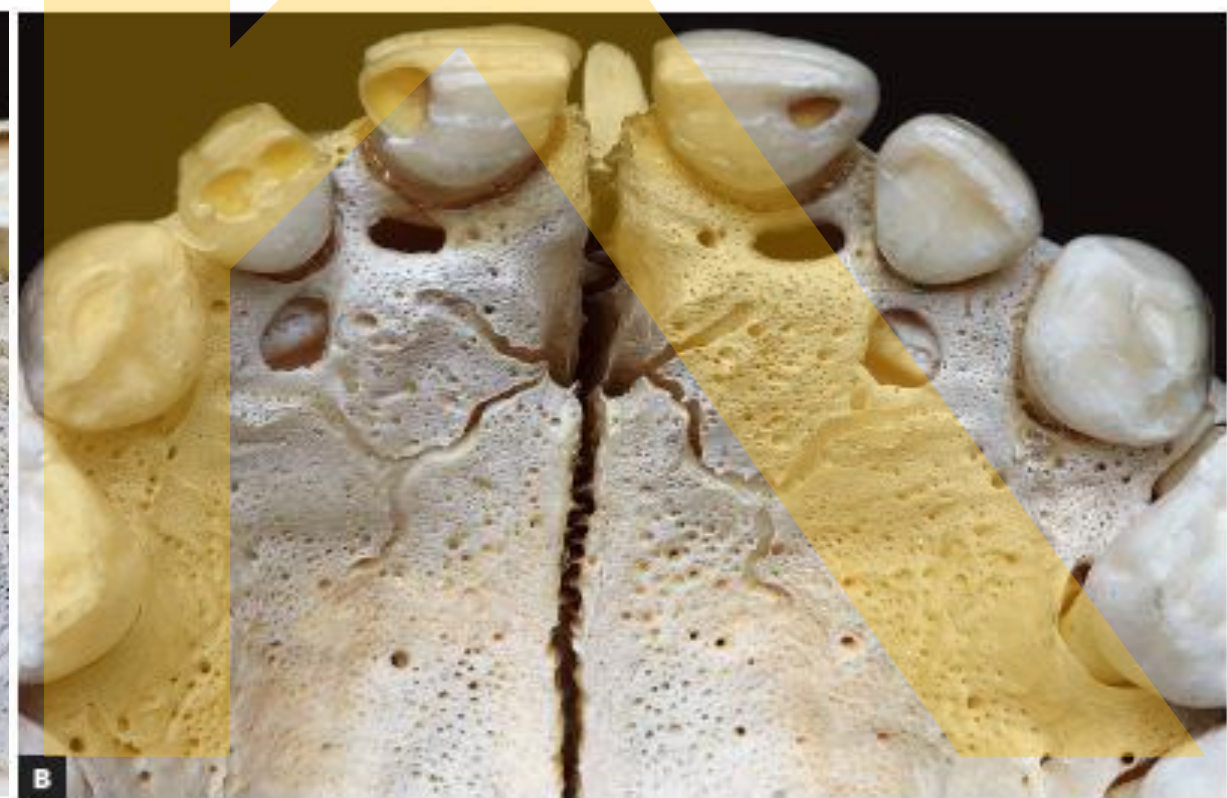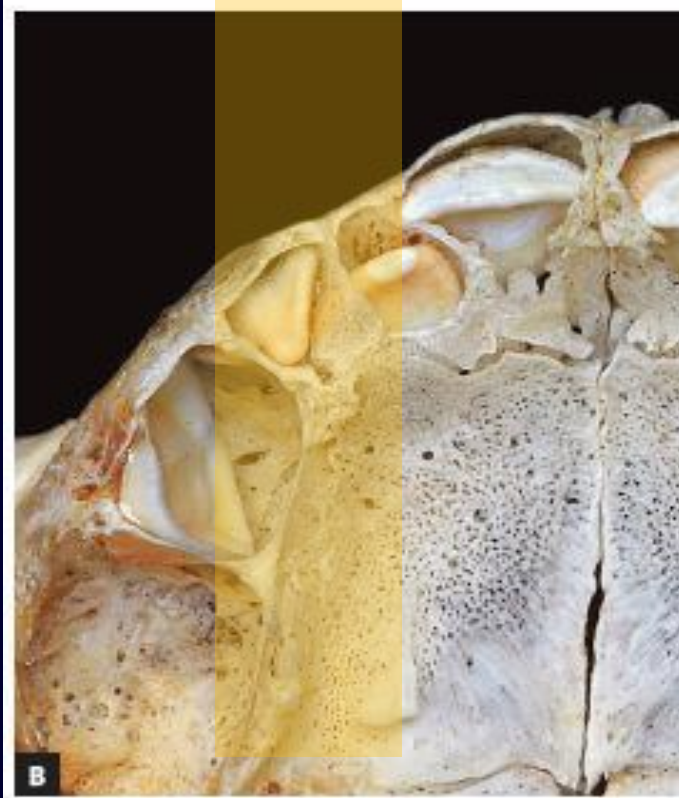
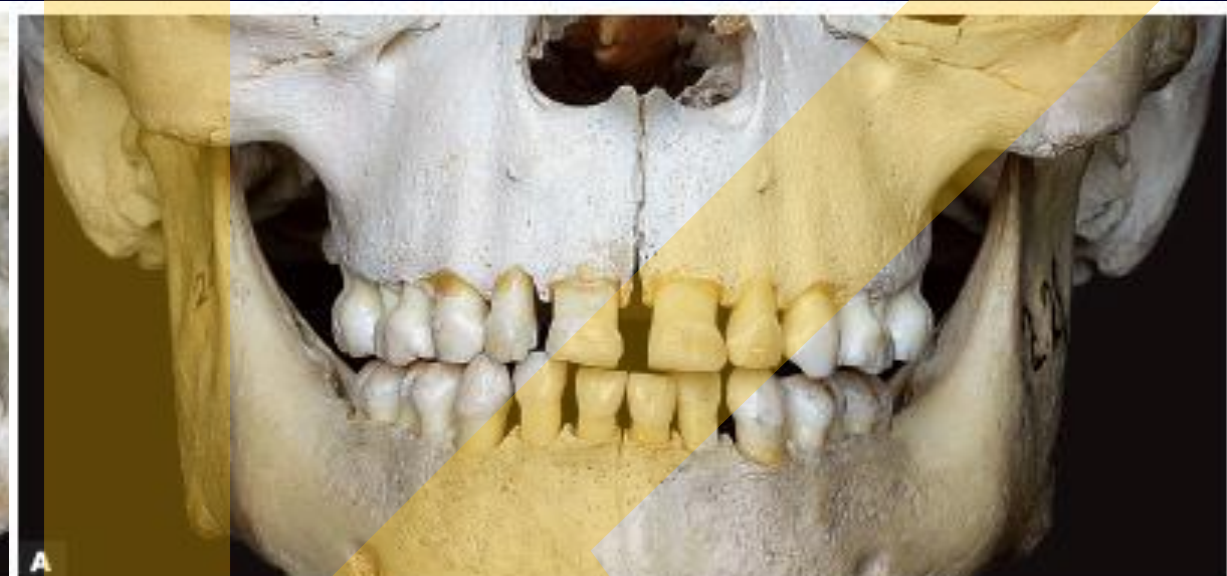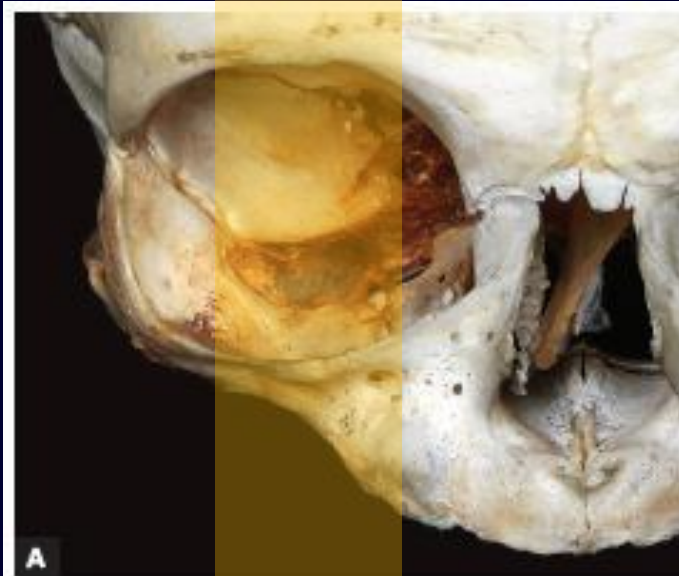6.5-week-old embryo.

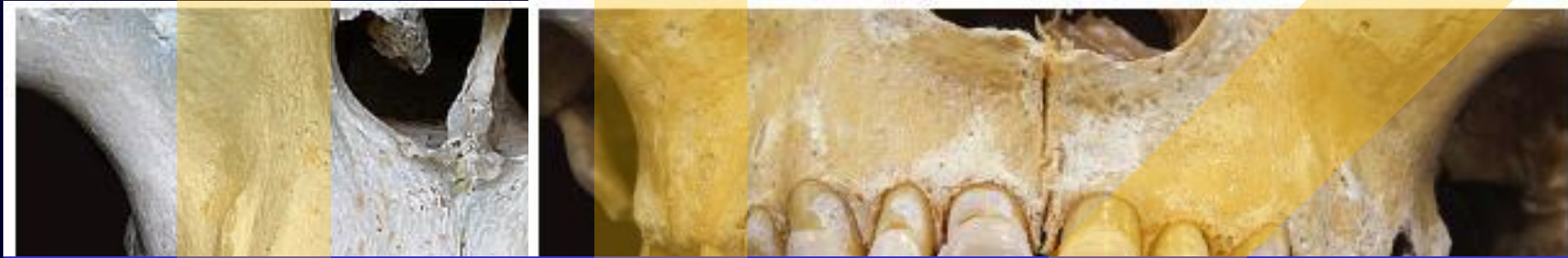The palatine shelves are in the vertical position on each side of the tongue.

The shelves have elevated, but they are widely separated.

The primary palate has fused with the secondary palatal shelves.

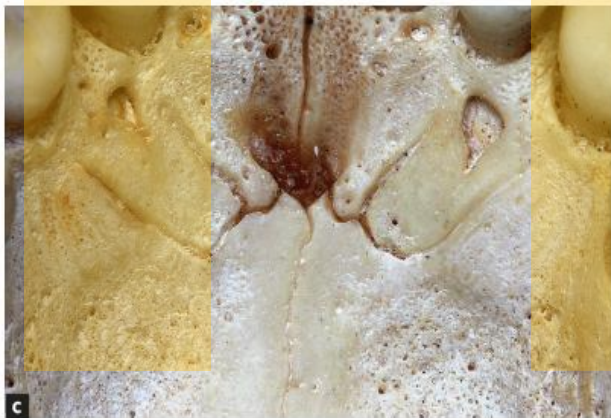
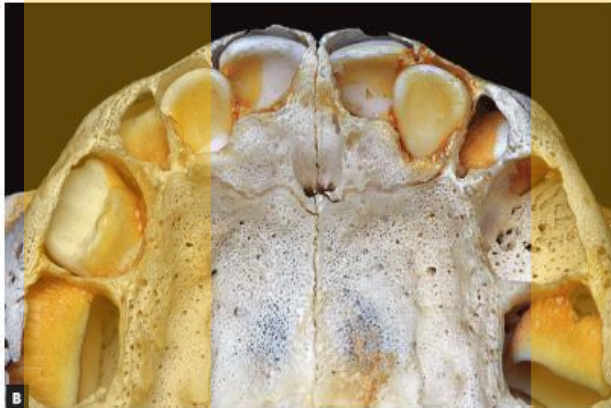
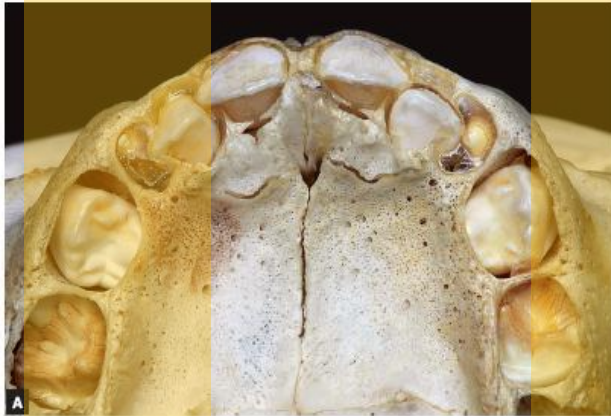

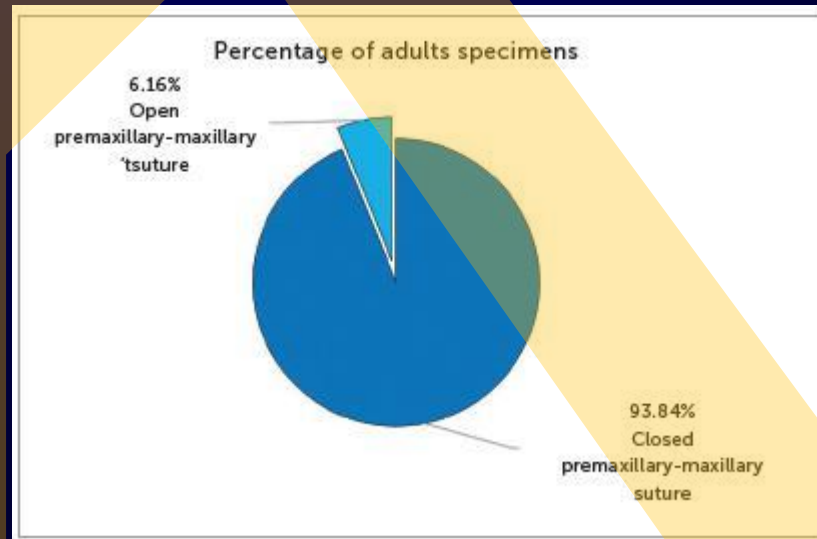


To determine the percentage of opening of the premaxillary-maxillary suture, two observers independently identified the side on which the suture had the longest opening and traced a straight line from the incisive foramen to the middle point between the maxillary lateral incisor and the maxillary canine in the palatal region. The end of the suture was projected orthographically onto this straight line, and the percentage of opening was calculated according to the ratio between the length of the open segment projection and the total segment length. The evaluation of suture opening percentage considered that 100% open were those sutures that reached the end of the straight line, and 0%, those that did not extend from the incisive foramen, as shown in





Morphological patterns of premaxillary-maxillary suture in children, with irregular shapes that are simple or complex, but always greatly variable.



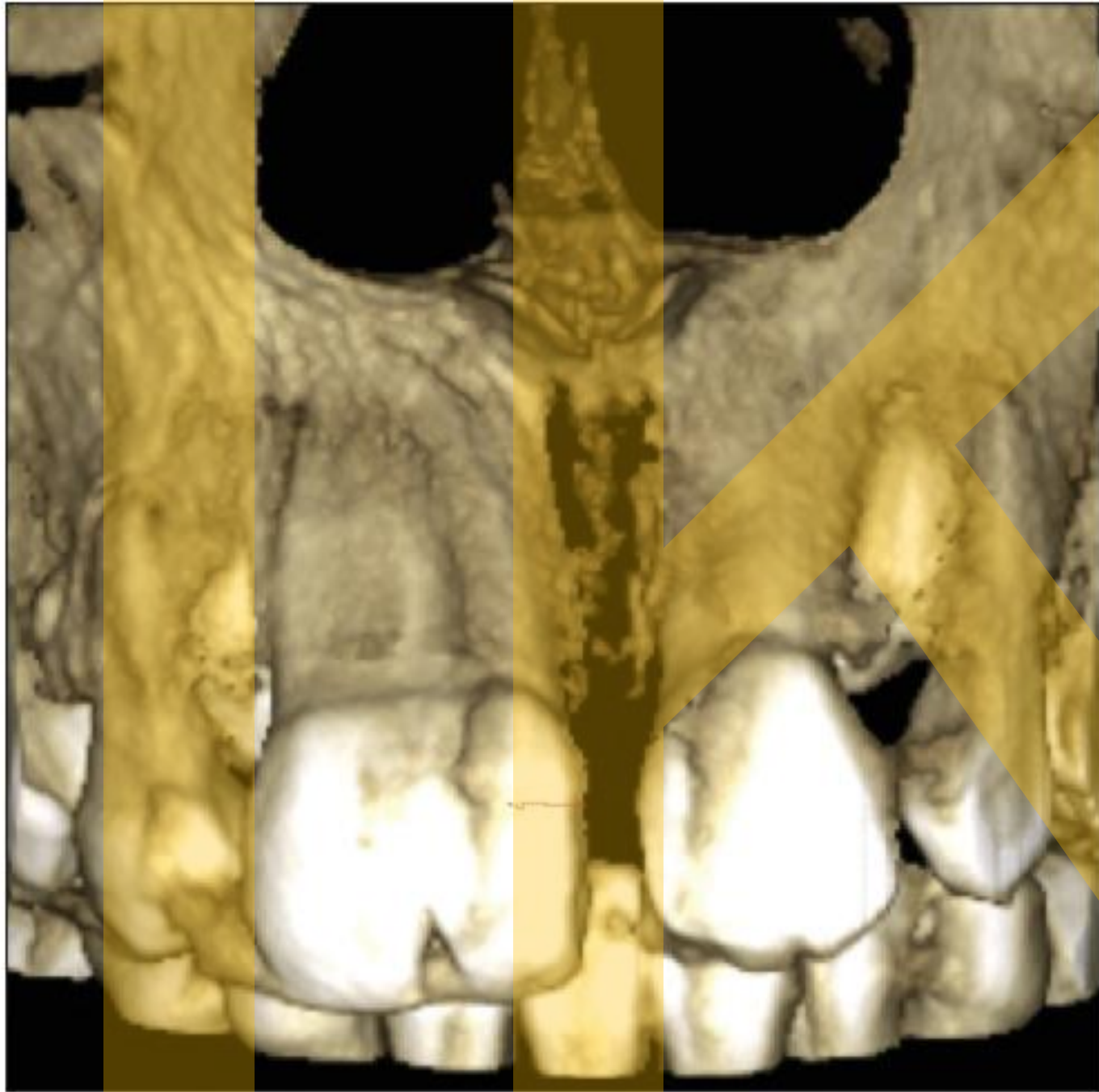
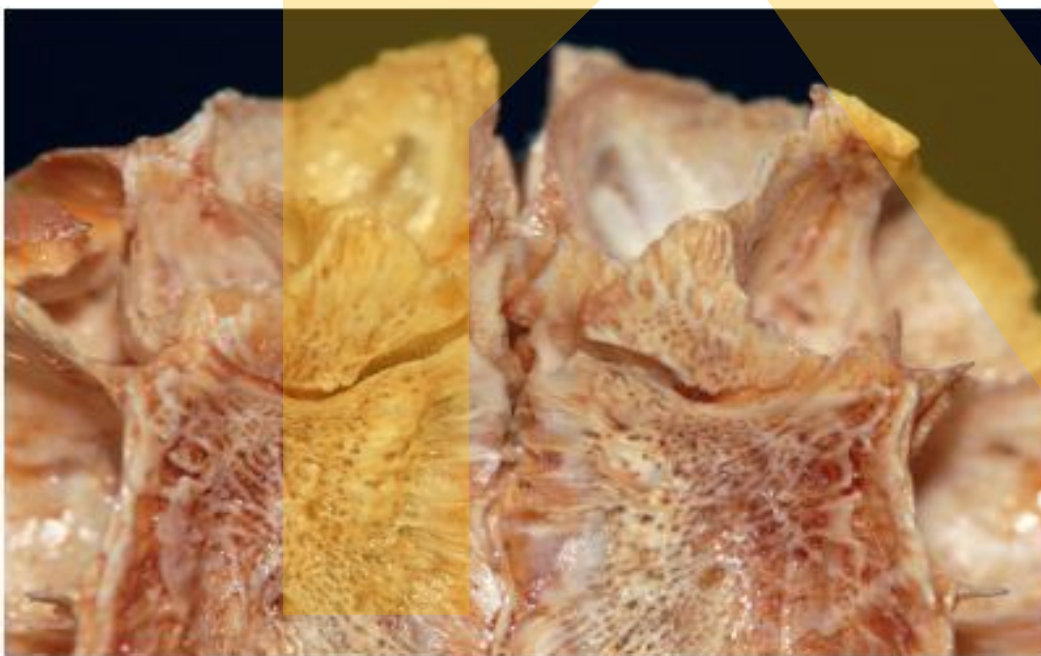
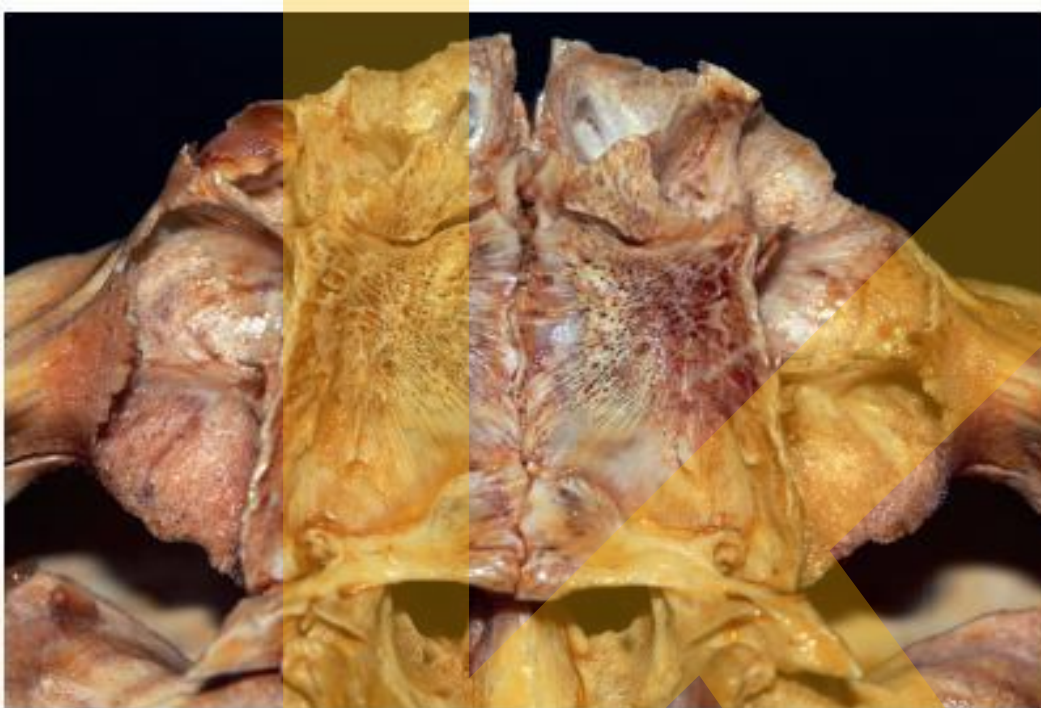
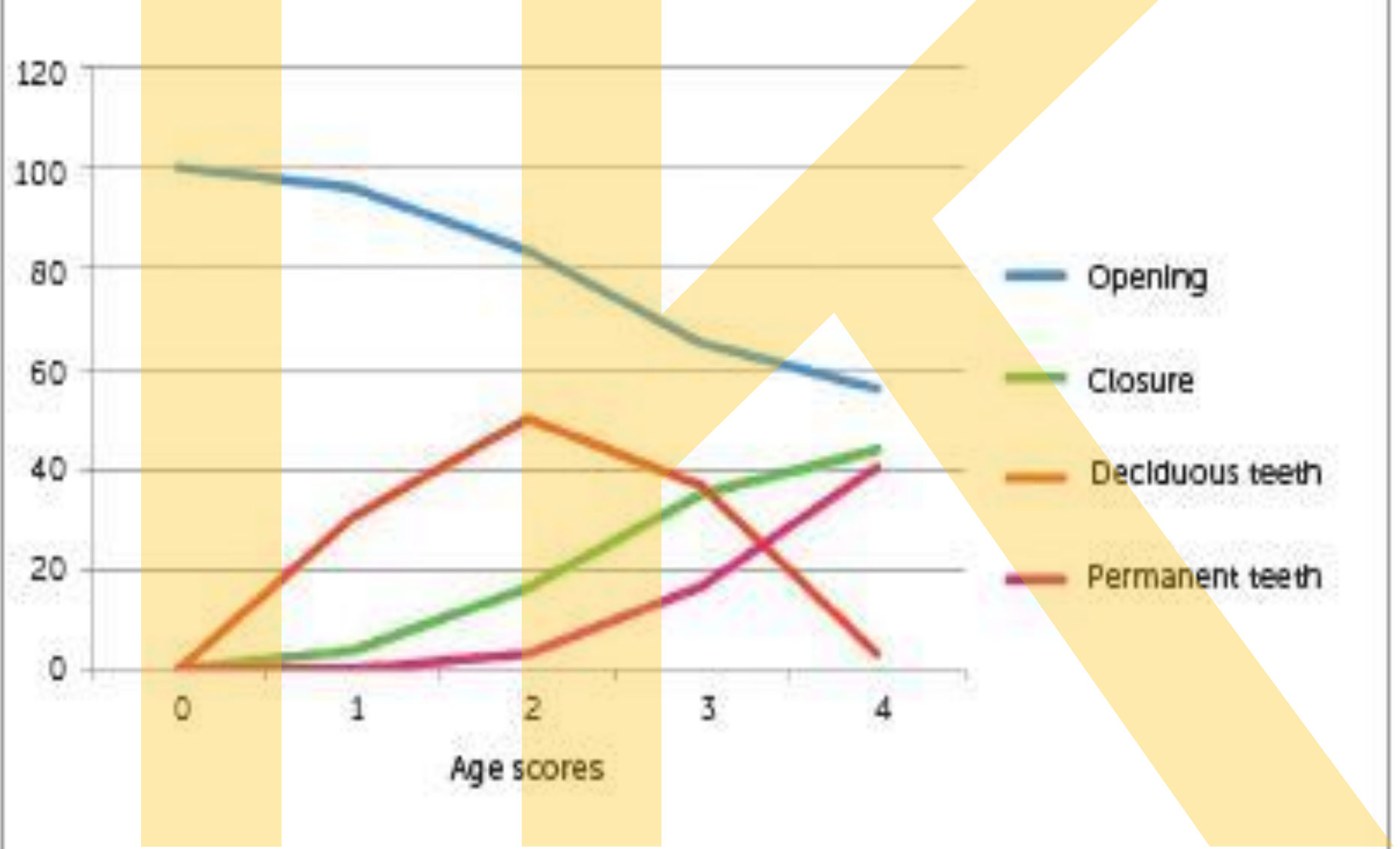
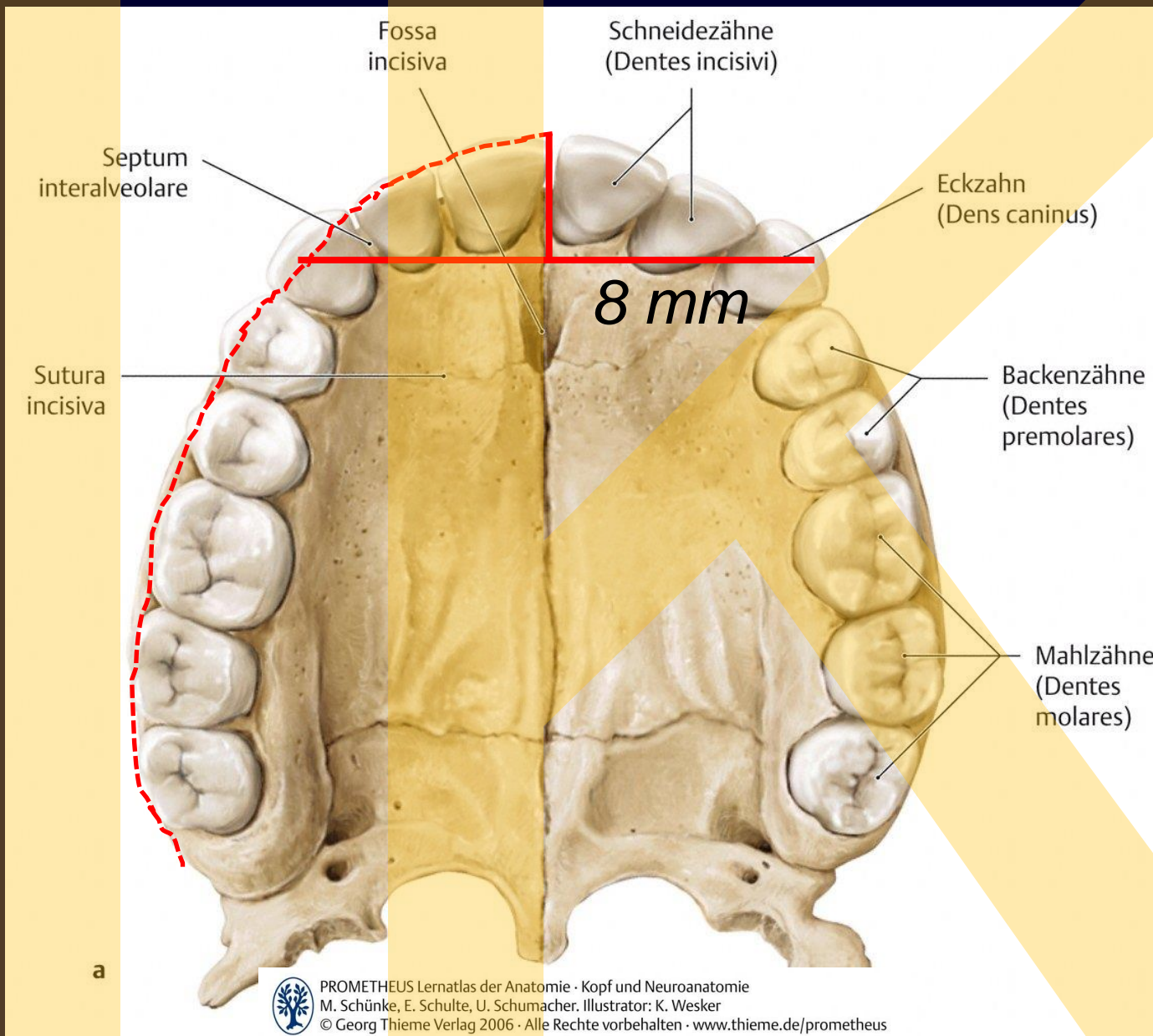


Figure 4: Cone-beam computed tomography with three-dimens



Percentage of premaxillary-maxillary suture opening and closure in deciduous and permanent teeth





Hrbolková linie
 Tubercular line

Vzdálenost od řezákového bodu ke spojenci mezi hroty špičáků
 Distance between incisale point and line connecting tops of canini

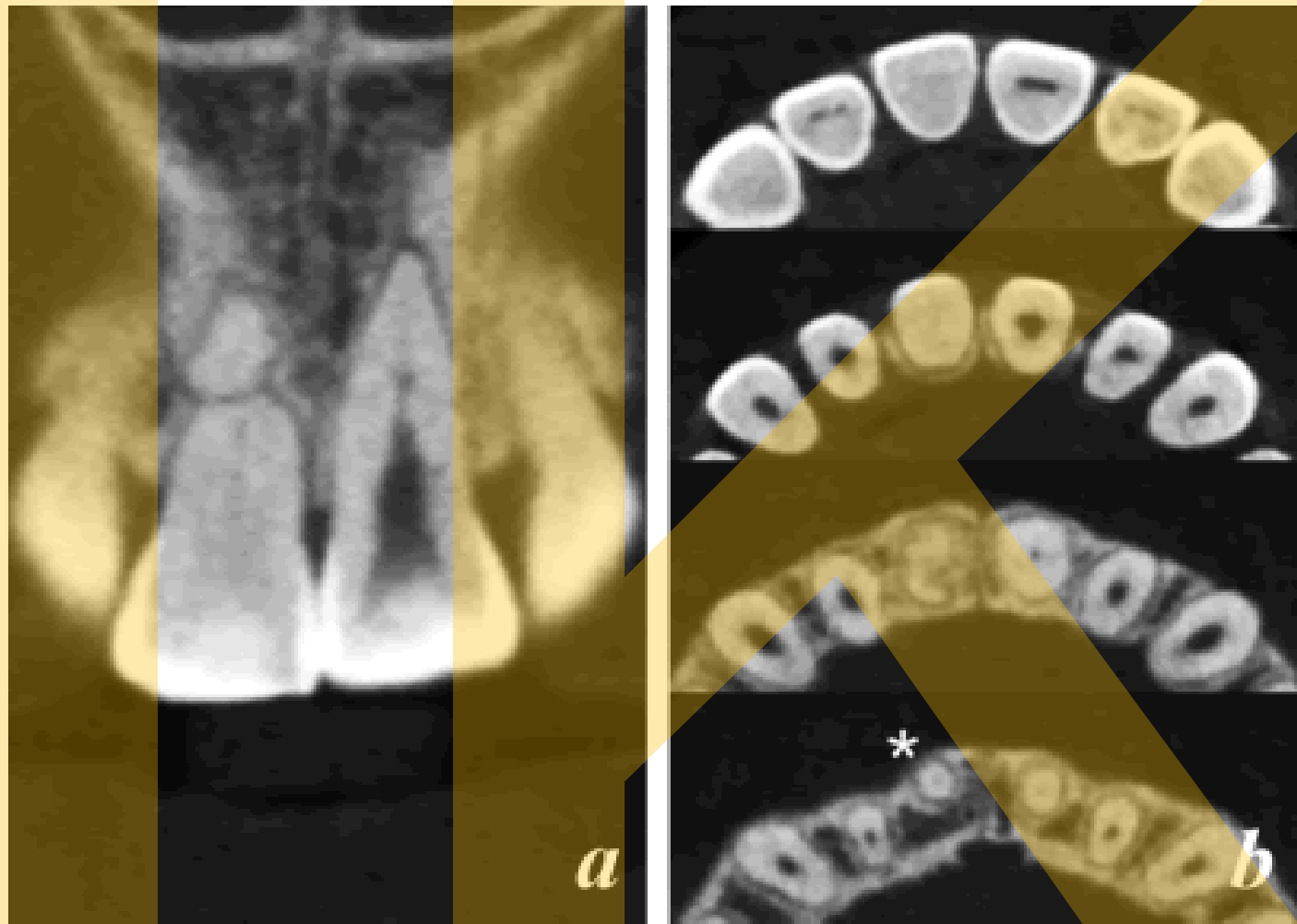
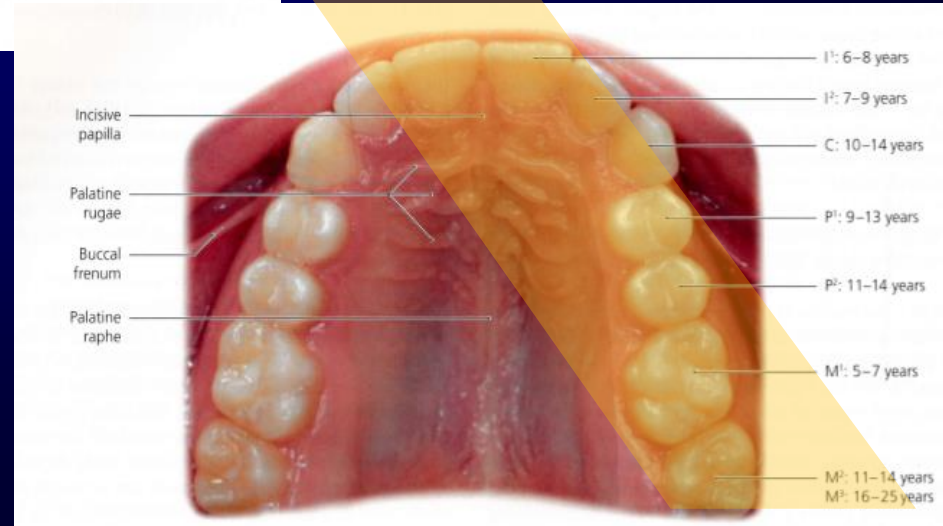
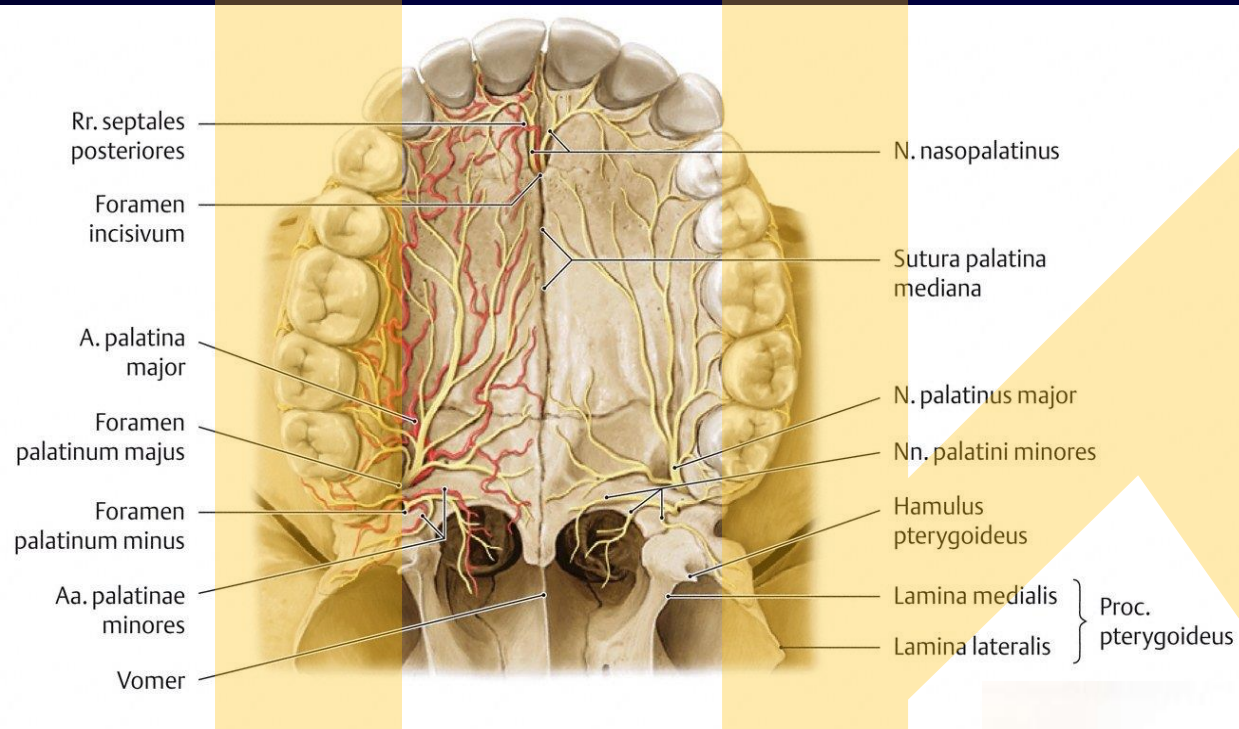
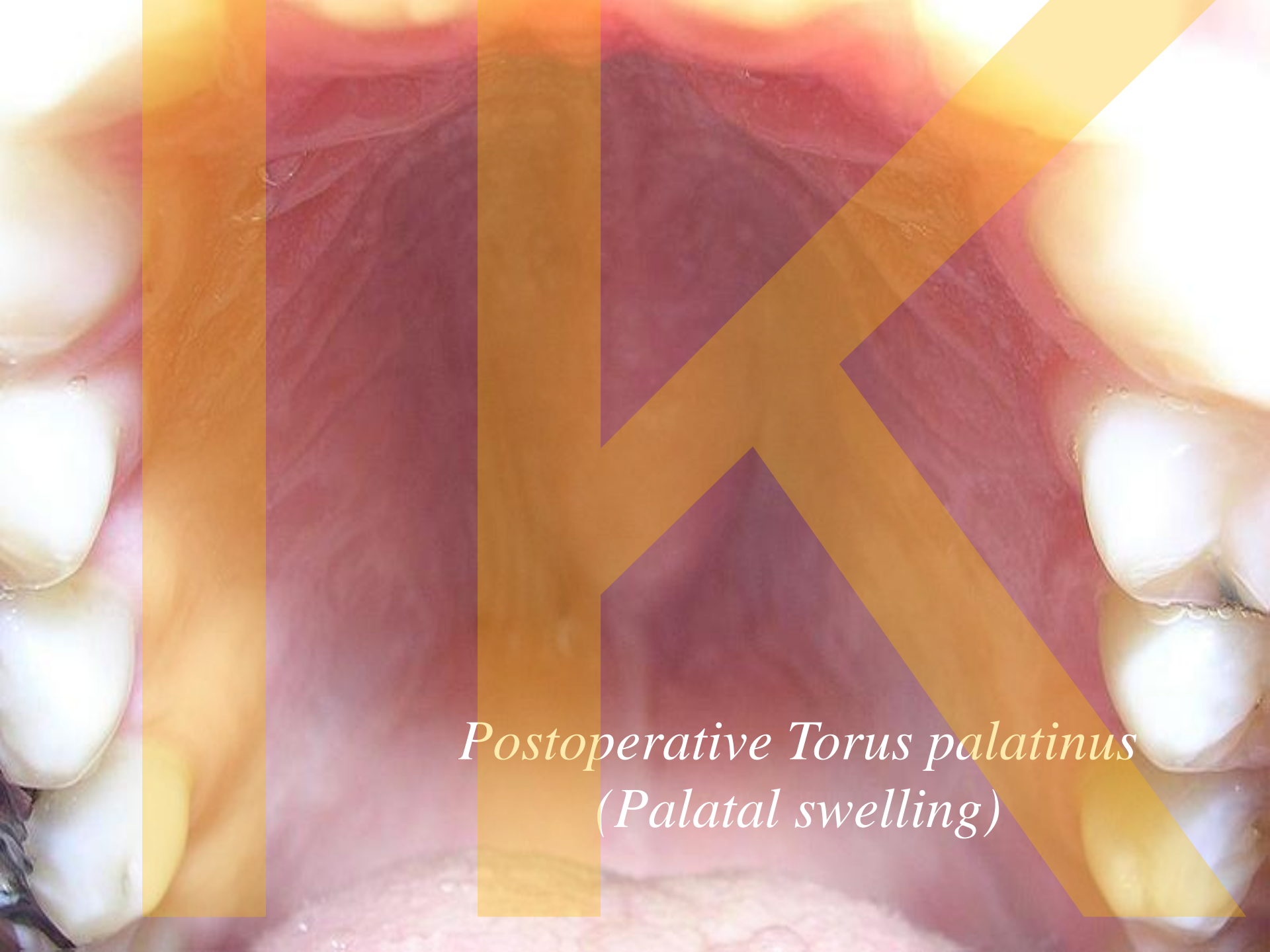

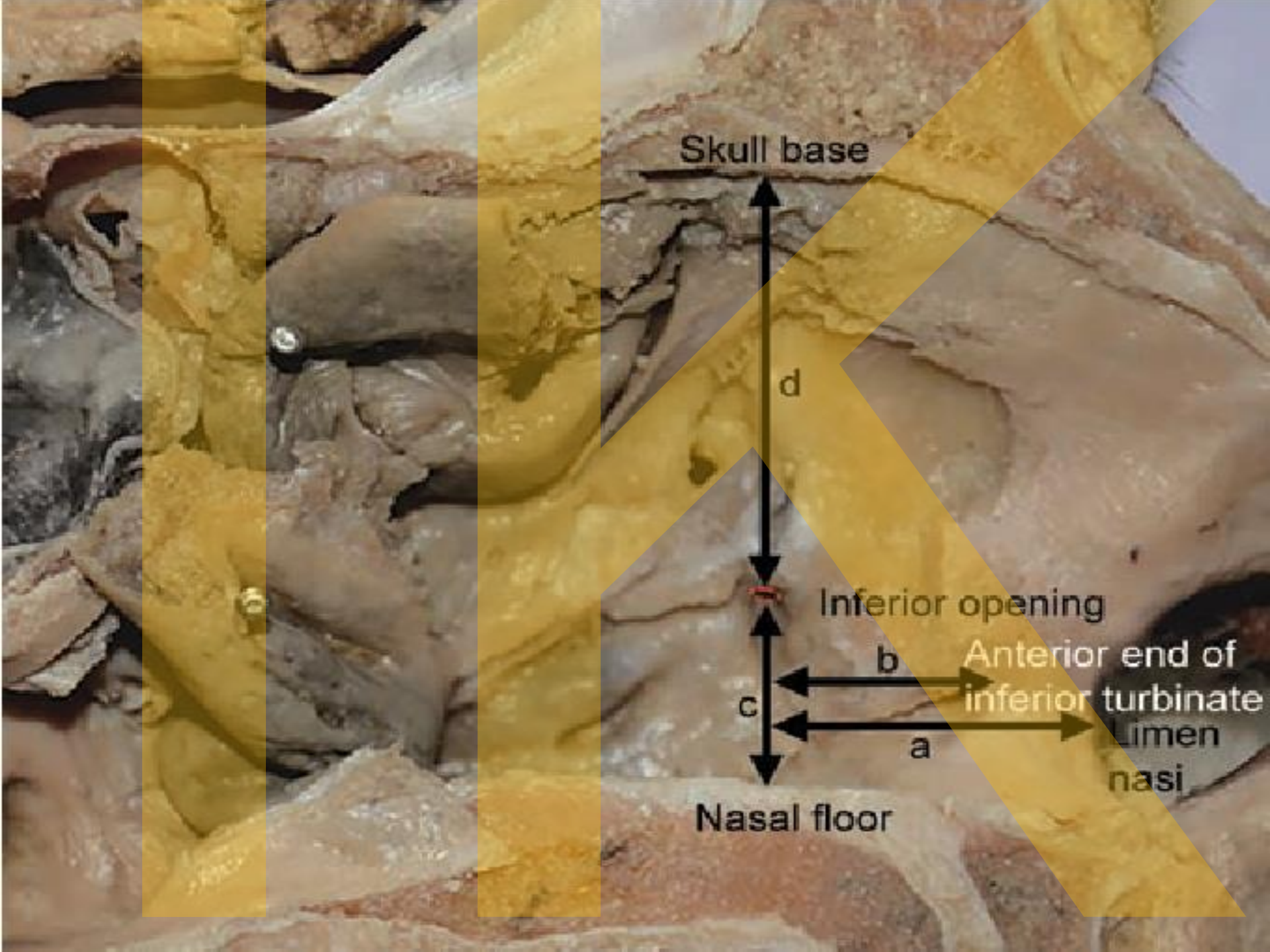
Figure 3. (a) CBCT in a coronal view of tooth 11 and 21; (b) Axial images from multi-slice CBCT. Note the different degrees of obliteration with total PCO and stenosis of tooth 8 and partial PCO of tooth 21. Tooth 11 showed a minimal presence of a canal in the last axial view ().*

Sulcus palatinus major; its content





*Postoperative Torus palatinus
(Palatal swelling)*



Skull base

d

Inferior opening

b

Anterior end of inferior turbinate

c

a

Limen nasi

Nasal floor

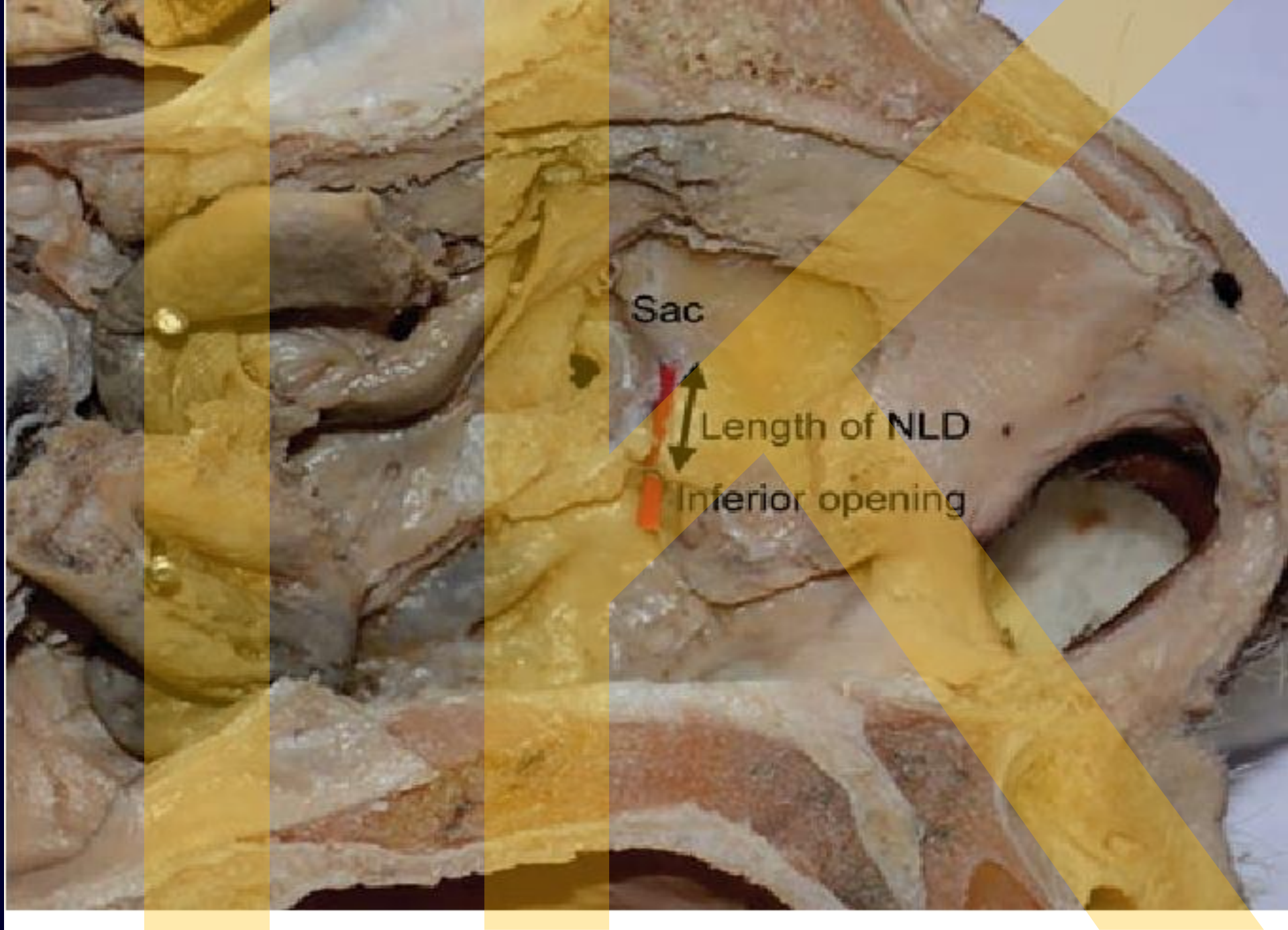


Fig. 3: Length of NLD

Růst maxily

*Podél osy procházející intraalveolárním septem
mezi lateral dočasným řezákem a špičákem
(„opening bridge“)*

ventrokaudálně

Vliv sutur frontomaxillaris, zygomaticomaxillaris, pterygopalatina

Vliv sutur incisiva et intermaxillaris

kaudálně

septum nasi

Vliv na okolní struktury

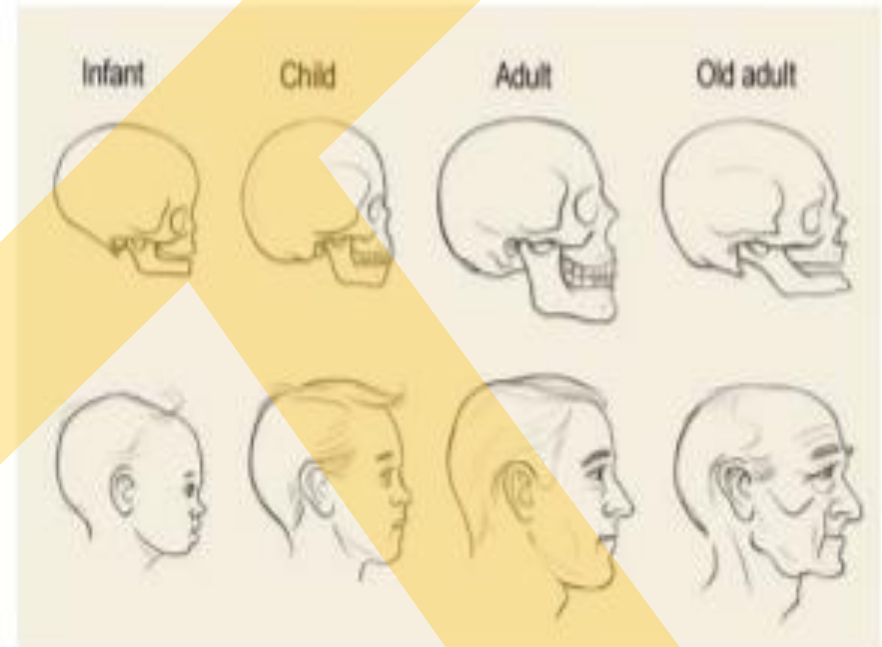
postnatálně

sutura palatina mediana (7-19 rok roste o cca 5 mm)

Age changes of the maxilla

➤ At birth:

- I. The **transverse** and **antero-posterior** diameters of the bone are **much greater** than the **vertical**.
- II. The **frontal process** is well-marked and the **body** of the bone consists of **little more than the alveolar process**.
- III. The **teeth sockets** reaching almost to **the floor of the orbit**.
- IV. The **maxillary sinus** presents the appearance of a **furrow** on the lateral wall of the nose

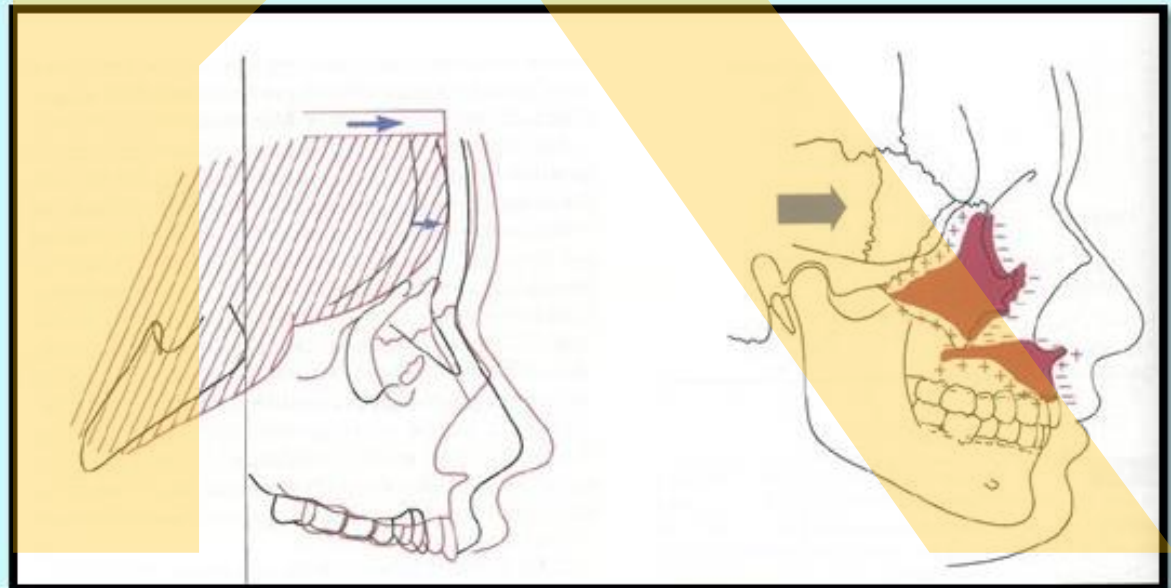


Růst nasomaxilárního komplexu

Growth of the nasomaxillary complex

- Growth of this area produced by two basic mechanisms
- (1) Passive **displacement**, created by growth in the cranial base that pushes the maxilla forward, and (2) **active growth** of the maxillary structures and nose

Diagrammatic representation of a major mechanism for growth of the maxilla



Tuber maxillae maxillar tuberosity

- Established by the posterior limit of anterior cranial base .

TF

- De

RO

- Er

sii

1) Bone deposition occurs along the posterior margin of the maxillary tuberosity.

This causes lengthening of the dental arch and enlargement of the antero- posterior dimension of the entire maxillary body.

- Al

This helps to accommodate the erupting molars.

- =

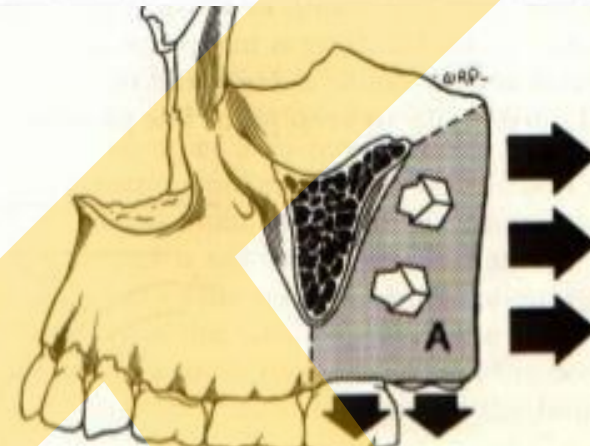
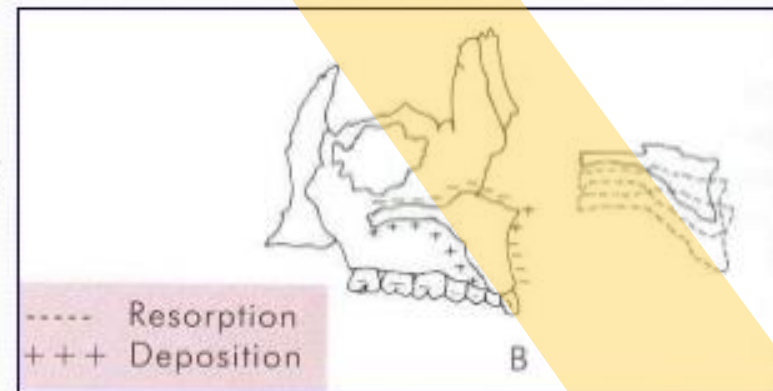


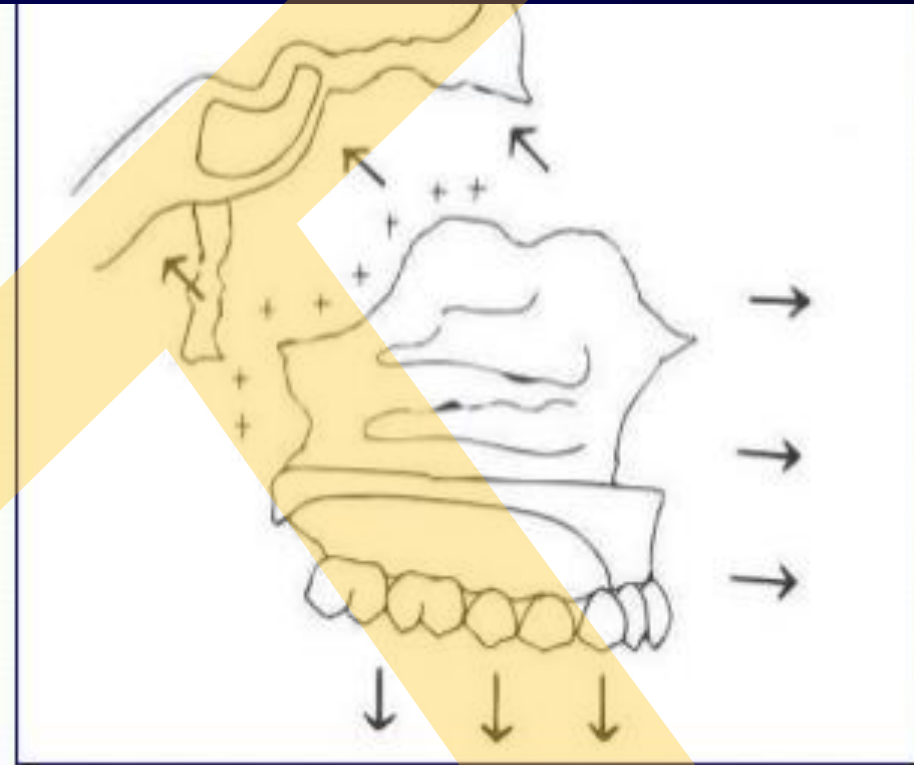
FIGURE 3-87



76

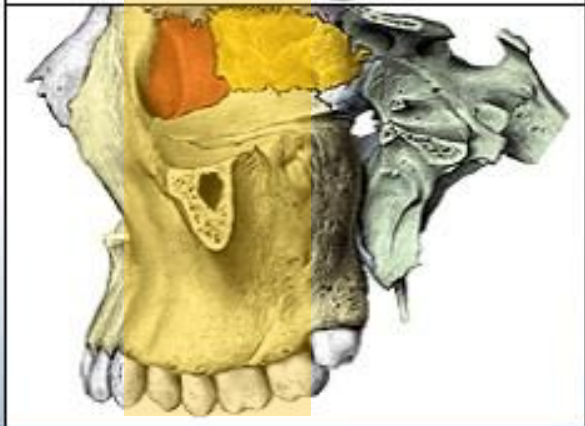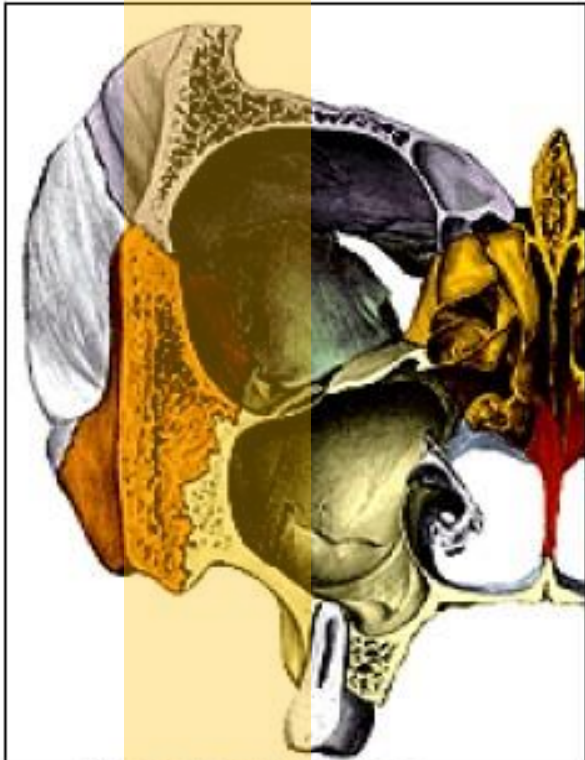
‘Přemístění’ vlastní růstem *primary displacement*

is also seen in a forward direction. This occurs by growth of the maxillary tuberosity in a posterior direction. This results in the whole maxilla being carried anteriorly.

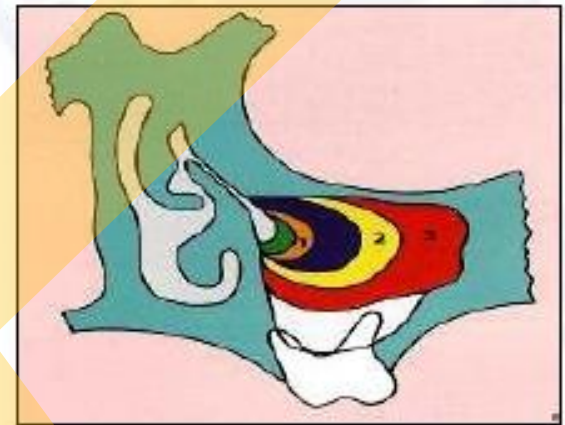


This is a primary type of displacement as the bone is displaced by its own enlargement

Sinus maxillaris



- antrum Highmori
- narození
7x4x4 mm
- RTG
4-5 měsíc
- bifasický růst
0-3 let & 7-12 let
- 18 let: 34x33x23 mm
- topografie
orbita - n. + vasa infraorbitalia
pr. alveolaris – M1, M2, PM2, M3, C
f. pterygopalatina & infratemporalis
MNM – ostium + akces. ostia



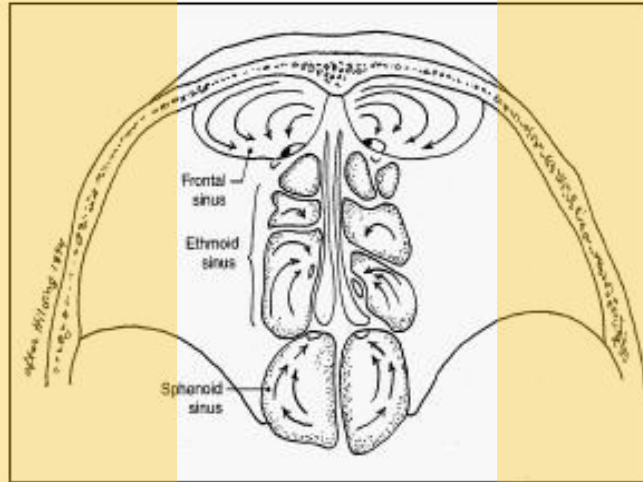
EXPANSION OF MAXILLARY SINUS

At birth - 7 mm length
- 4 mm height
- 4 mm width

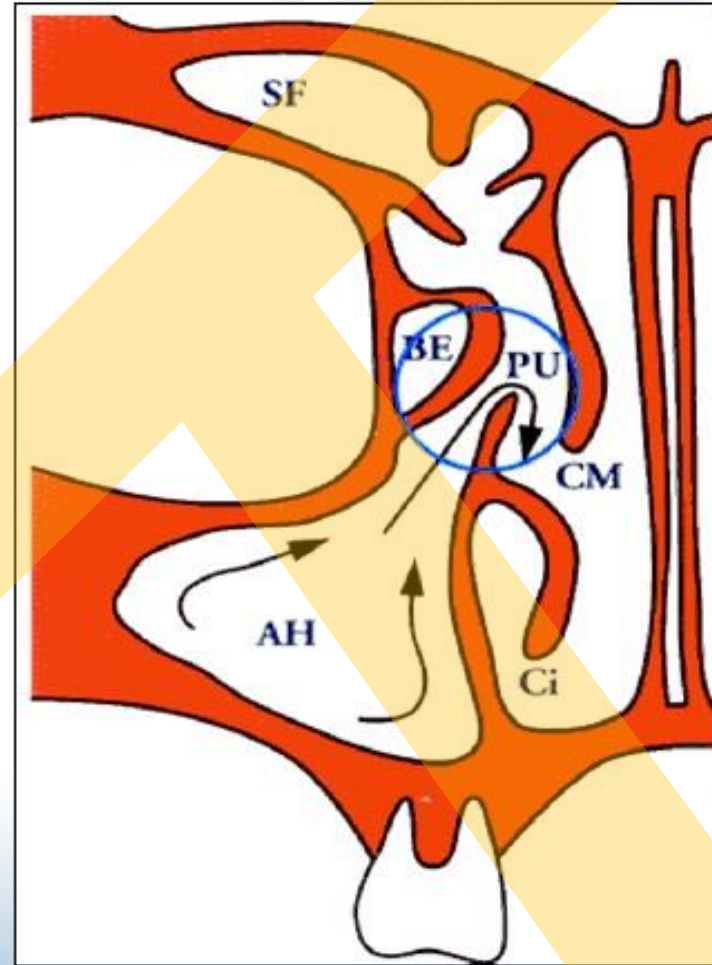
Expands at rate of - 2 mm vertically yearly
- 3mm A-P yearly

Expansion by - bone resorption
- by tooth eruption
(as vacated bone become pneumatized)

Ostiomeatální komplex



mukociliární clearance



The sinus was well known to anatomists before Highmore. It had been illustrated by Leonardo da Vinci (1452-1519) and had been noticed by Giulio Casserio (1561-1616)

Růst maxily

*Podél osy procházející intraalveolárním septem
mezi lateral dočasným řezákem a špičákem
(„opening bridge“)*

ventrokaudálně

Vliv sutur frontomaxillaris, zygomaticomaxillaris, pterygopalatina

Vliv sutur incisiva et intermaxillaris

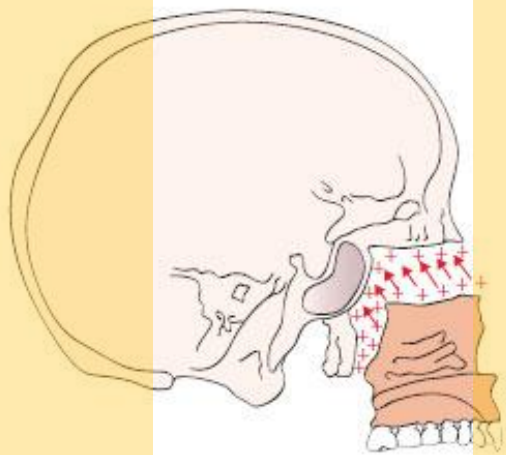
kaudálně

septum nasi

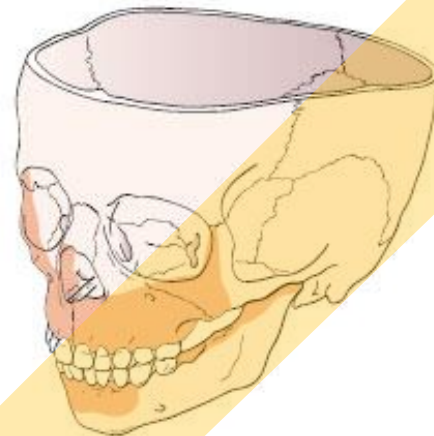
Vliv na okolní struktury

postnatálně

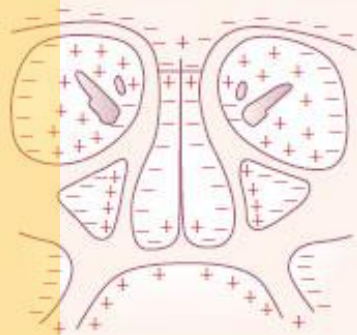
sutura palatina mediana (7-19 rok roste o cca 5 mm)



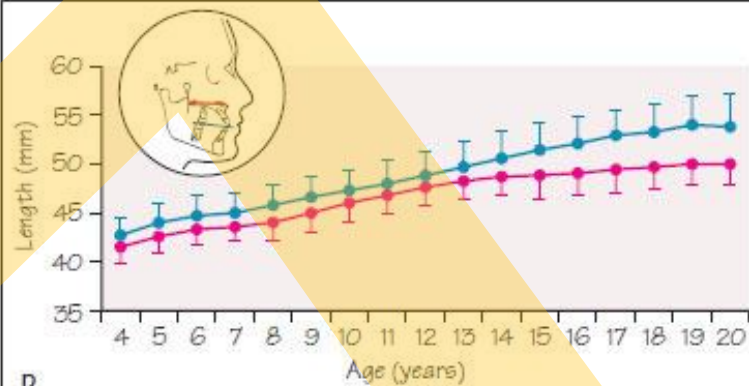
A



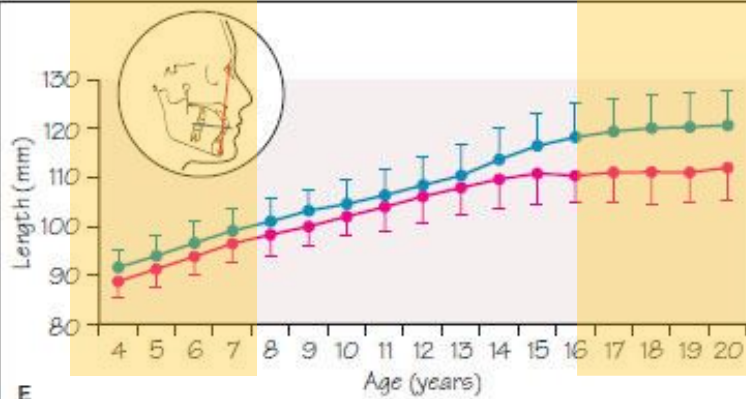
B



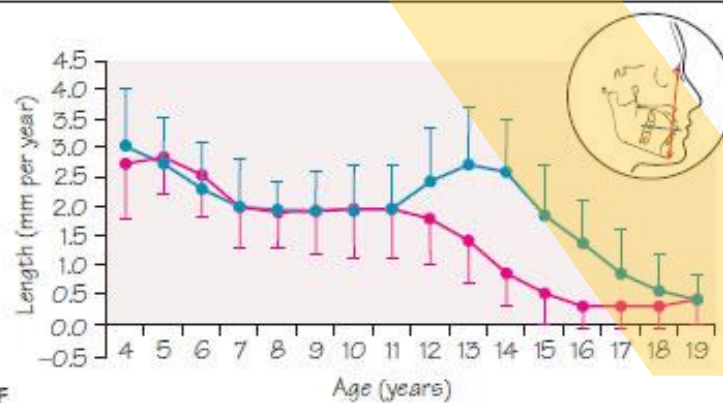
C



D



E



F

* * * * *