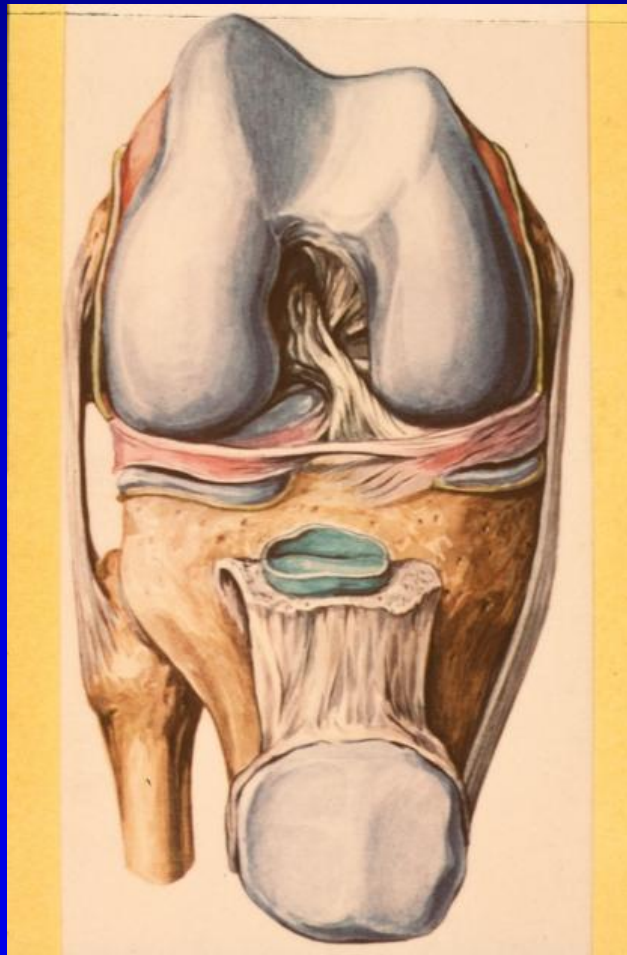
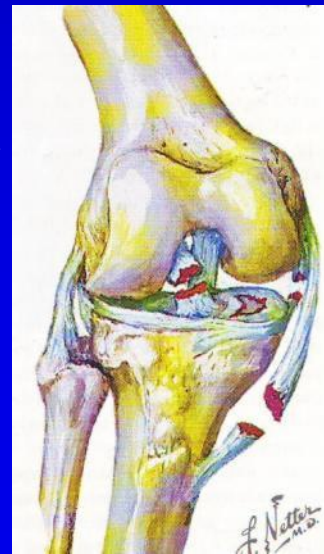


# Anatomie kolenního kloubu



# Kolenní kloub – kloub superlativů

- Největší
- Nejsložitější
- Dvě nejdelší páky (kosti) těla
- Nejmohutnější vazivový aparát
- Nejmohutnější svalový aparát
- Velmi frekventní závažná poranění kloubu



# Kolenní kloub

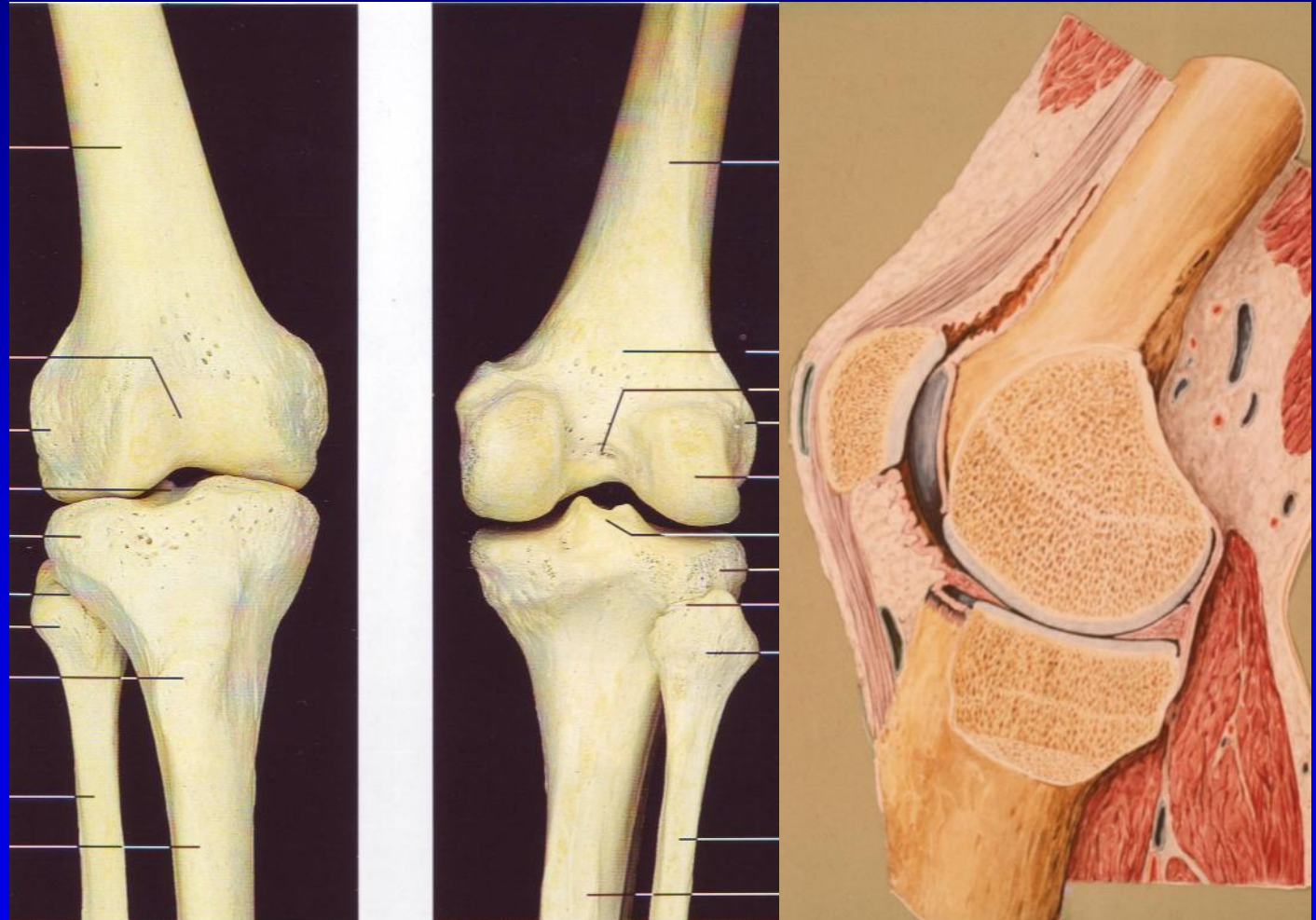
- Funkce estetická
- Významný milník ve světě módy



# Kolenní kloub

## artikulující kosti

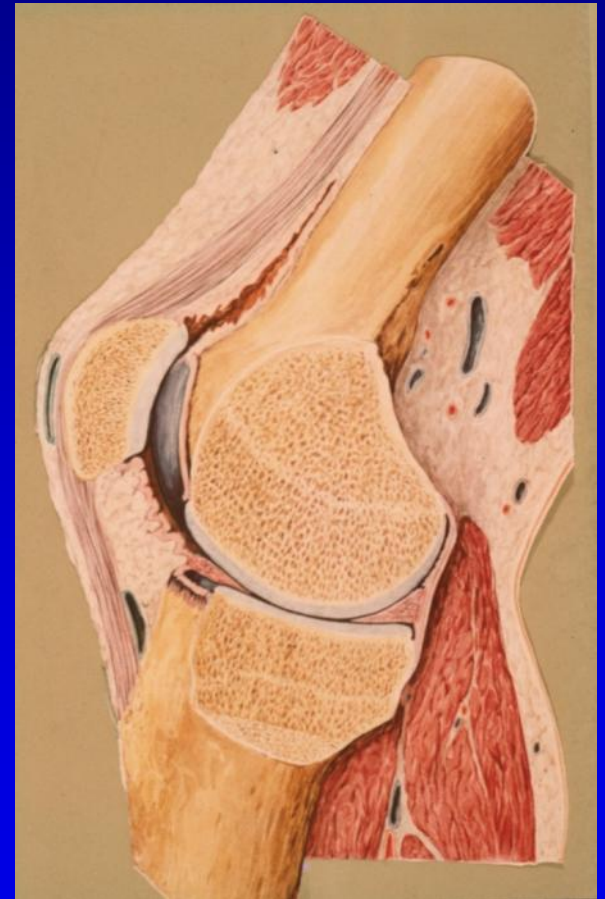- Femur
- Patella
- Tibia



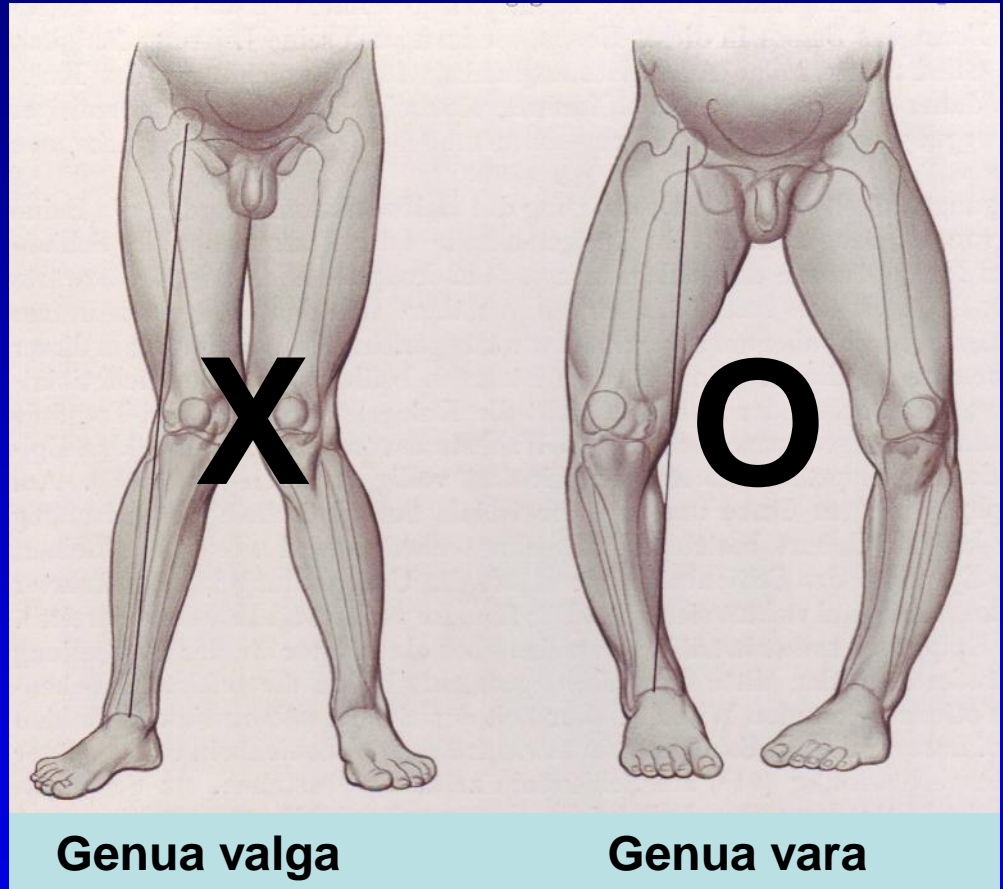
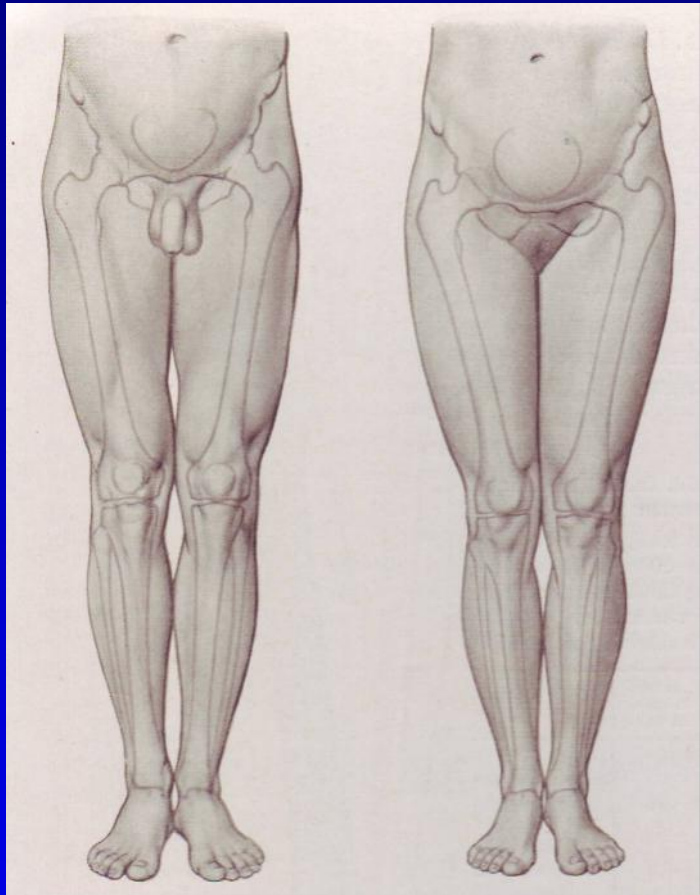


# Kolenní kloub

- Femoro-patelární  
*(sedlový)*
- Femoro-tibiální
  - *Mediální*
  - *Laterální*

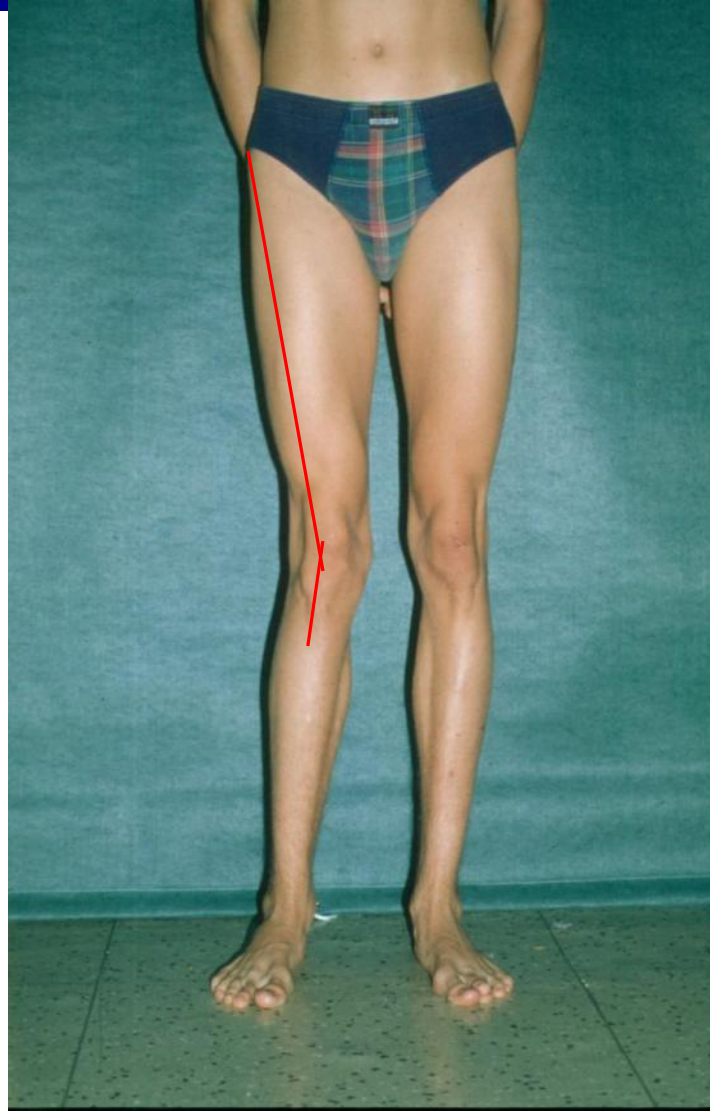
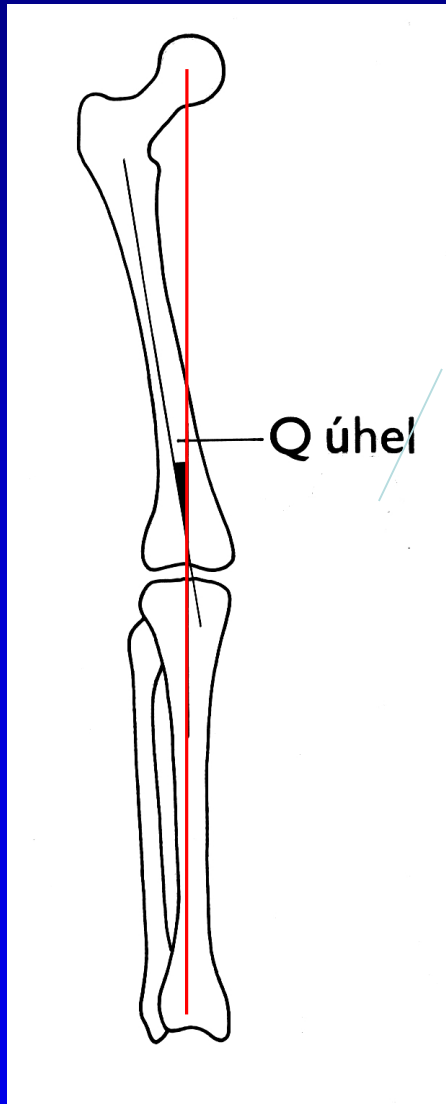


# Osové uspořádání kolenního kloubu



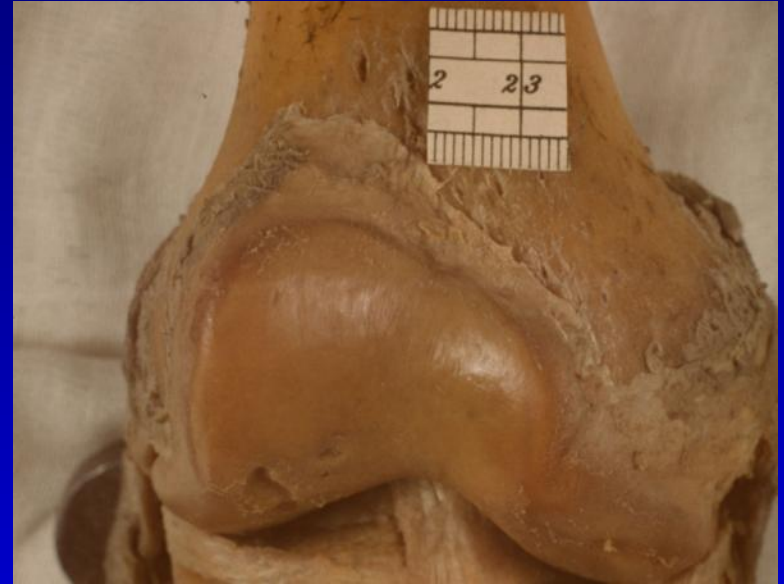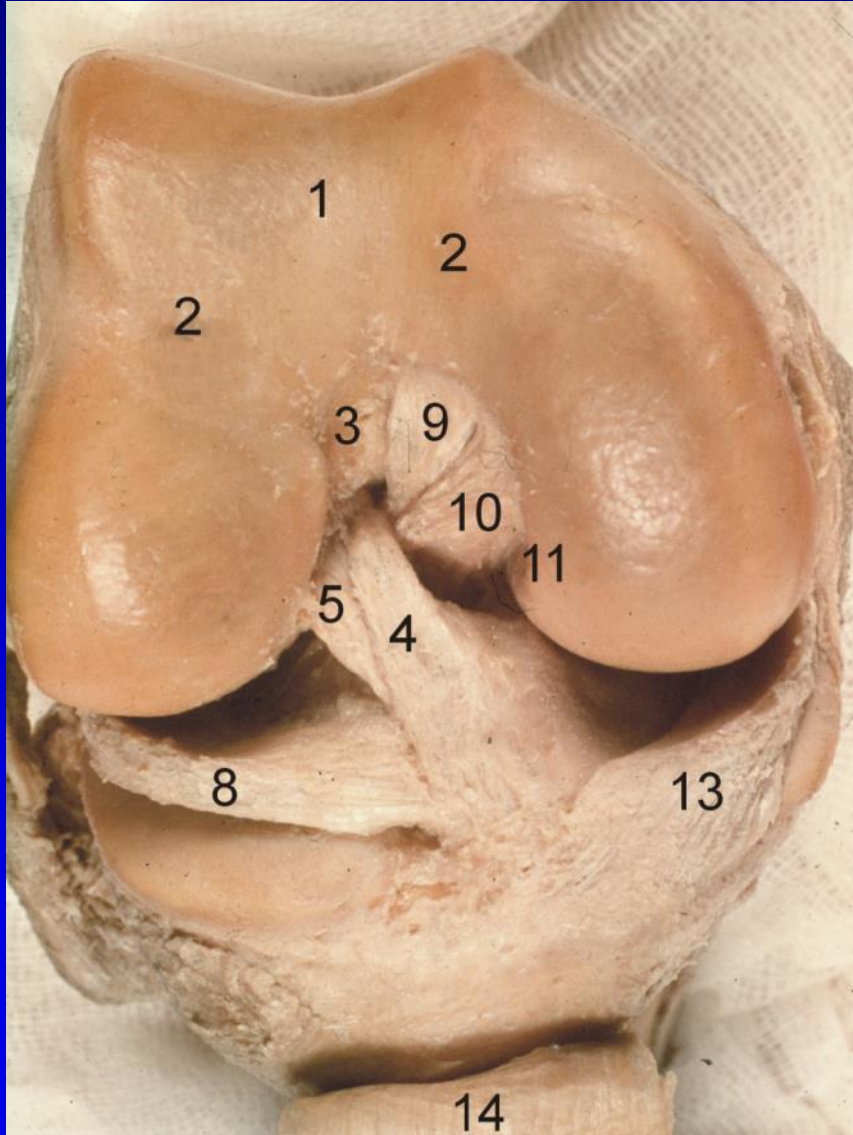
# Osové uspořádání kolenního kloubu

## Anatomická x mechanická osa



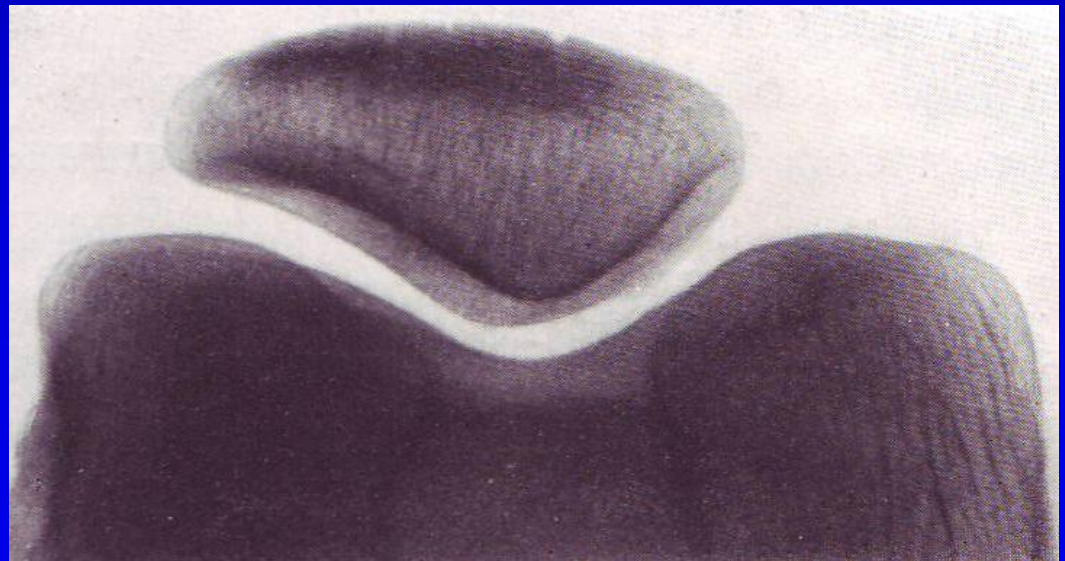
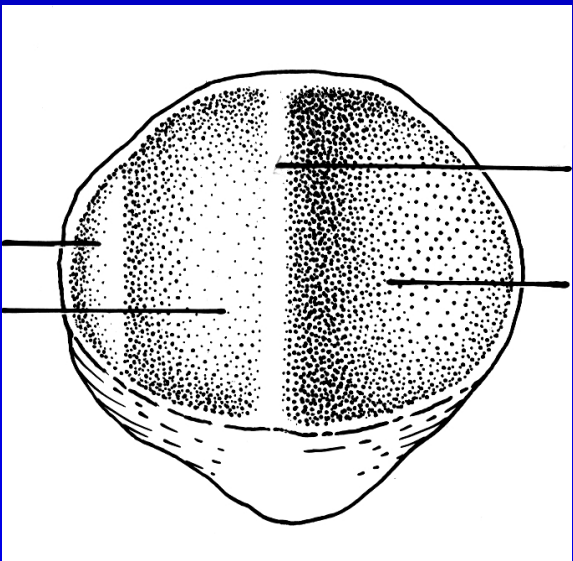
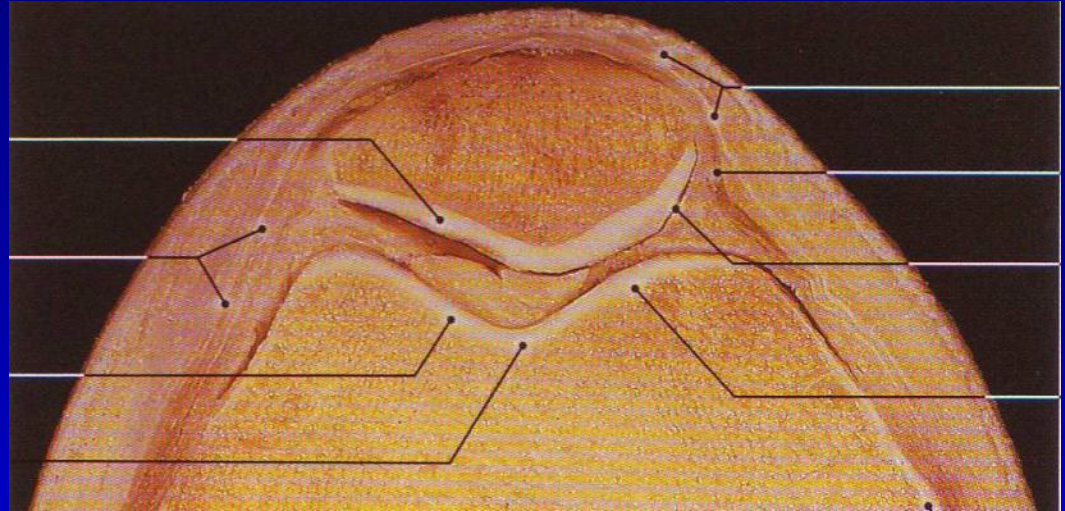
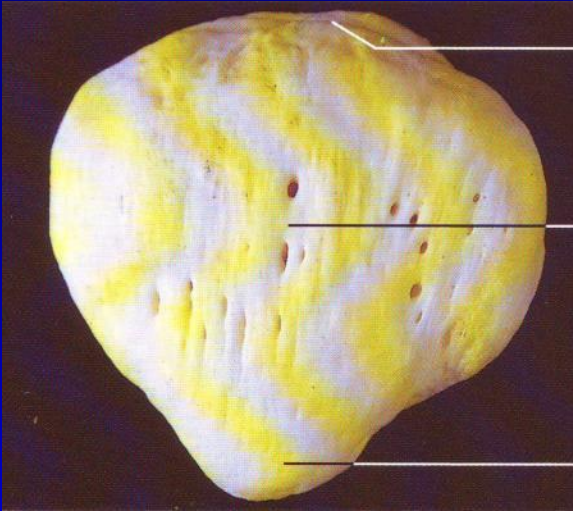


# Femur





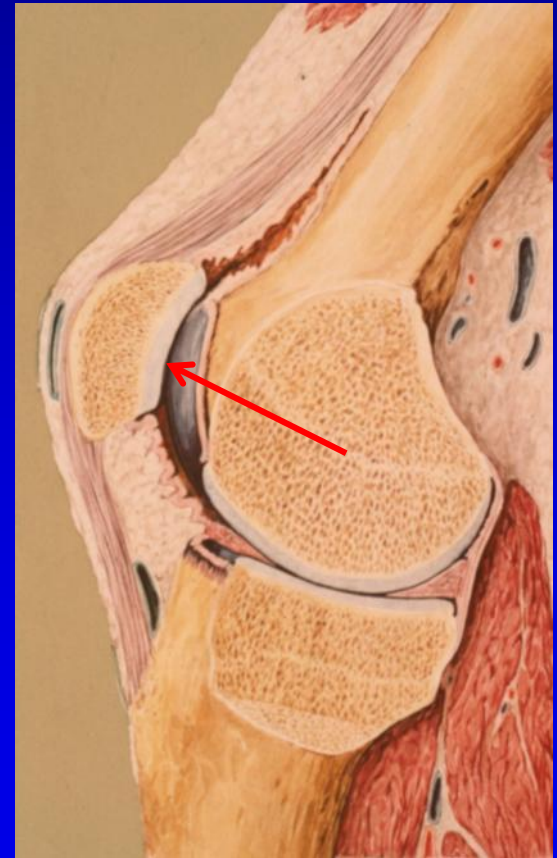
# Patella



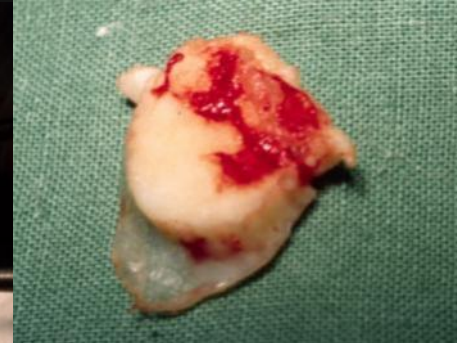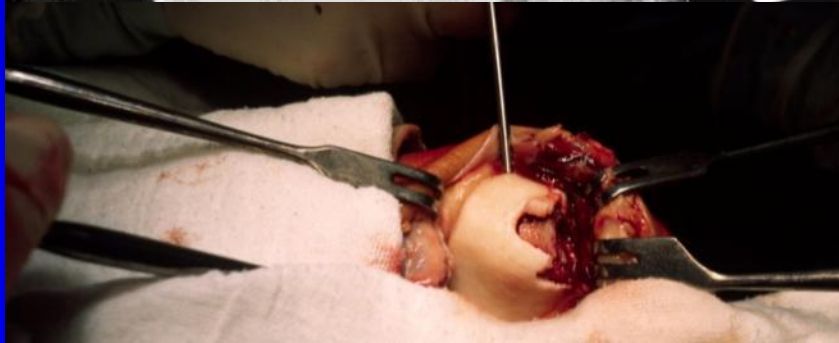

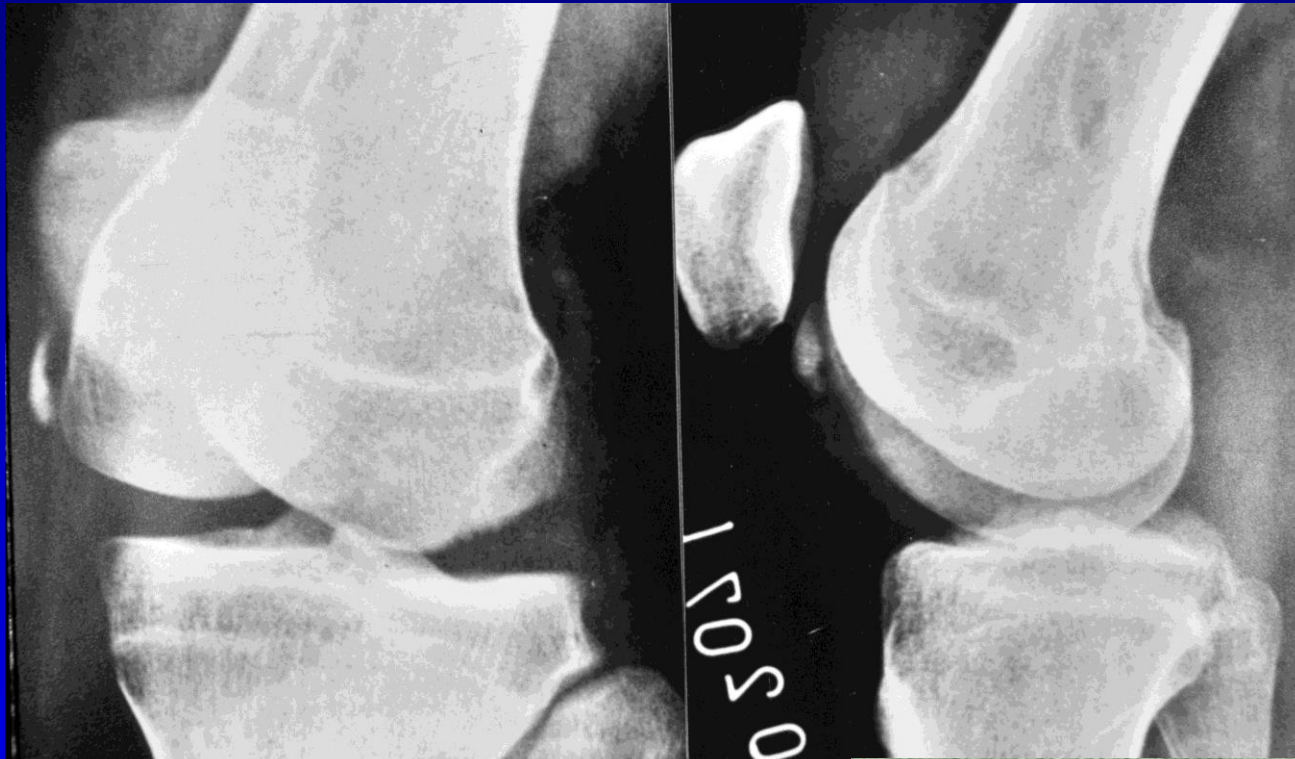
# Funkce čéšky

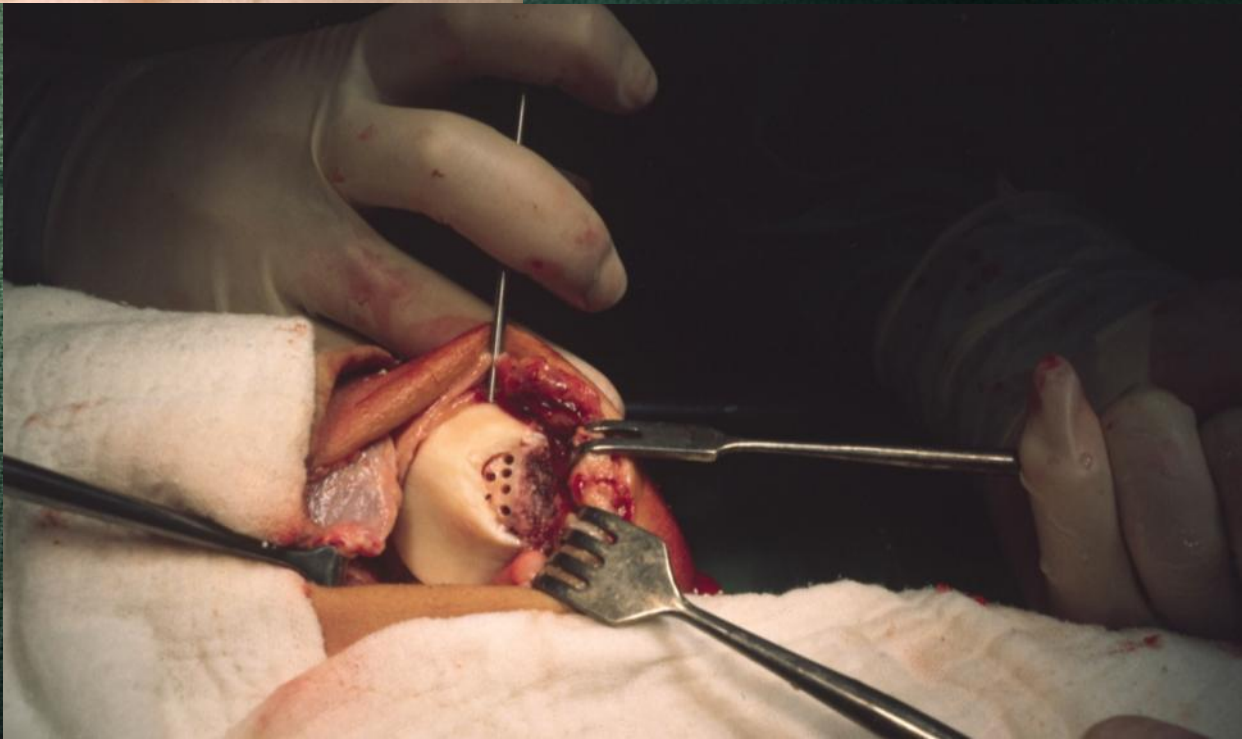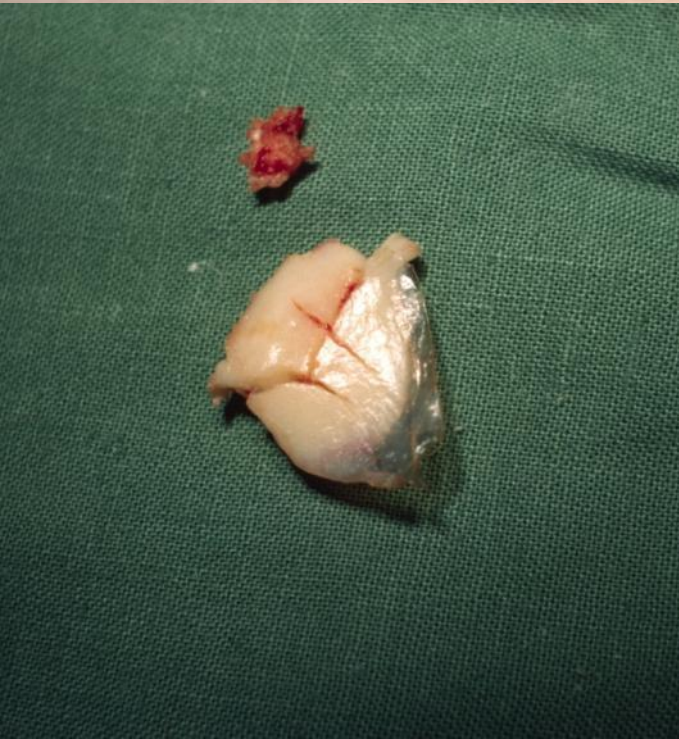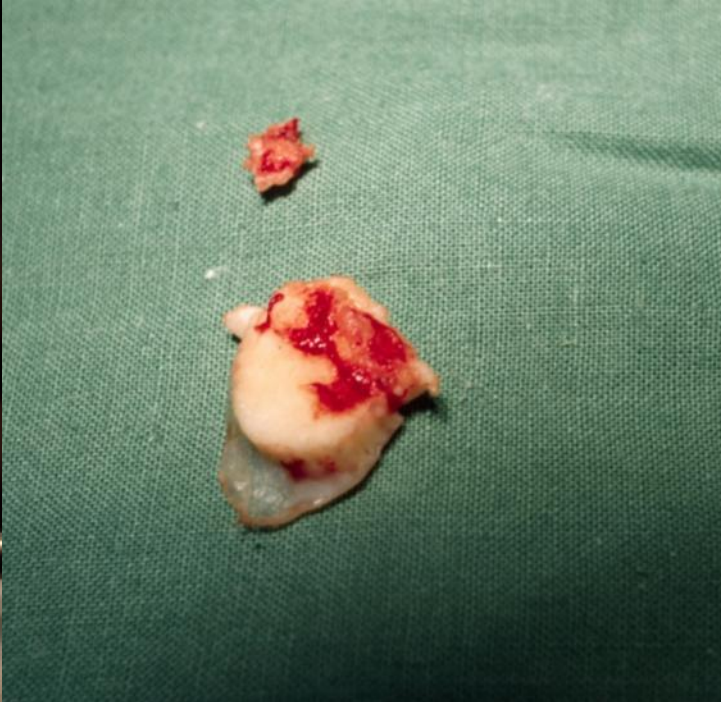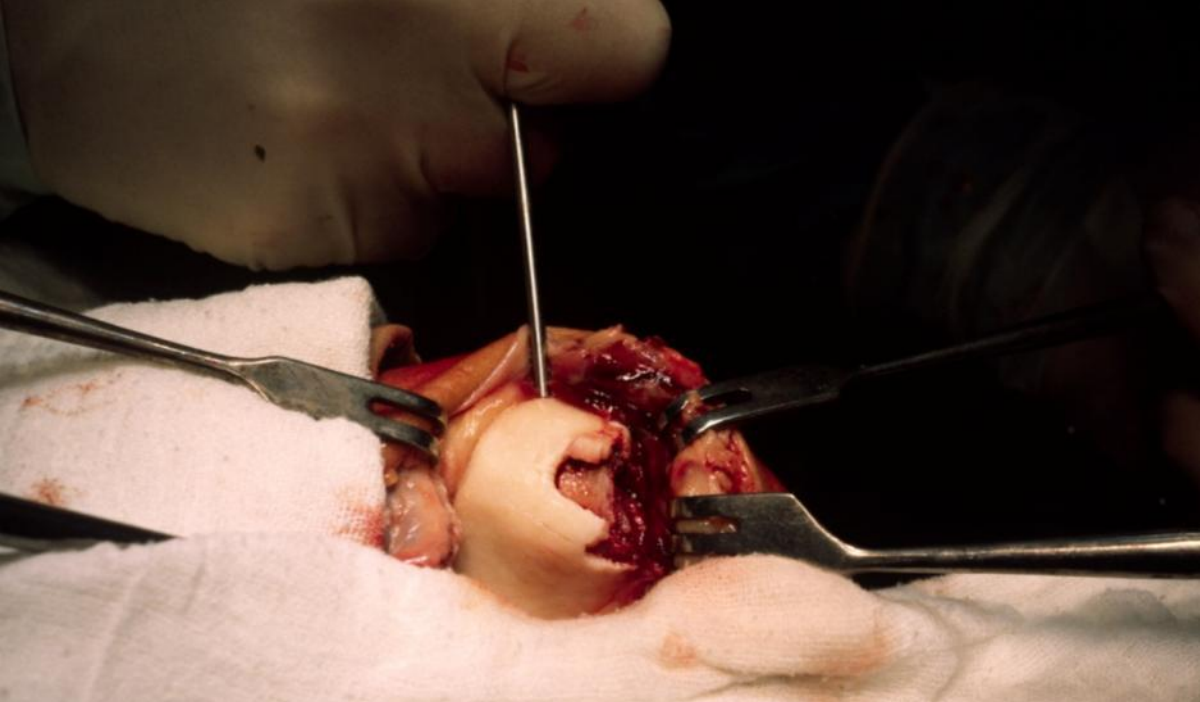
- Centralizuje tahy jednotlivých částí m. quadricps femoris
- Zlepšuje páku mqf
- Chrání přední část kloubu
- Estetika kloubu



# Nitrokloubní zlomeniny osteochondrální

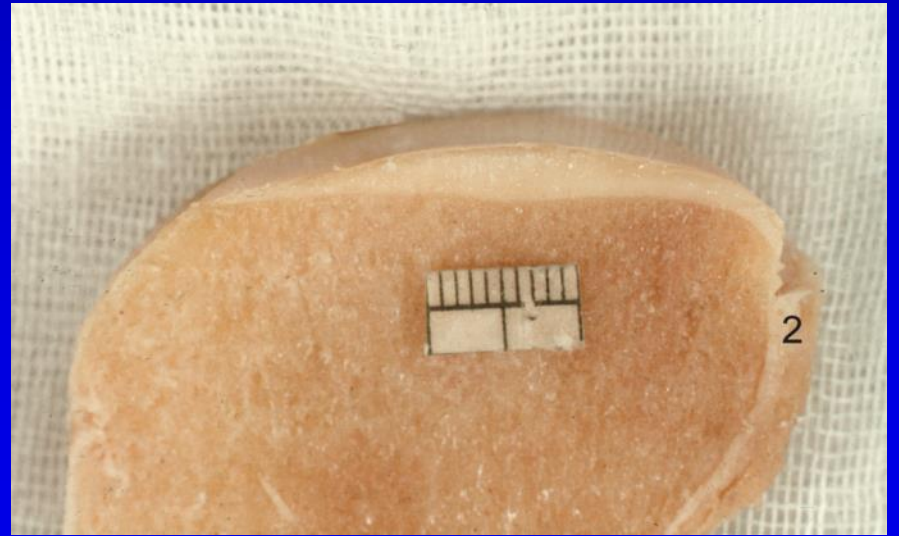
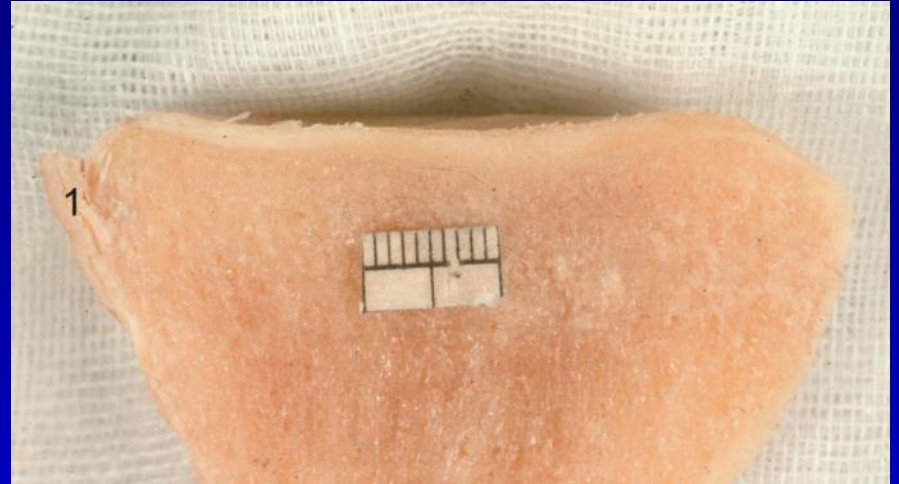
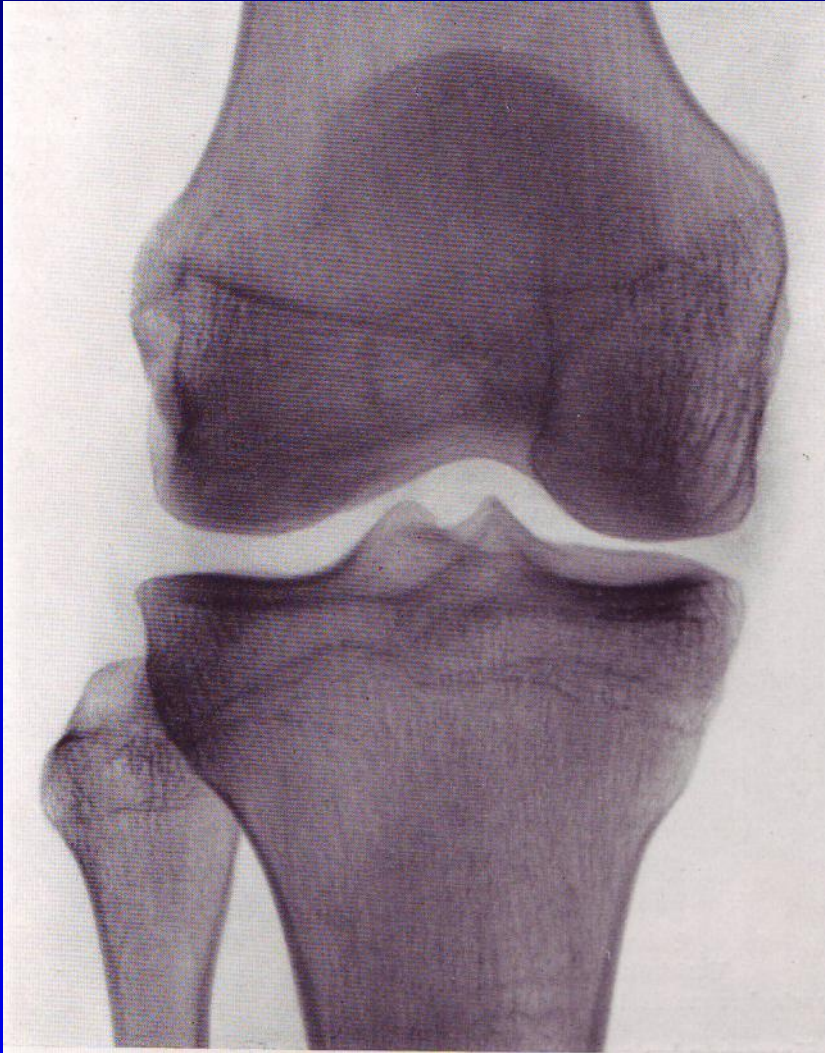




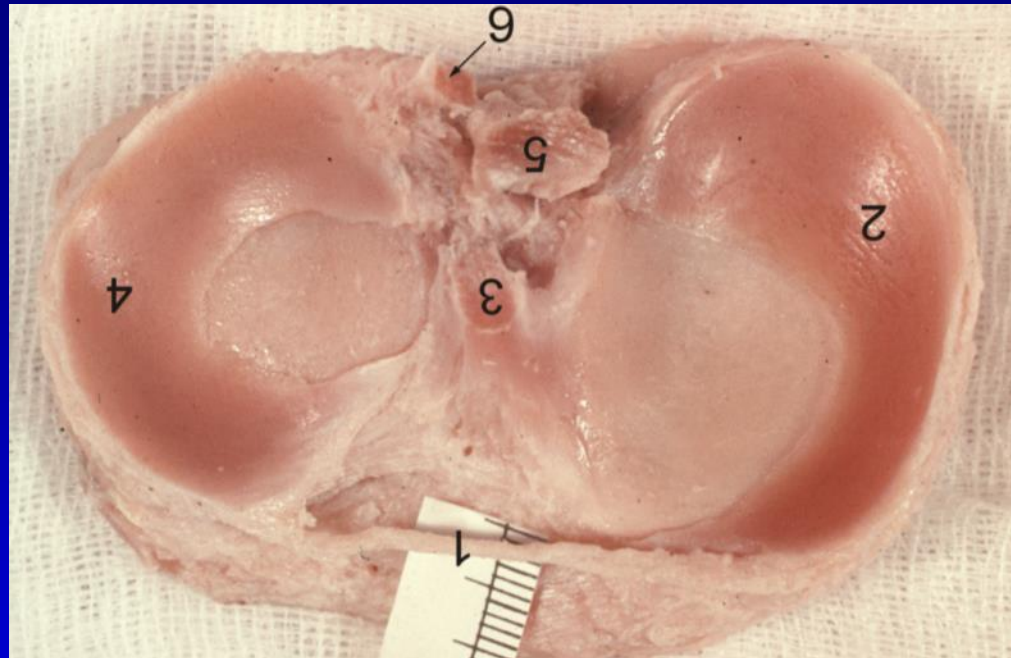




# Tibie

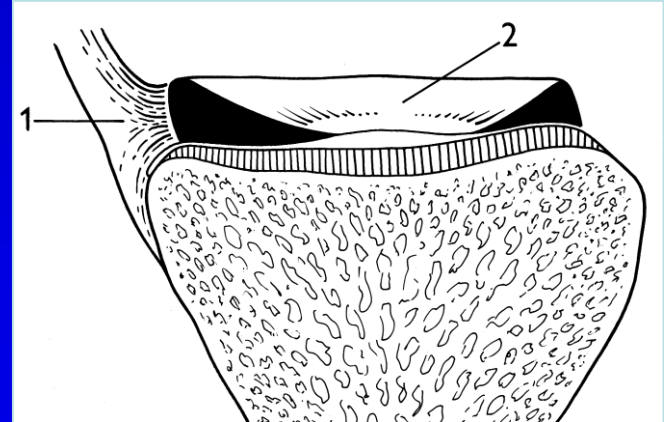
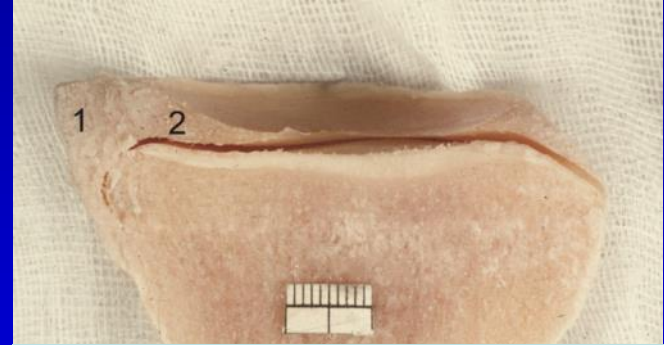
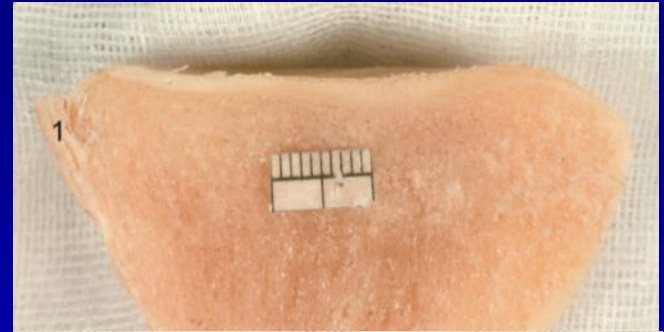
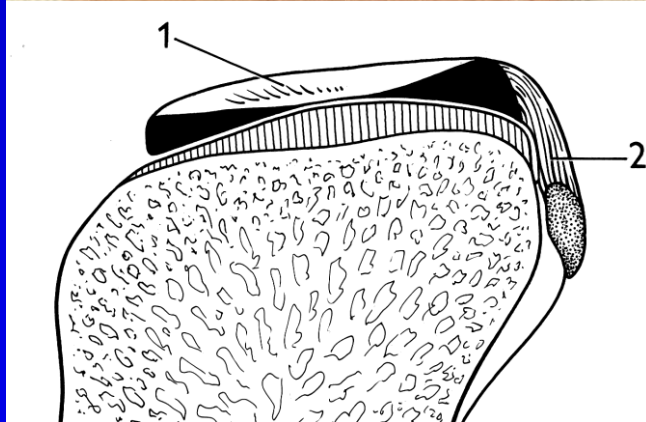
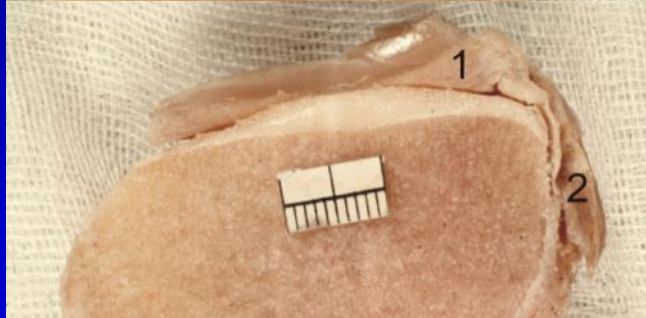



# Menisky

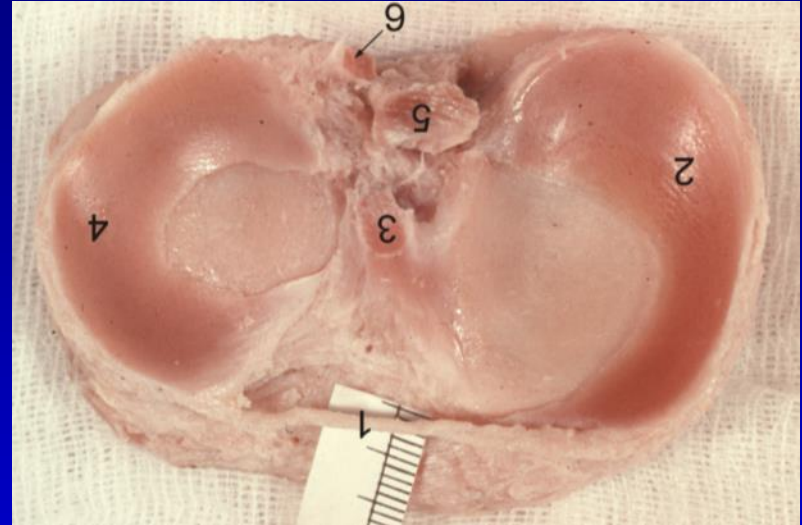
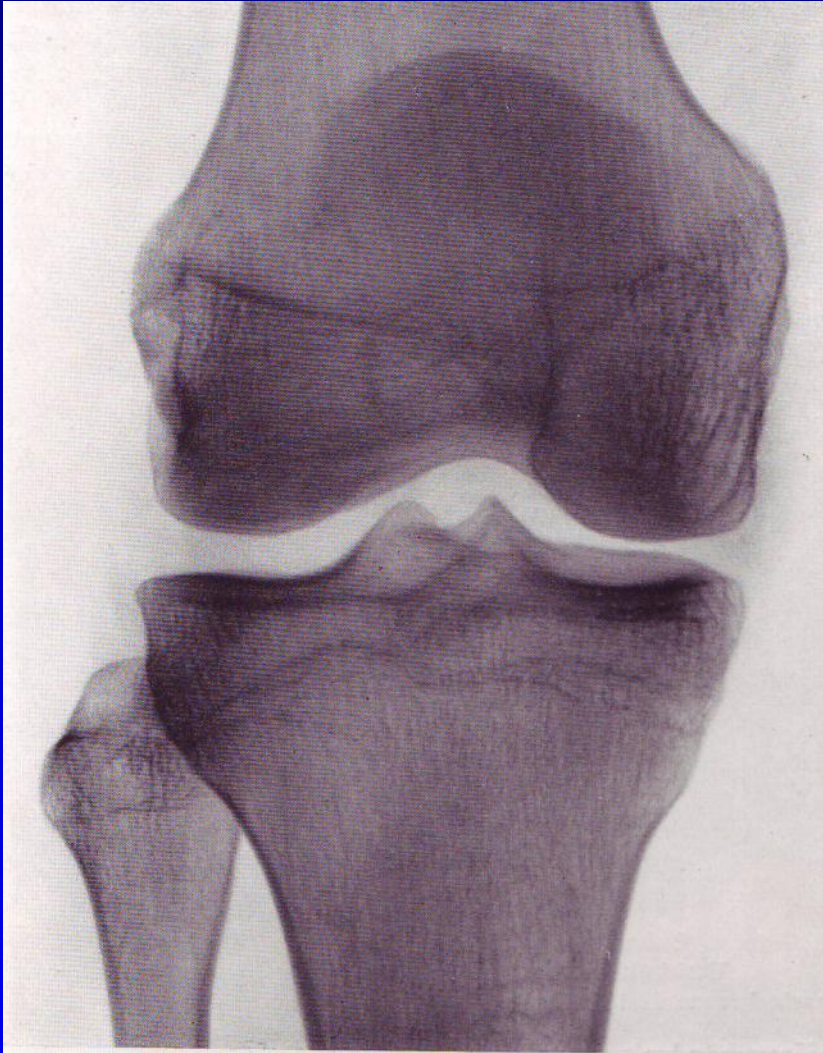




# Menisky

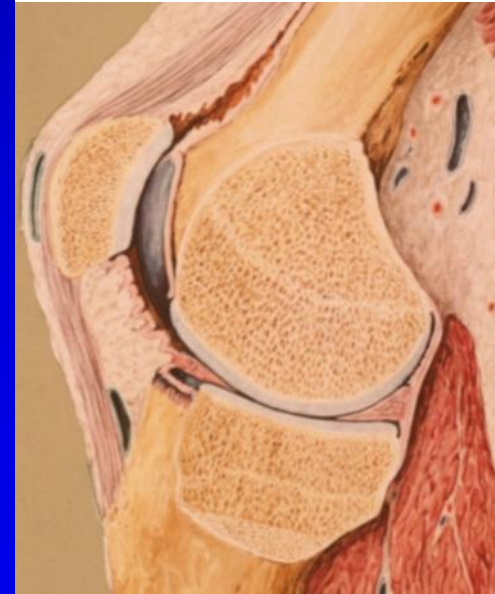


# Menisky



# Funkce menisků

- Dotváří jamky na kondylech
- Přenášejí tlakové síly
- Roztírají synovii (*pístní kroužky*)
- Zabraňují uskřinutí pouzdra

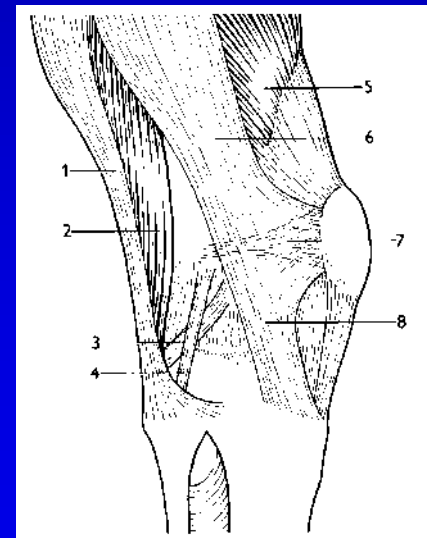
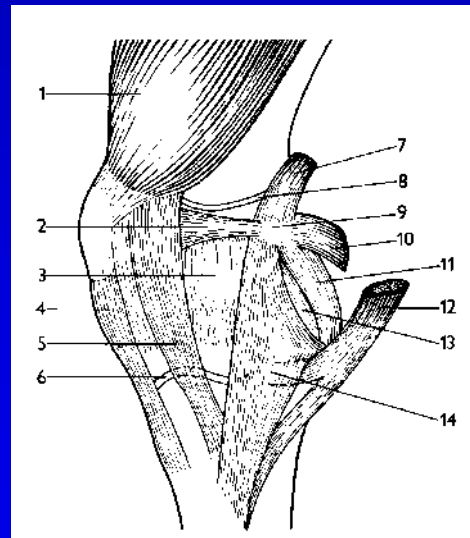
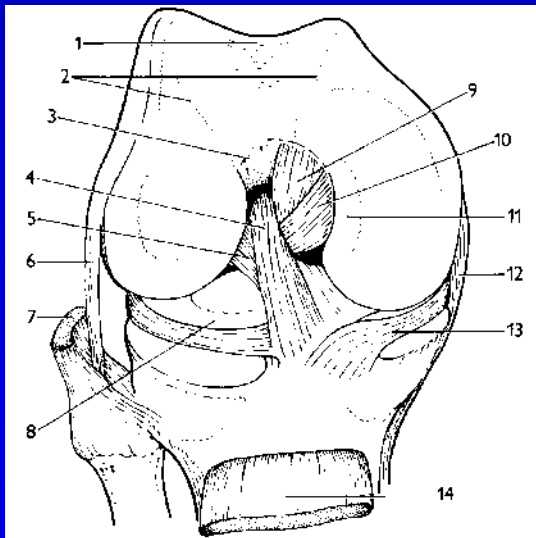




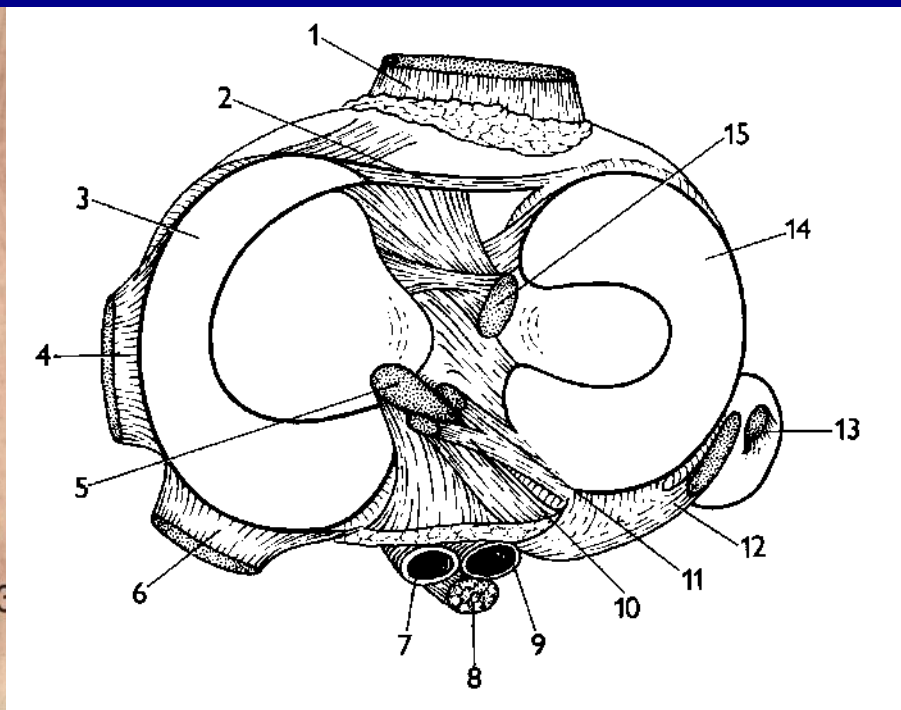
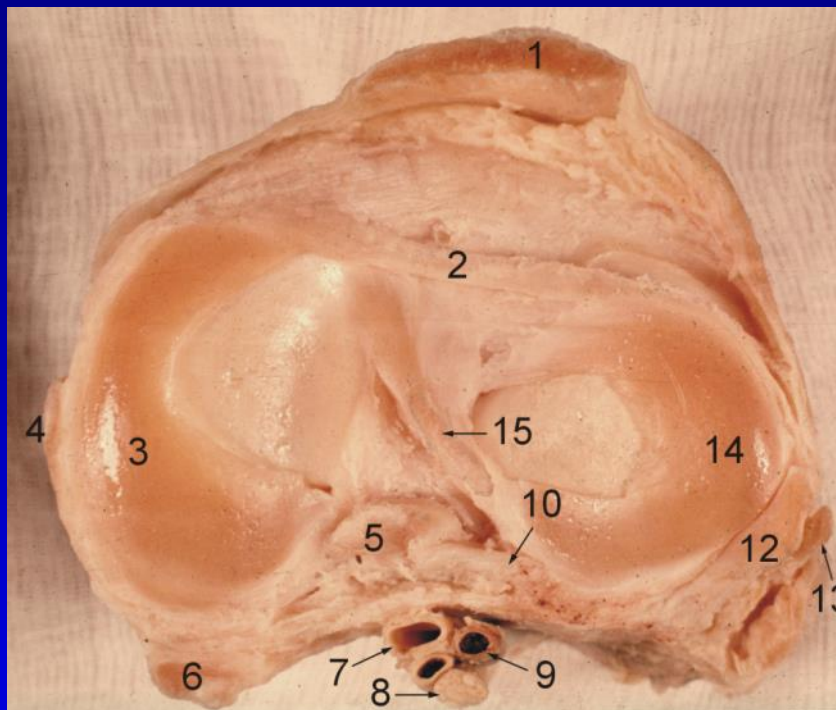
# Vazivový aparát

## Základ kloubní pouzdro

- Intraartikulární vazy
- Kapsulární vazy



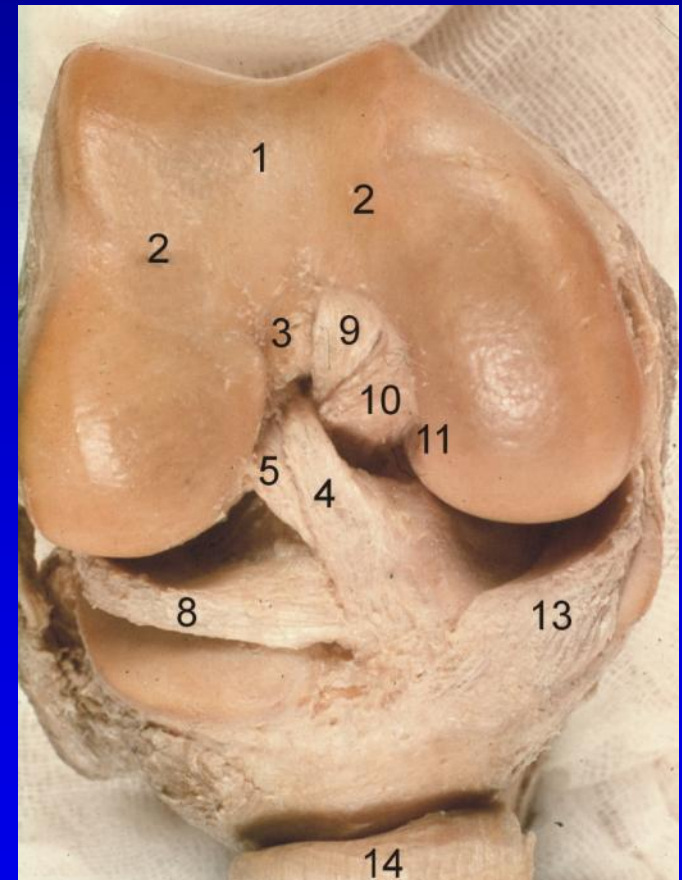
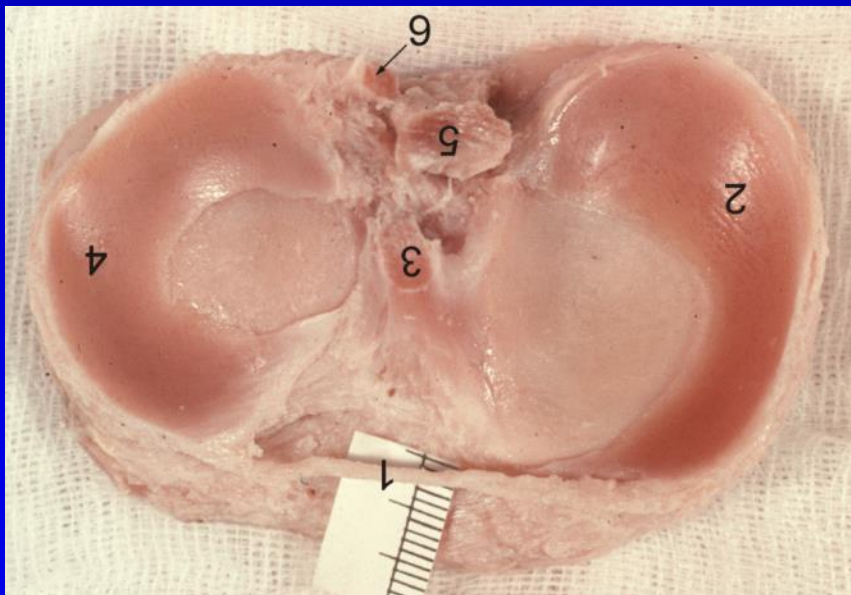
# Kloubní pouzdro



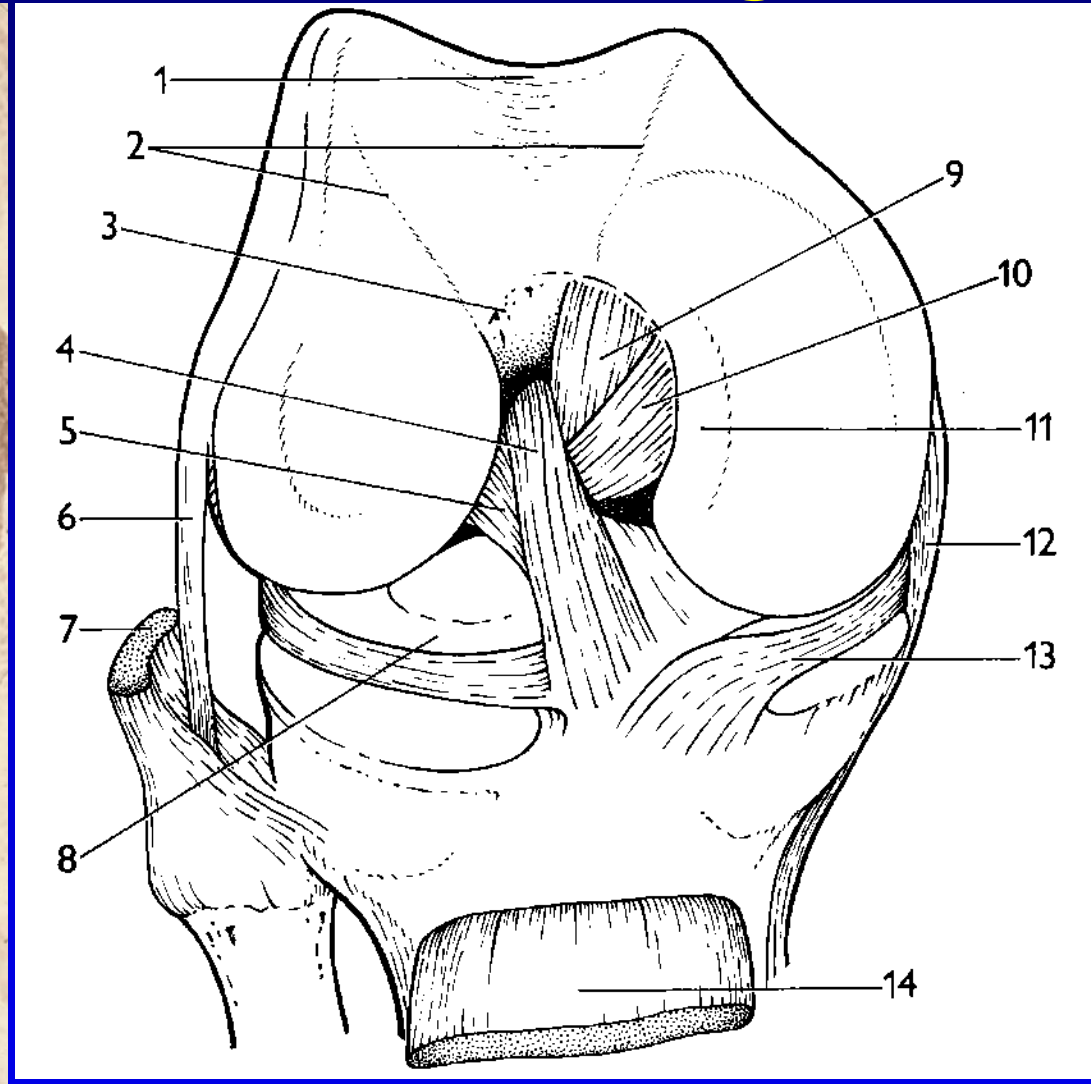
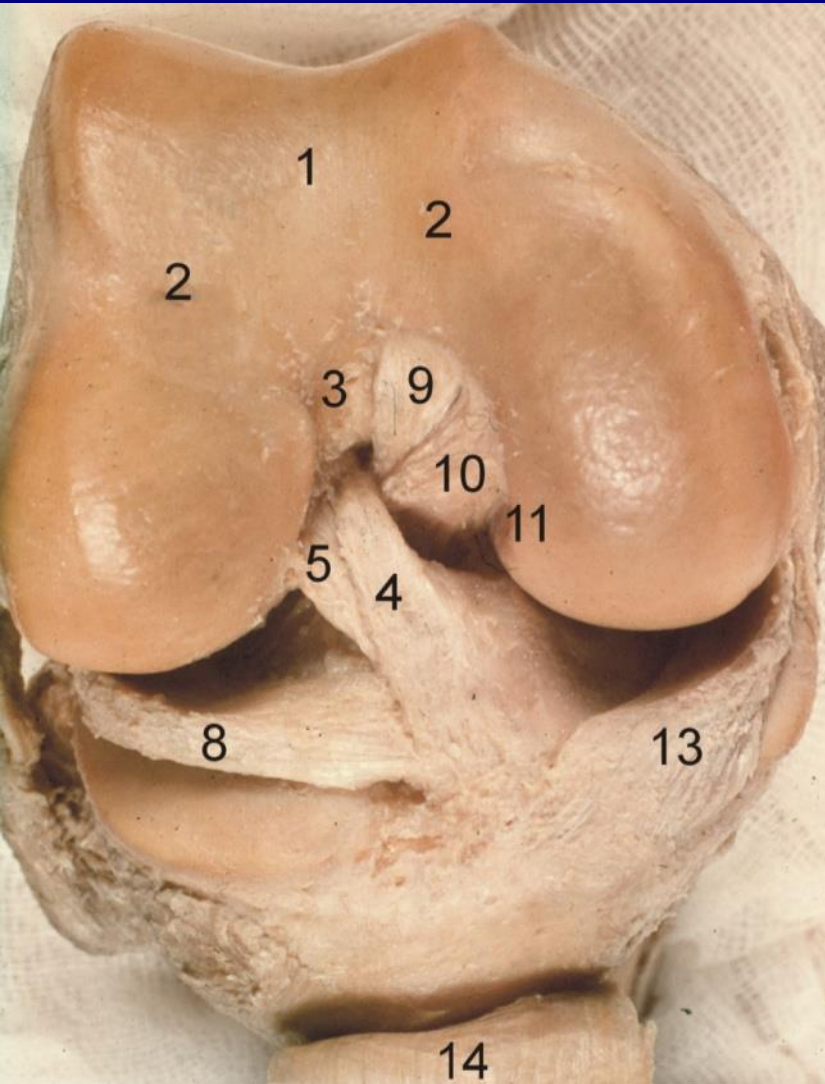


# Intraartikulární vazy

- Lig. cruciatum anterius
- Lig. cruciatum posterius
- Vazy menisků

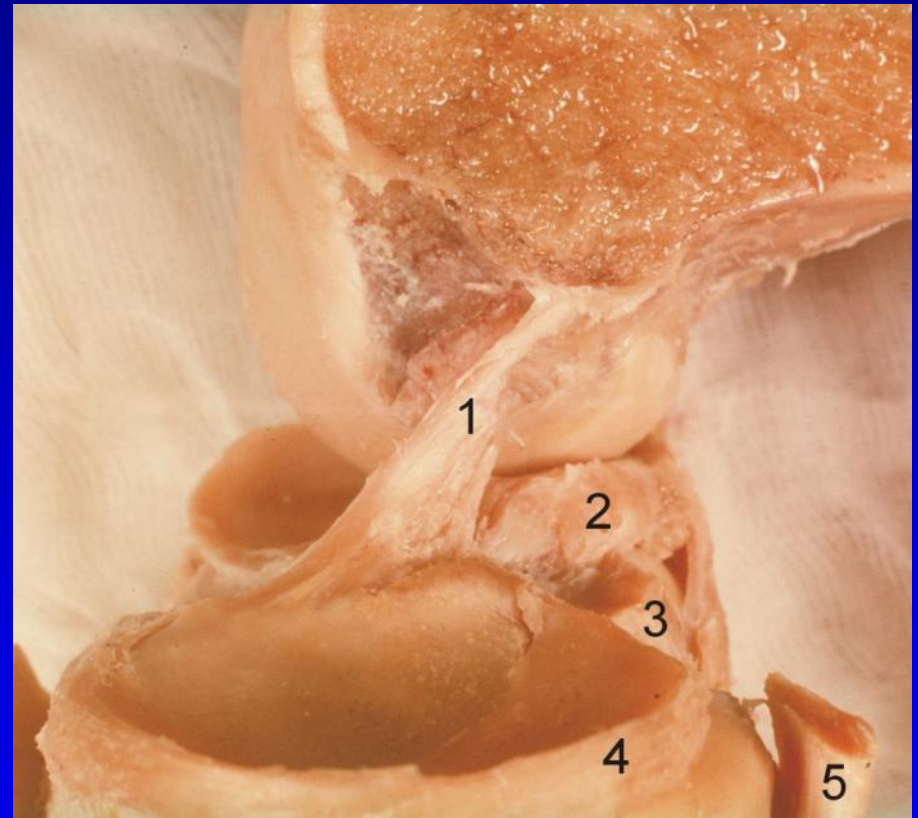
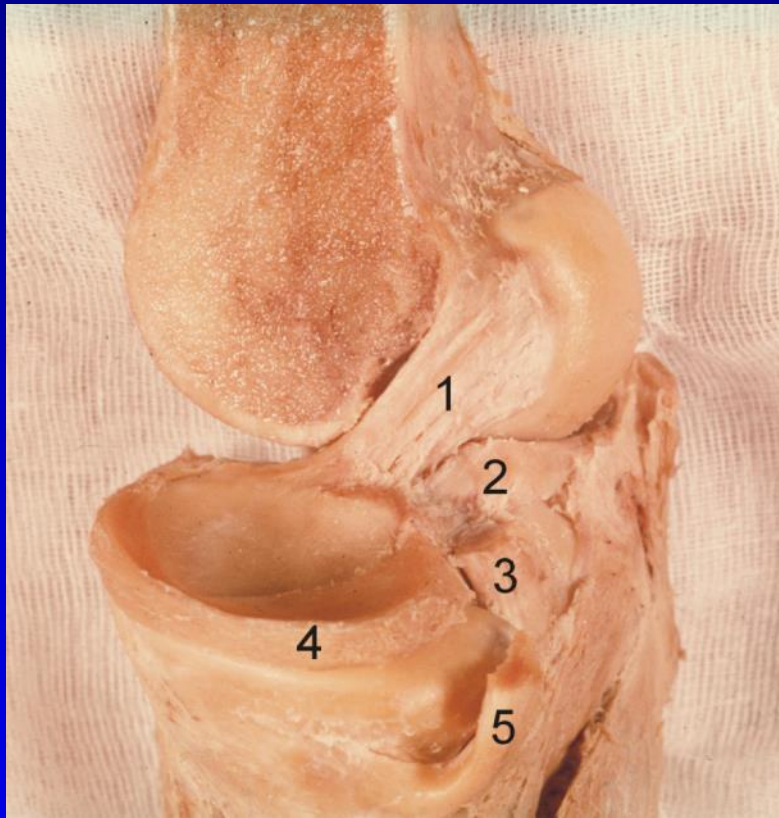


# Intraartikulární vazy



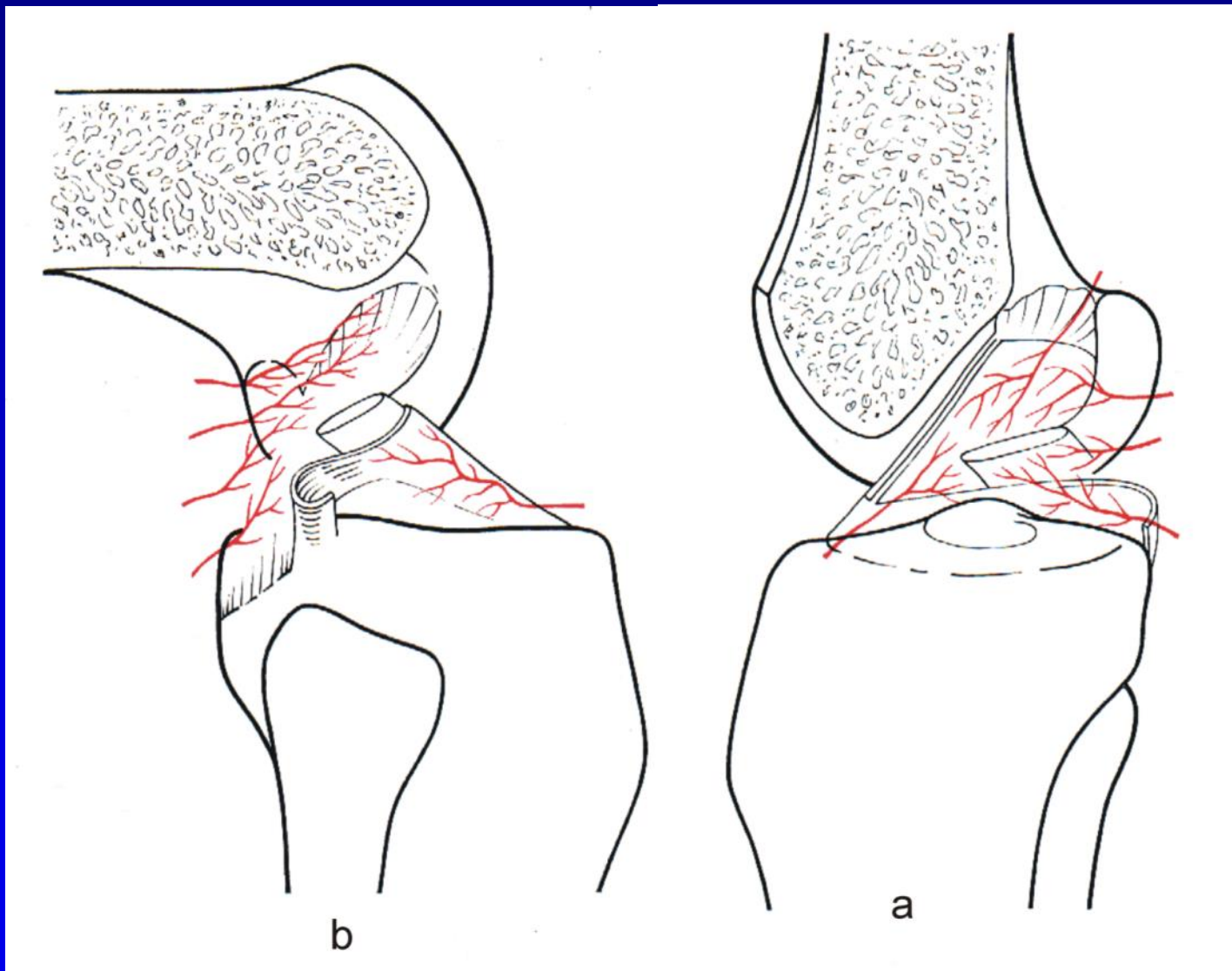
# Lig. cruciatum anterius

nejčastěji poraněný vaz kolenního kloubu

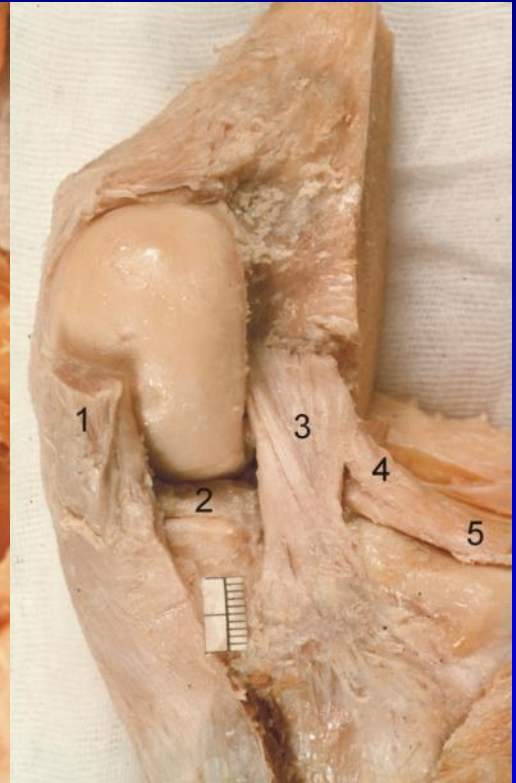
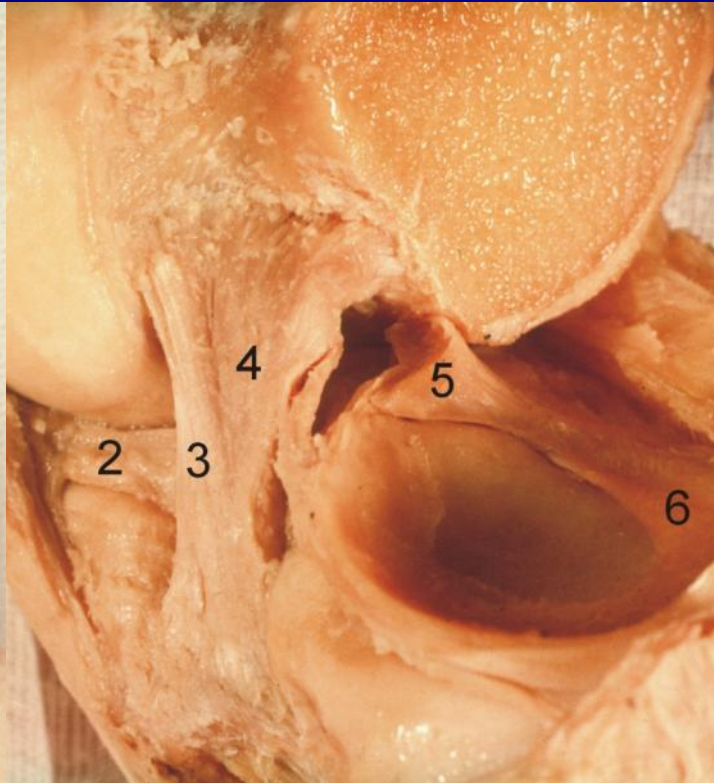
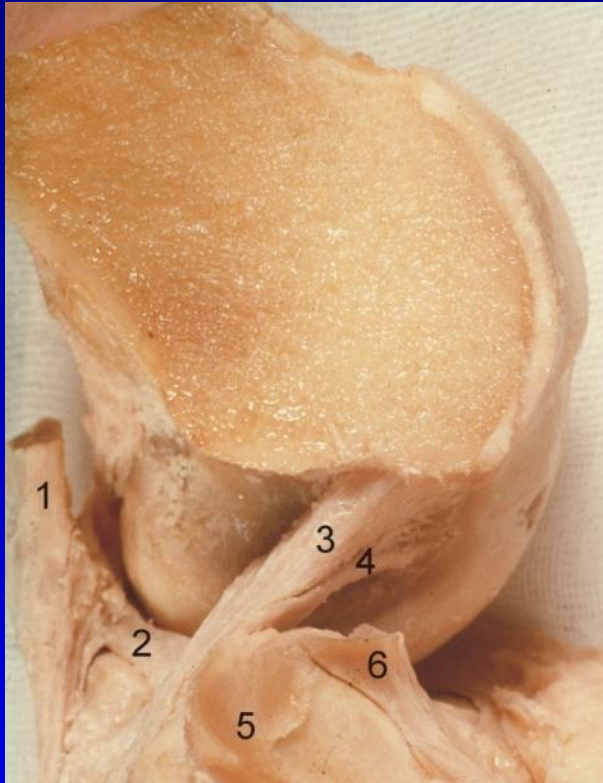



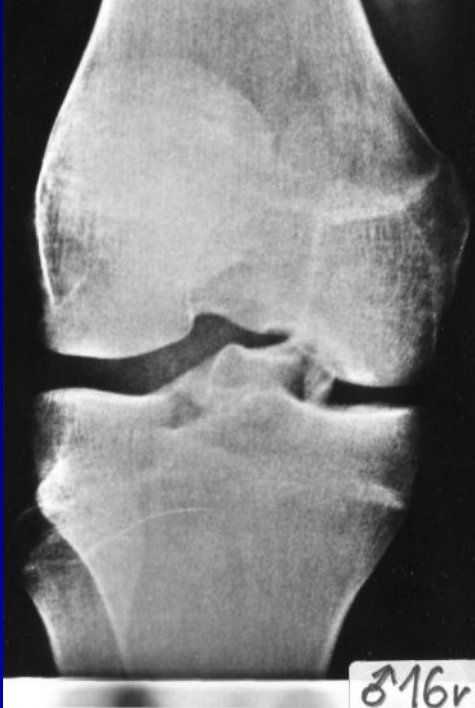# Trochu kliniky



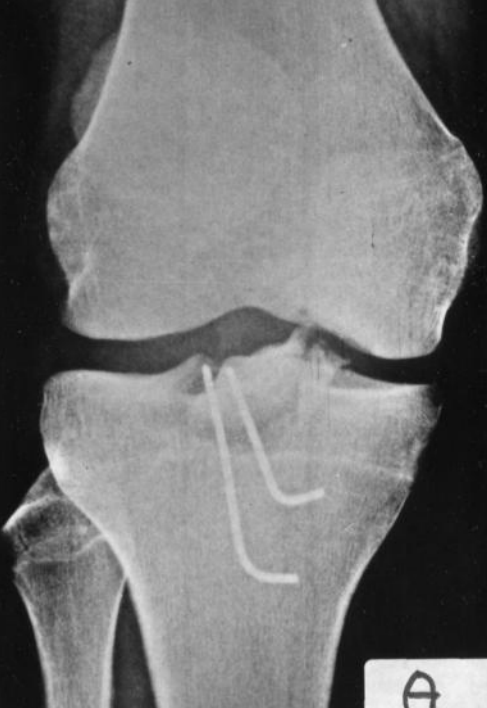# Lig. cruciatum posterius



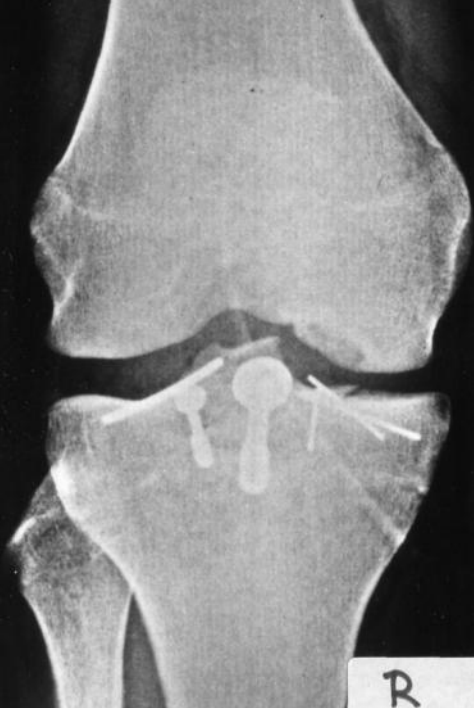



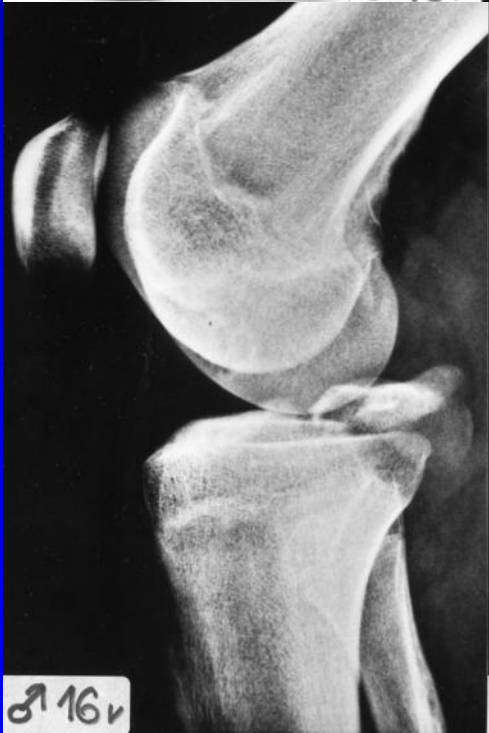♂16v



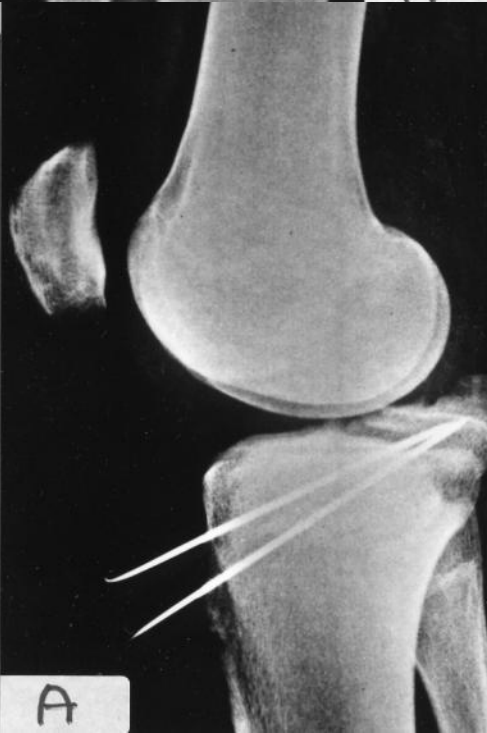A



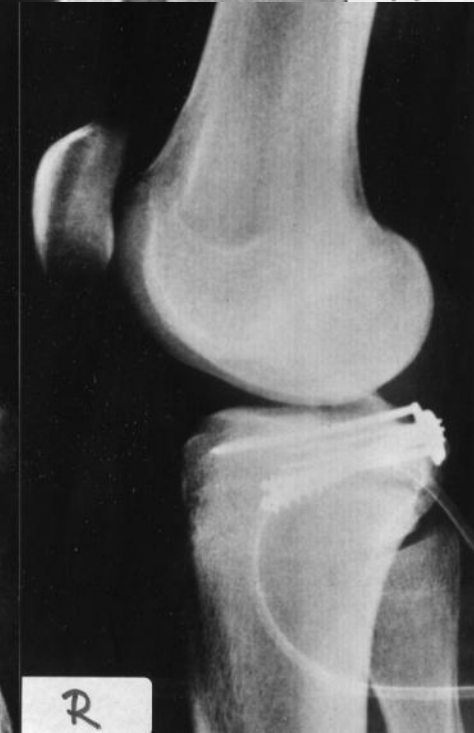R



♂16v

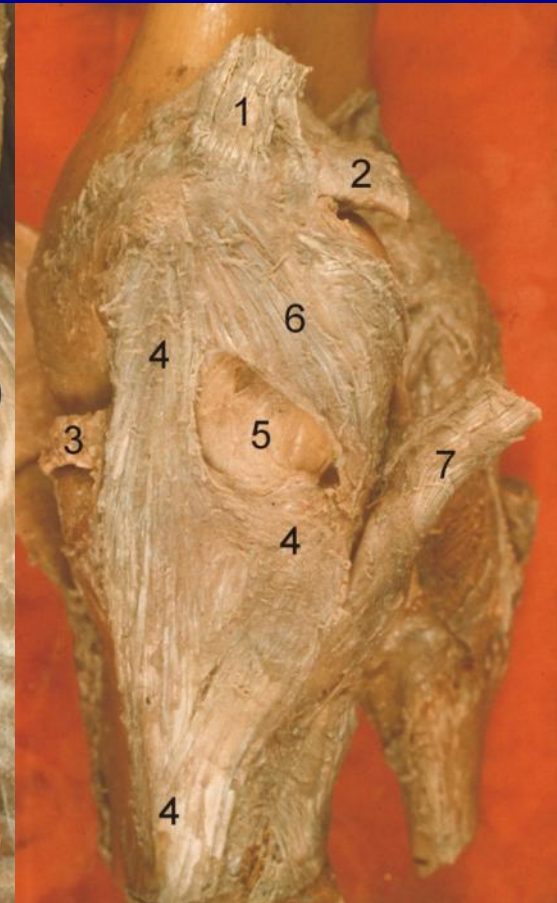
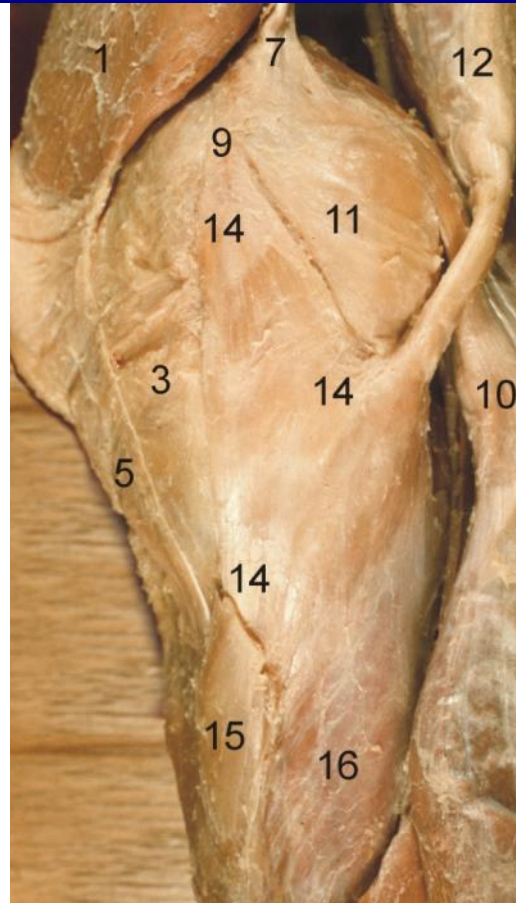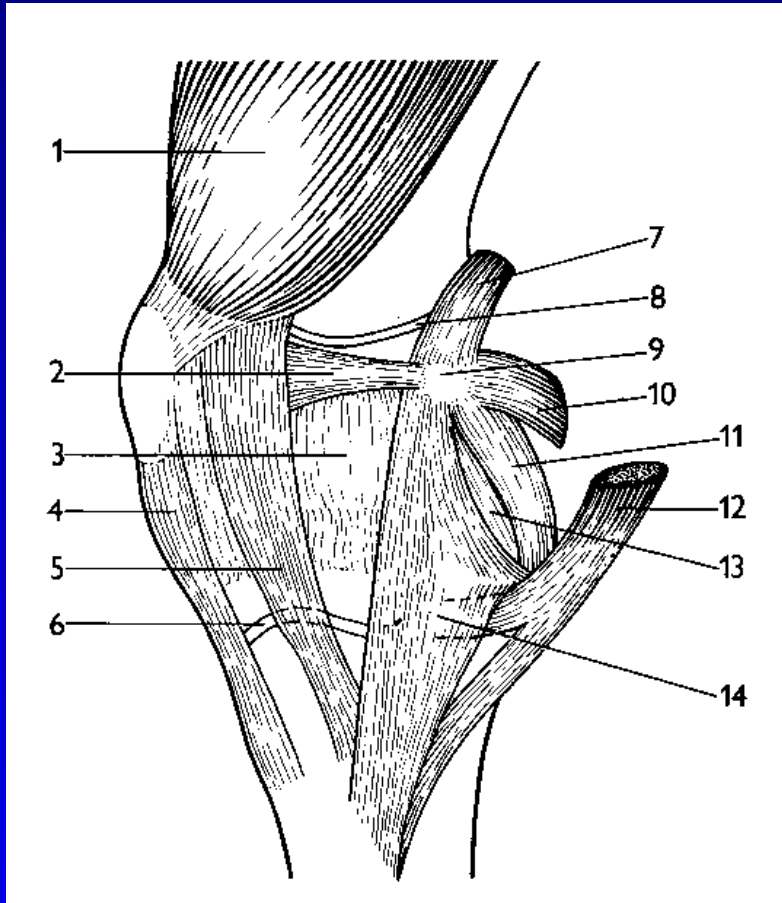


A



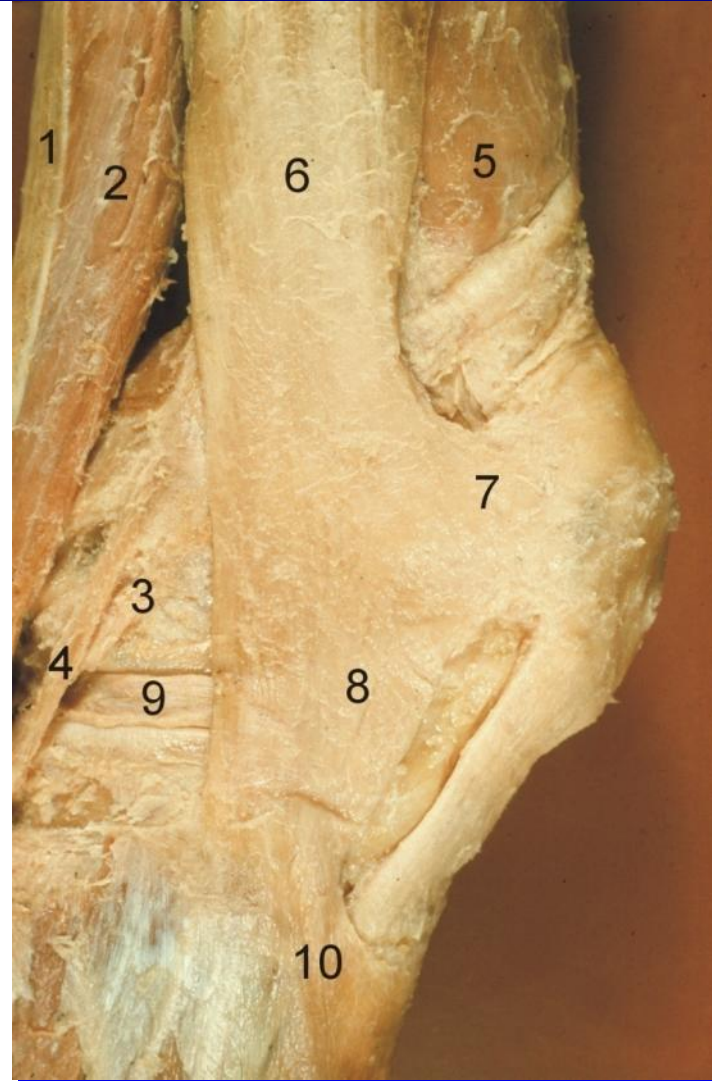
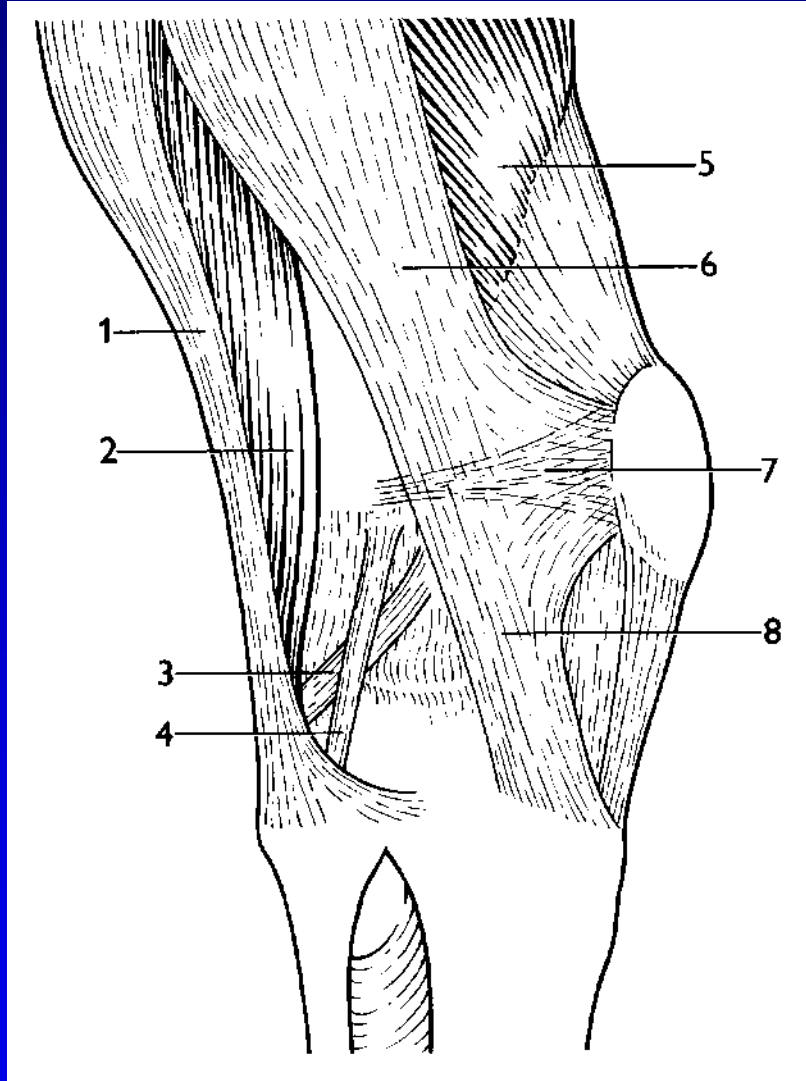
R

# Kapsulární vazy mediální



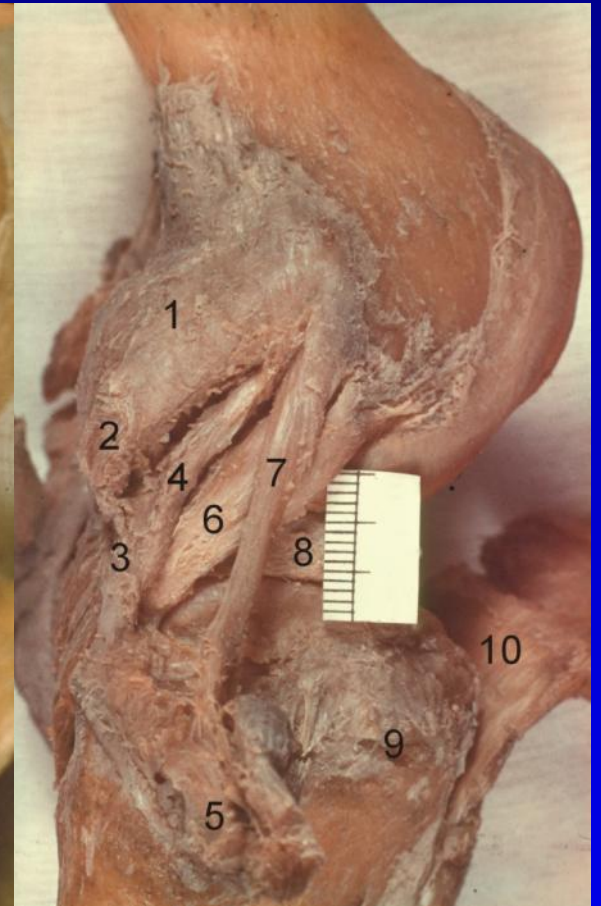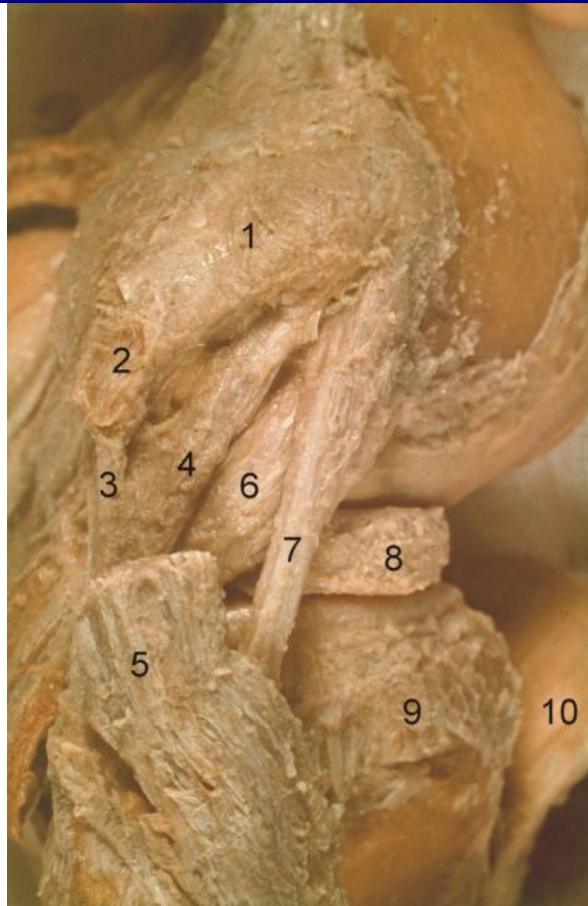
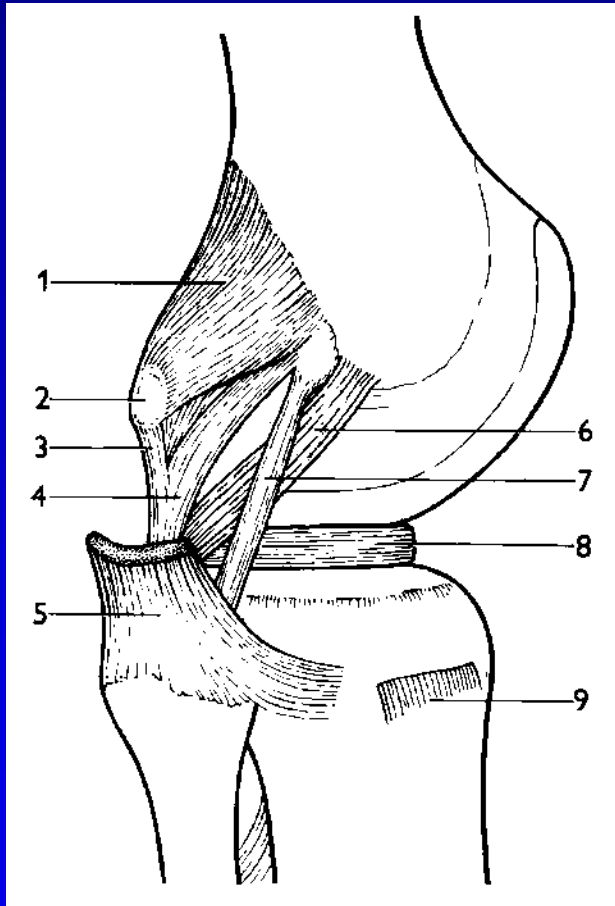


# Kapsulární vazy laterální

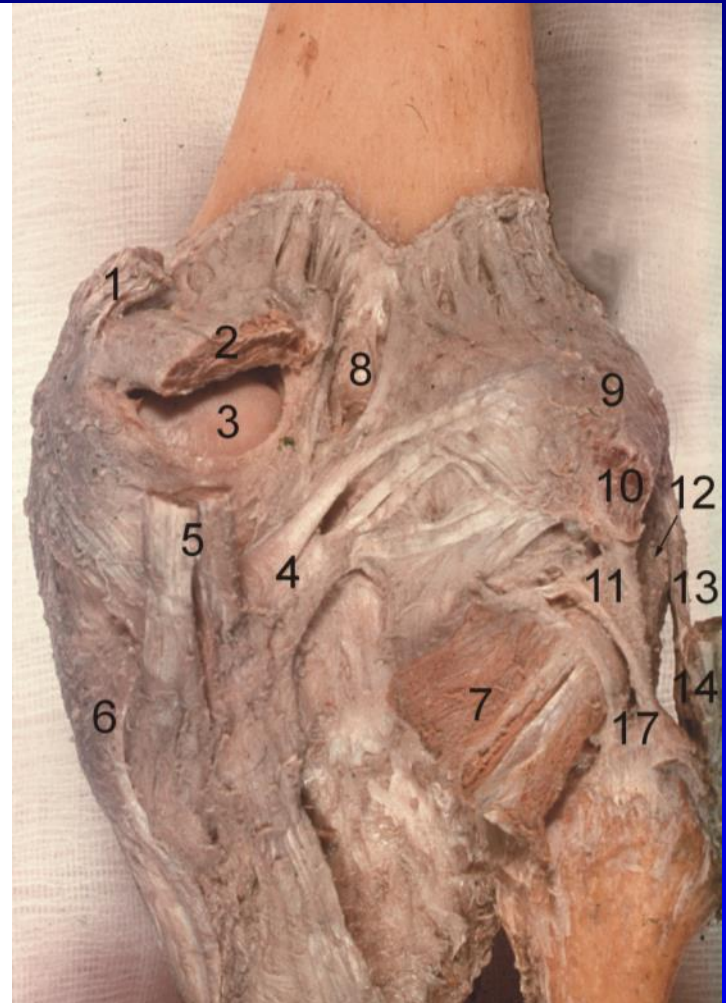
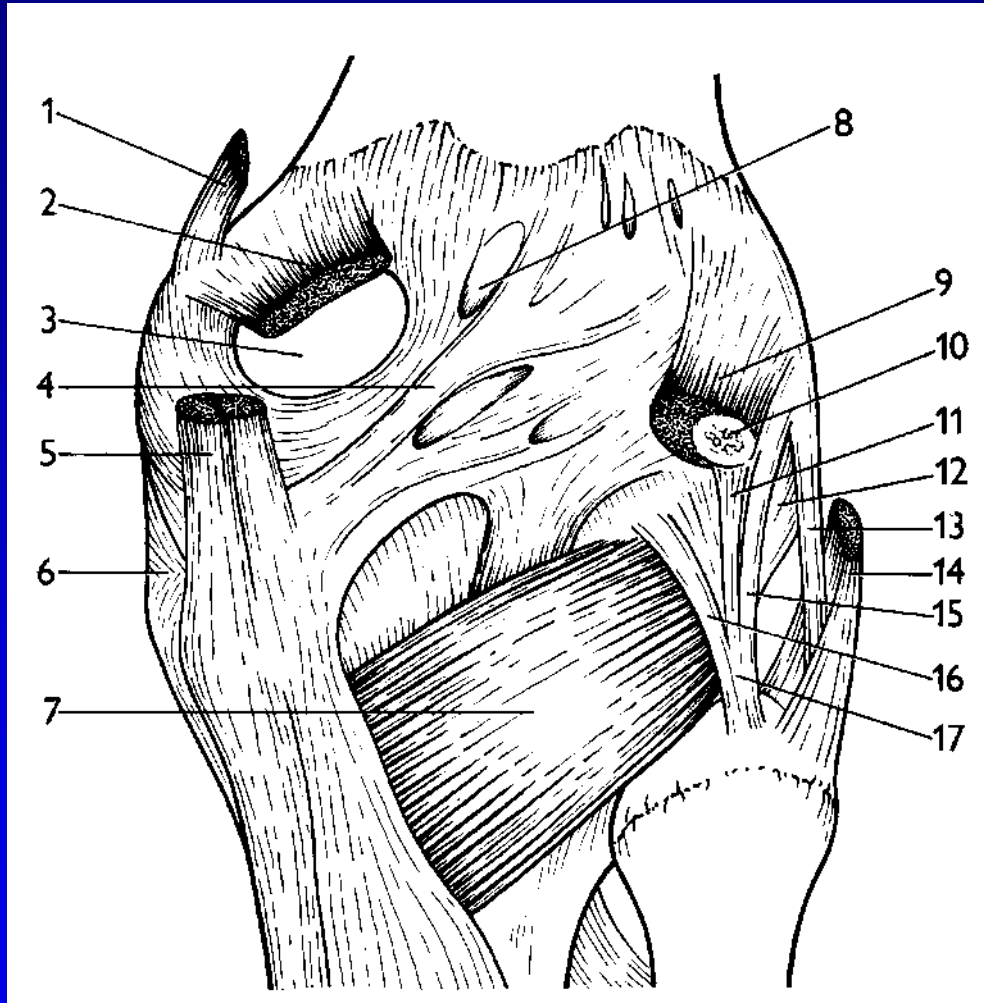




# Kapsulární vazy laterální

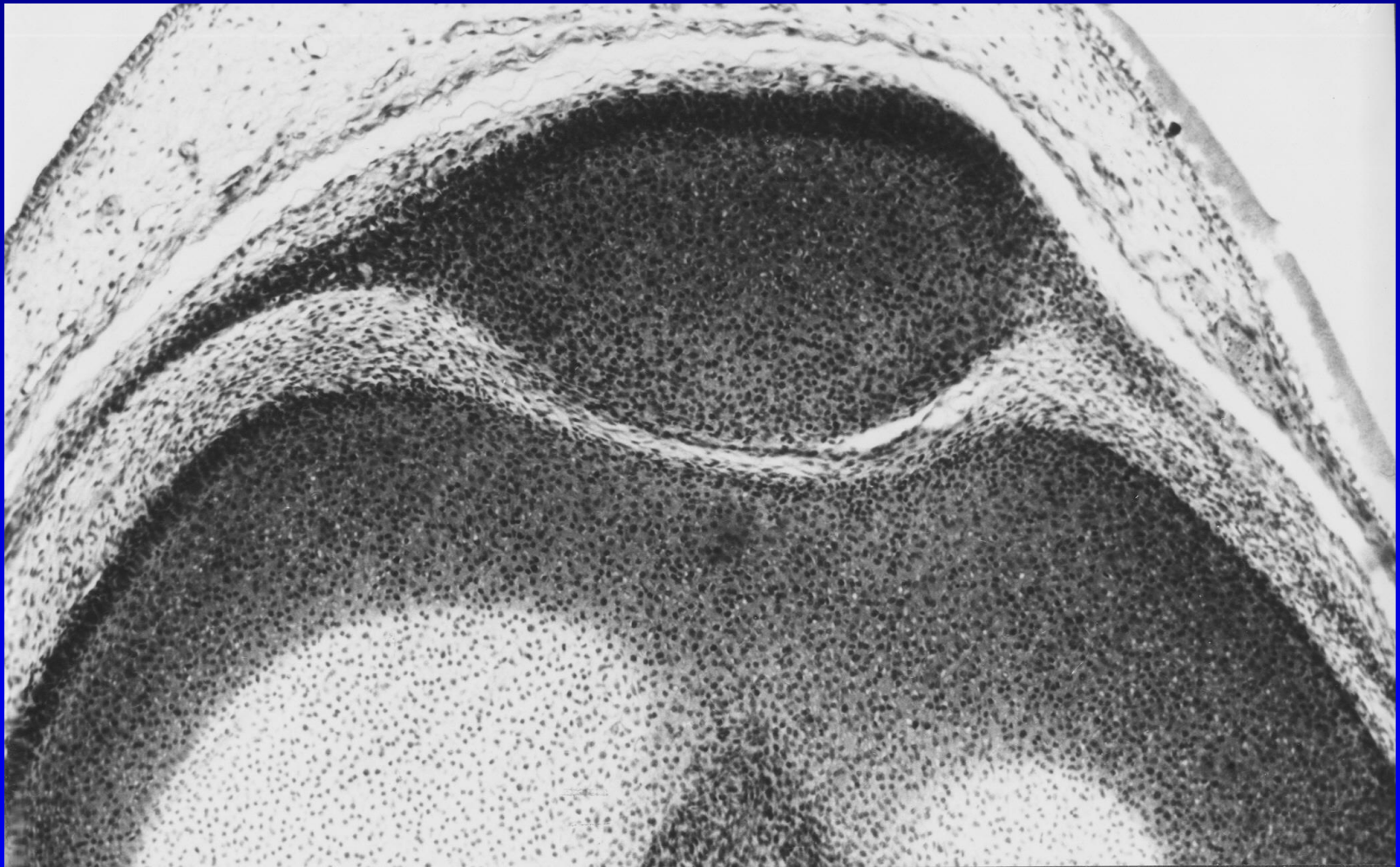


# Kapsulární vazy dorzální





# Retinakula čéšky





# Kloubní dutina

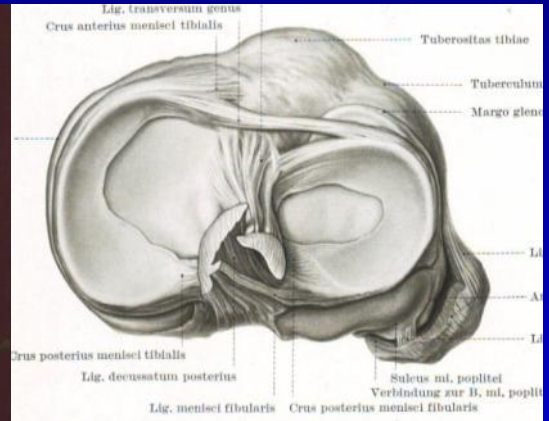
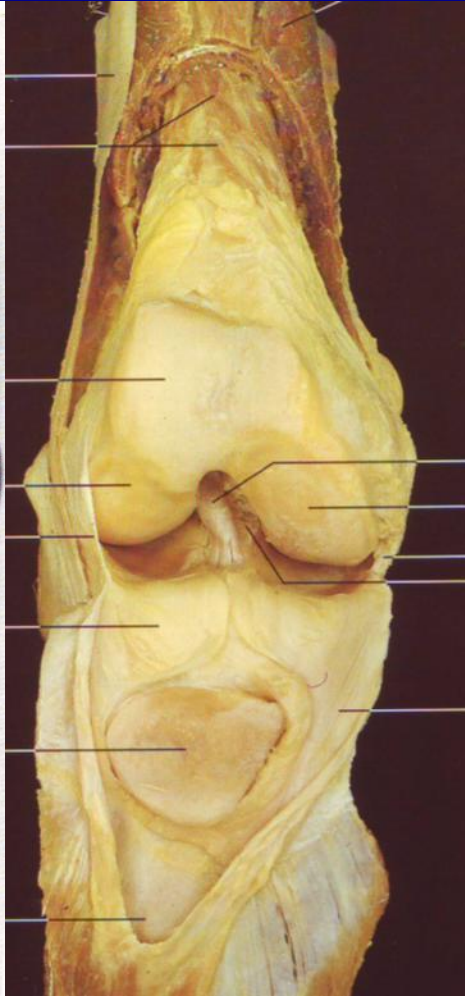
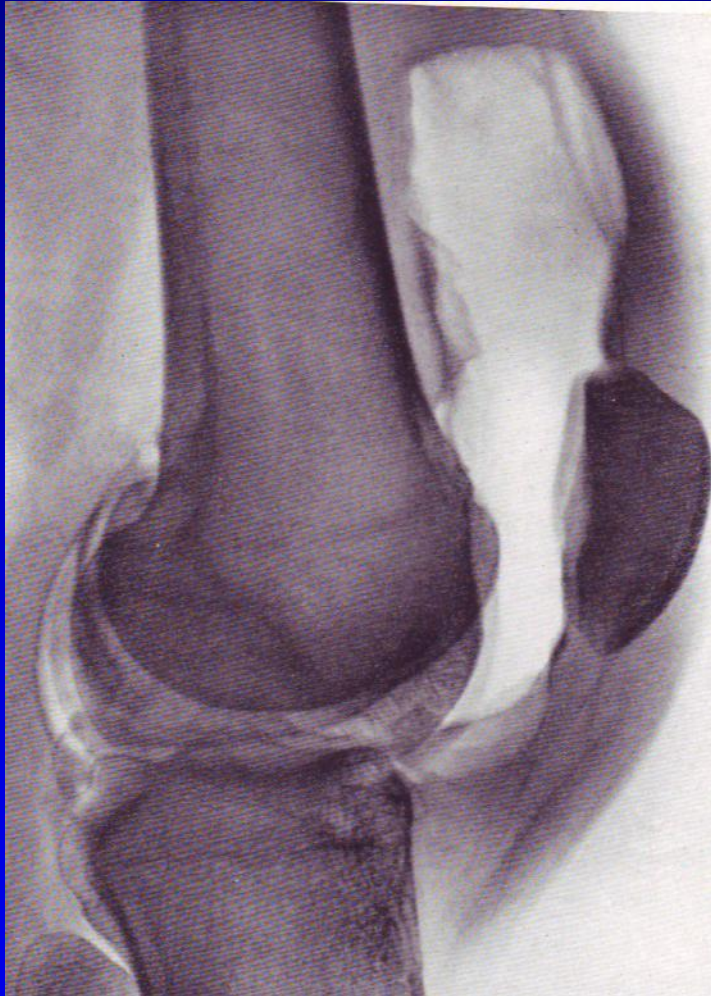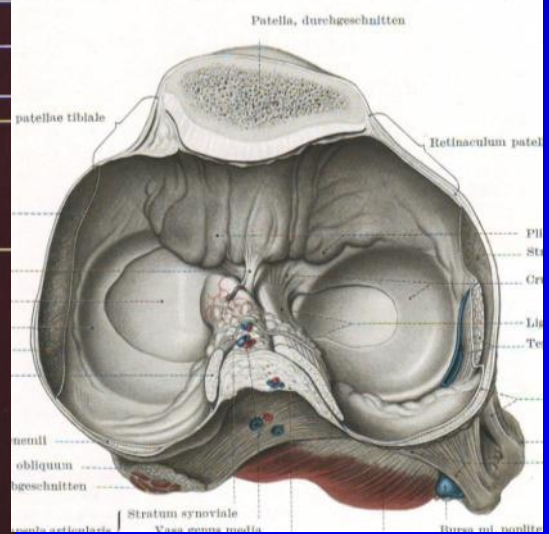

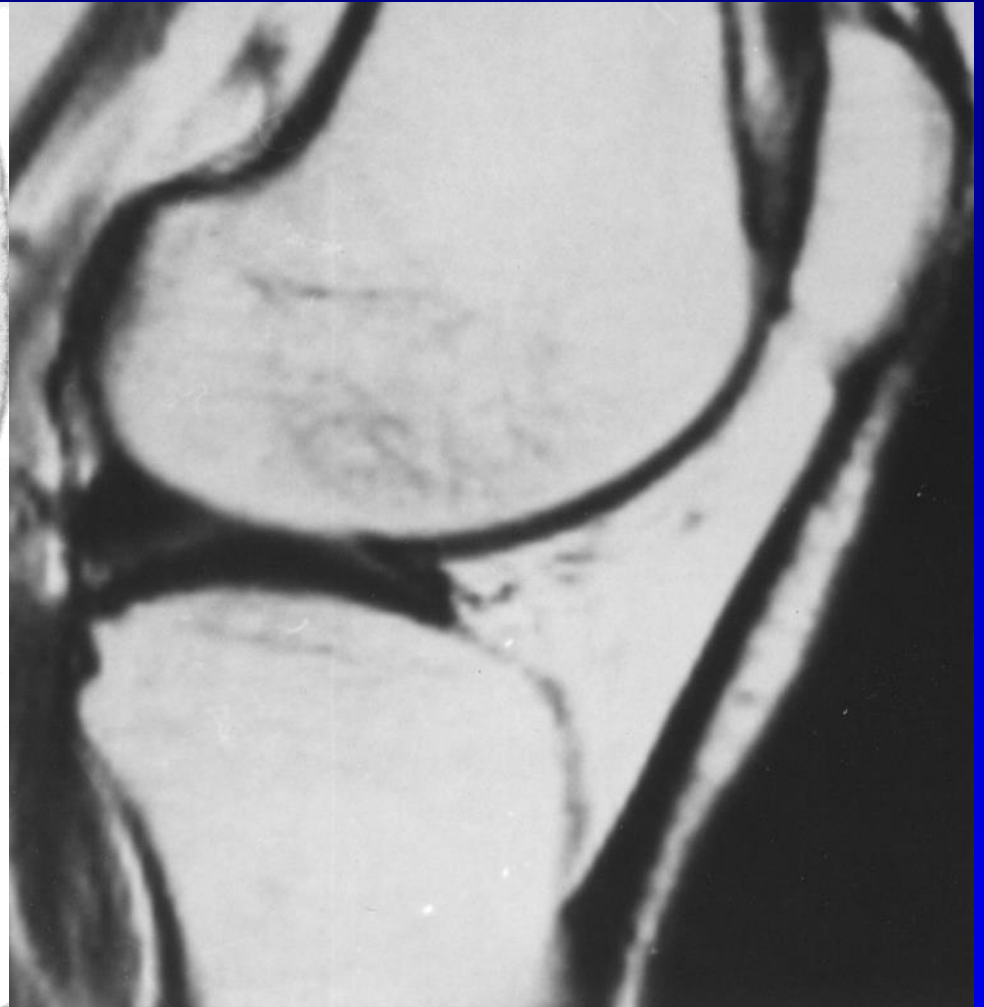
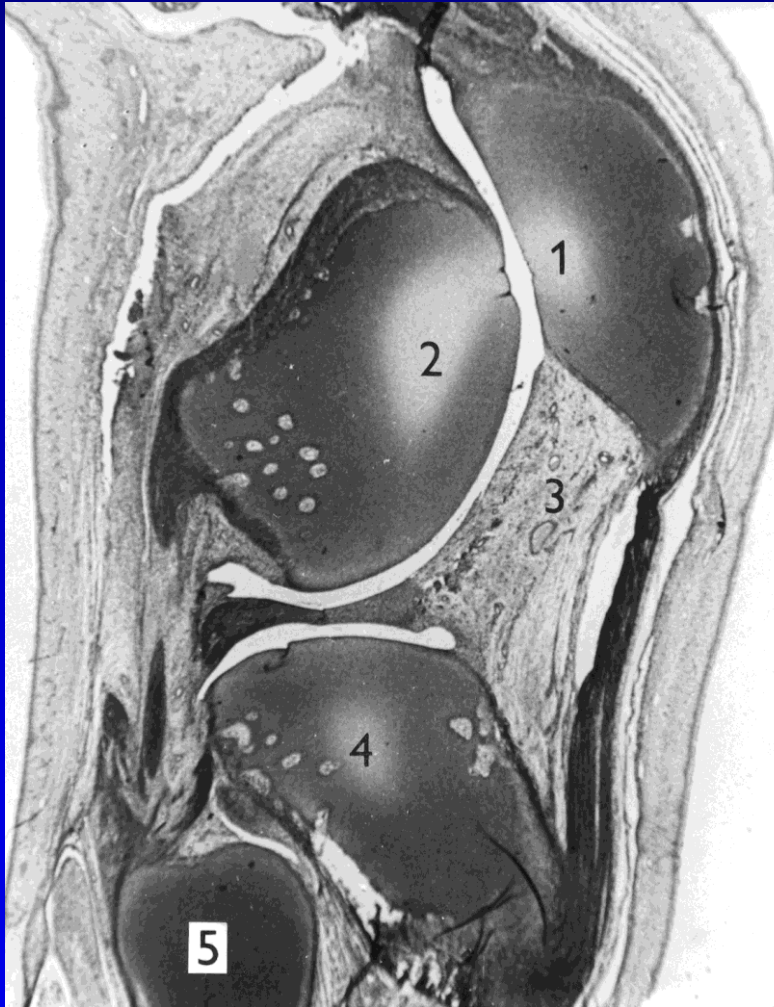Abb. 182. Schienbeinkopf, Menisci und Kreuzbänder von oben.

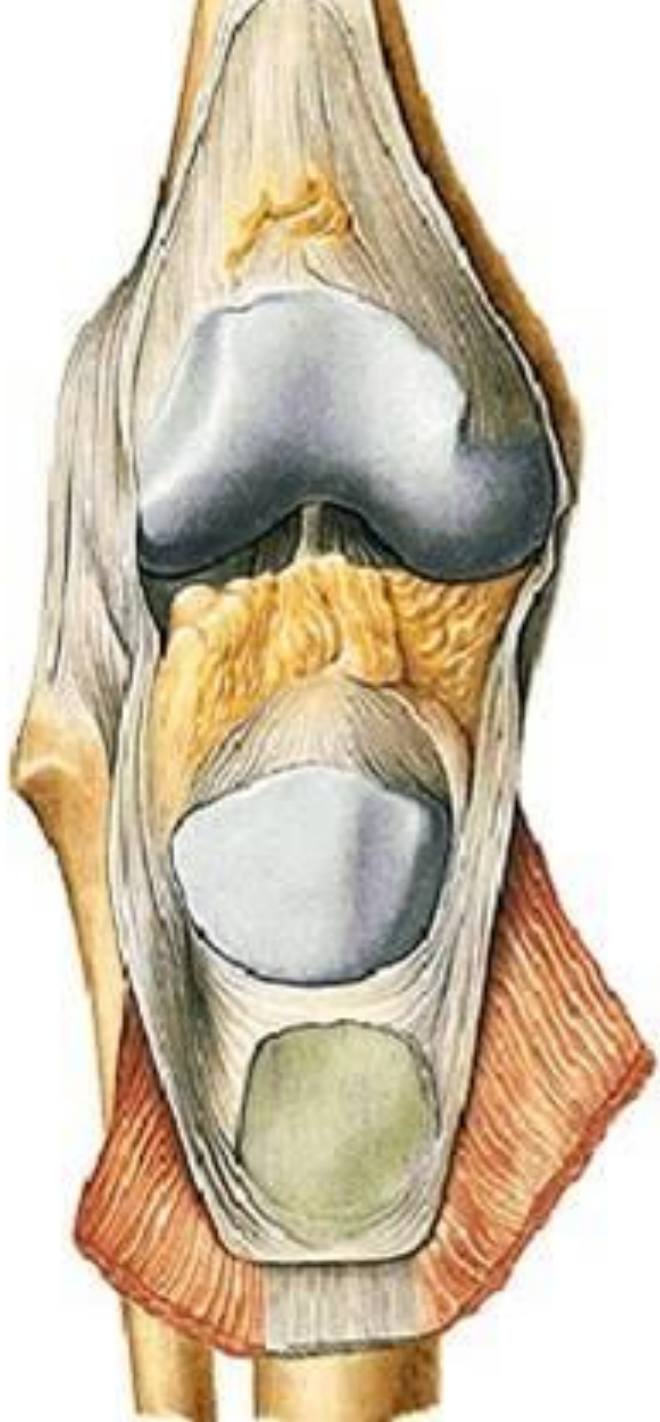


# Kloubní dutina

## Synoviální membrána



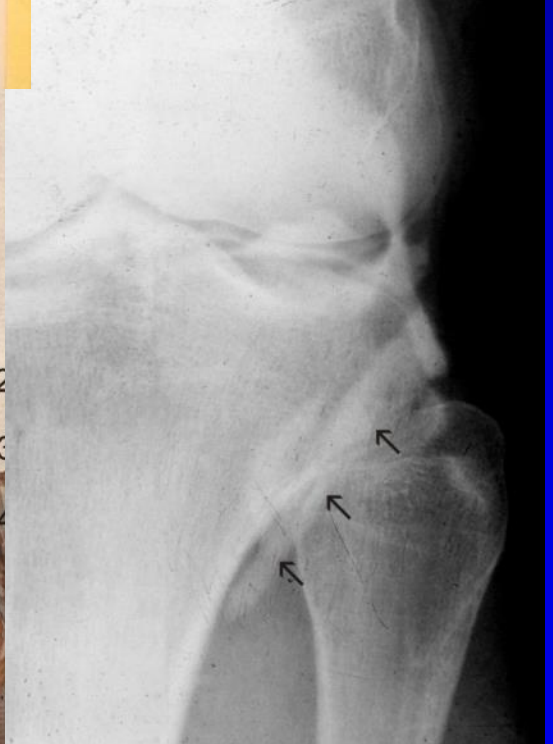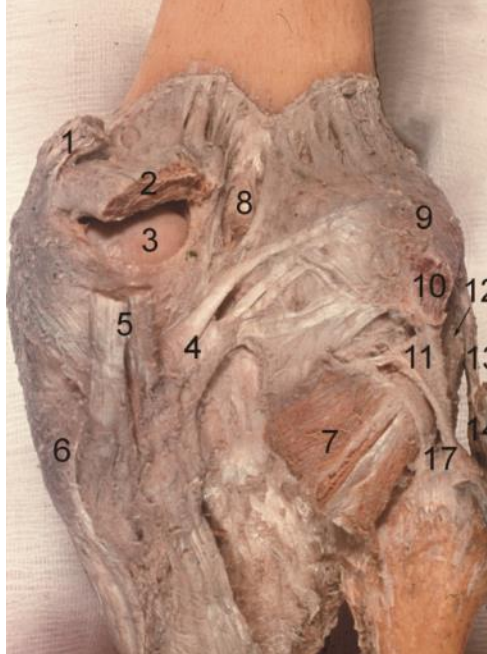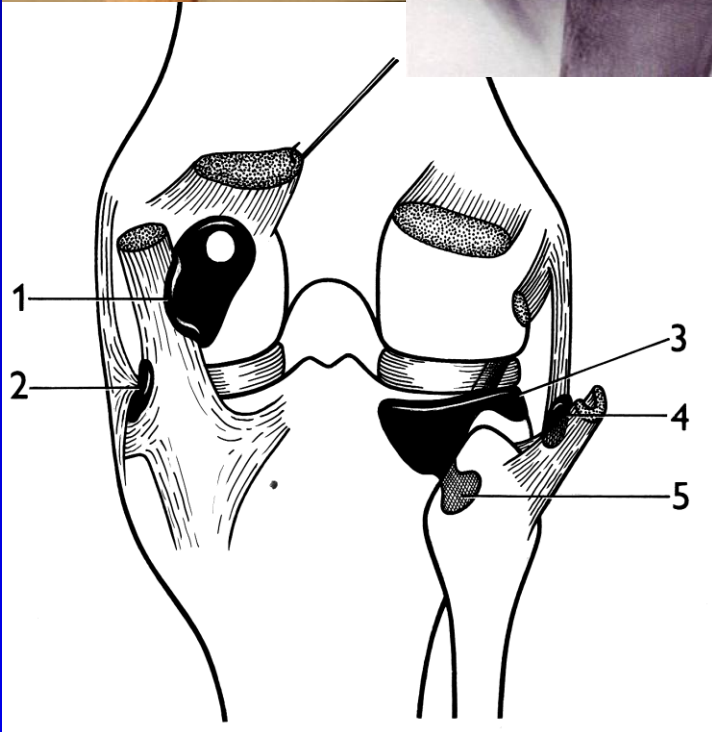
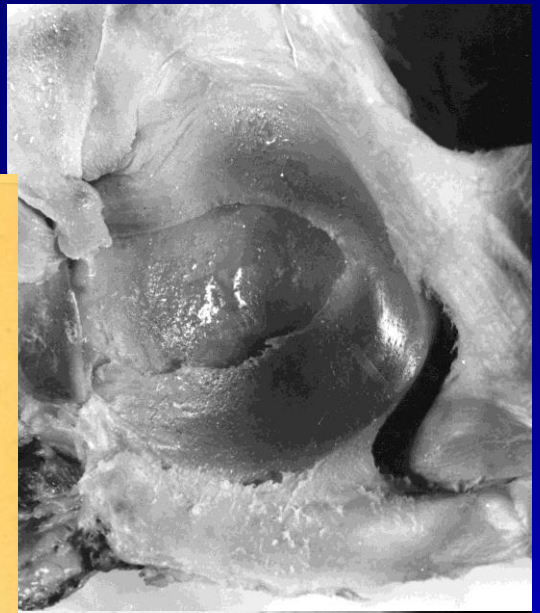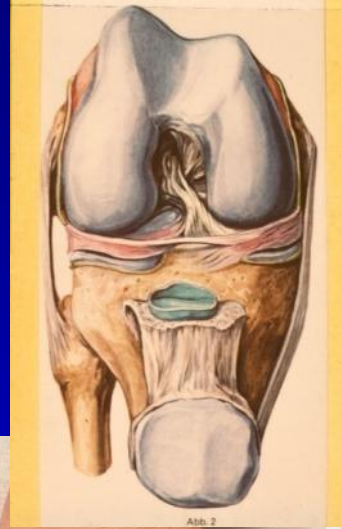
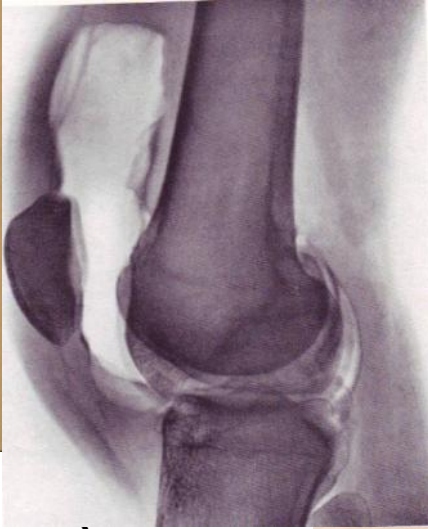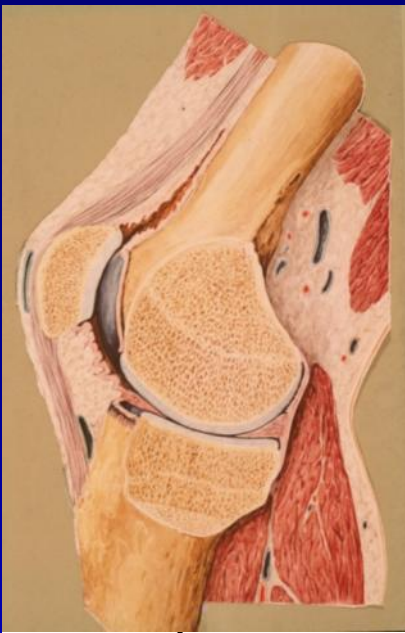


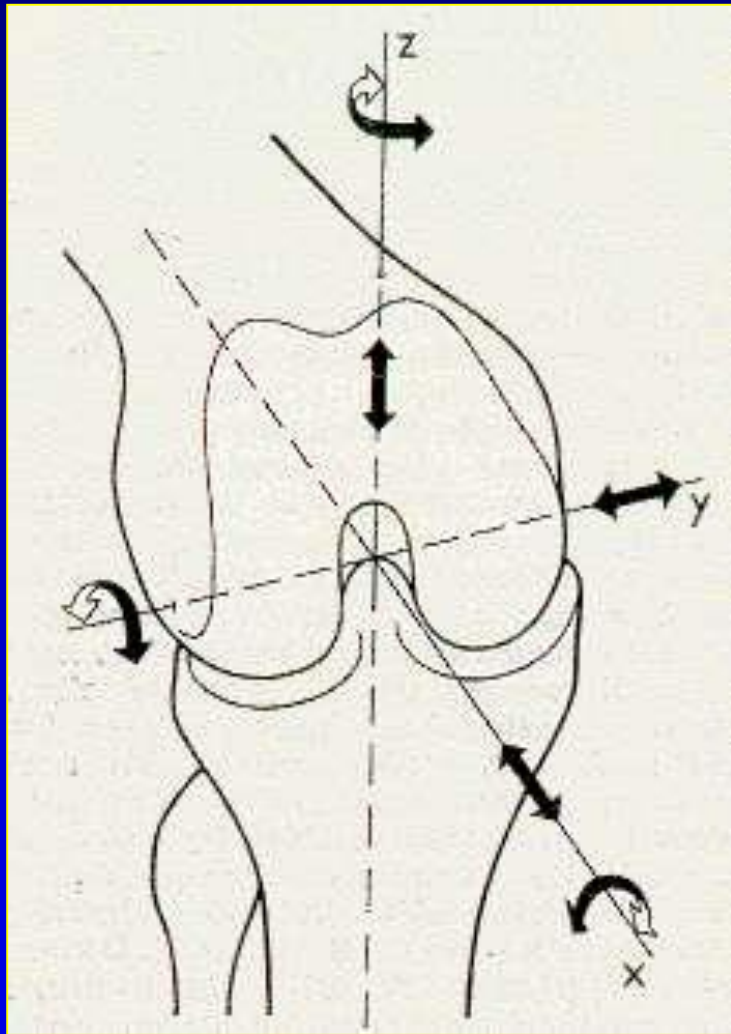


**Corpus adiposum genus  
Hoffovo tukové těleso**



# Burzy





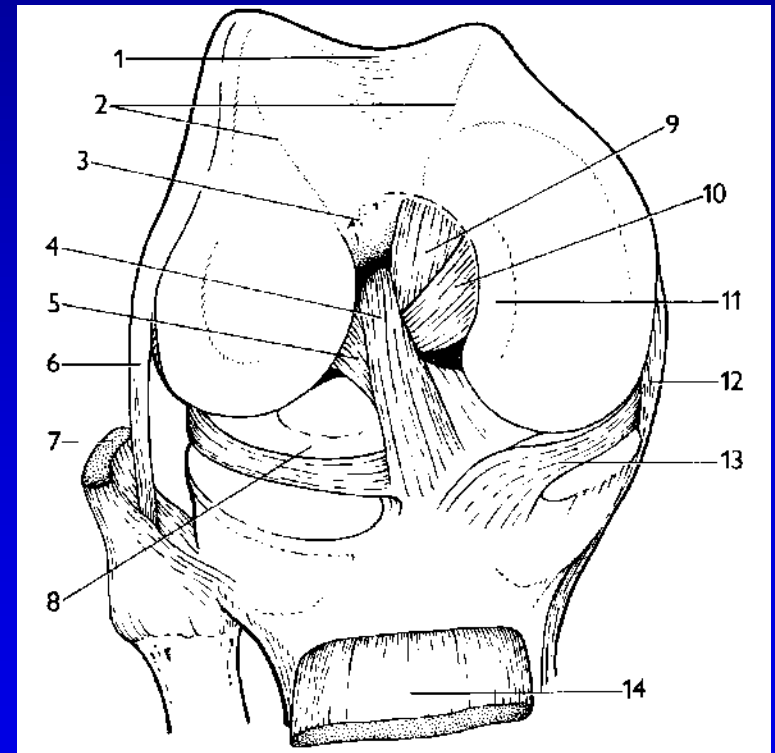
## Pohyby flexe/extense - 4 fáze:

1. počáteční rotace  
(odemknutí kolena)
2. valivý pohyb
3. posuvný pohyb
4. závěrečná rotace  
(uzamčení kolena)

rotace – vnitřní/zevní

# Základní pensum

- Složený kloub tvořený F, P a T.
- Dva zkřížené vazy
- Dva menisky
- Dva postranní vazy



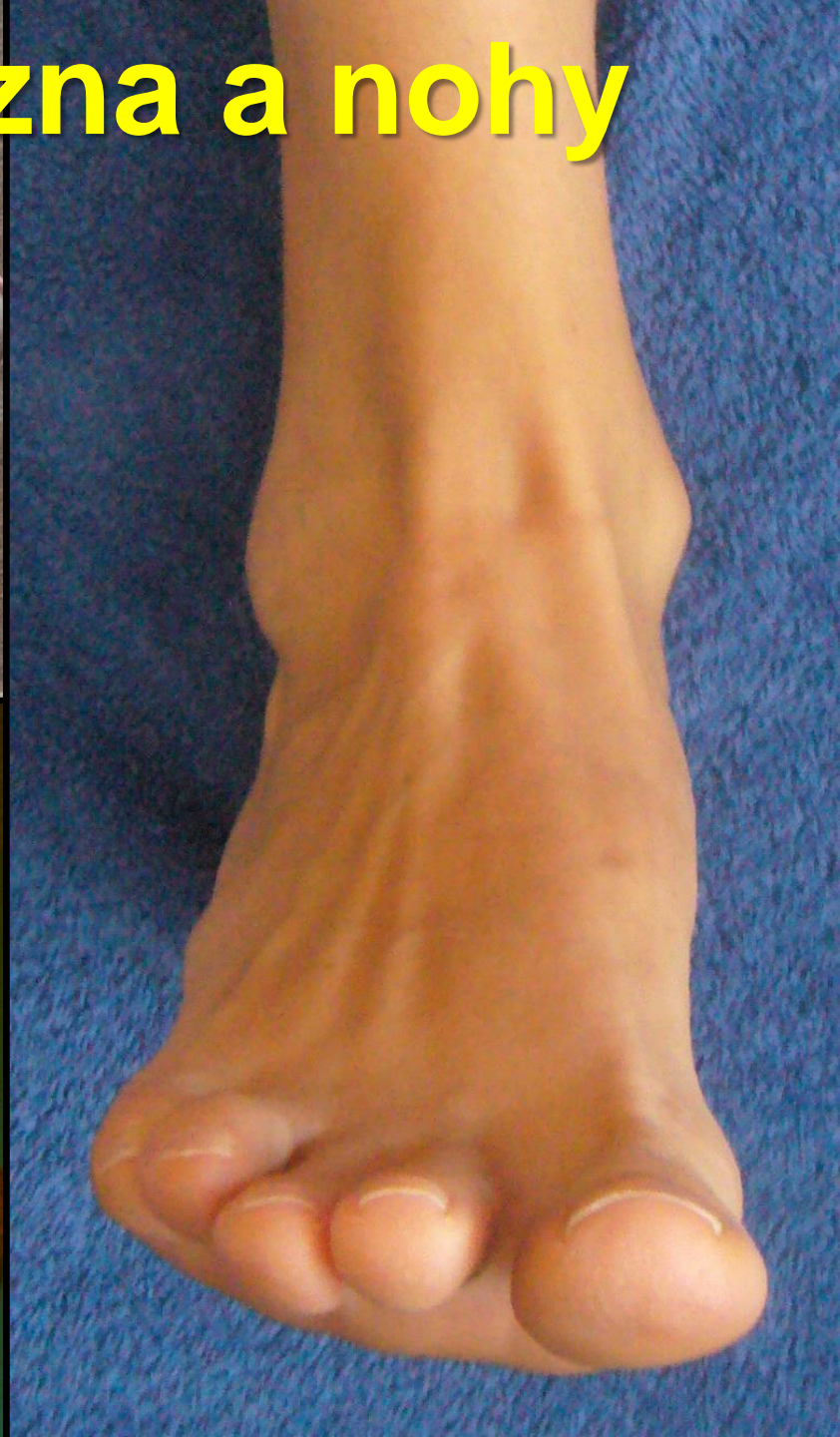
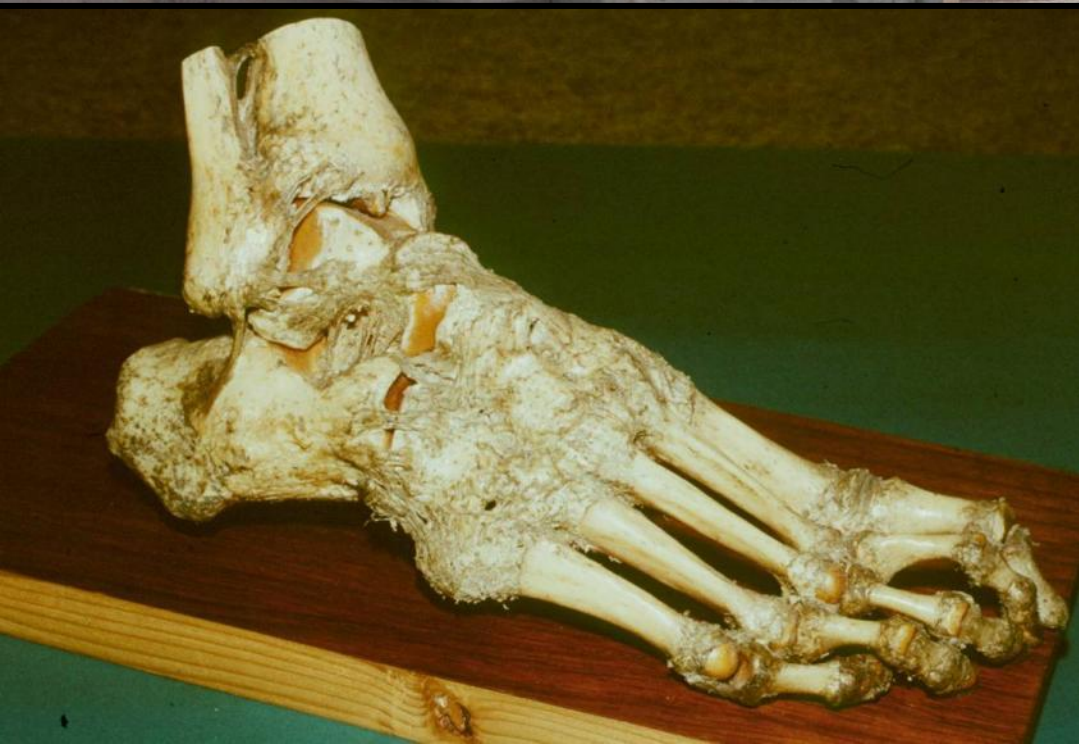
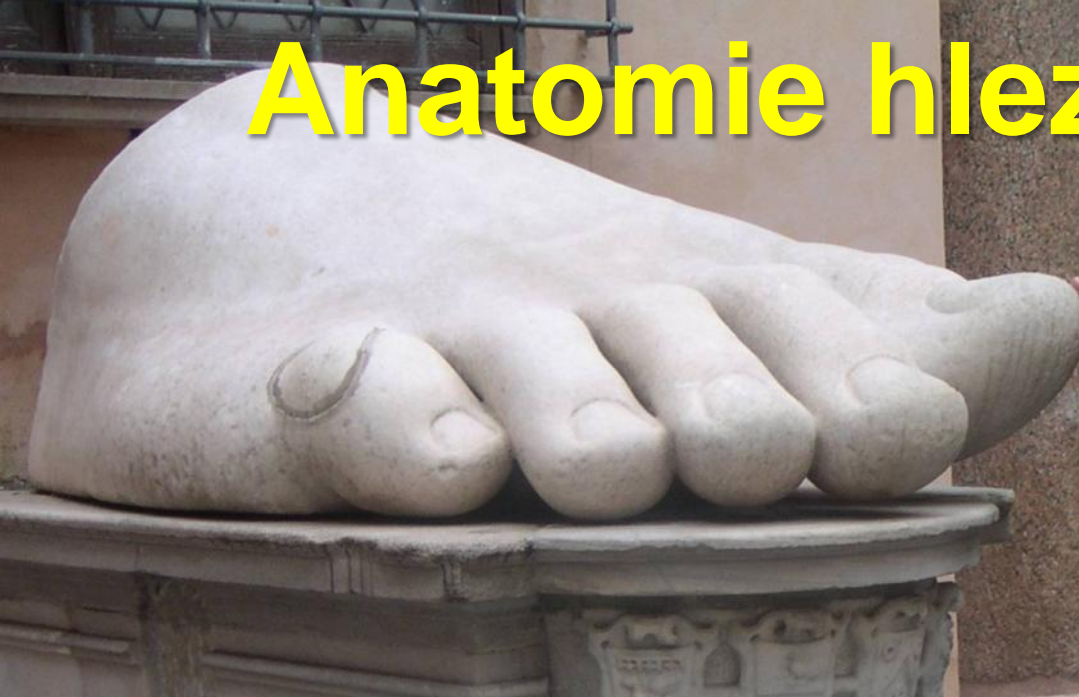Beinbrüchig schädlich als vberbrüch  
Wie diesem instrument auch sich  
Nachen und schmerzen lond sein 1717  
Endigend in sein gband mehr legt



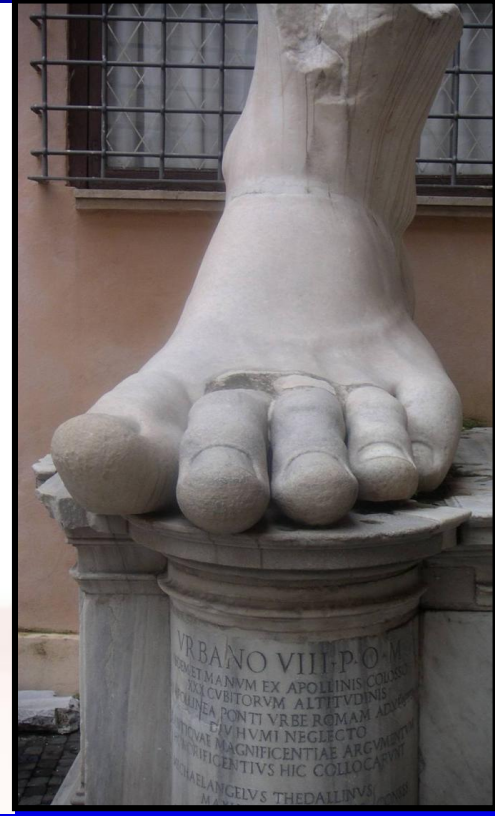
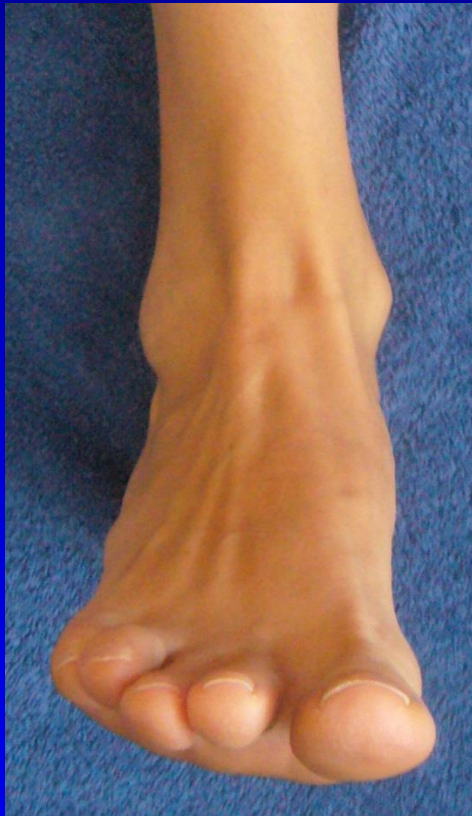
# Anatomie hlezna a nohy



# J. W. Goethe

Krásná noha je darem přírody.

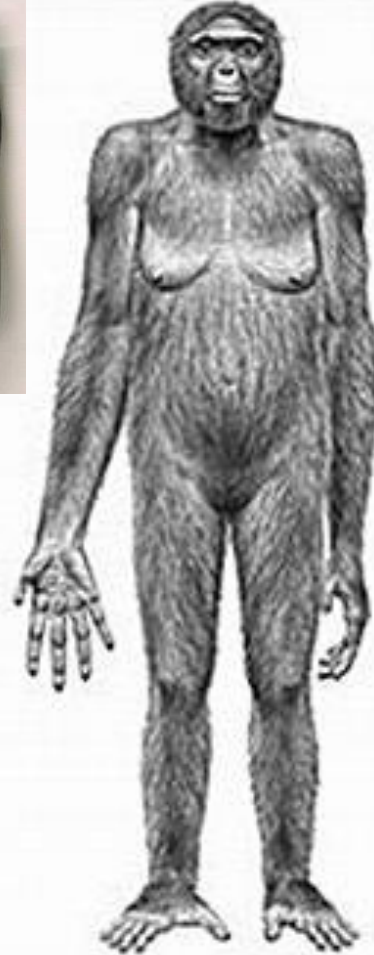
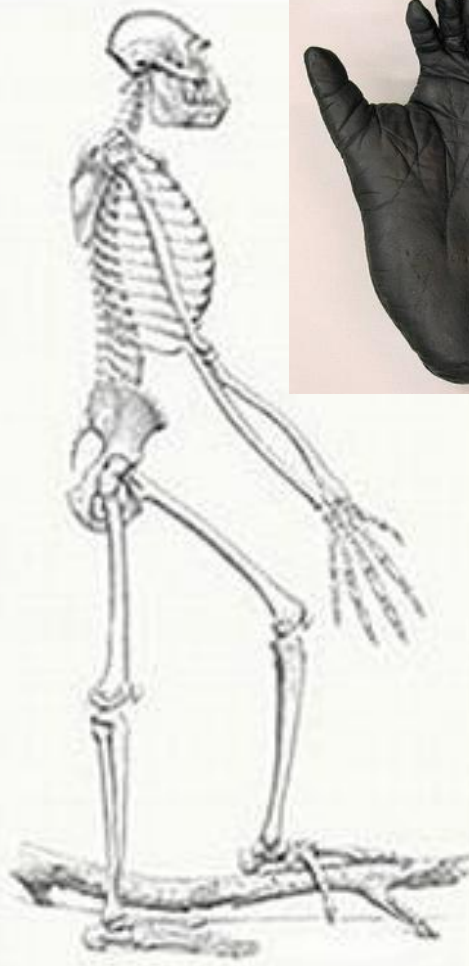
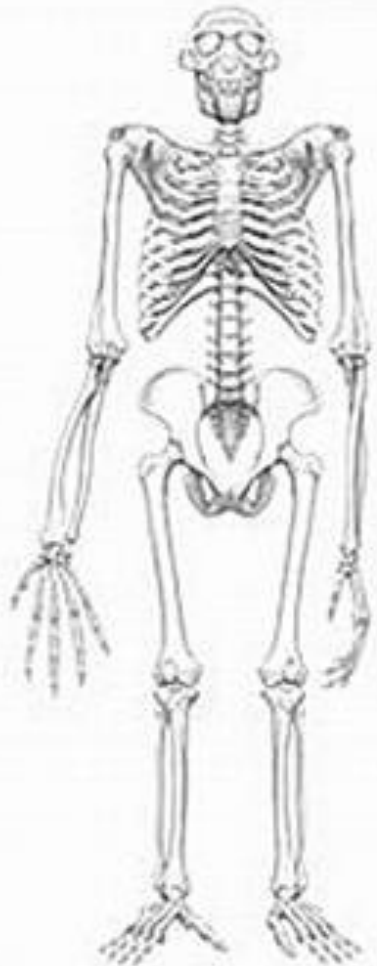


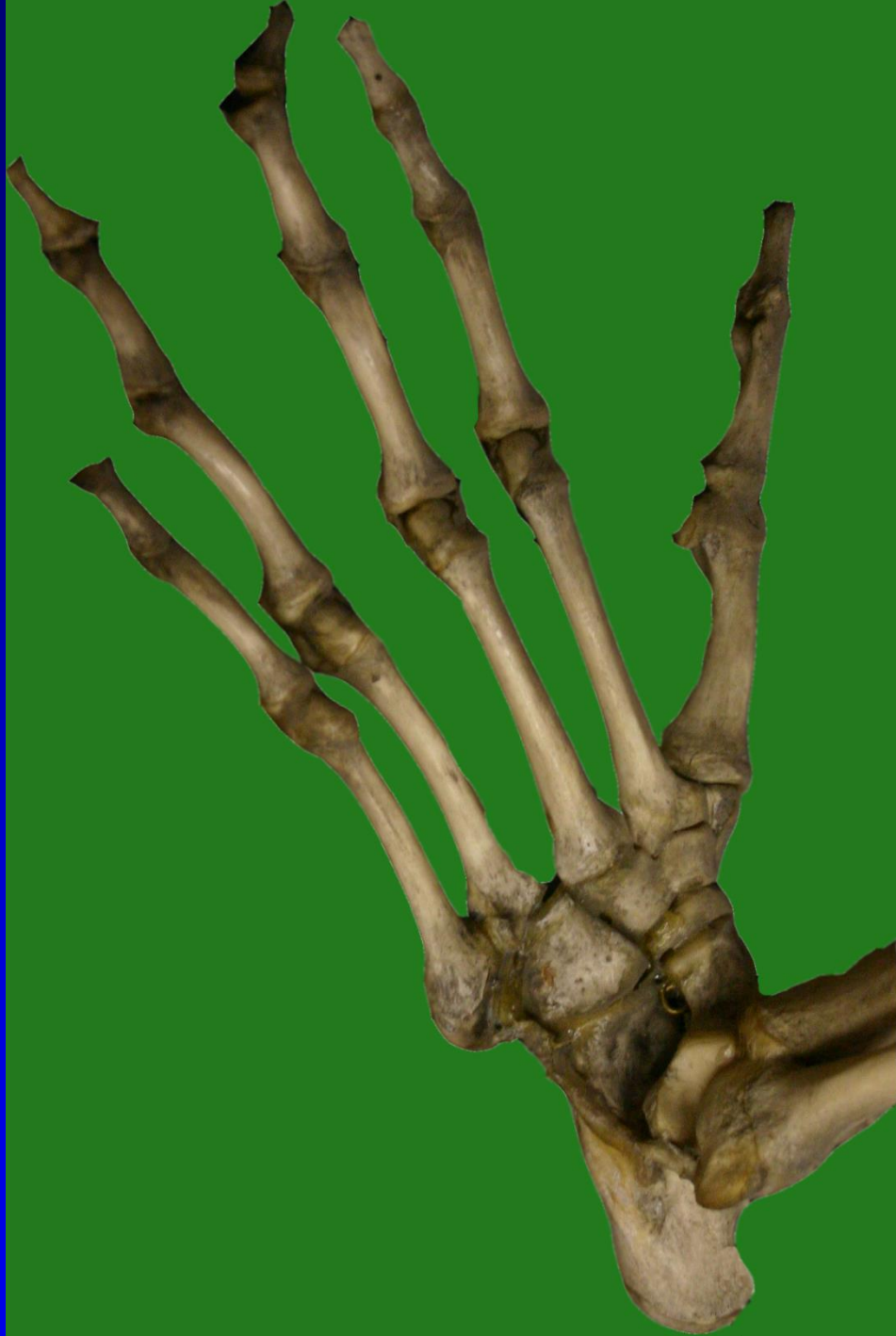



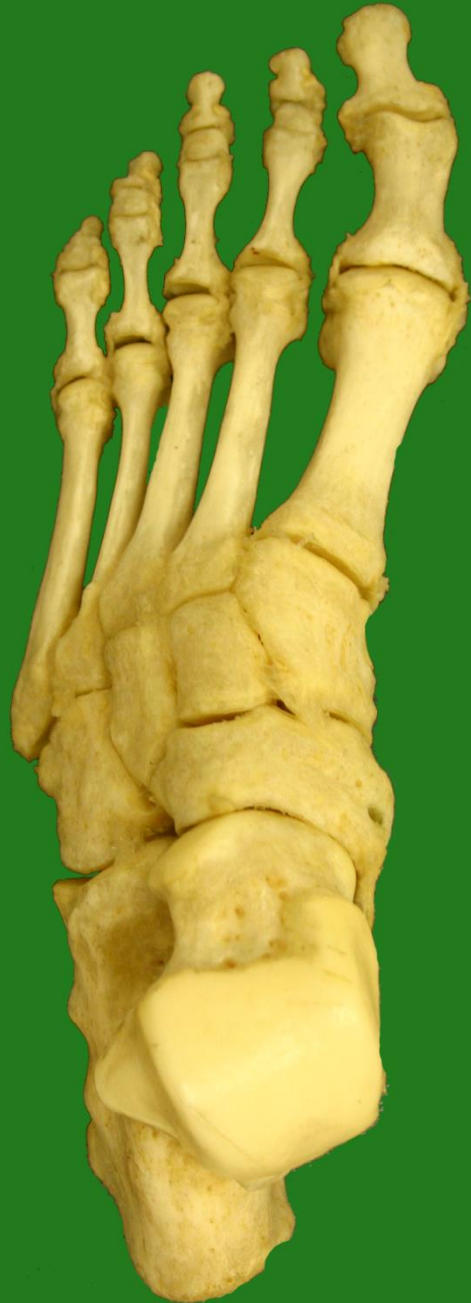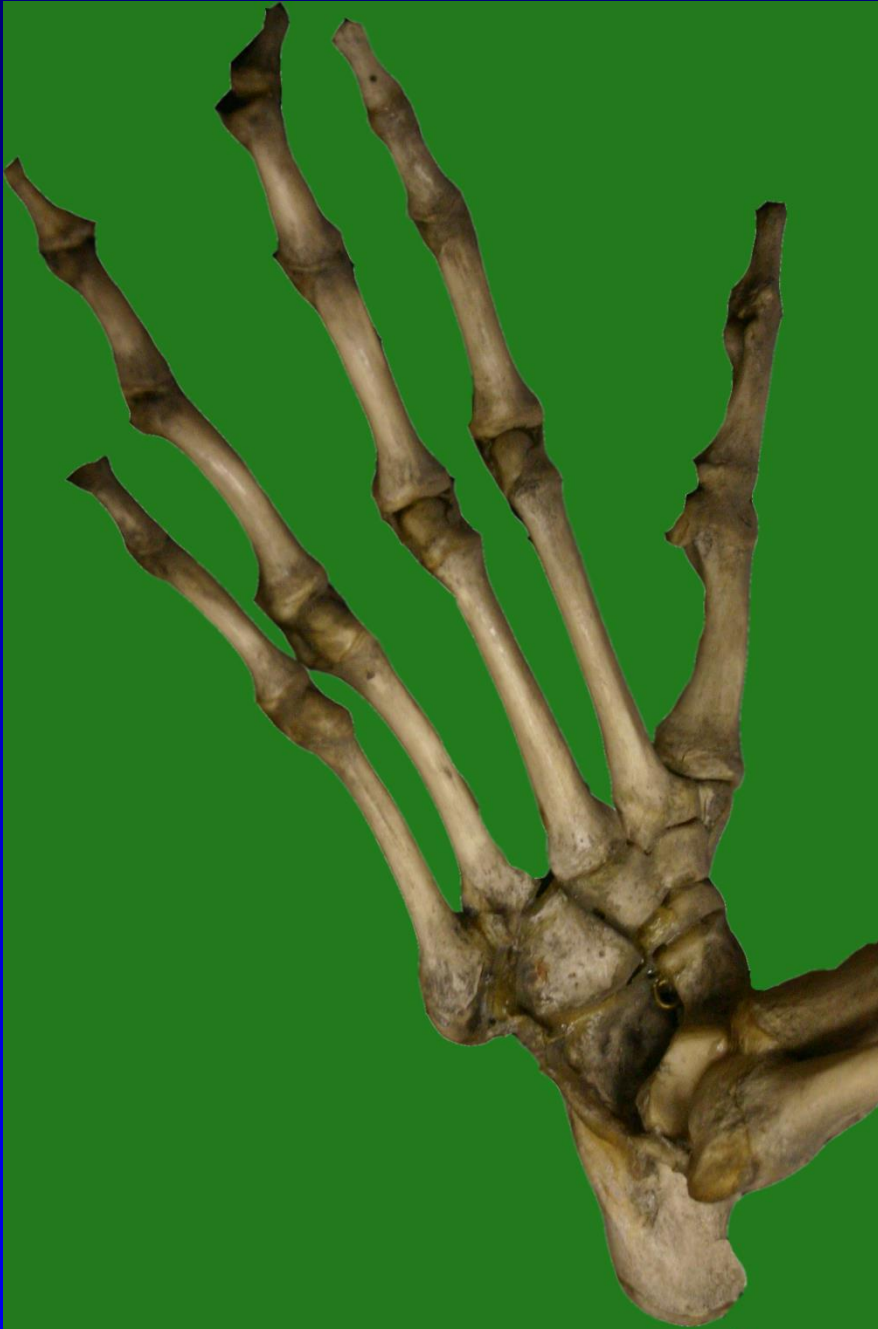# Ztráta opozice palce nohy významný krok v hominizaci našich předků





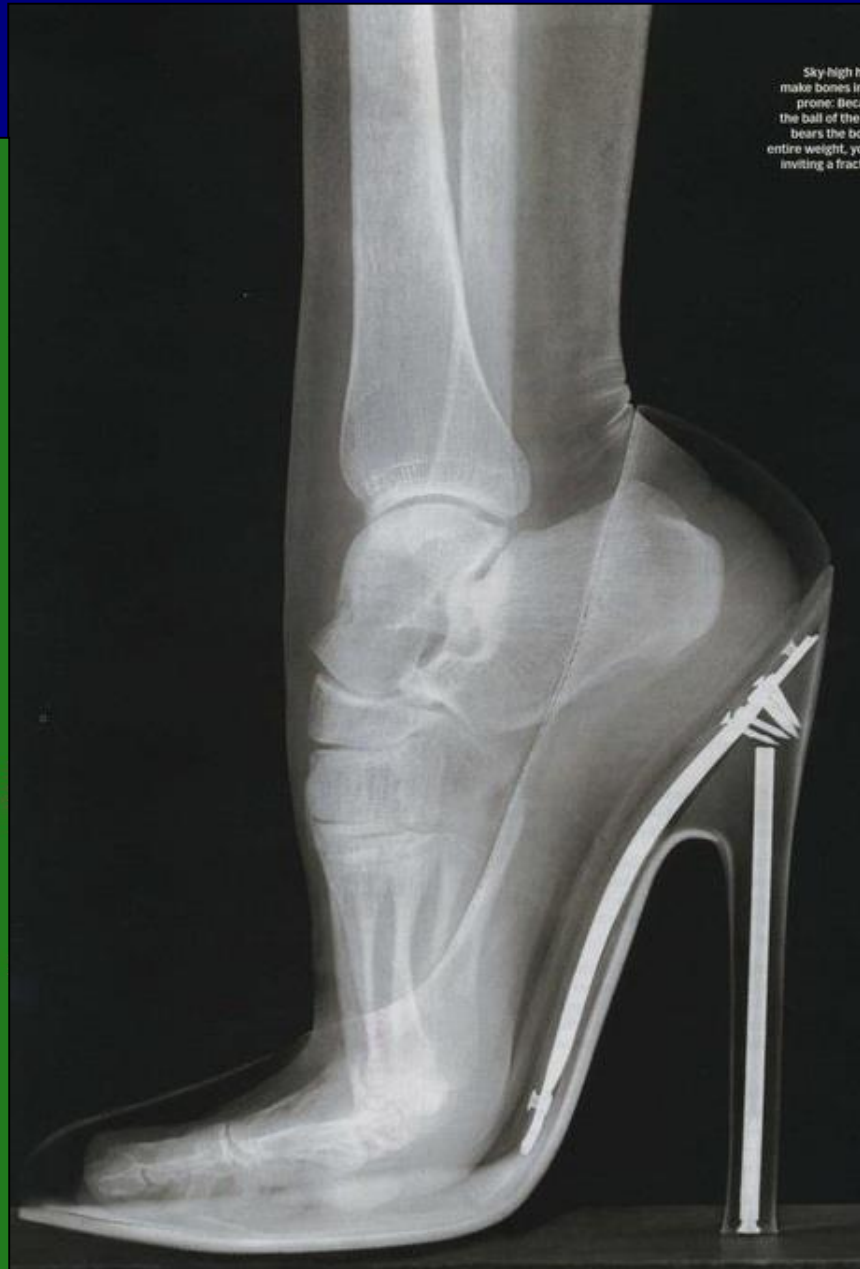
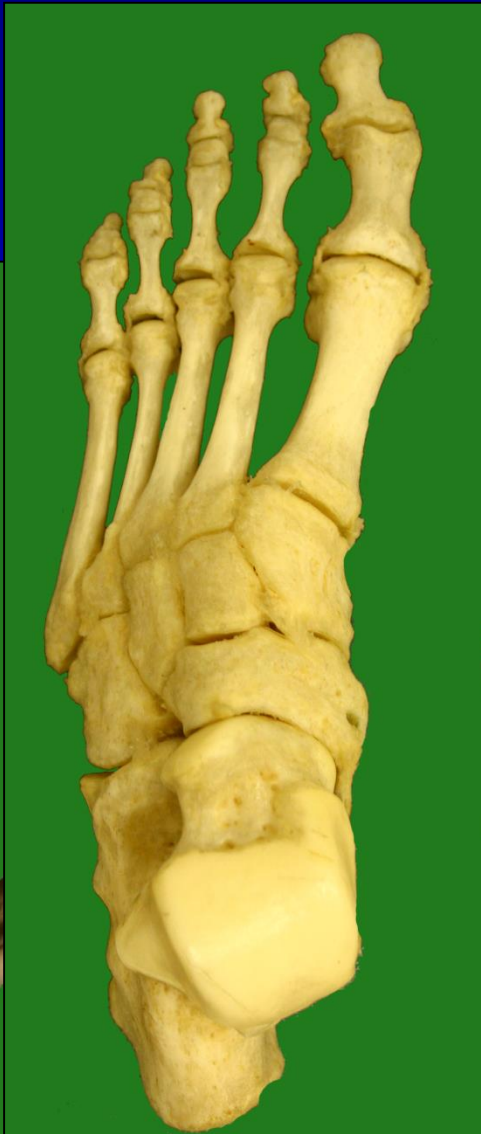
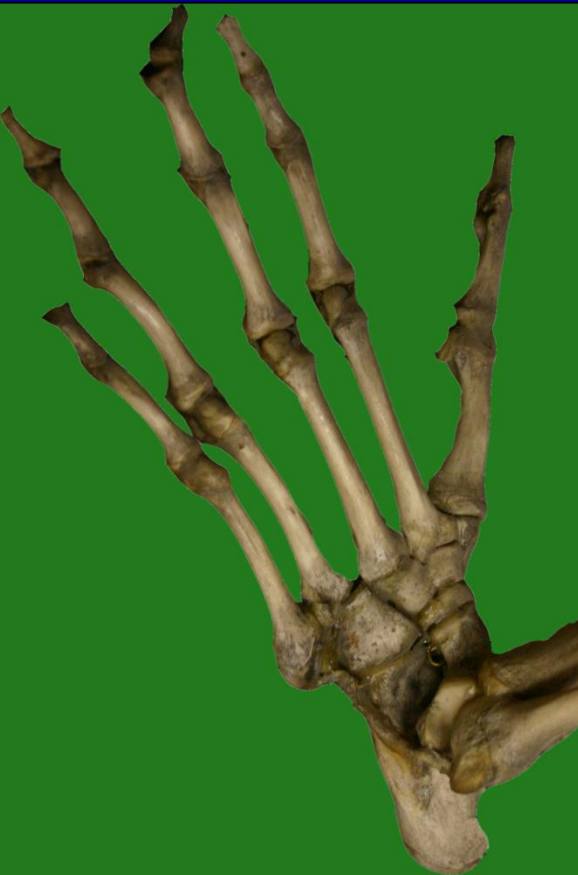

**ŽENA**

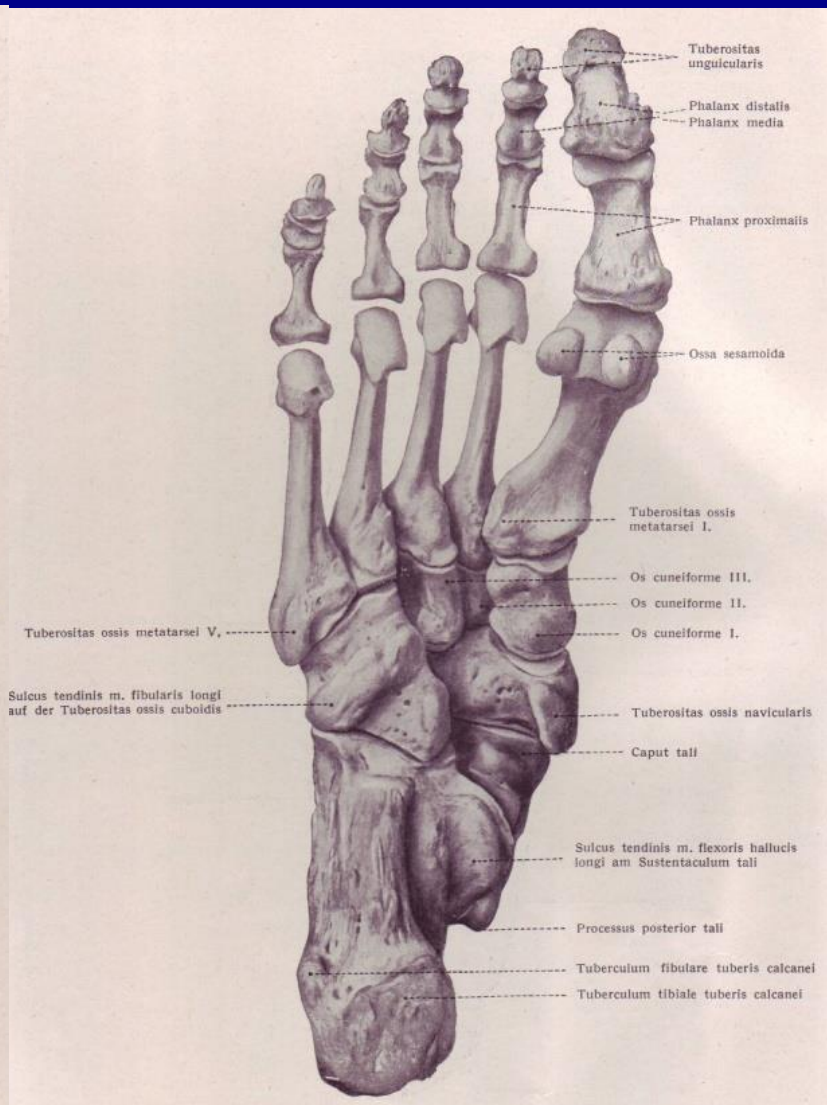
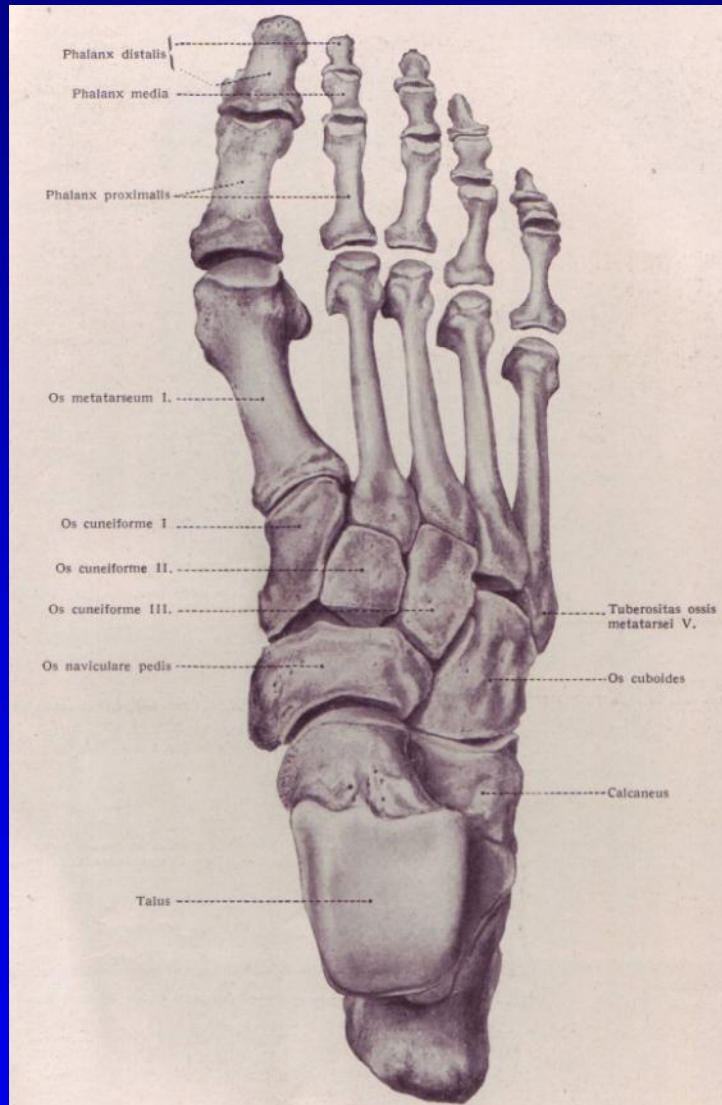
**MUŽ**

**ŠIMPANZ**

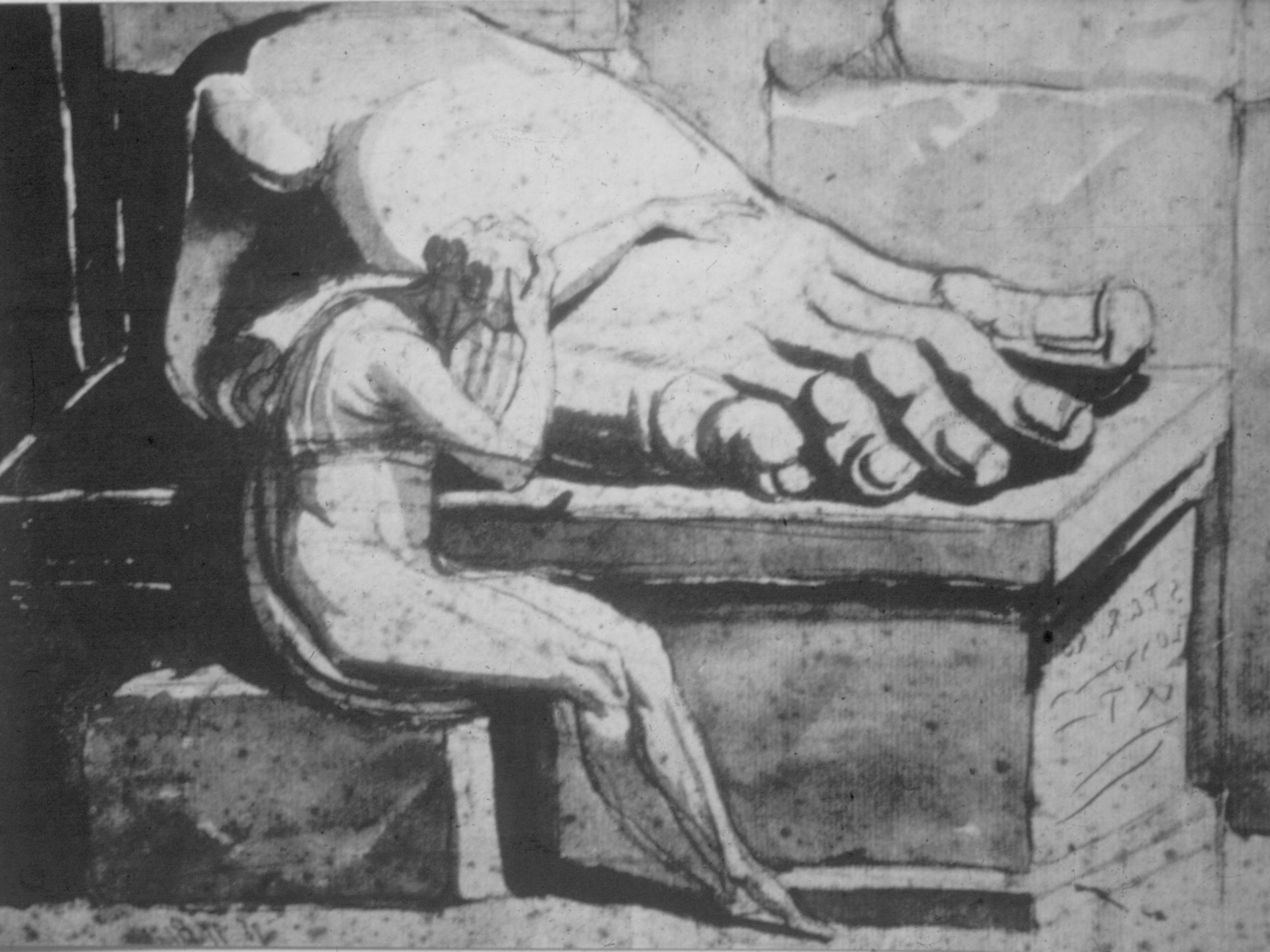


# Skelet nohy a hlezna

## 30 kostí





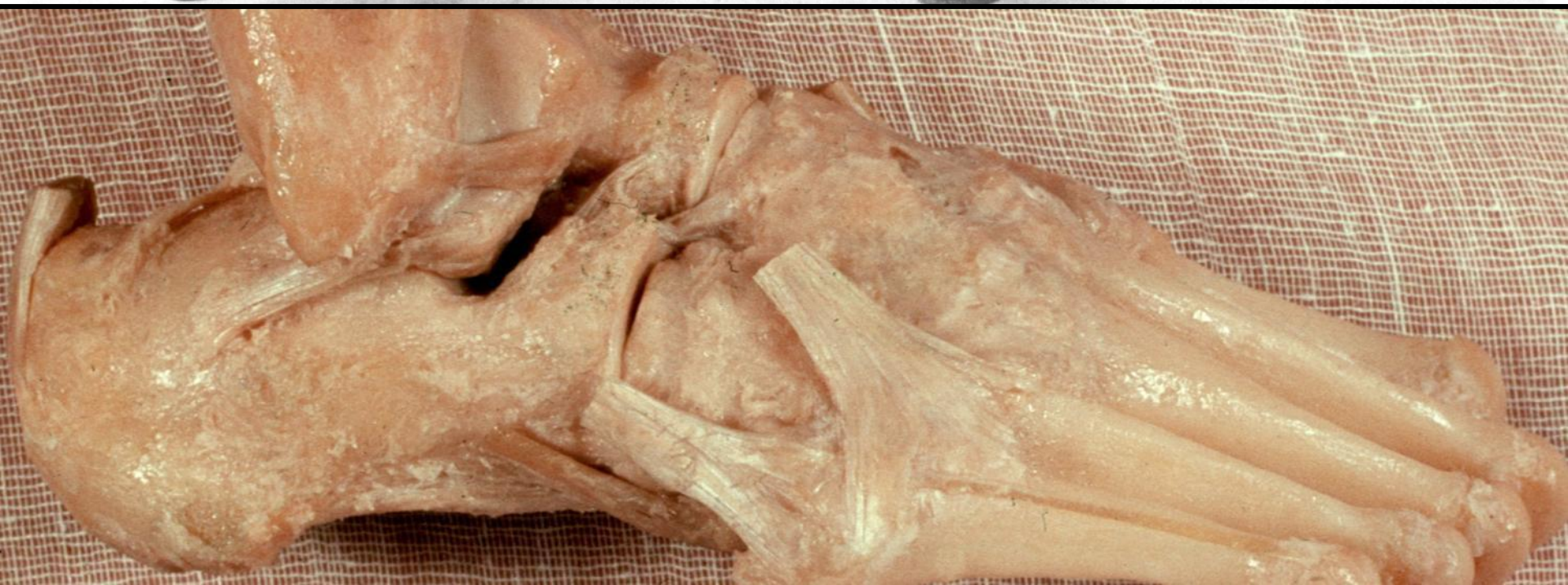

**Hlezno**

**Lisfranc Jacques 1790-1847**

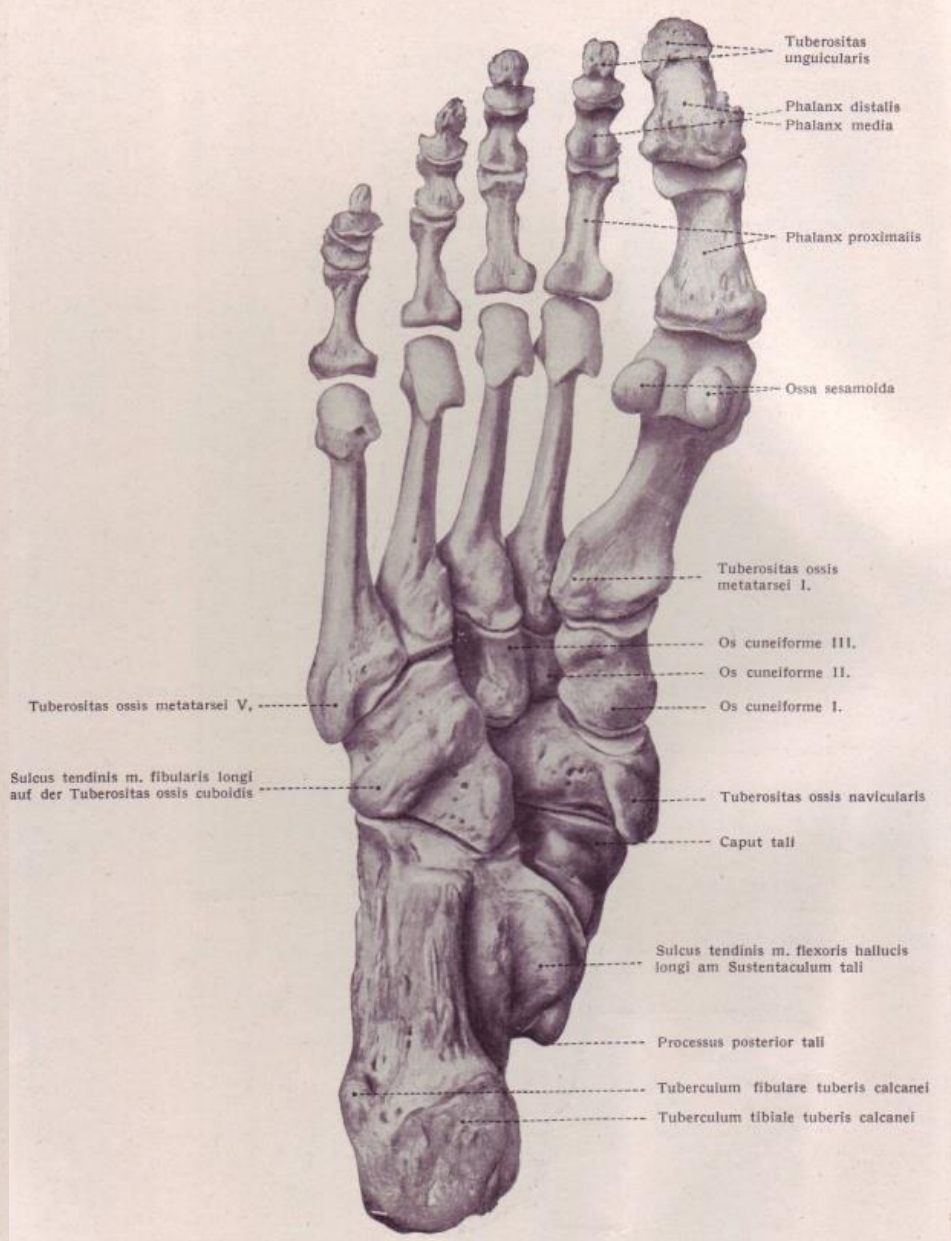
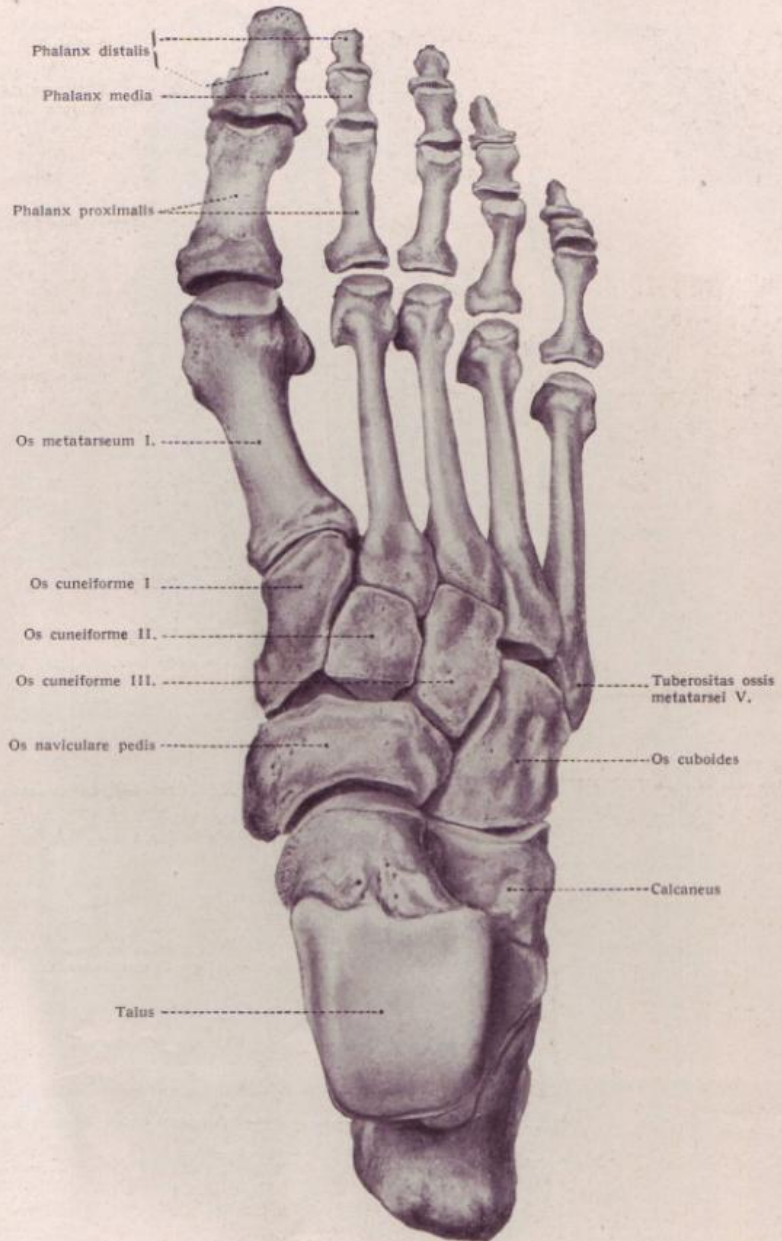
**Subtalární kloub**

**Chopart Francois 1743-1795**

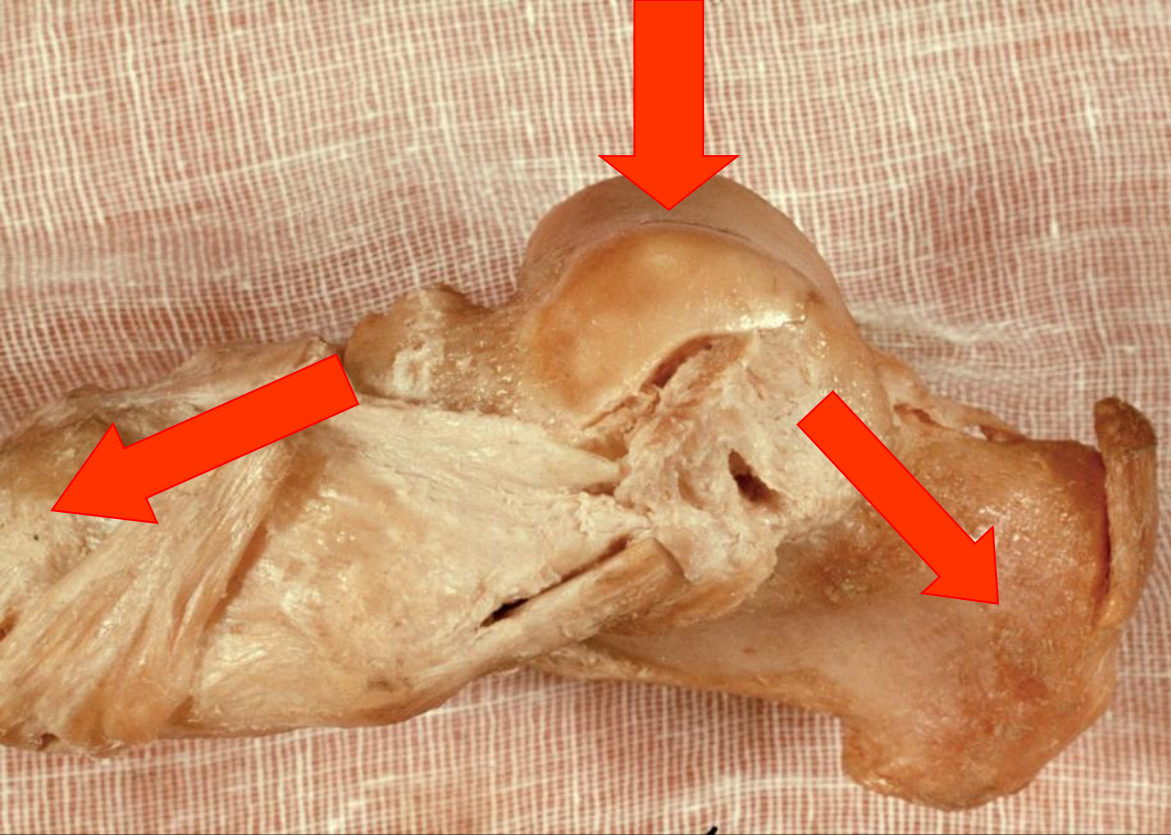




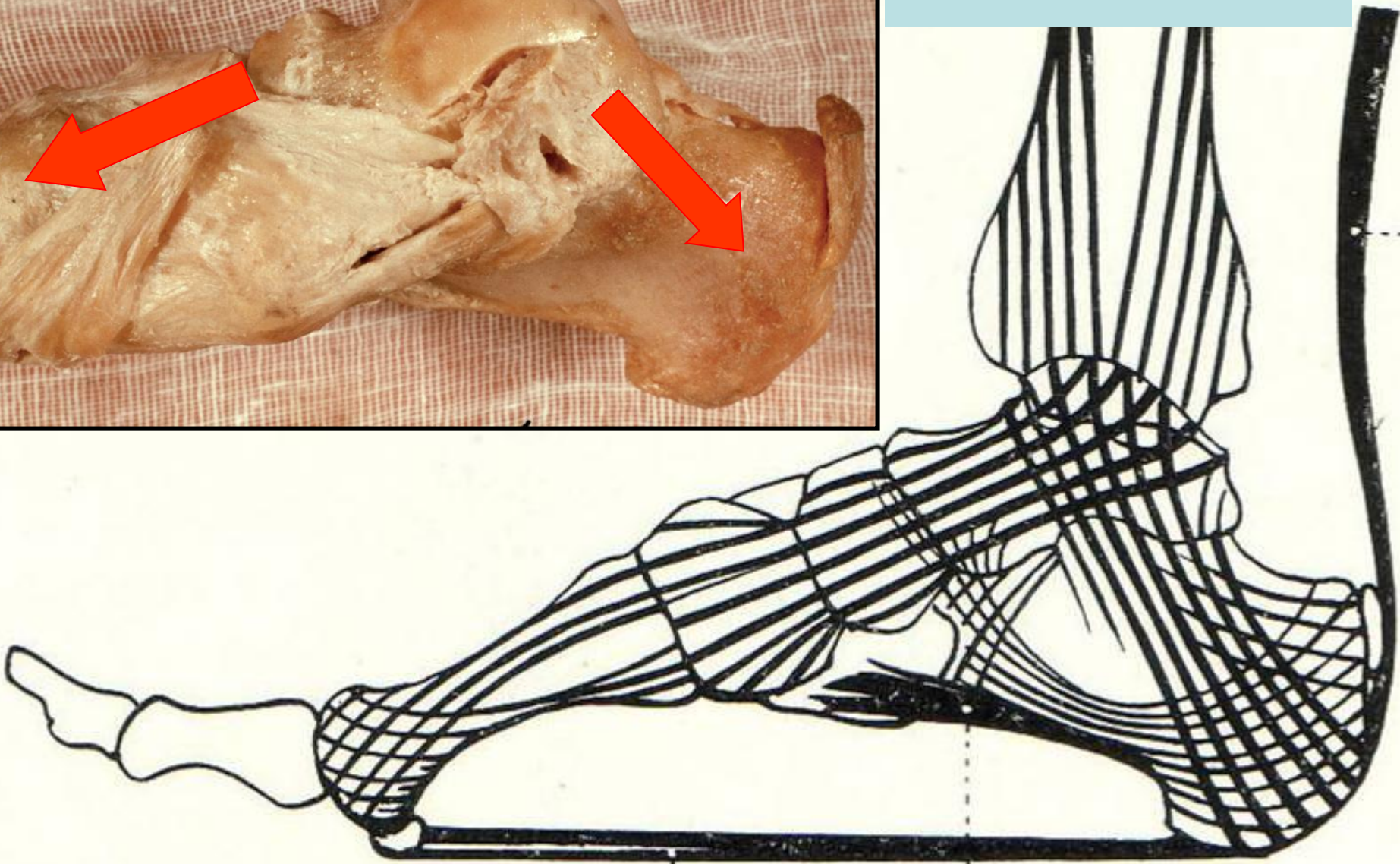
# Skelet nohy a hlezna





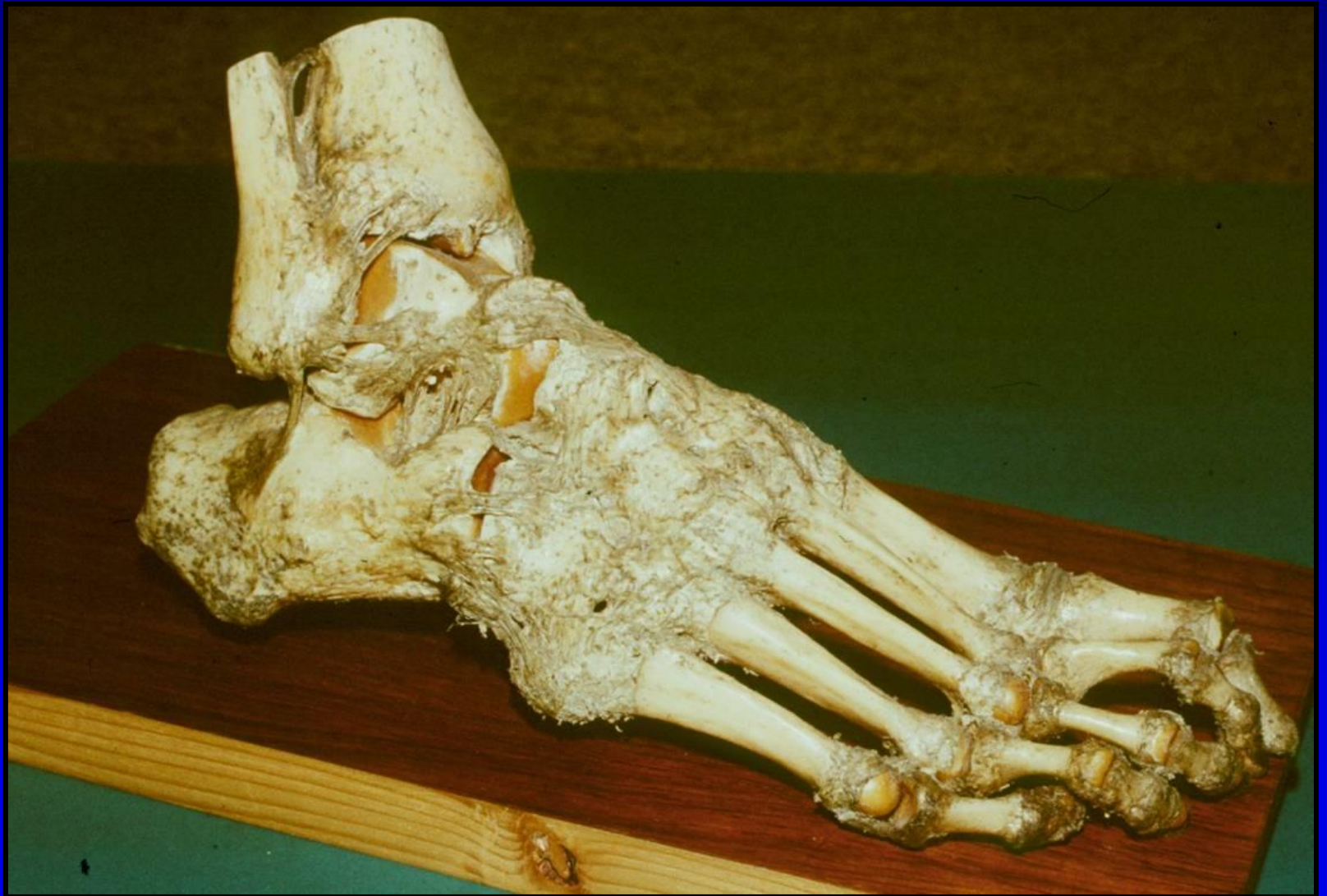

**Talus**





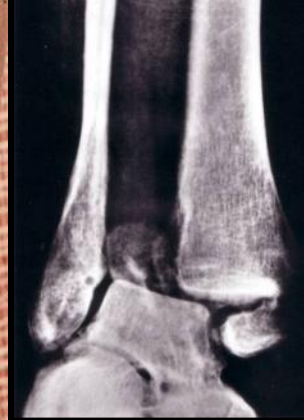# Anatomie hlezna art. talocruralis





ANTERIOR

POSTERIOR 1



*Syndesmosis*

*Syndesmosis*

*Lig. deltoideum*

2

3

4

5

*Ligg. fibularia*

*Ligg. fibularia*

*Lig. deltoideum*

2

7

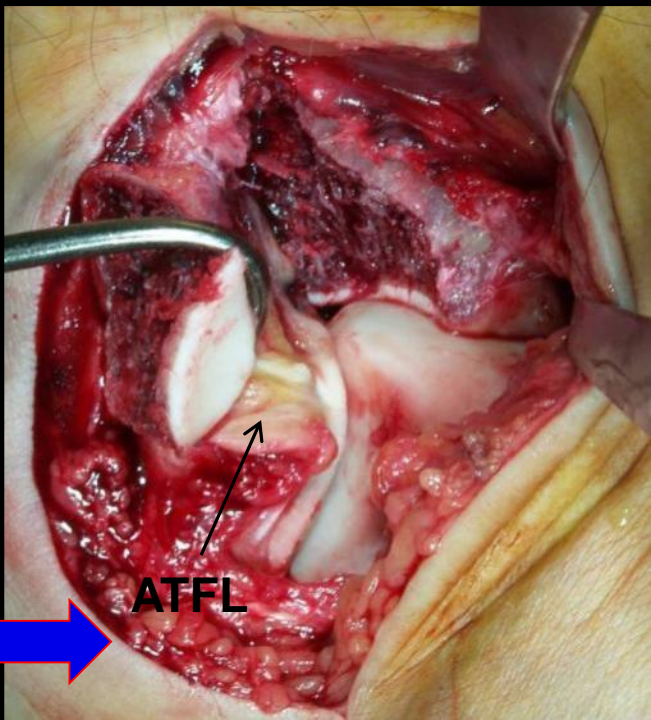
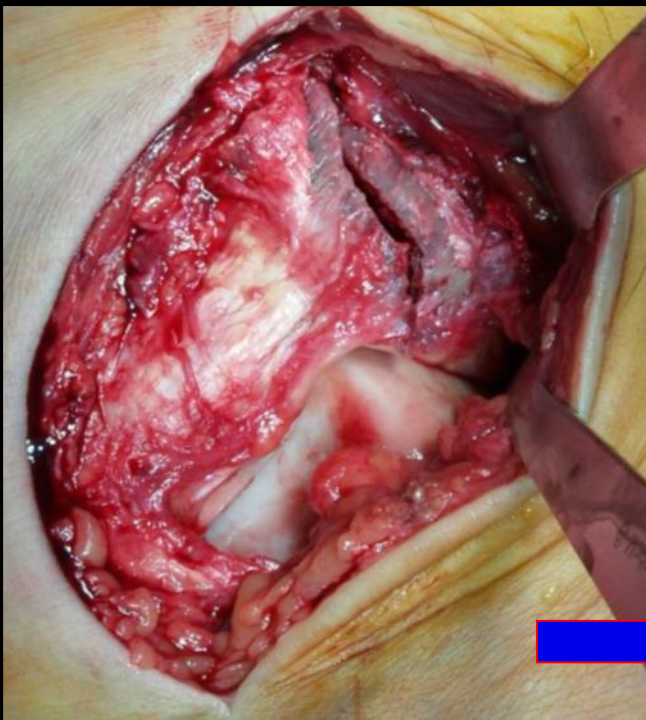
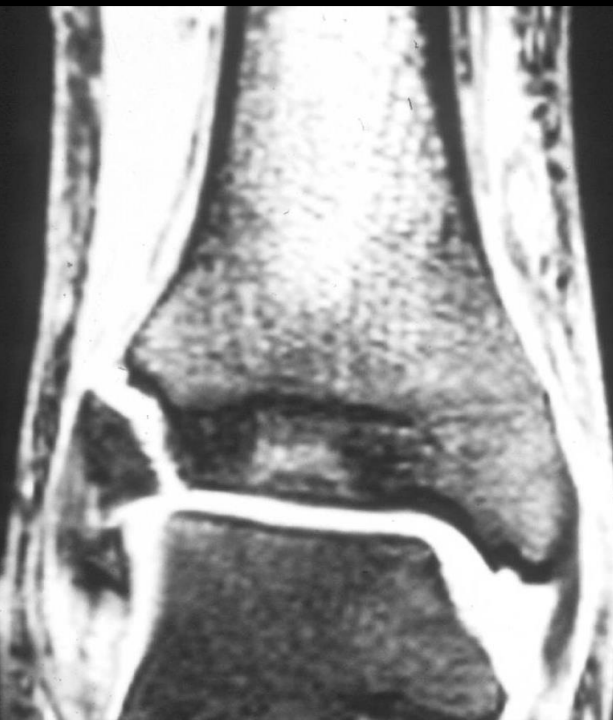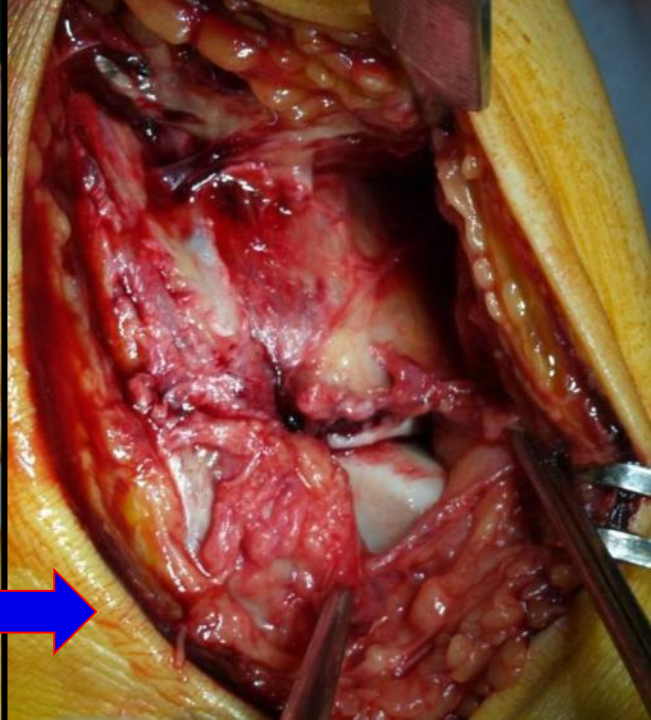
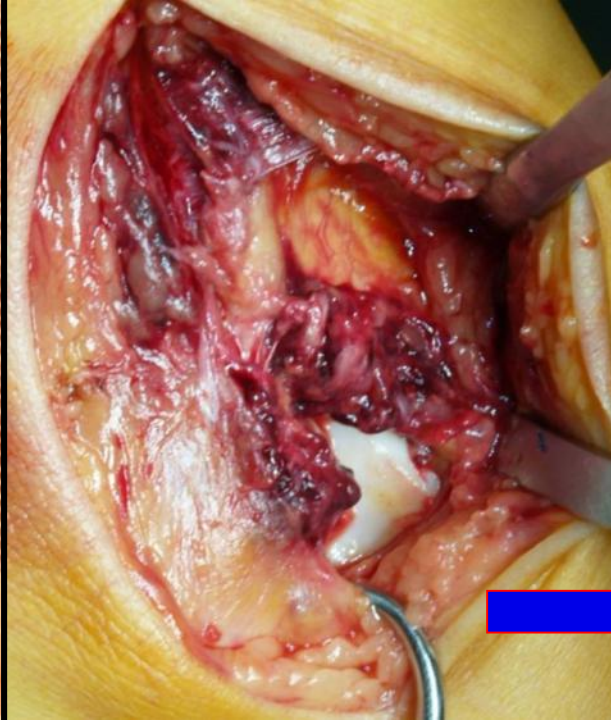
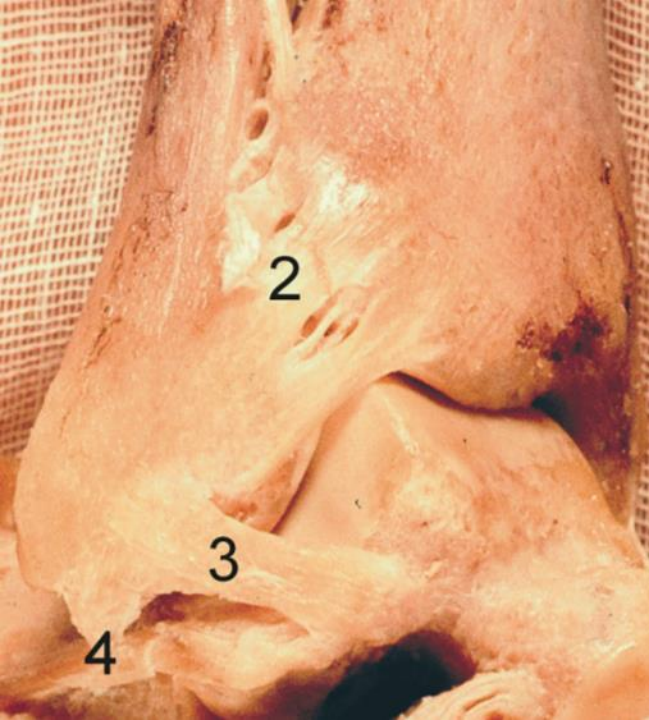
8

5

6

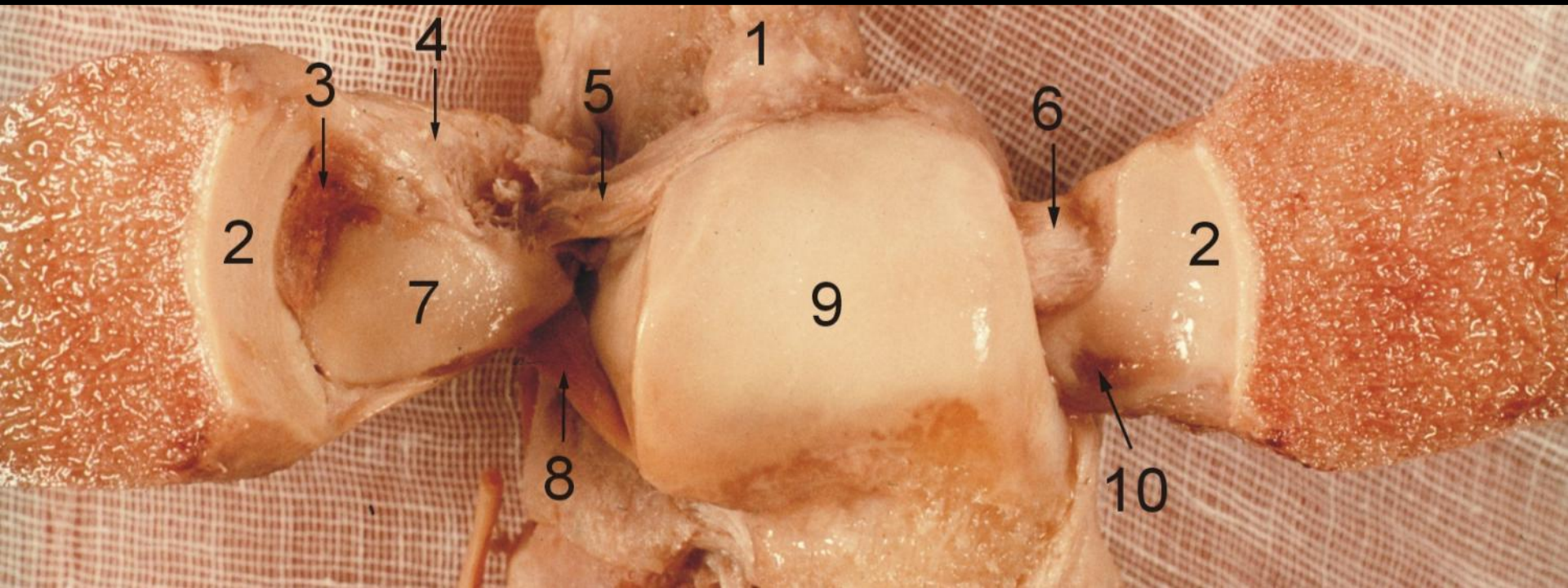
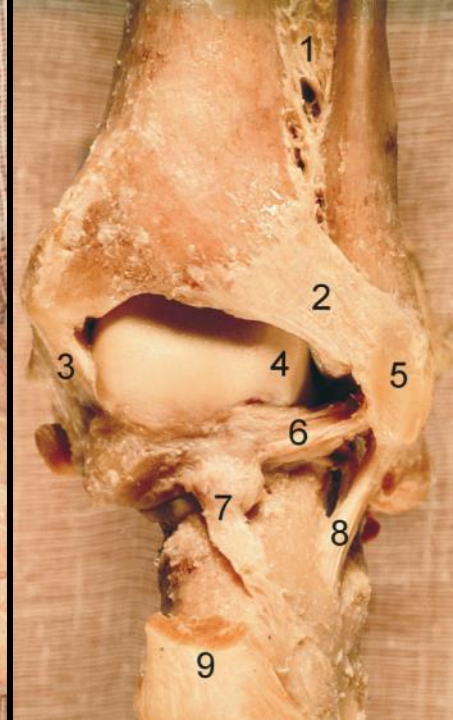
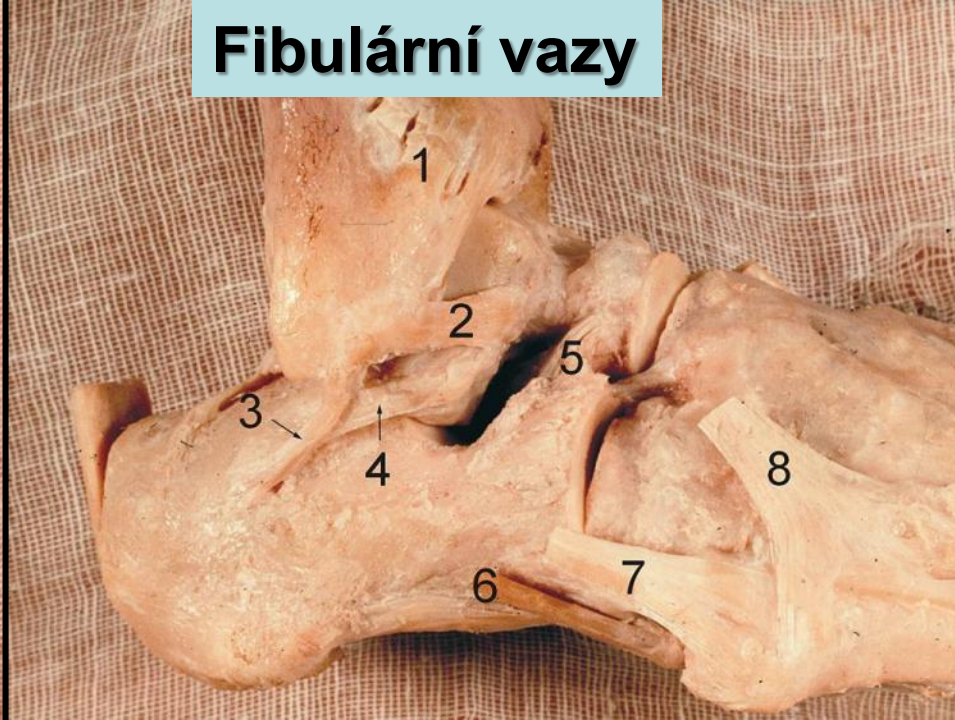
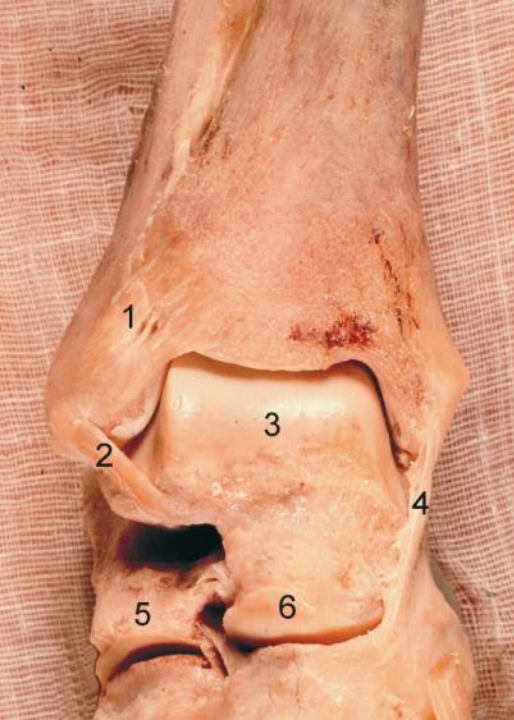
9





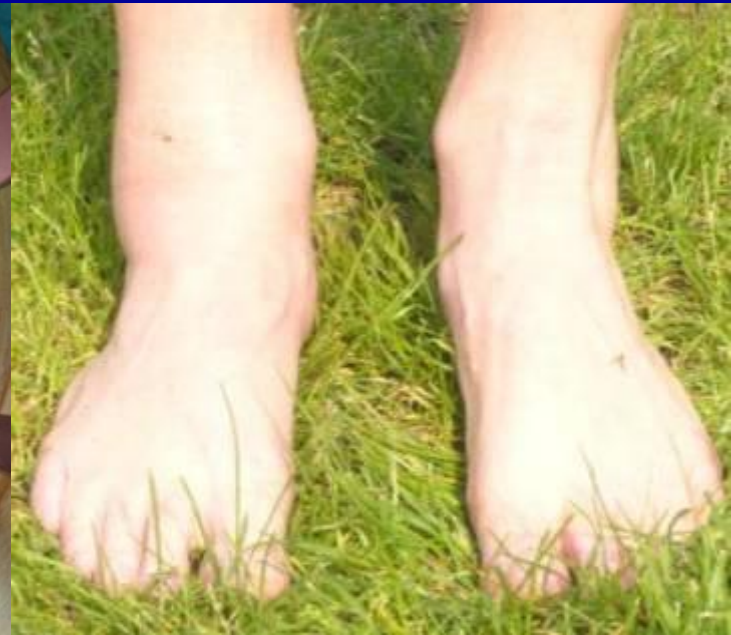
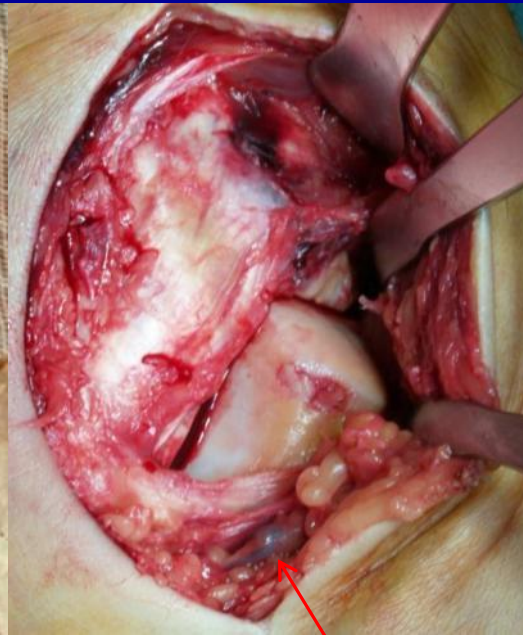
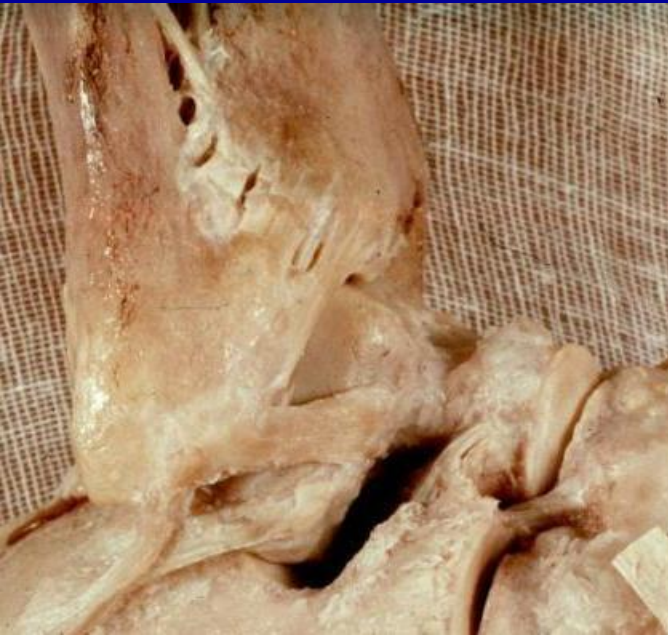# Fibulární vazy



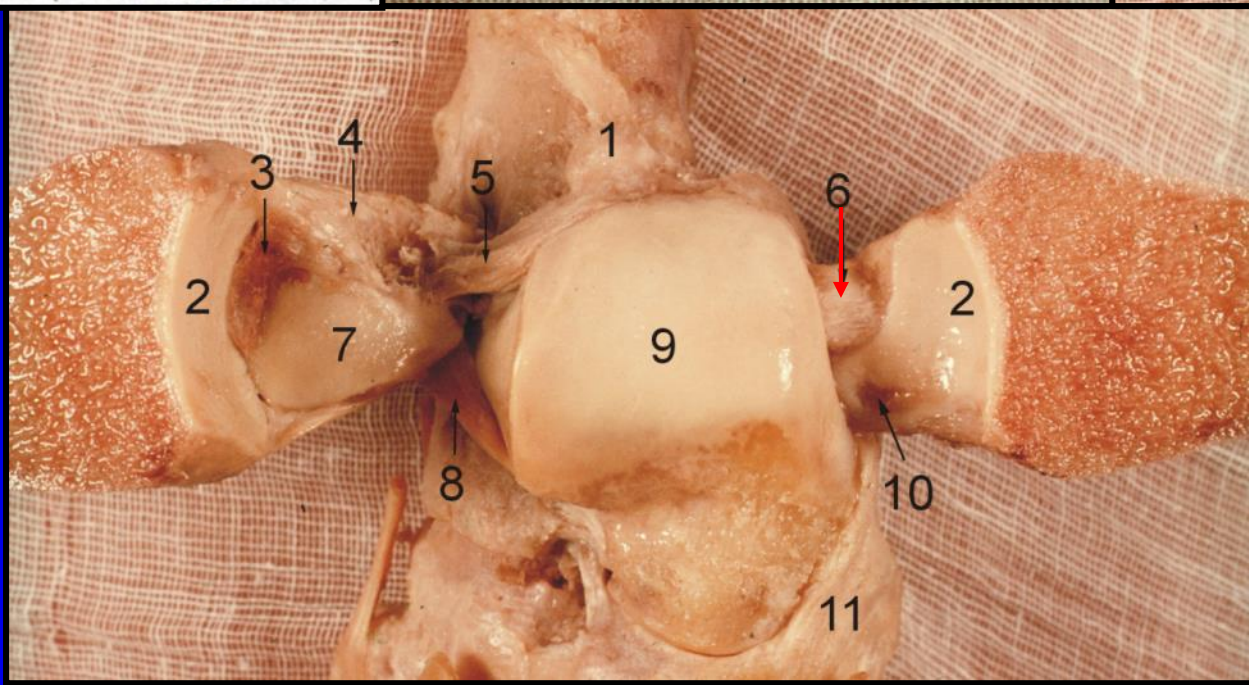
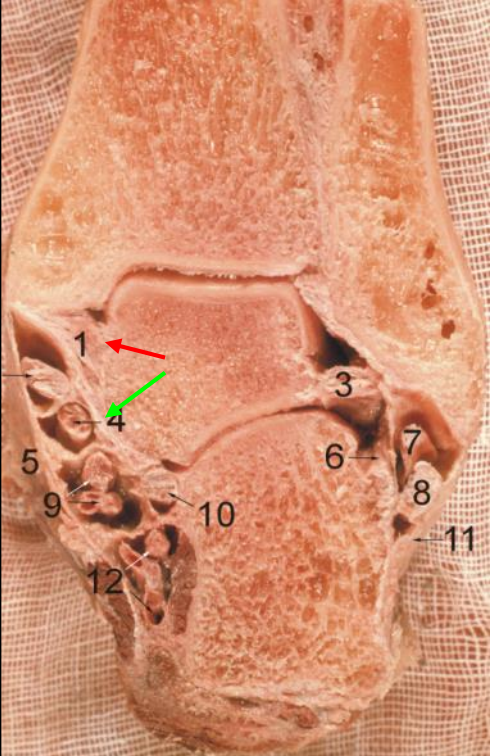
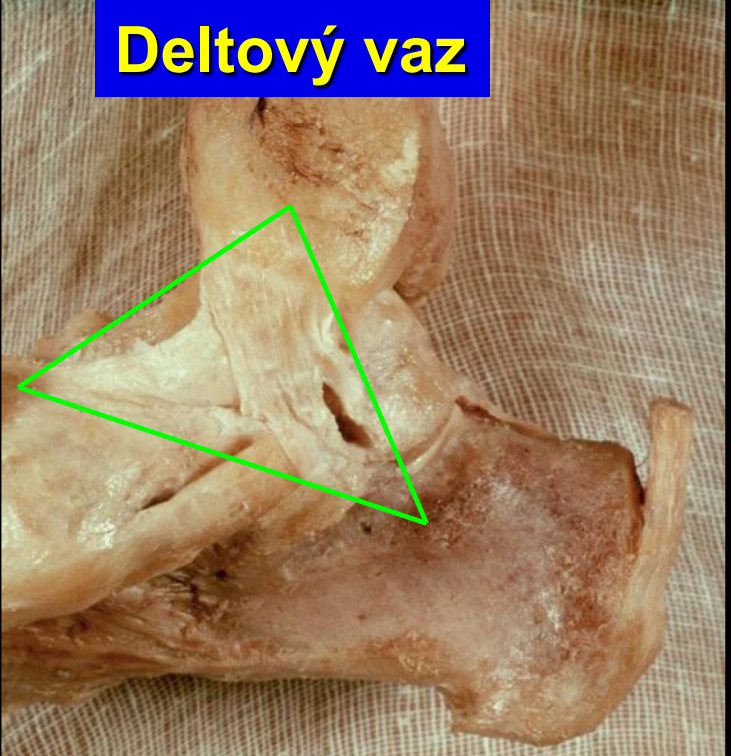
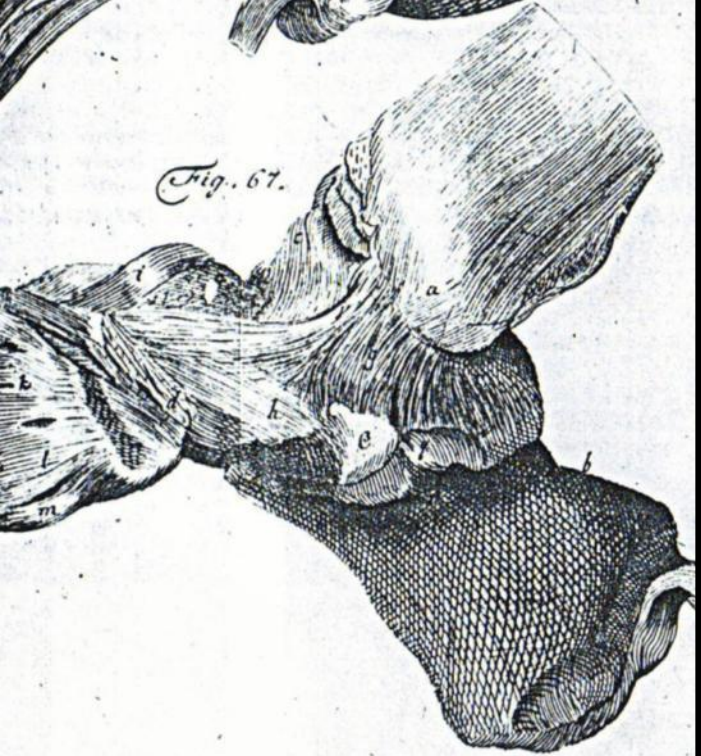

# Akutní hematom

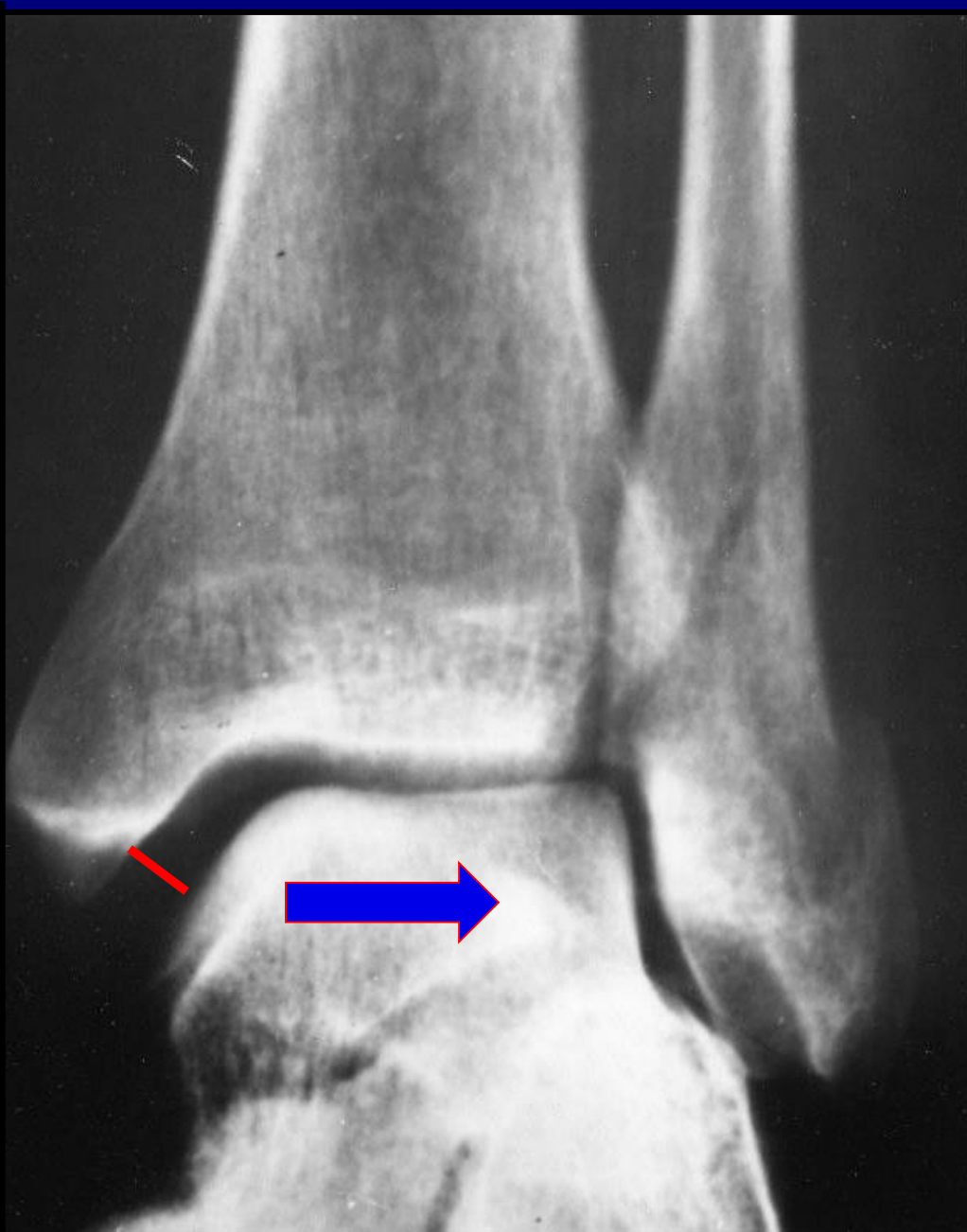
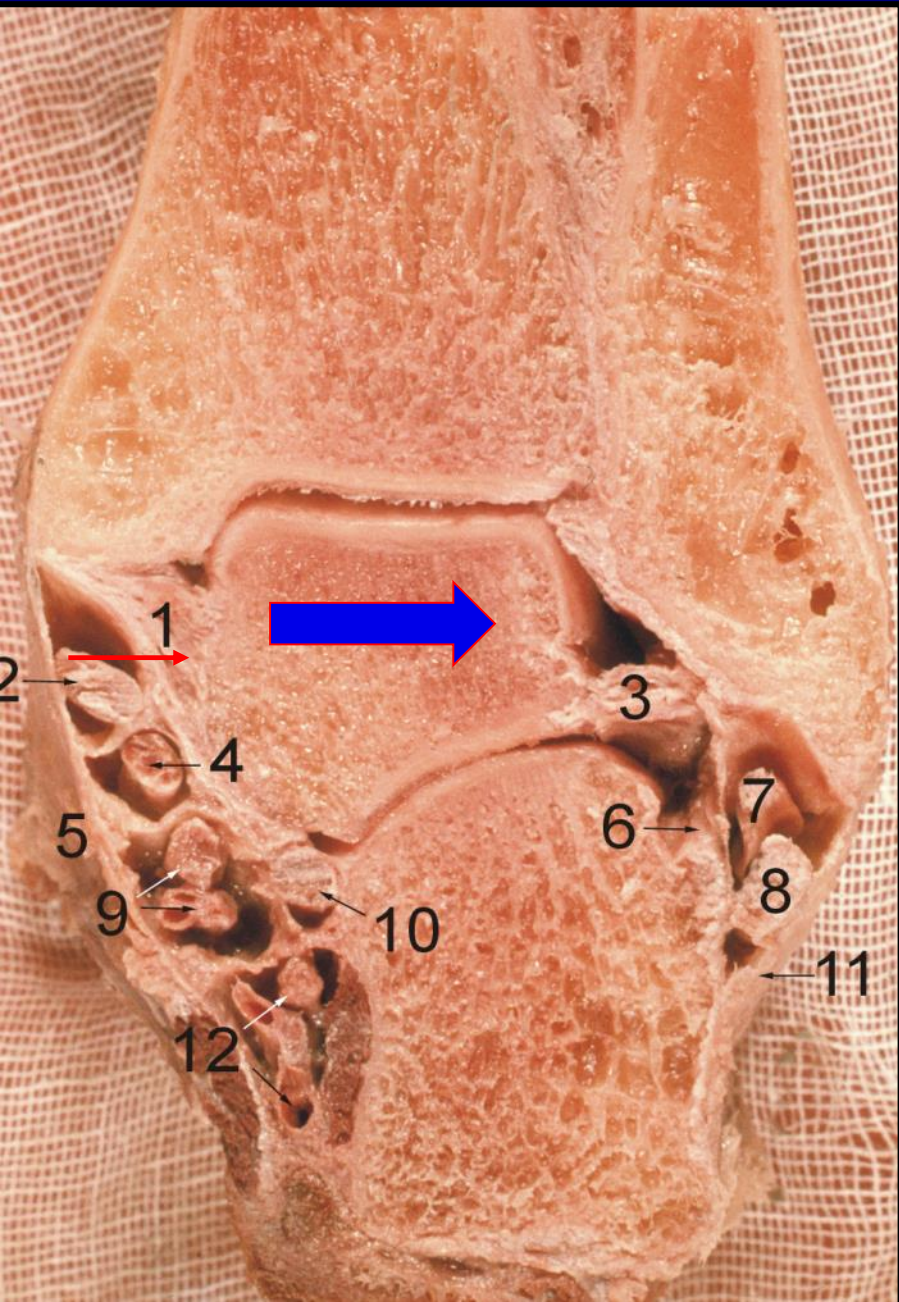




# Deltový vaz









# Dolní zánártní kloub

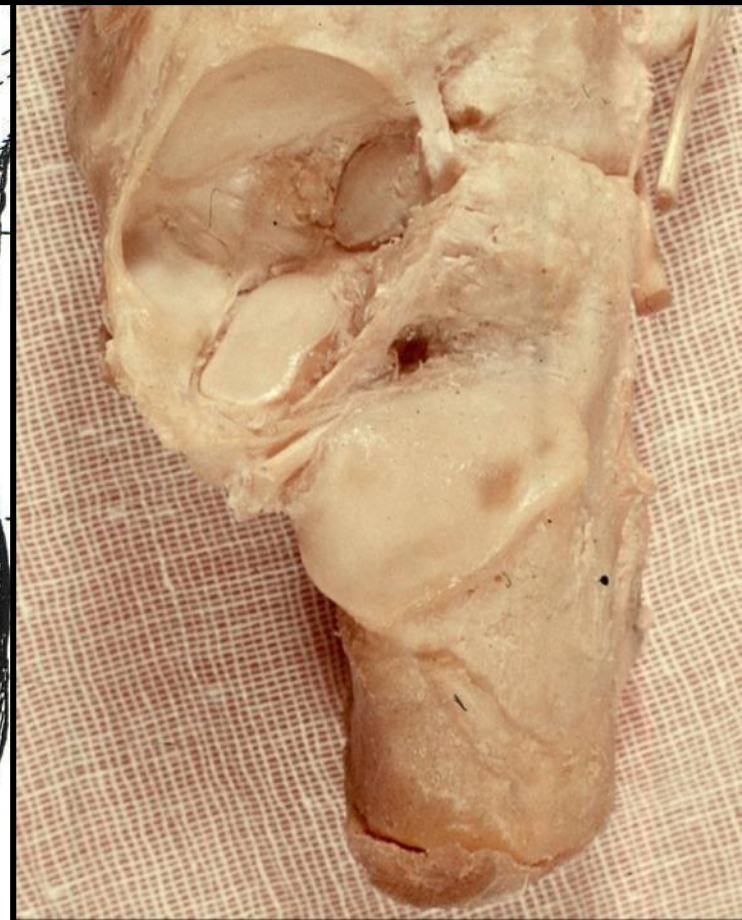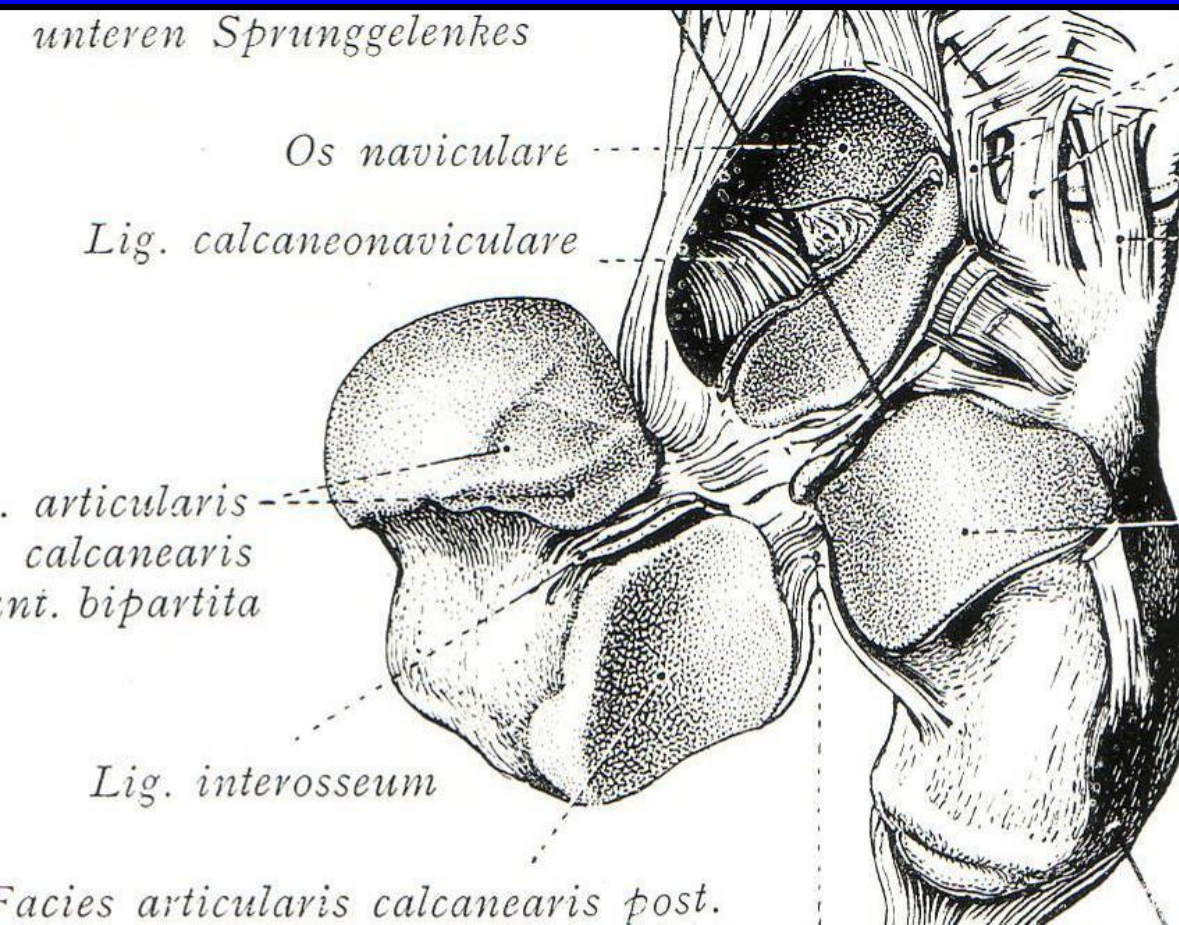
## Subtalární kloub

### Talo-Kalkaneo-Navikulární kloub

*přední*

### Talo-Kalkaneární kloub

*zadní*

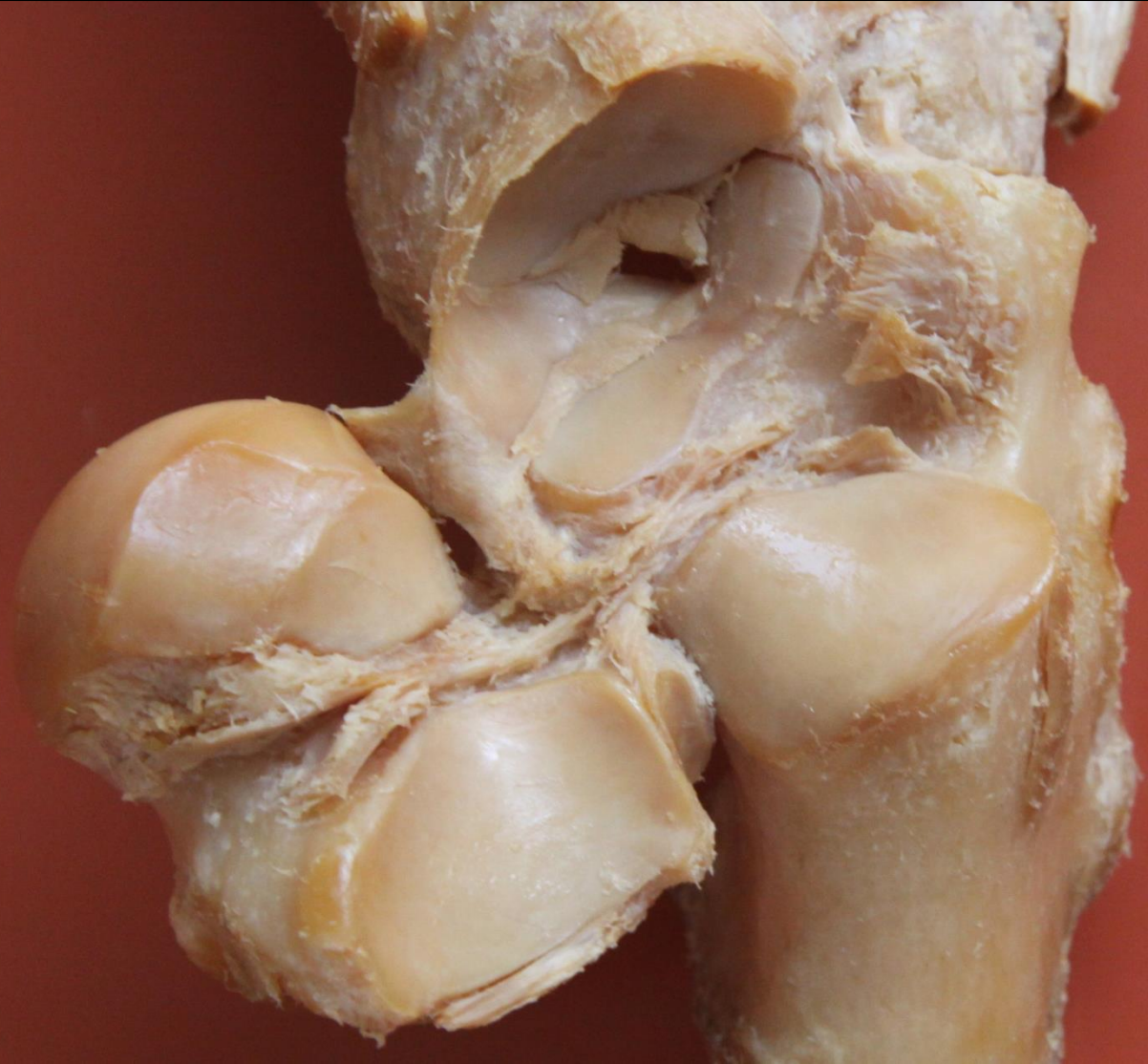
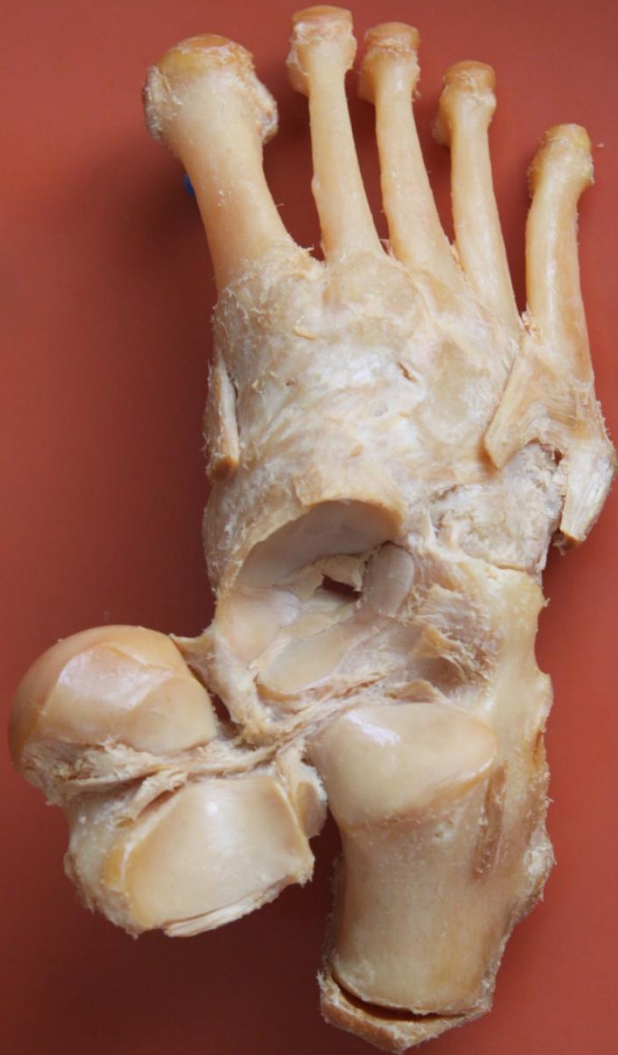


# Subtalární kloub

Talo-Kalkaneo-Navikulární kloub

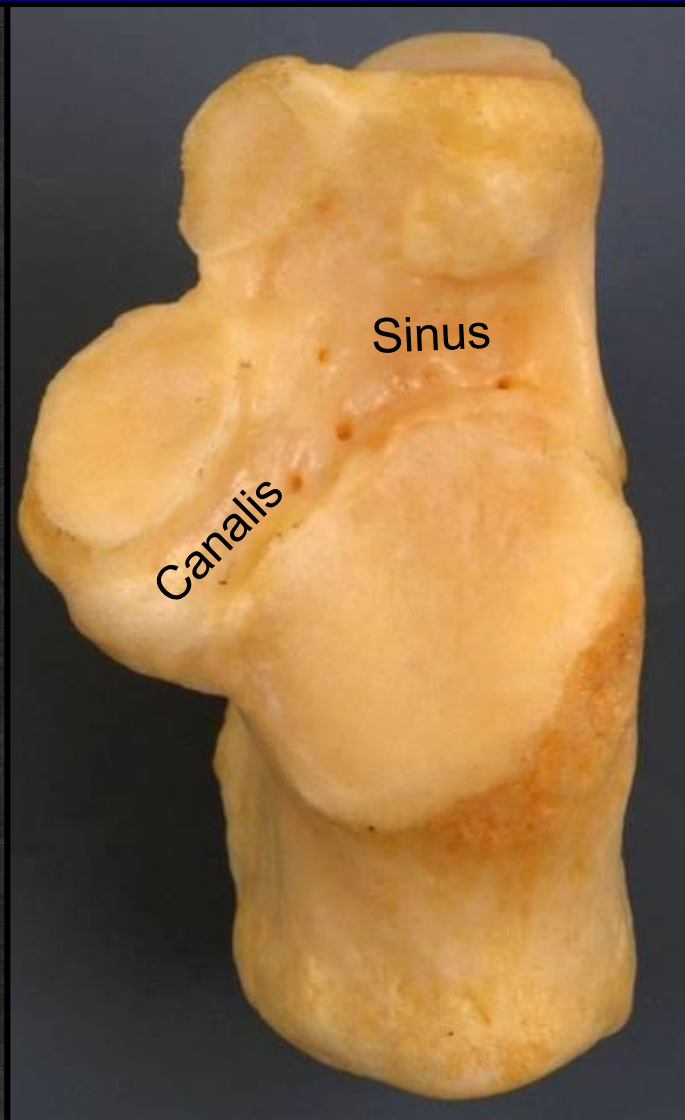
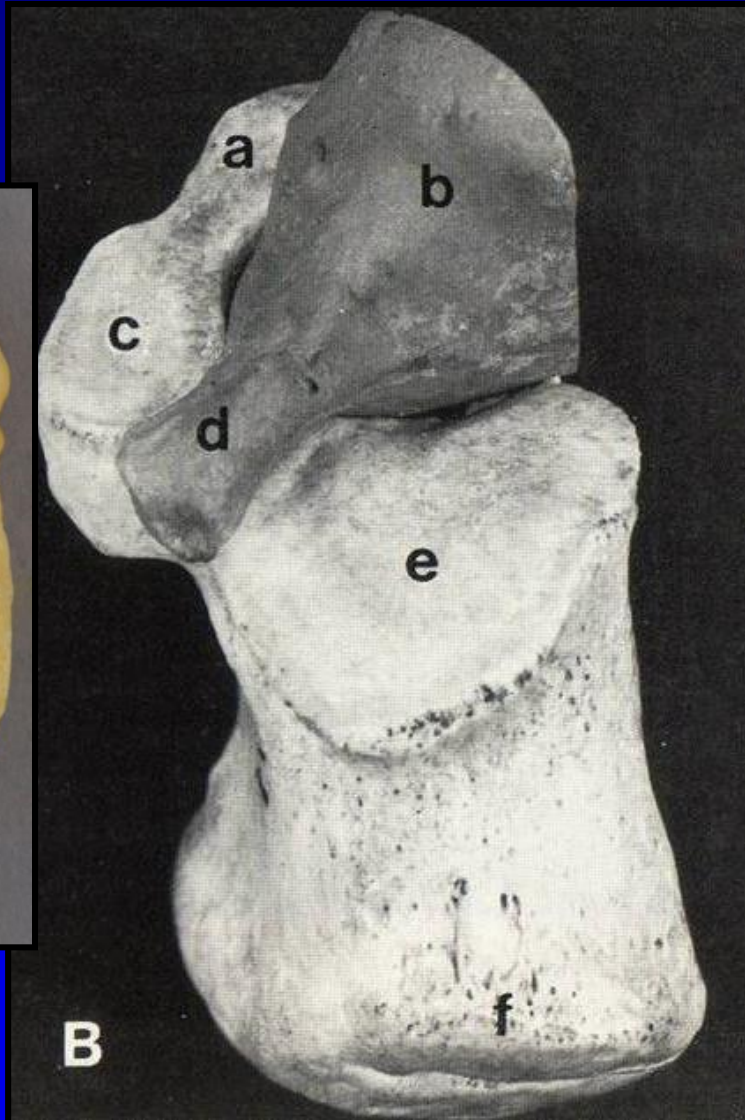
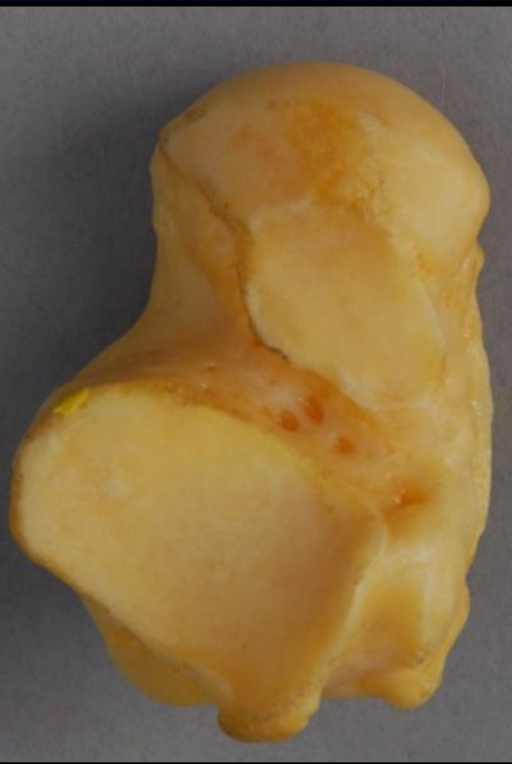
Talo-Kalkaneární kloub





# Canalis et sinus tarsi

Ca



# Chopartův kloub

*Articulatio tarsi transversa*

Více funkční než anatomická jednotka

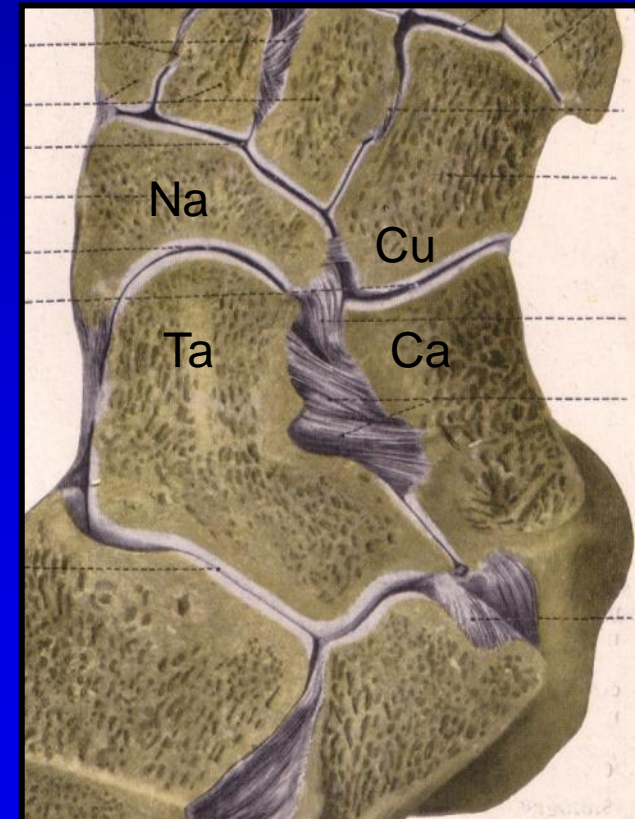
Dvě části

Talo-Navikulární kloub

*Kulový kloub*

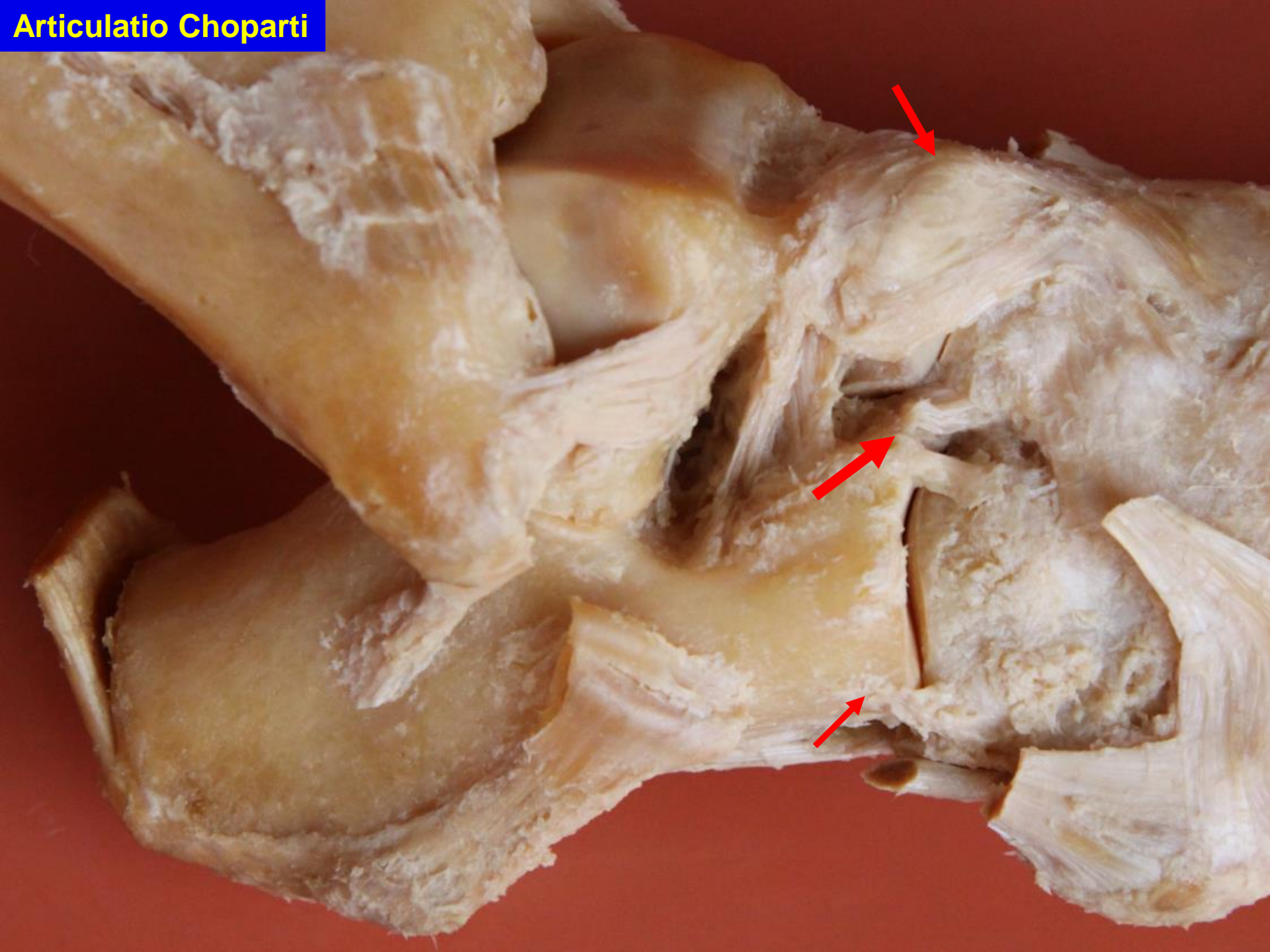
Kalkaneo-Kuboidální kloub

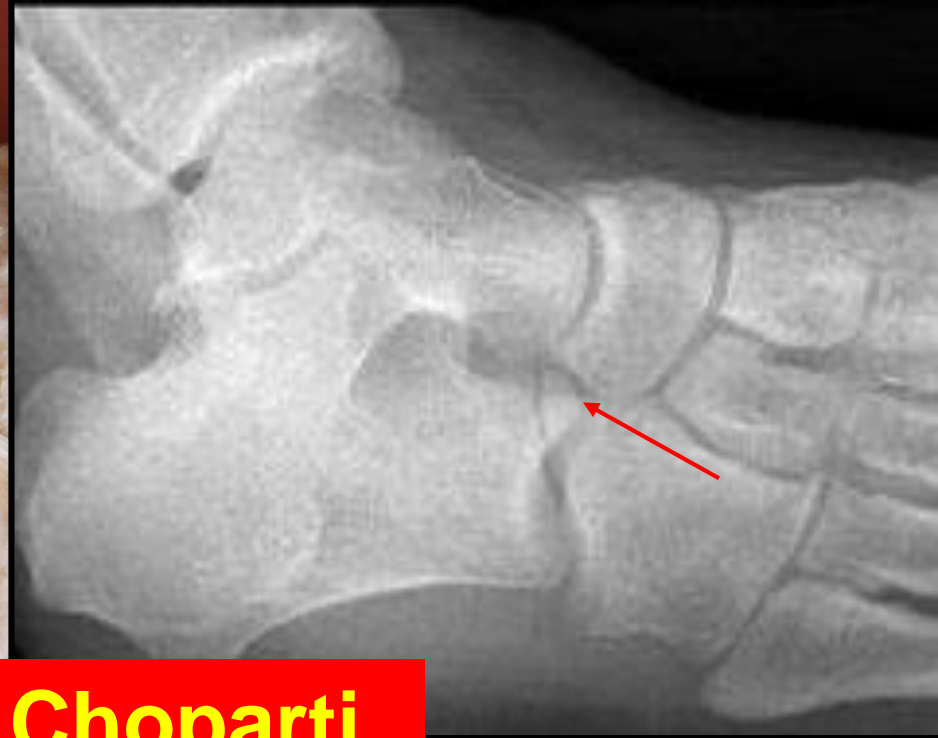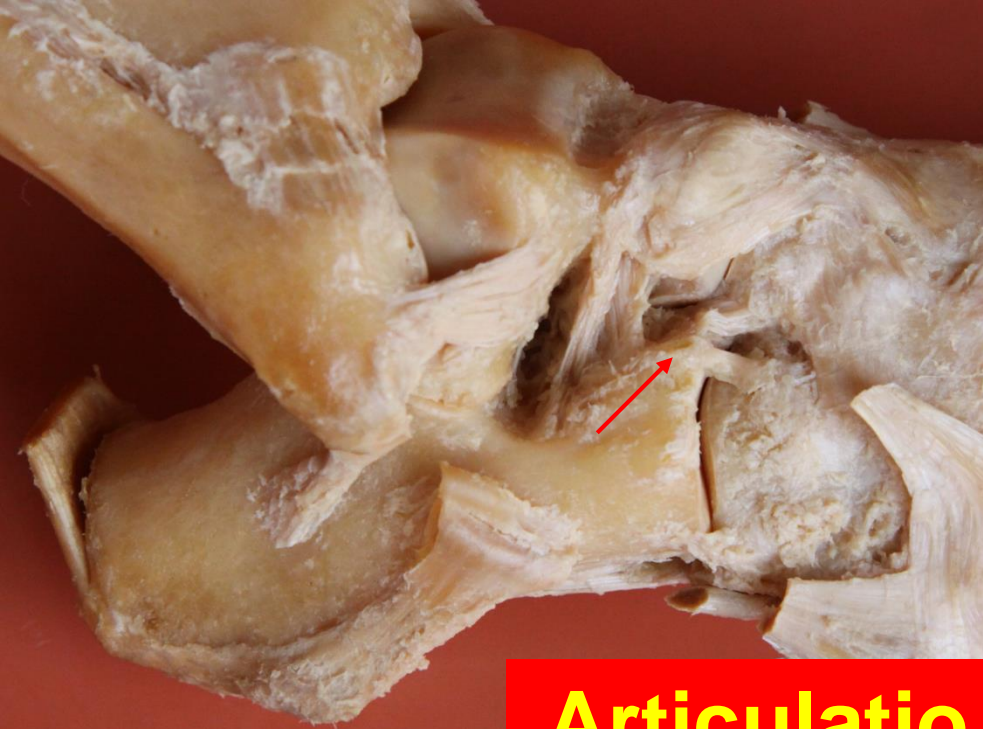*Sedlový kloub*



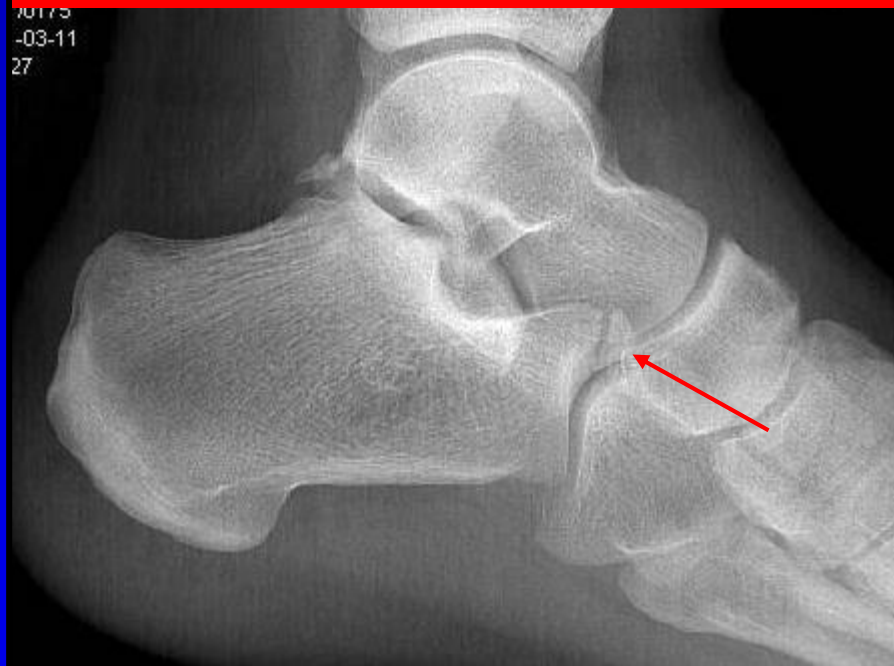

**Articulatio Choparti**





## Articulatio Choparti





# Lisfrancův kloub

## Art. tarsometatarsales

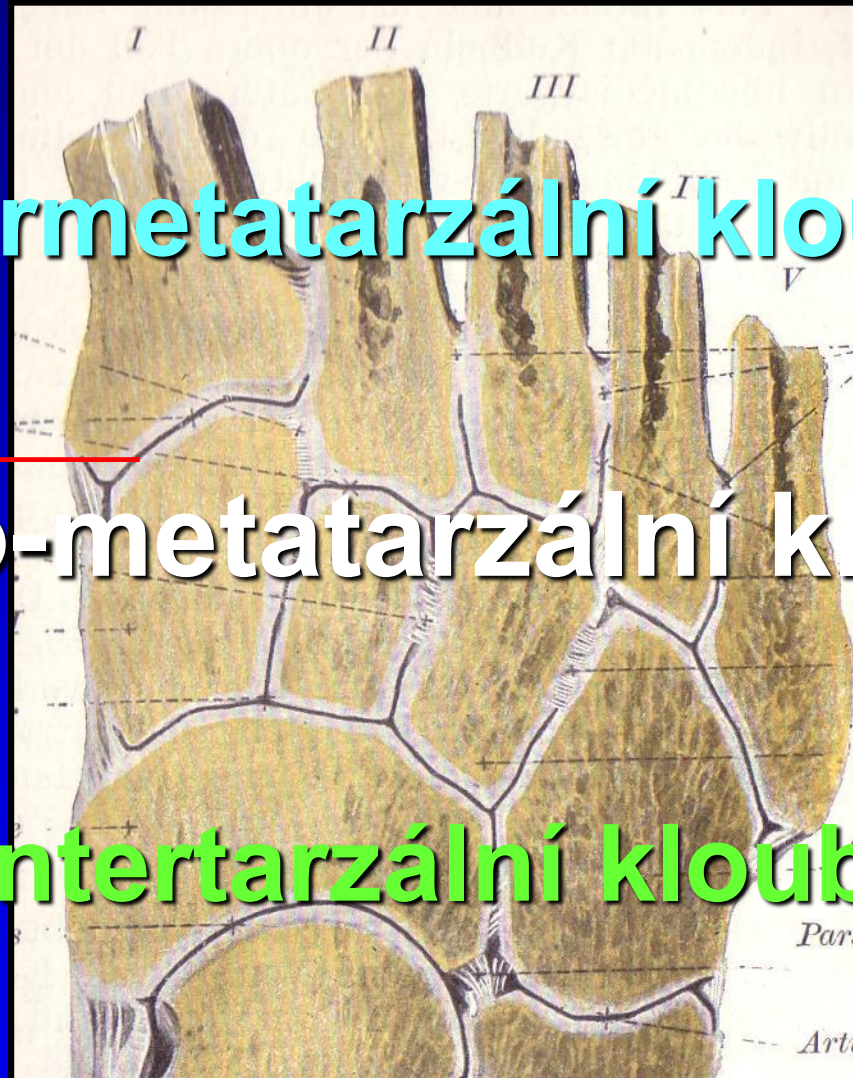Přednoží

Intermetatarzální klouby

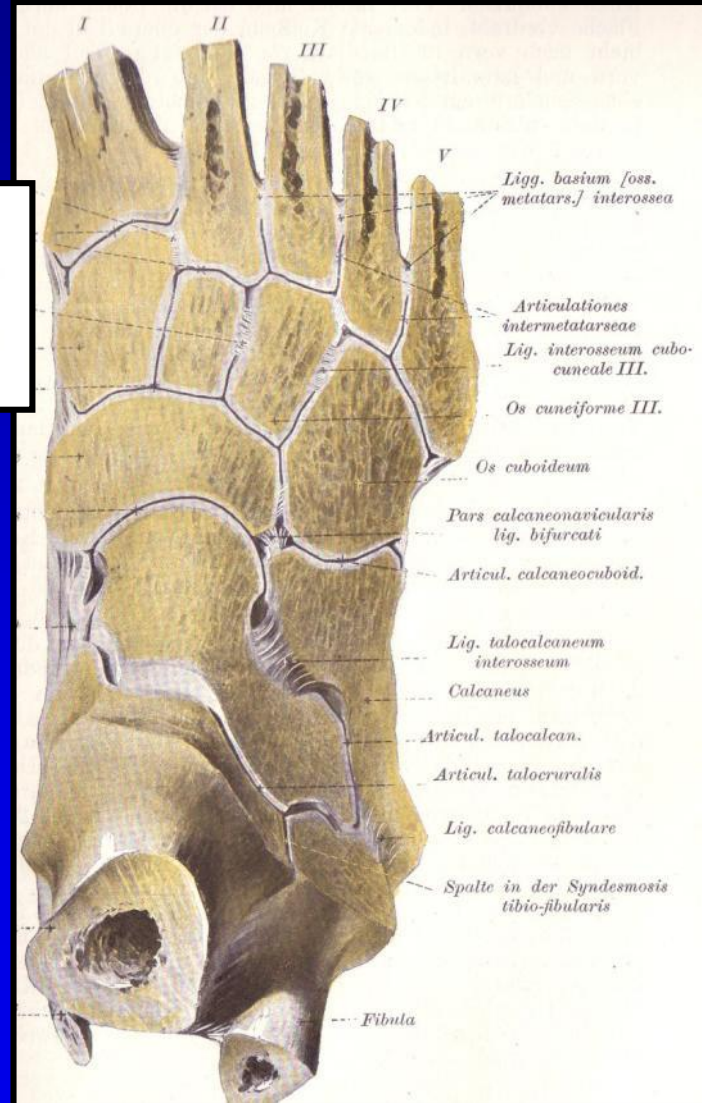
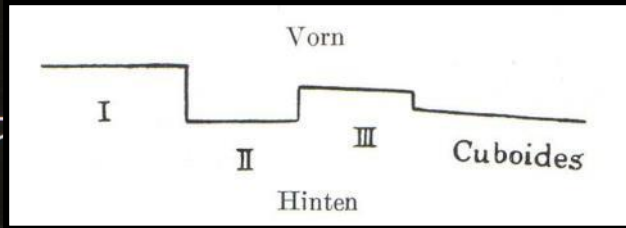
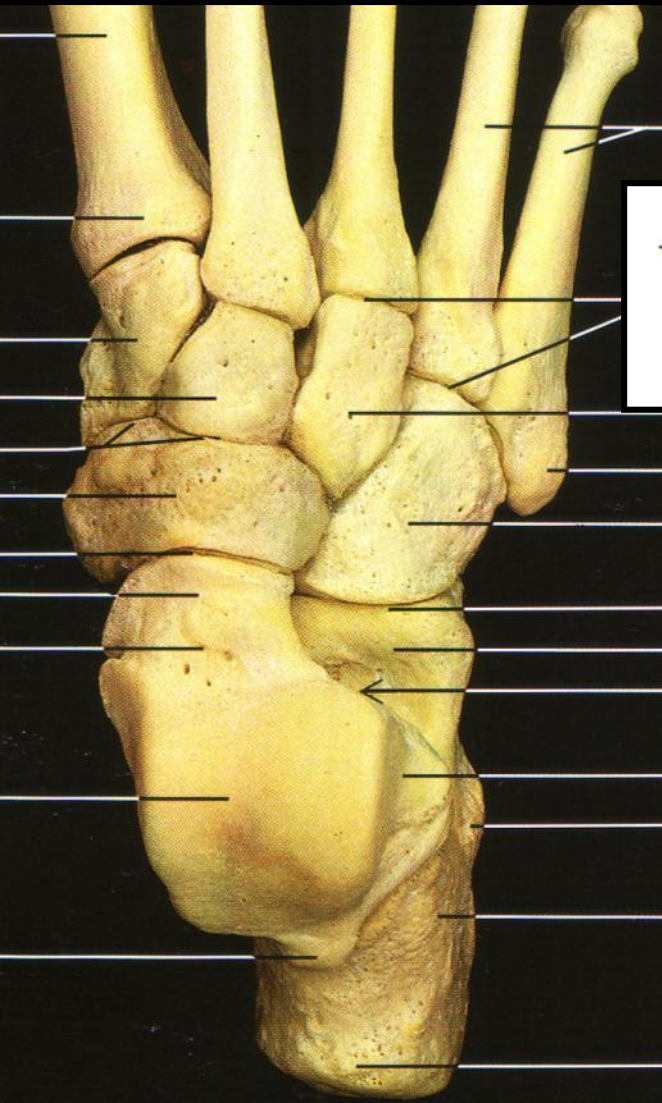Tarzo-metatarzální klouby

Středonoží

Intertarzální kloub



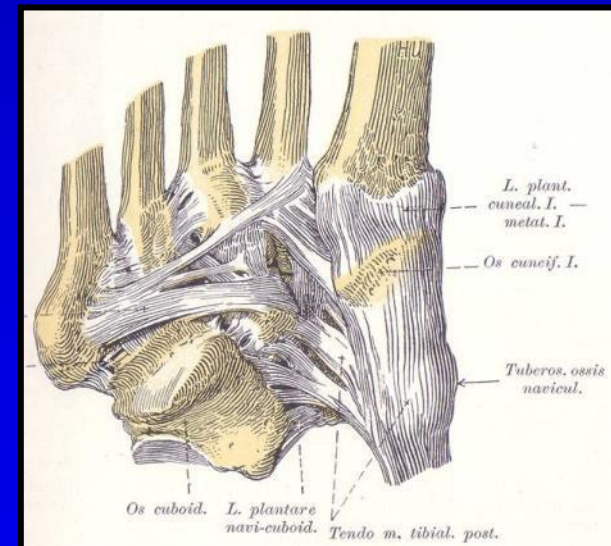
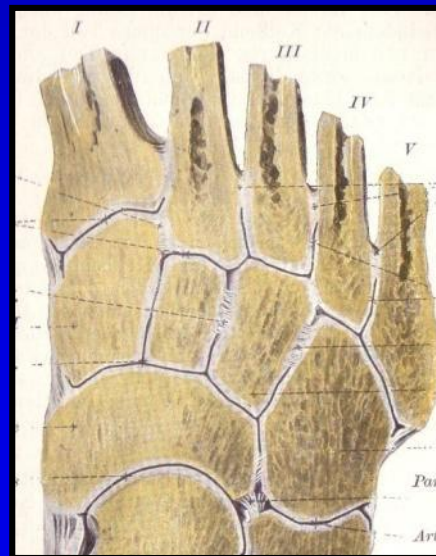
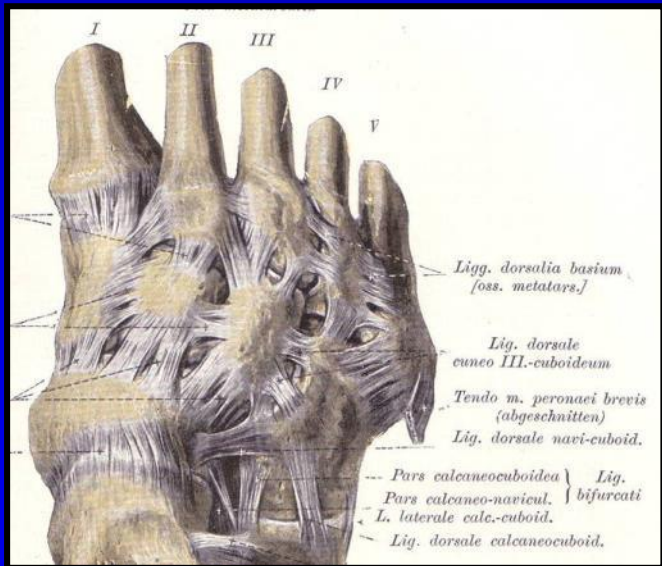
# Lisfrancův kloub





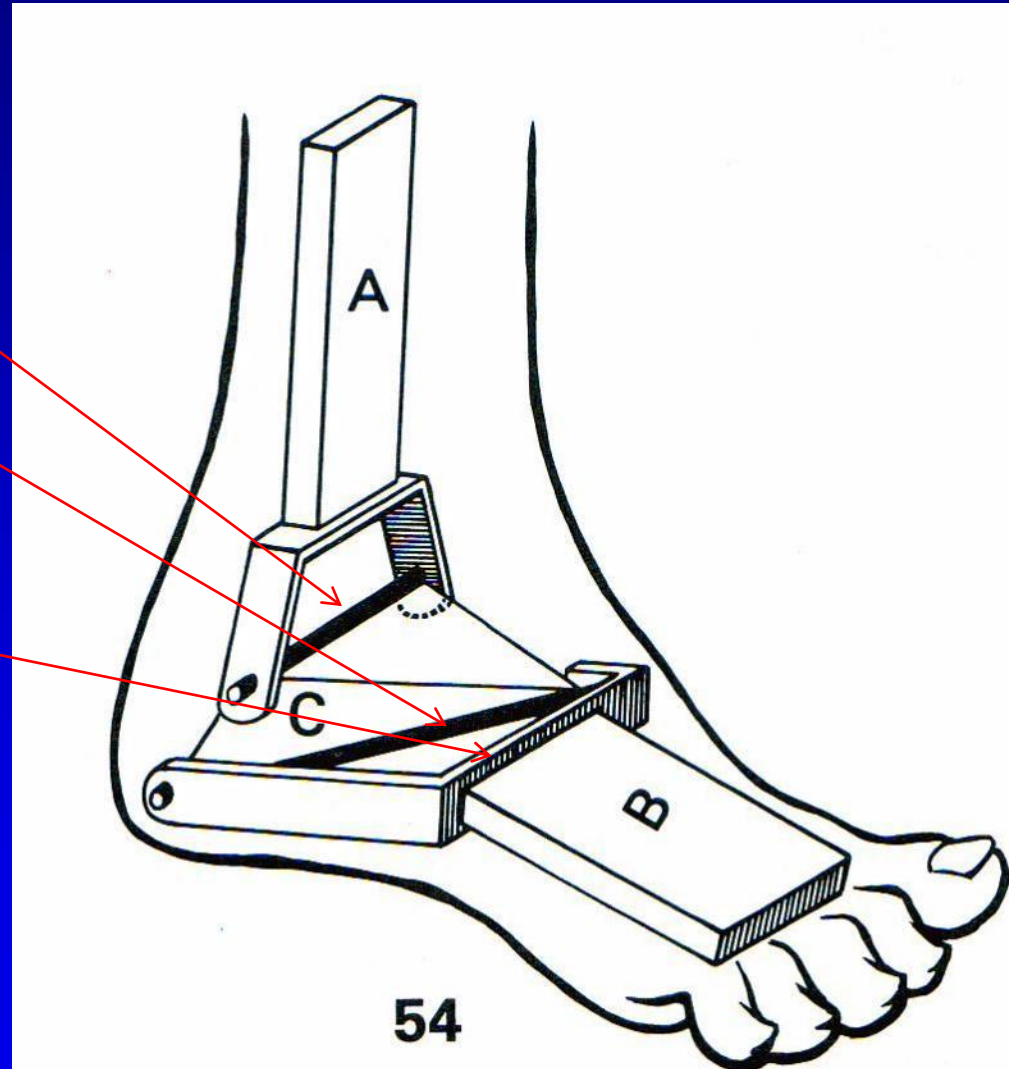
# Lisfrancův kloub

- Ligg. dorsalia
  - Ligg. interossea
    - Ligg. plantaria

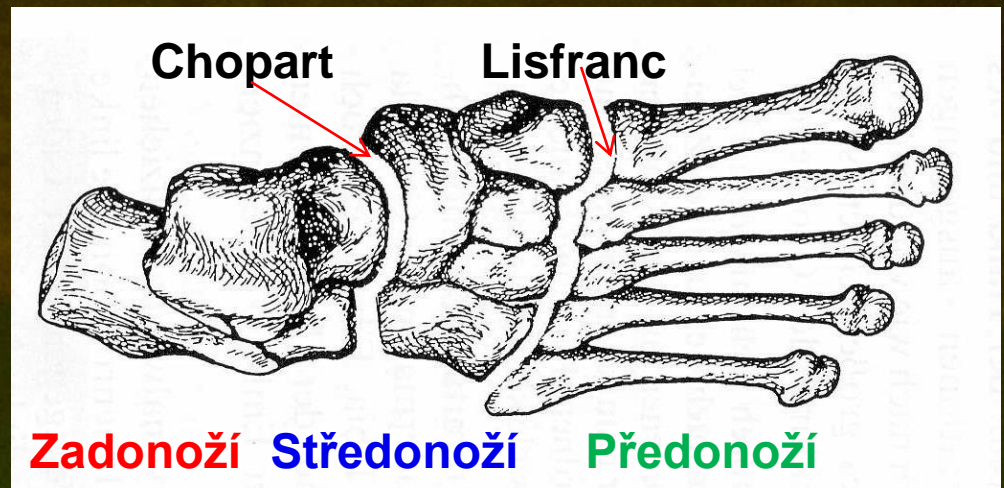
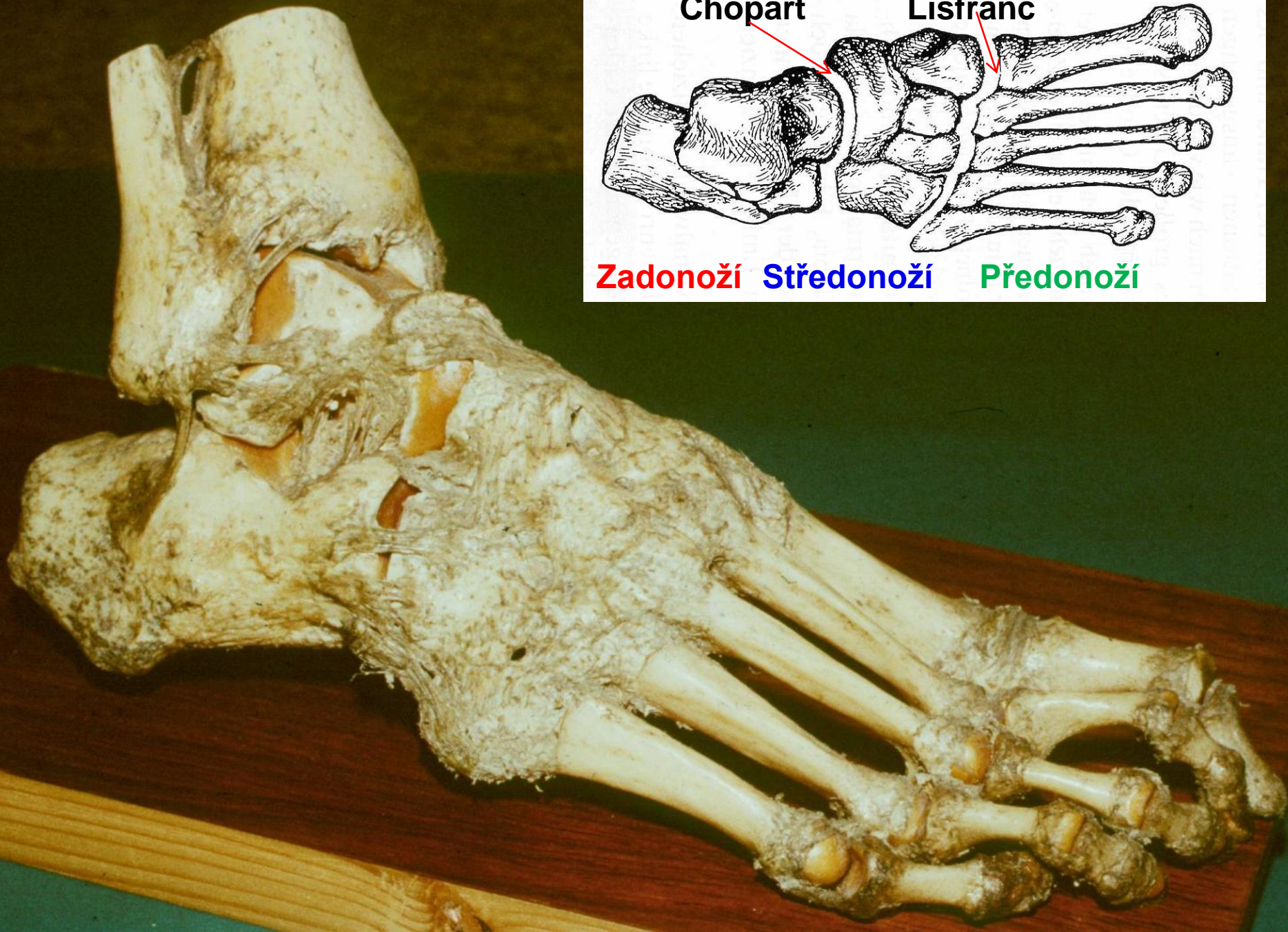


# Nejdůležitější klouby

- Hlezenní kloub  
*Plantiflexe/Dorziflexe*
- Subtalární kloub  
*Everze/Inverze*
- Chopartův kloub
- Lisfrancův kloub







Chopart

Lisfranc

Zadonoží

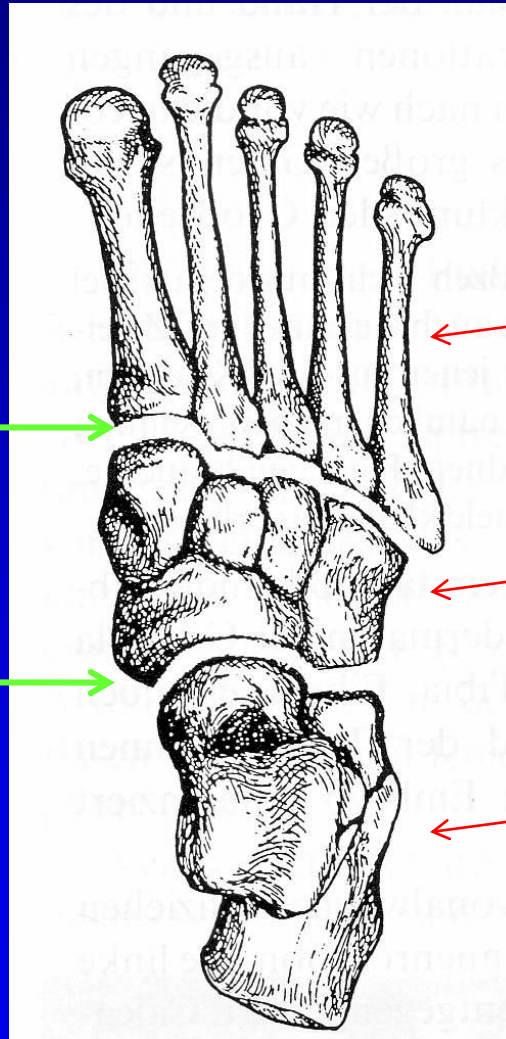
Středonoží

Předonoží

# Noha jako funkční jednotka

- Lisfranc

- Chopart

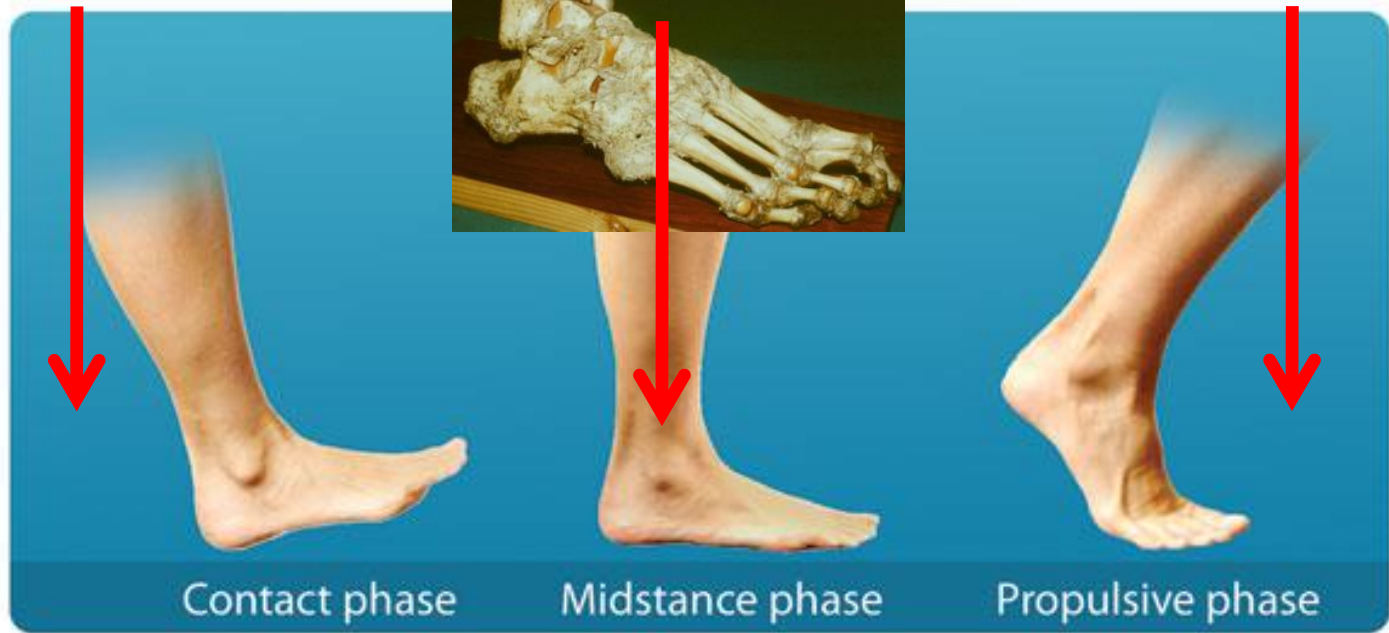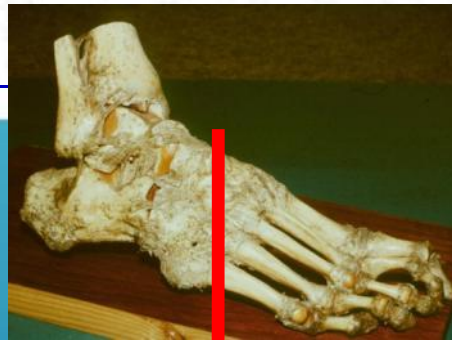
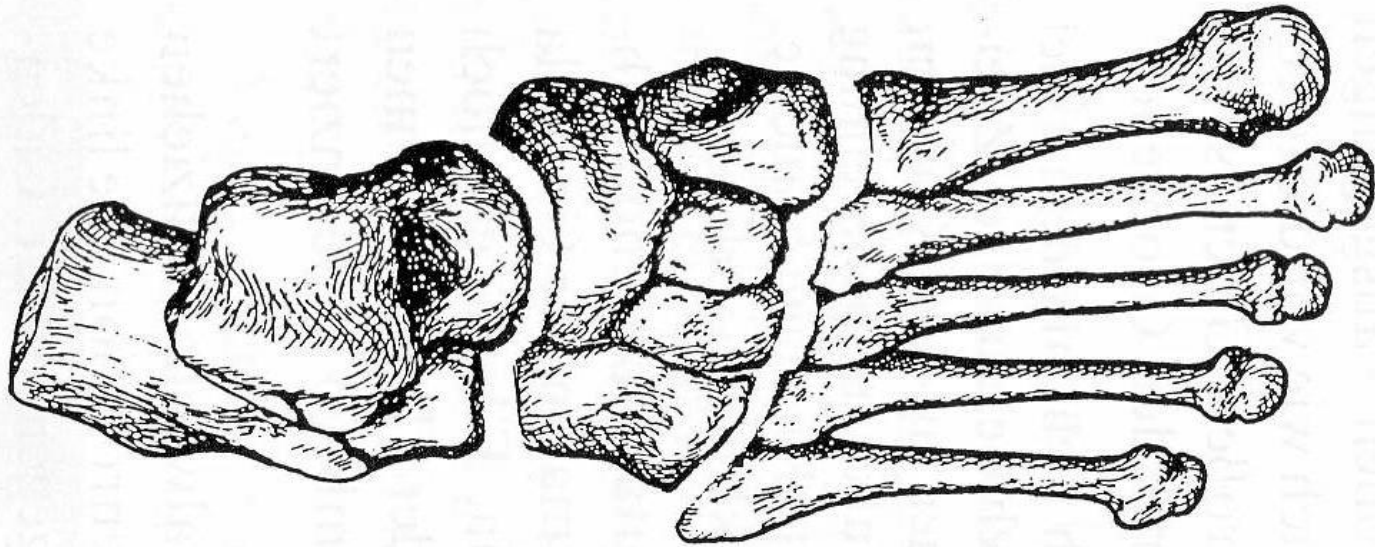


Předonoží

Středonoží

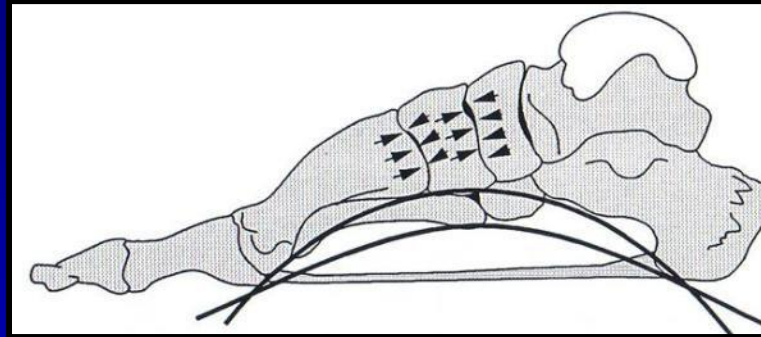
Zadonoží






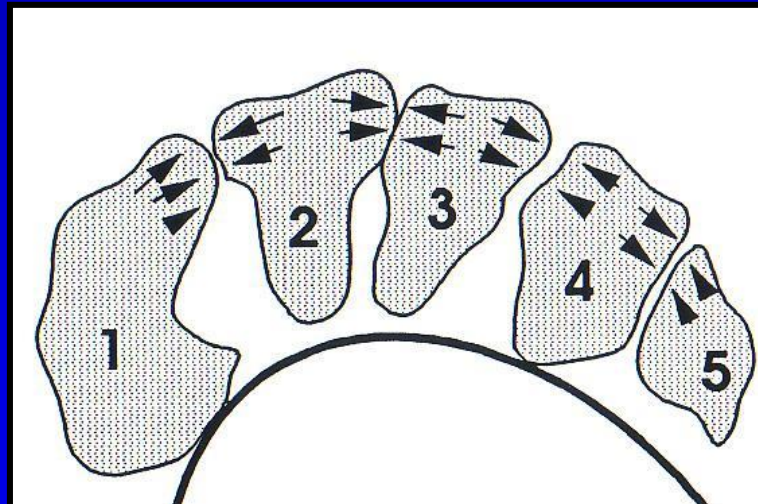
# Klenba nohy

Podélná



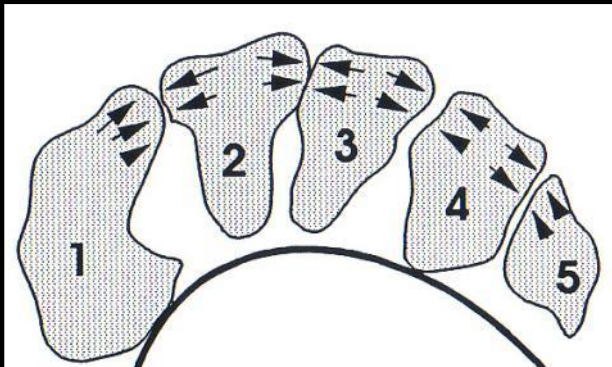
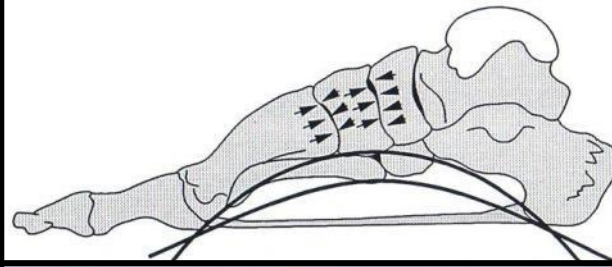
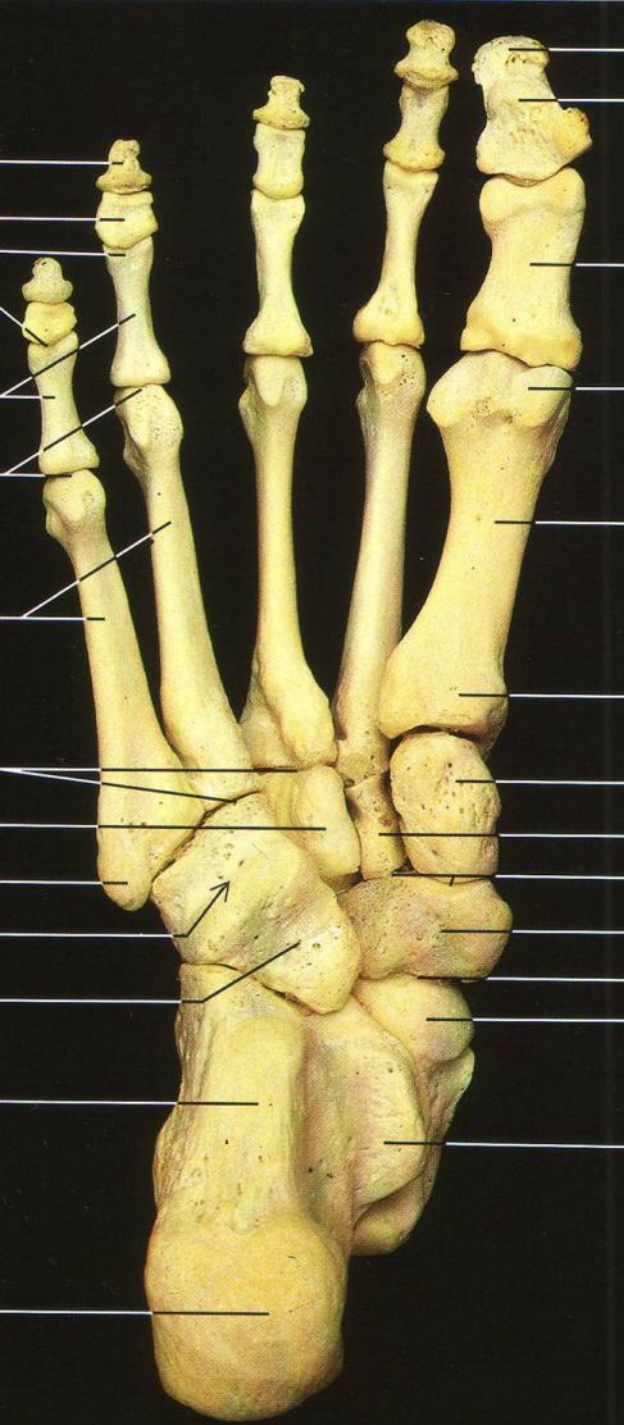
Talonavikulární kloub

Příčná

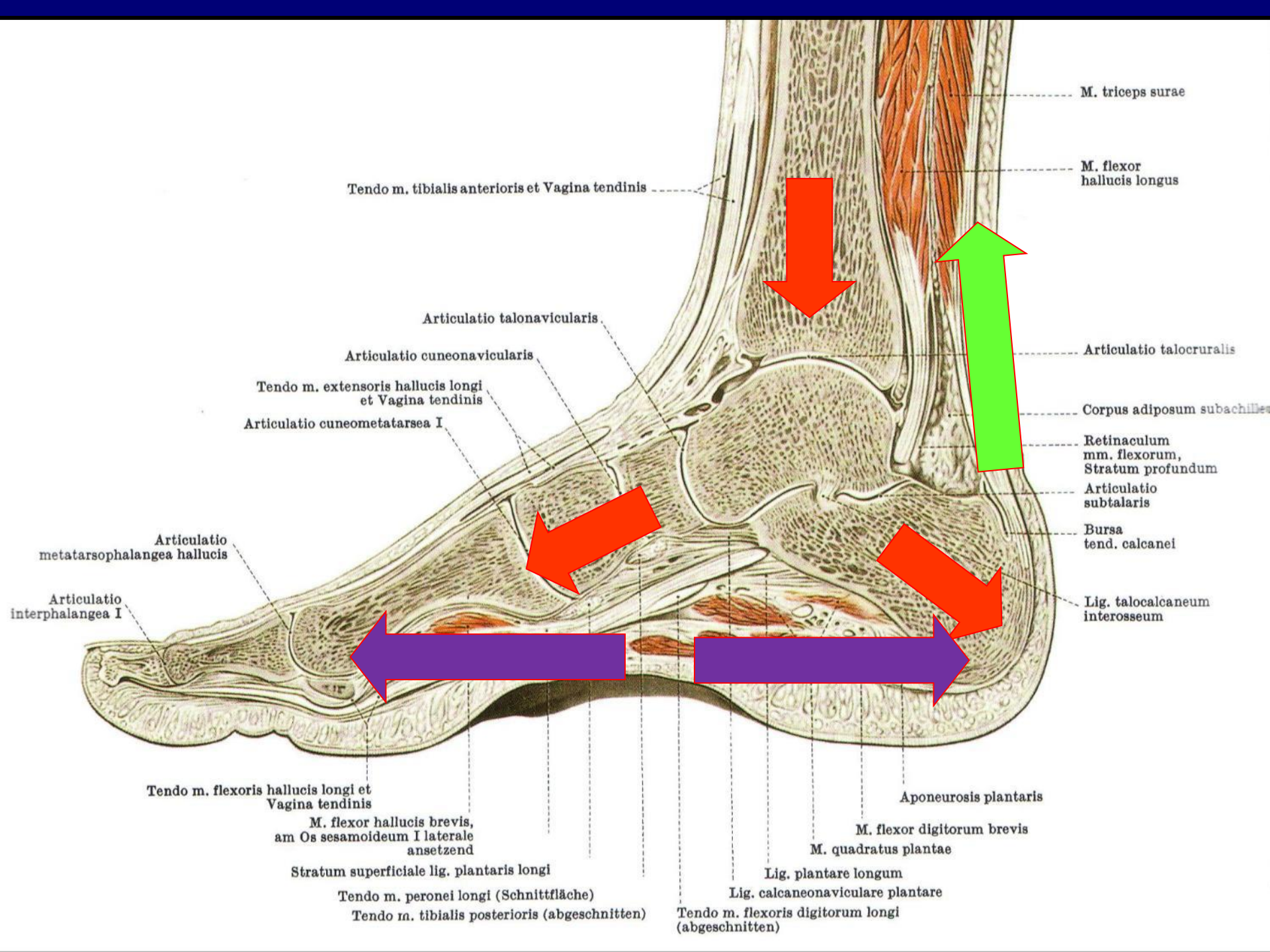


Lisfrancův kloub

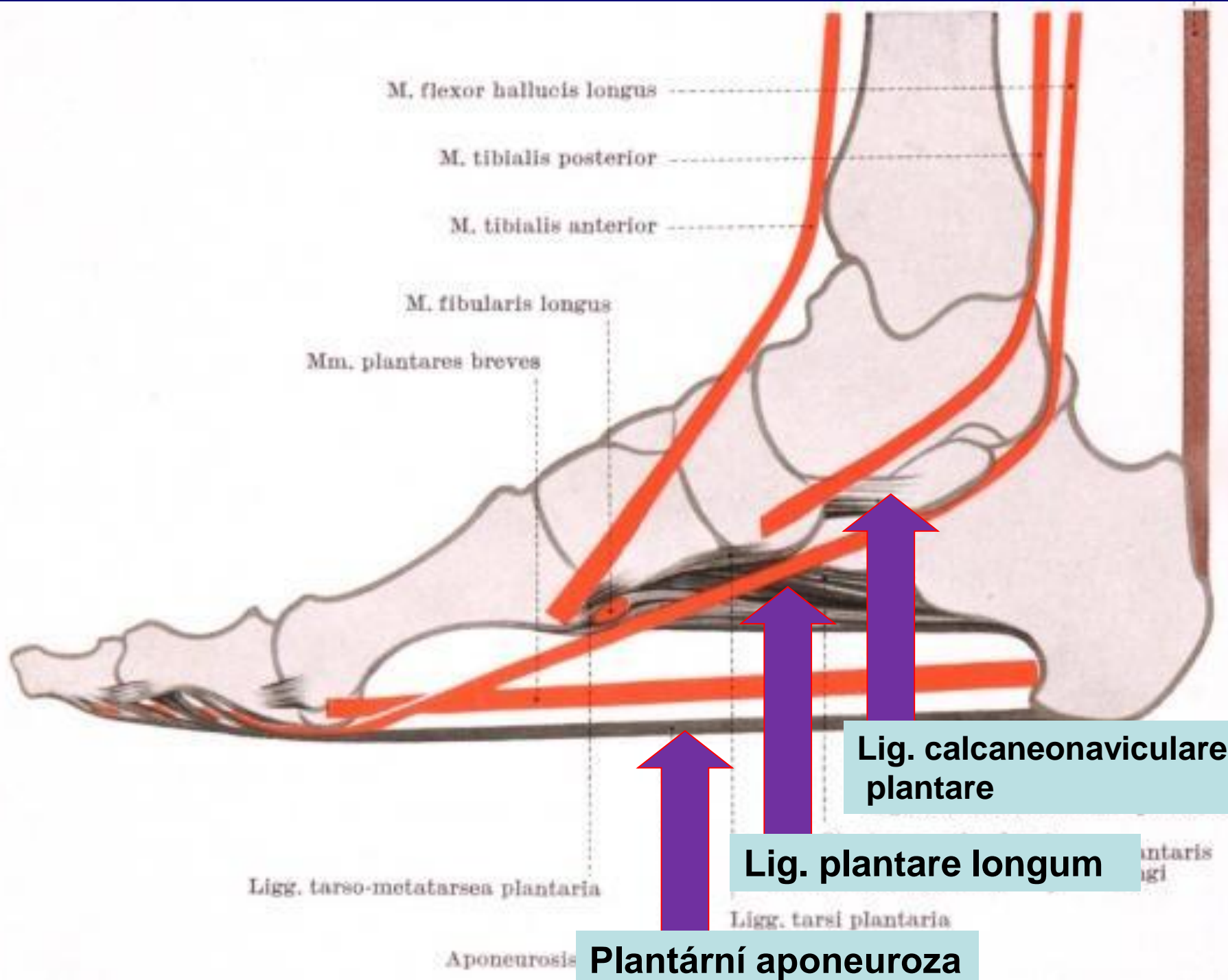




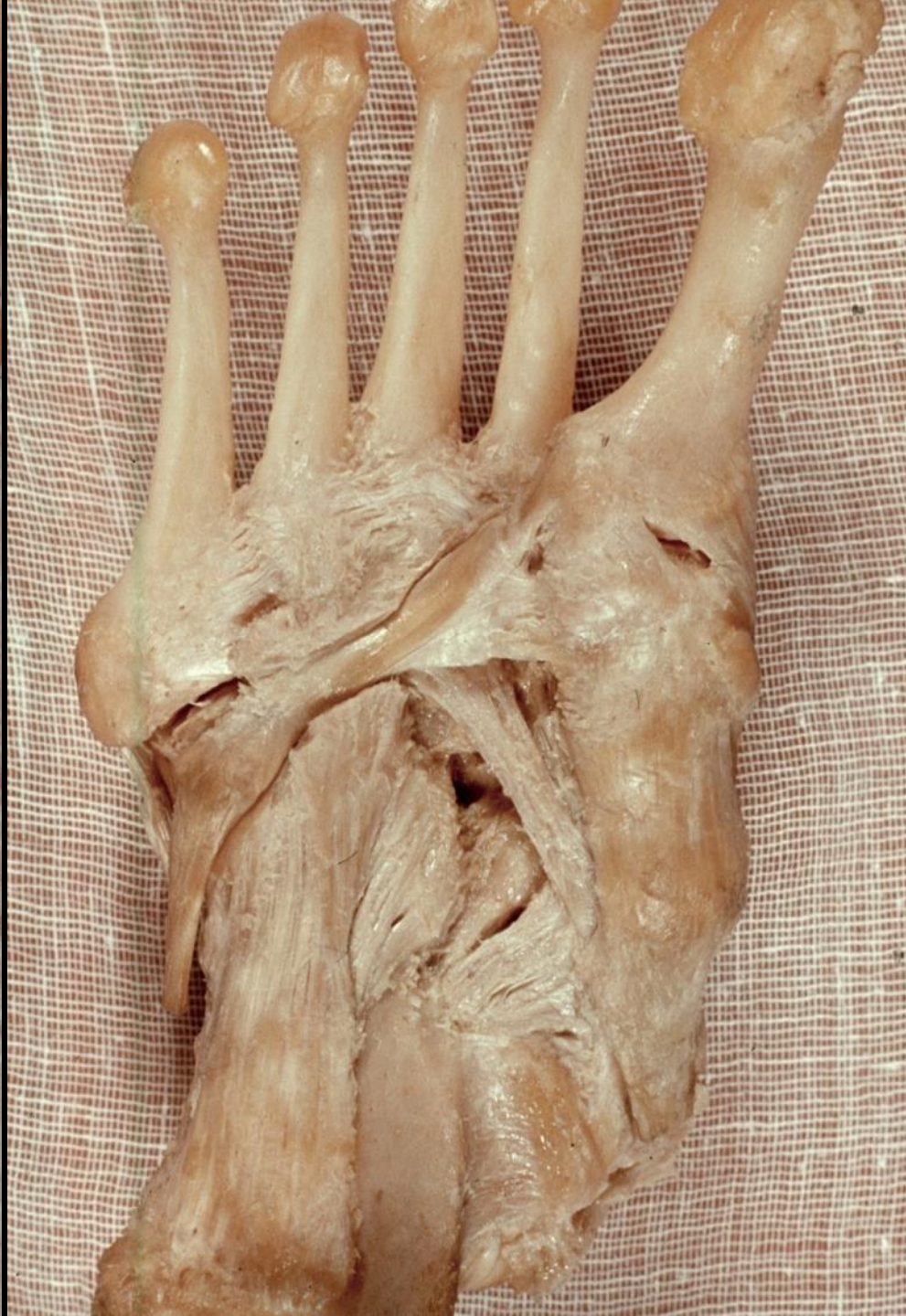
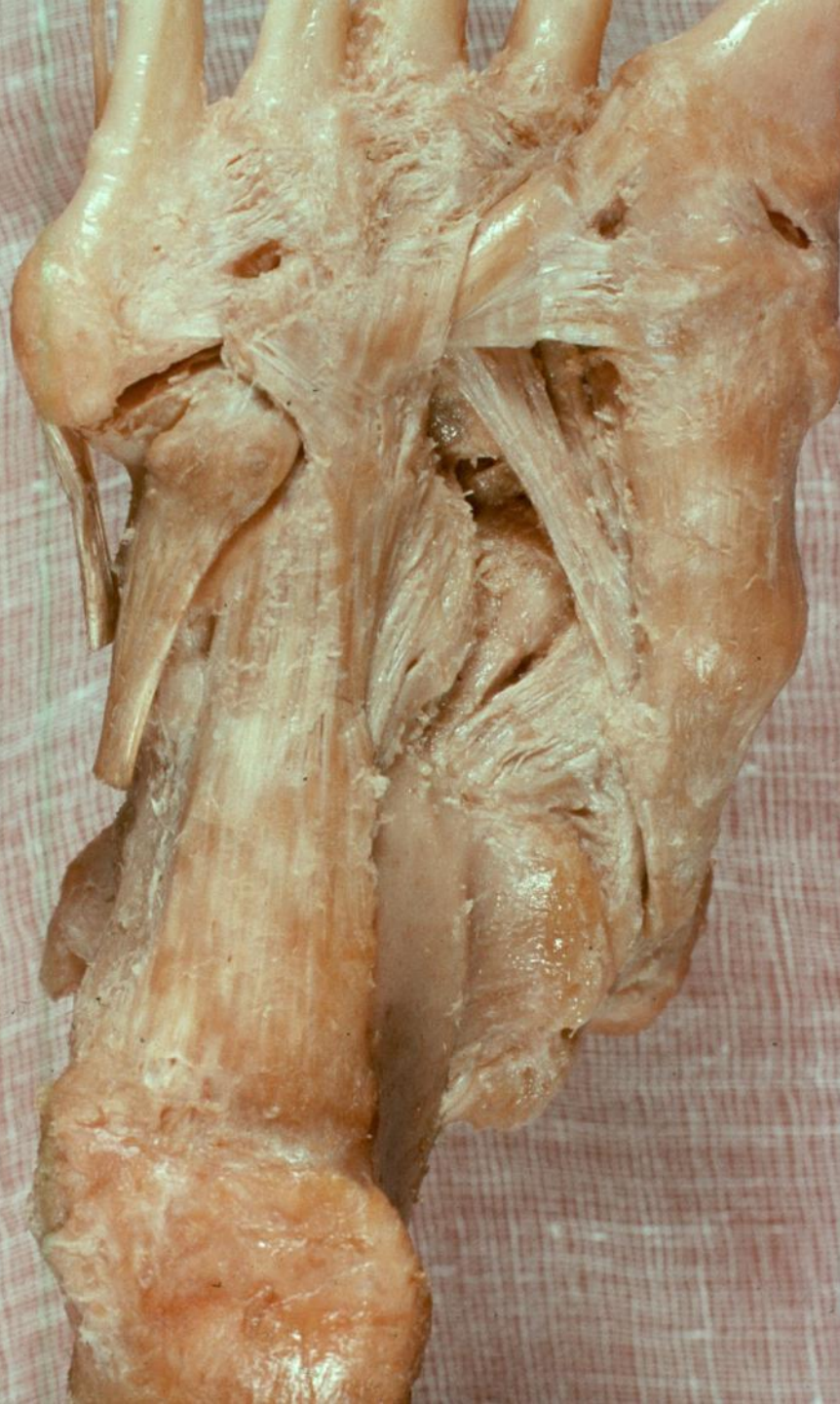






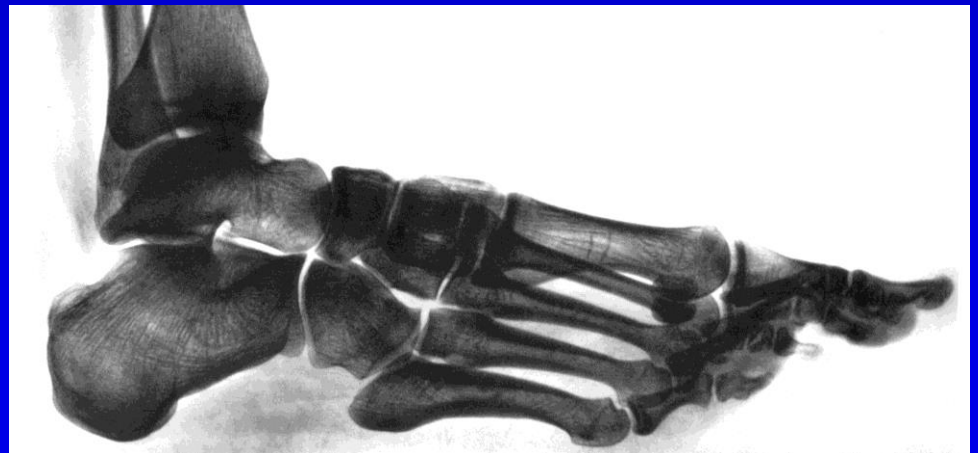






# Základní pensum I

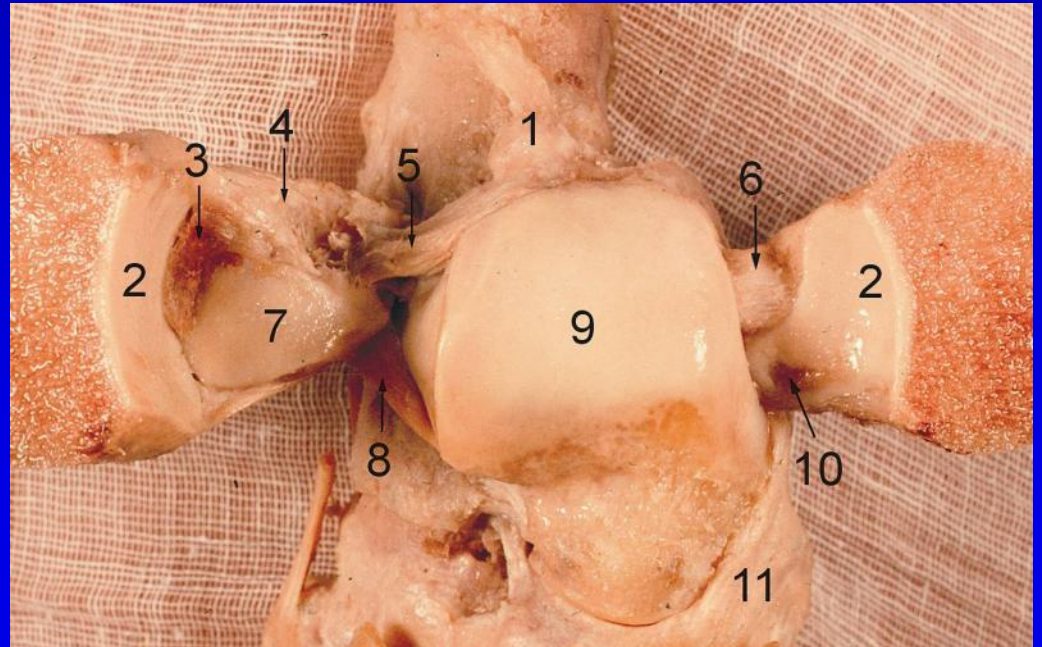
- Hlezenní kloub
- Subtalární kloub
- Chopartův kloub
- Lisfrancův kloub
- Klenba nohy



# Základní pensum II

## Hlezenní kloub

- *Vazy syndesmozy*
- *Fibulární vazy*
- *Deltový vaz*
- *Flexe/Extenze*

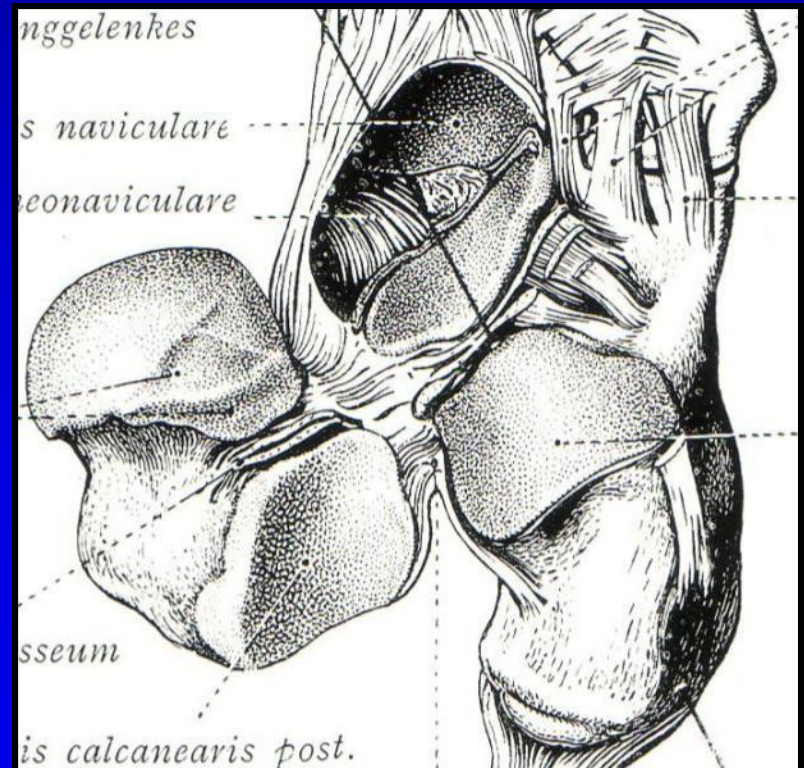




# Základní pensum II

## Subtalární kloub

- *Talus, calcaneus, naviculare*
- *Lig. interosseum*
- *Everze/Inverze*



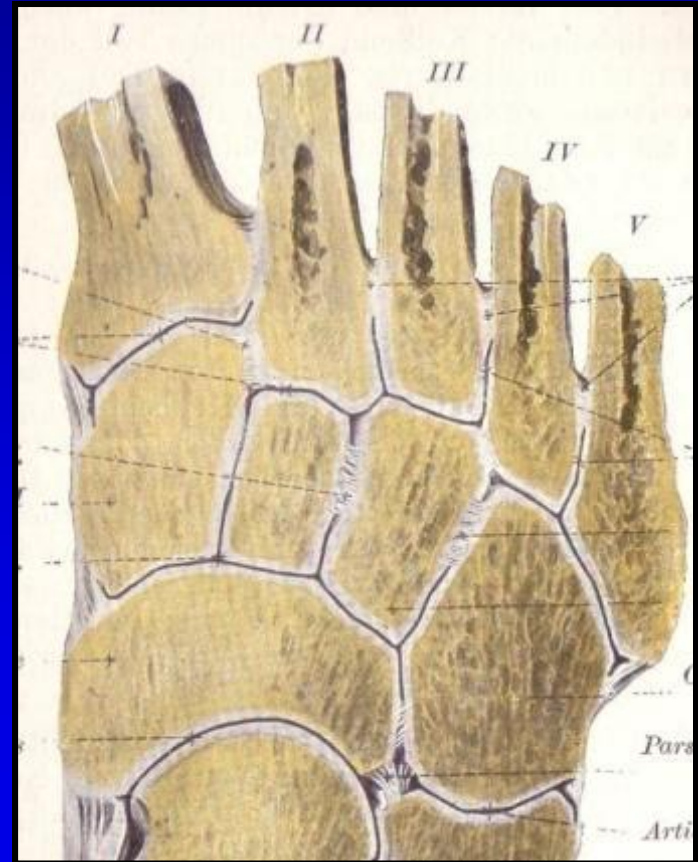
# Základní pensum III

Chopartův kloub

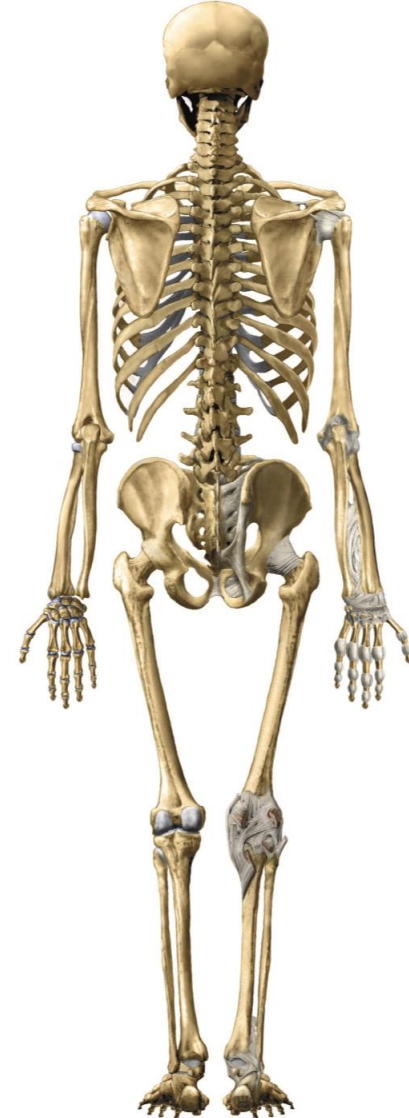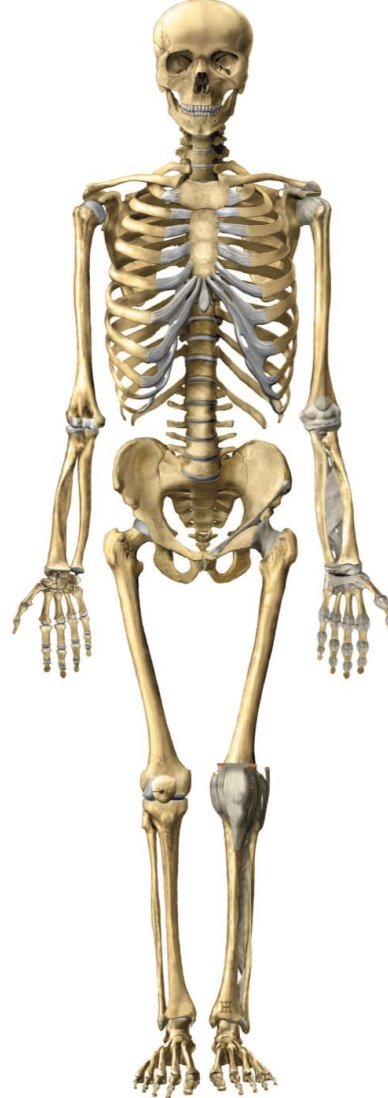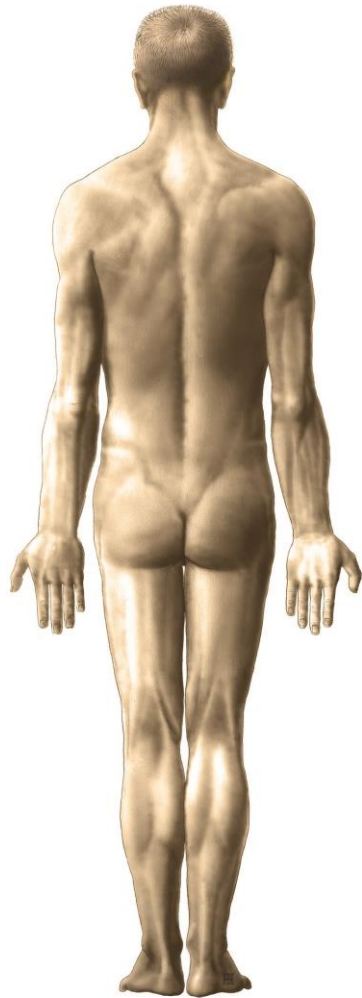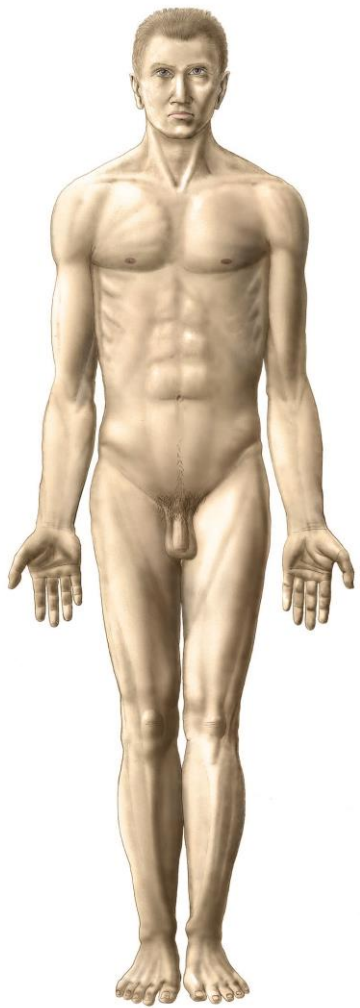
- *Lig. bifurcatum*

Lisfrancův kloub

- *Průběh kloubní linie*







# Obecná stavba končetiny

- Pletenec – Cingulum
- Volná končetina – Stylus

**Stylopodium**

část s jednou kostí

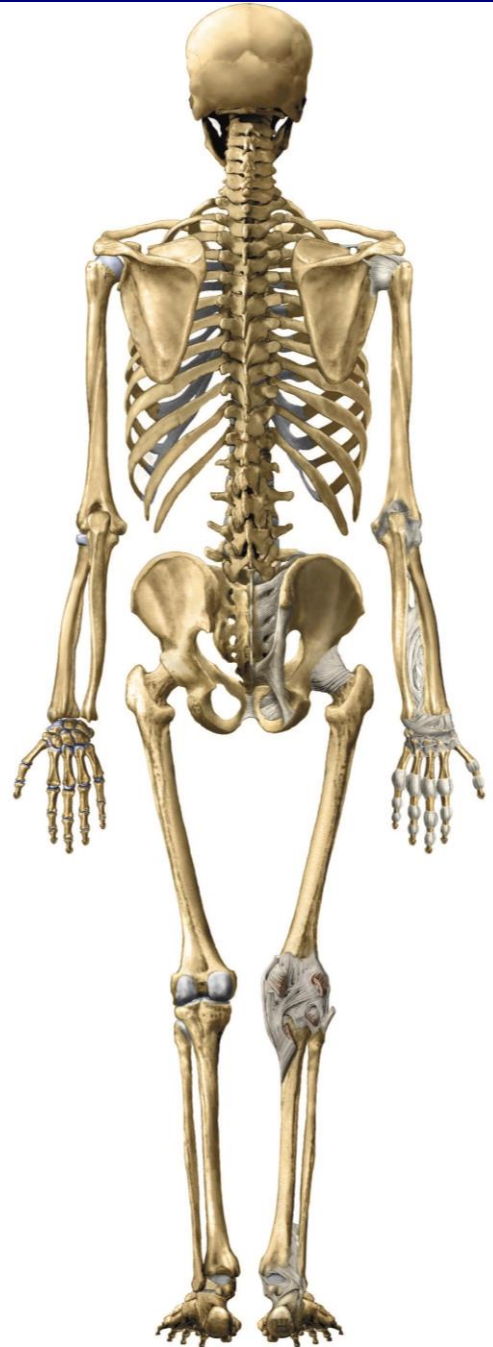
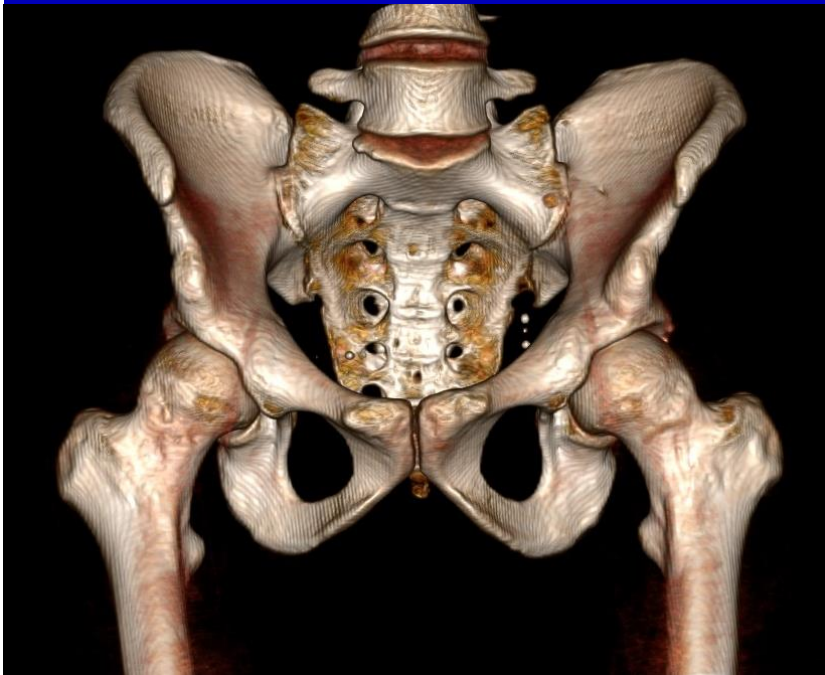
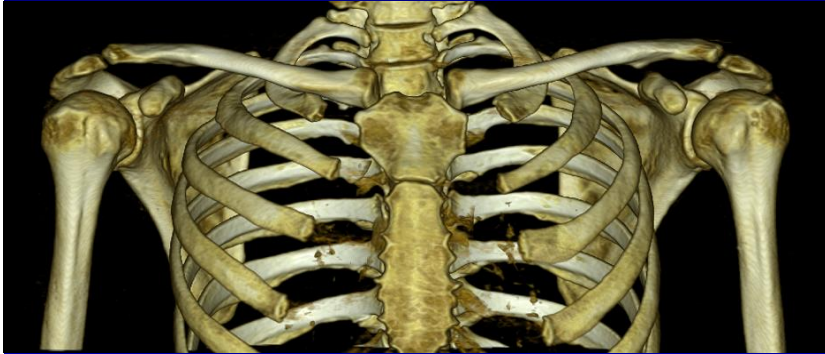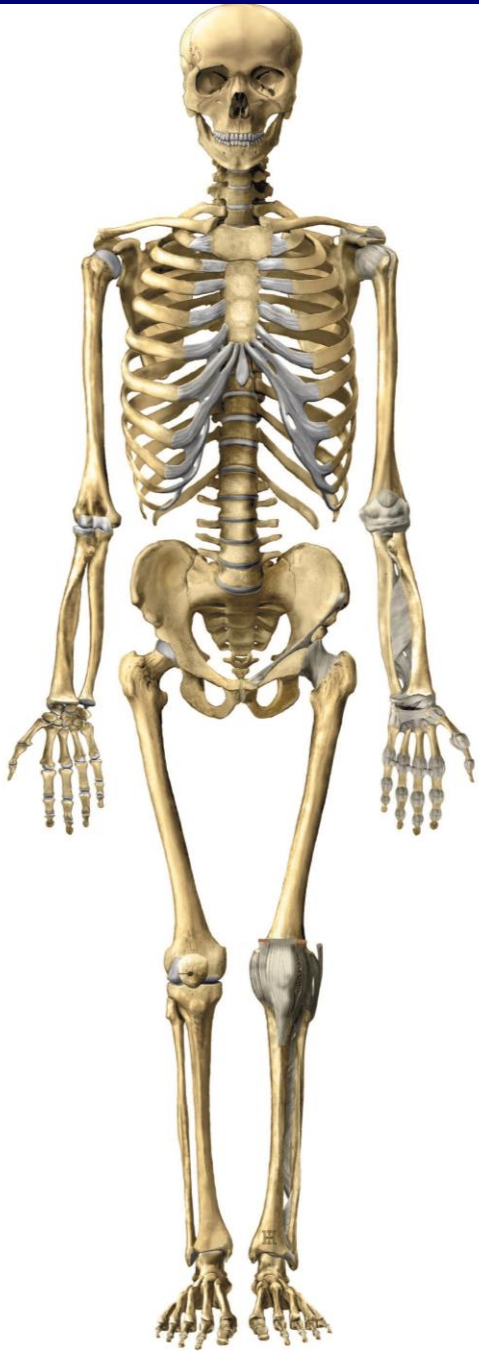
**Zeugopodium**

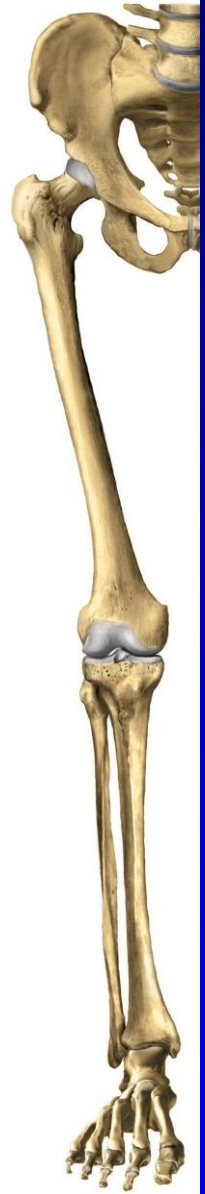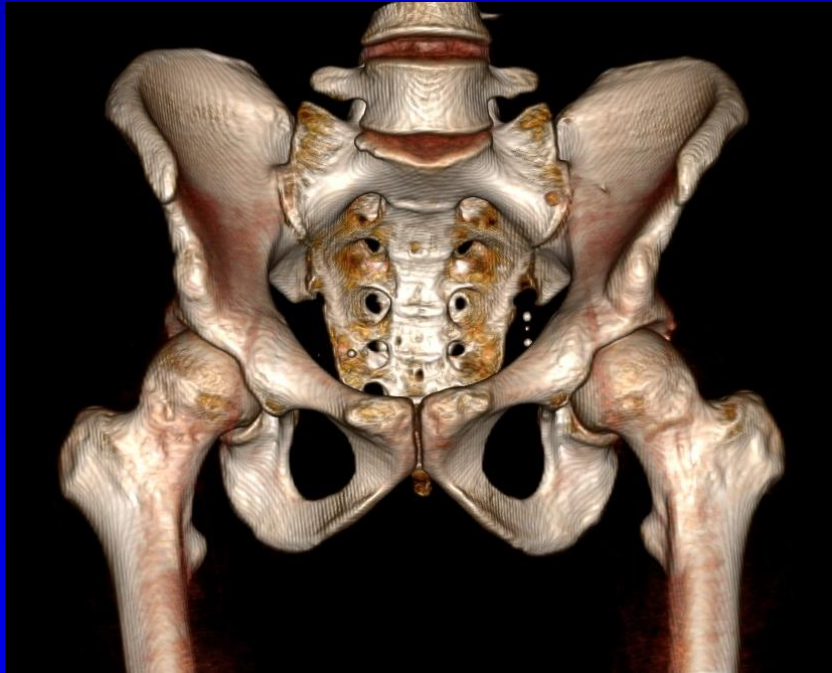
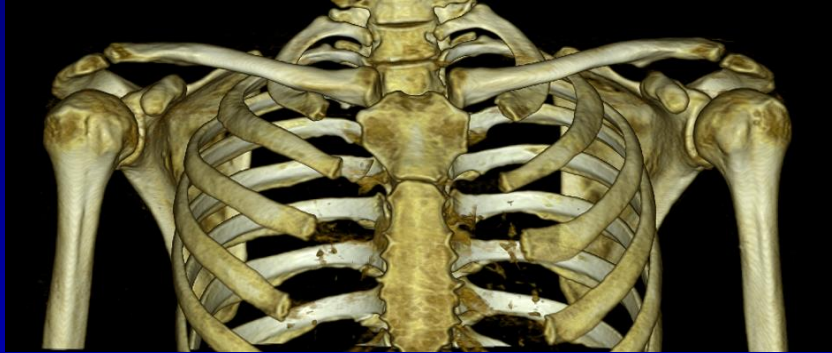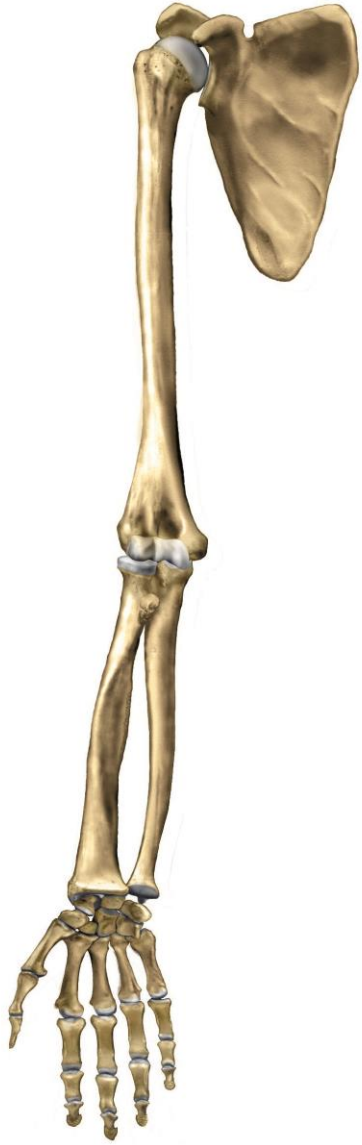část se dvěma kostmi

**Autopodium**

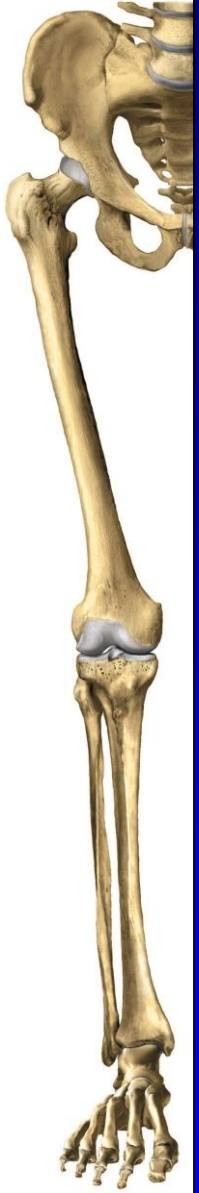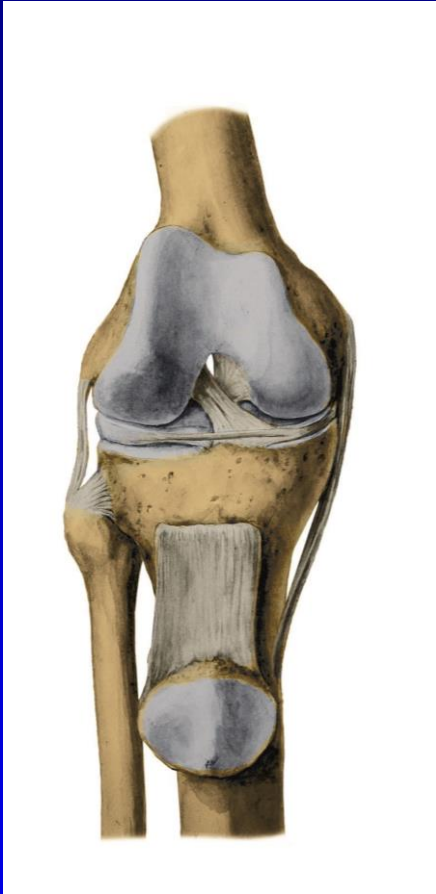
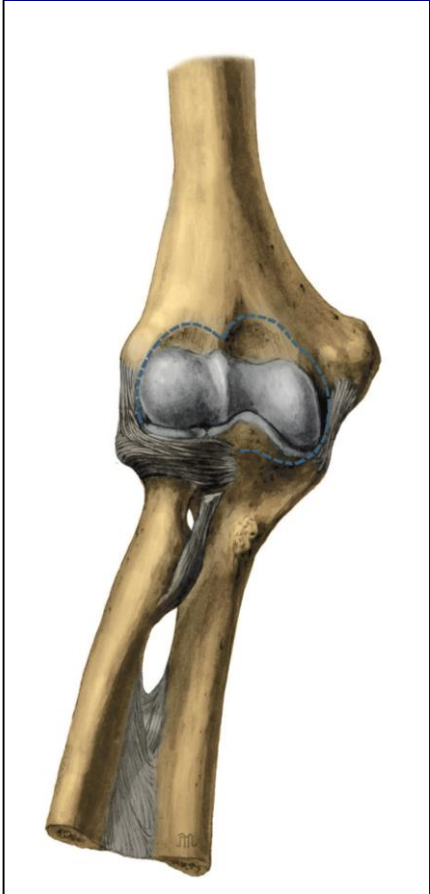
koncová část

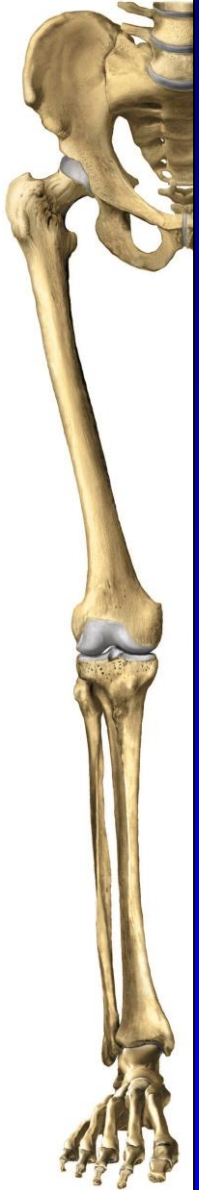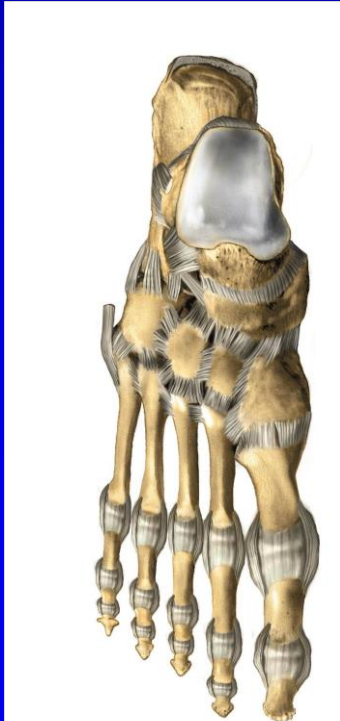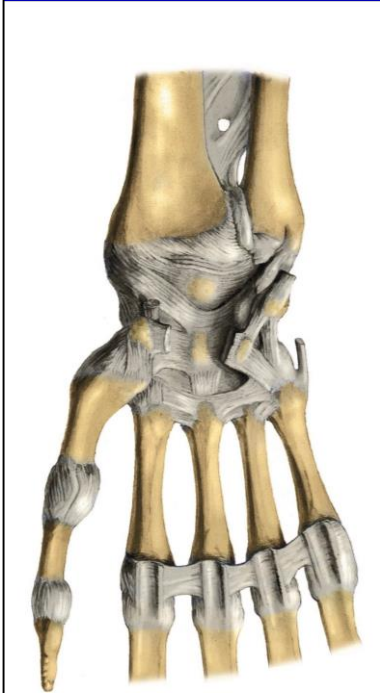


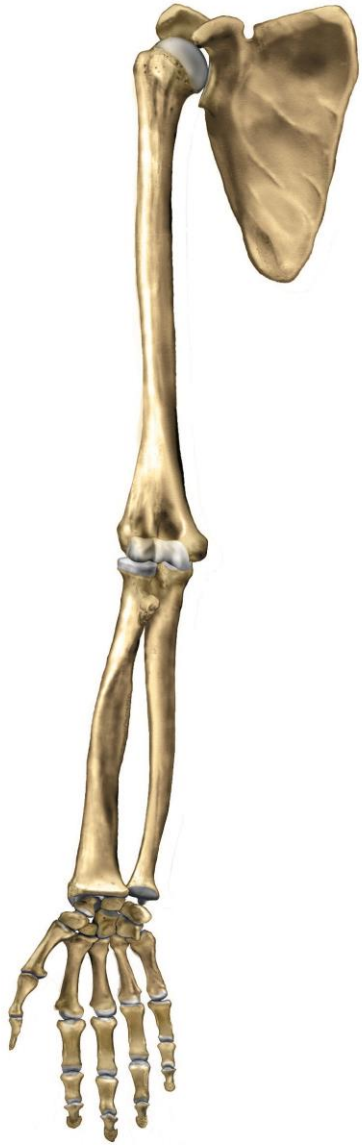











**Děkuji za pozornost**

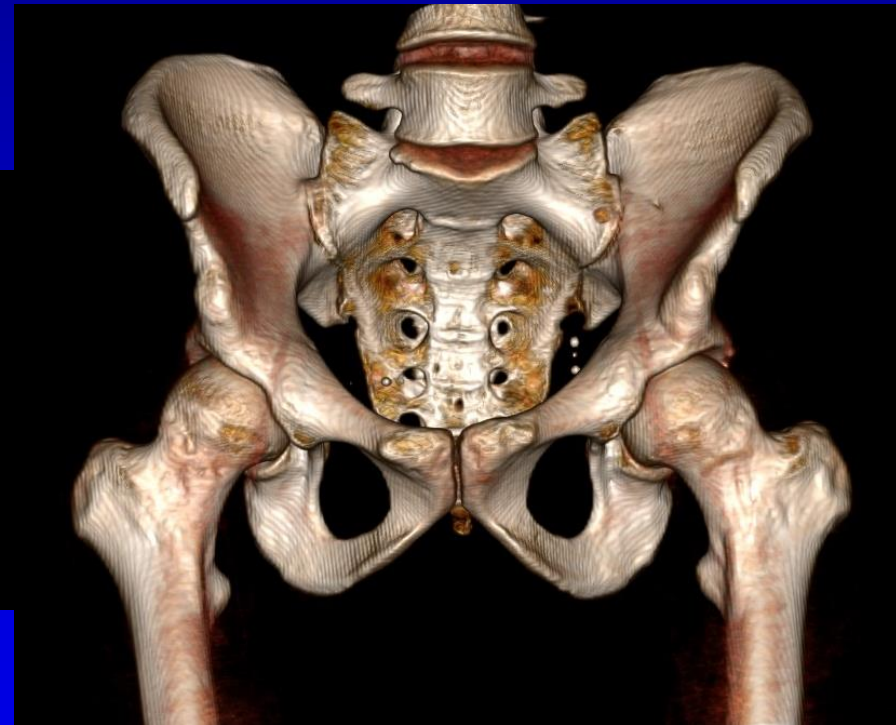
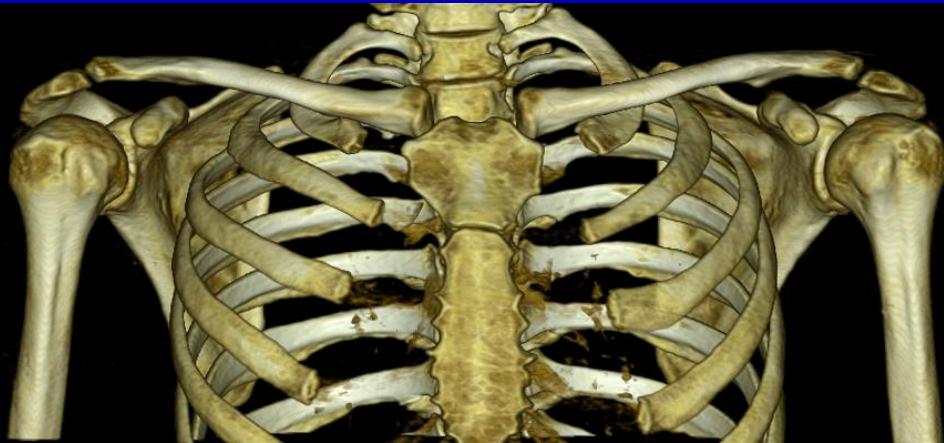

# Obecná stavba končetiny

Pletenec – Stylopodium

Glenohumerální / Kyčelní

Kulový kloub





# Obecná stavba končetiny

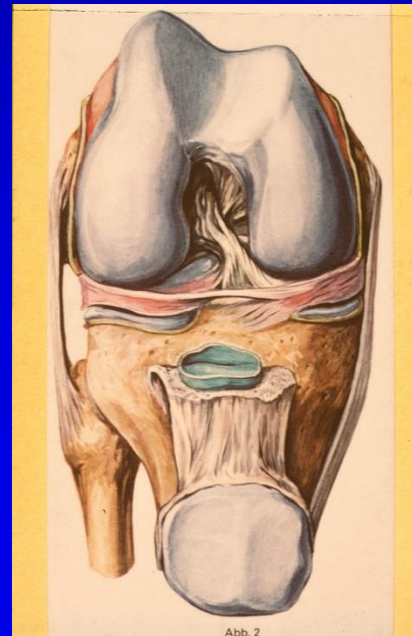
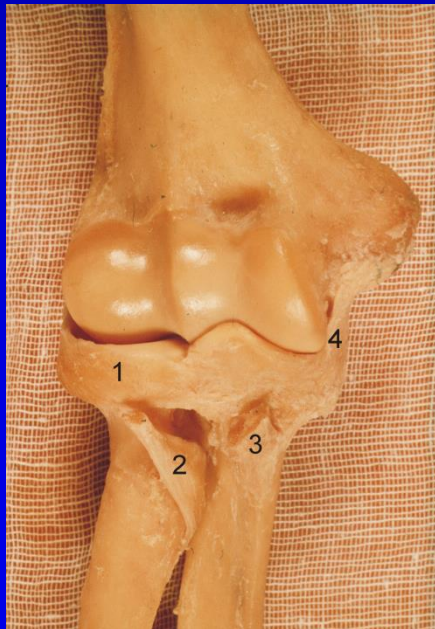
## Stylopodium – Zeugopodium

Humerus

Radius + Ulna

Femur

Tibie (Fibula)



# Obecná stavba končetiny

## Zeugopodium – Autopodium

Radius + Ulna  
Tibie (Fibula)

Zápěstí + Ruka  
Noha

