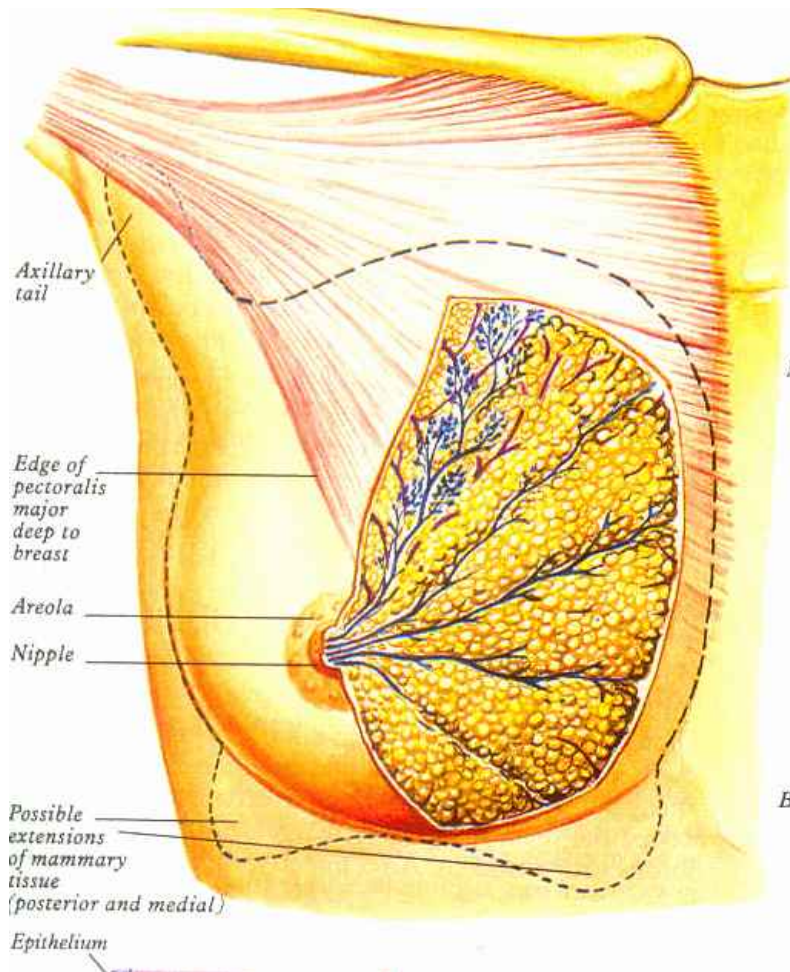
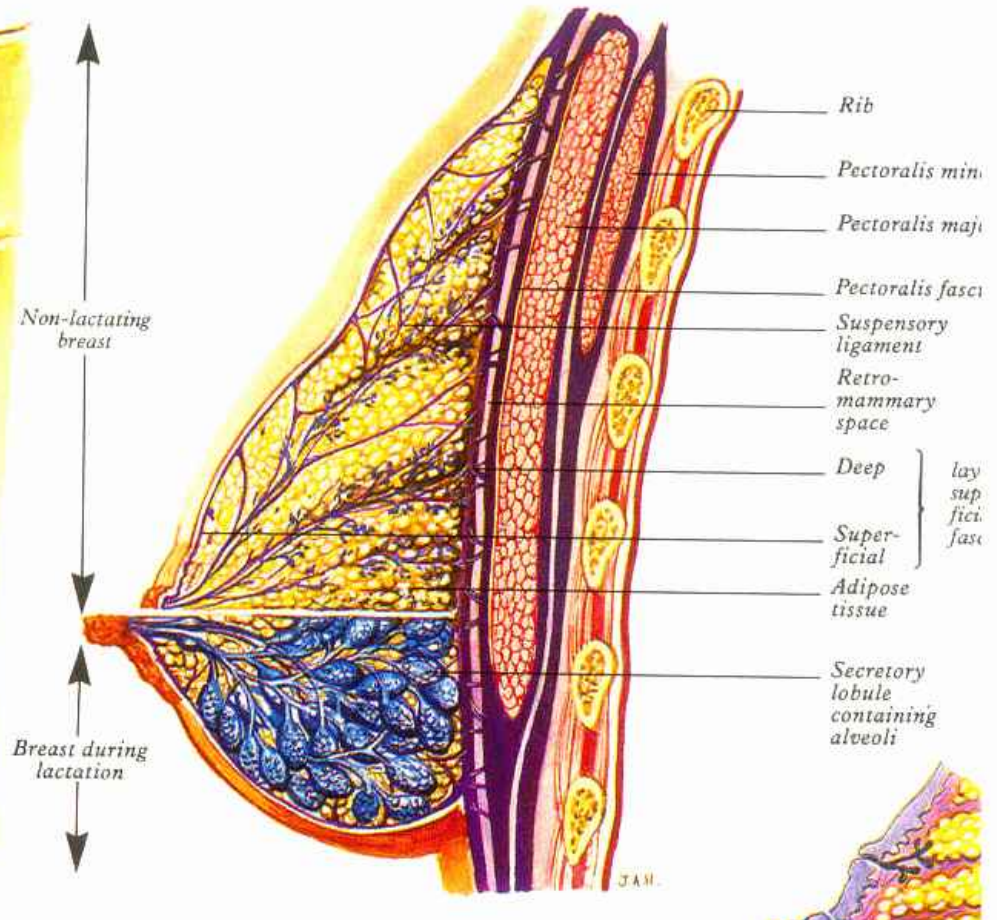


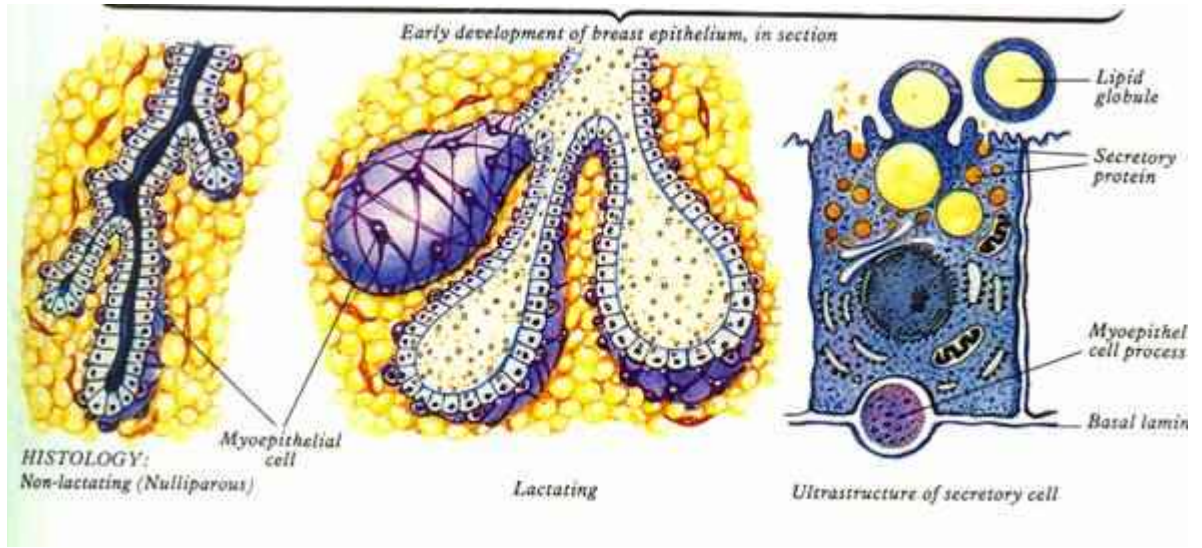
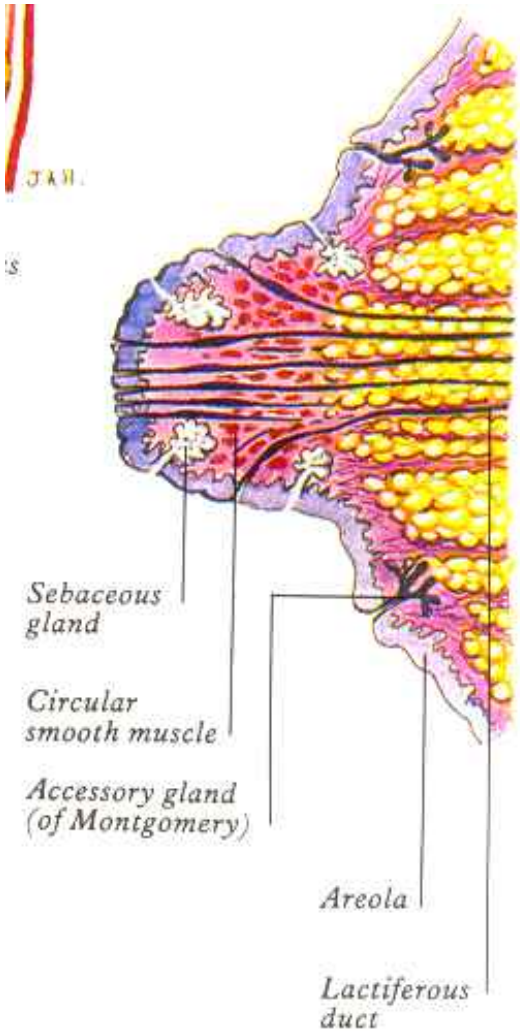
Mammary gland



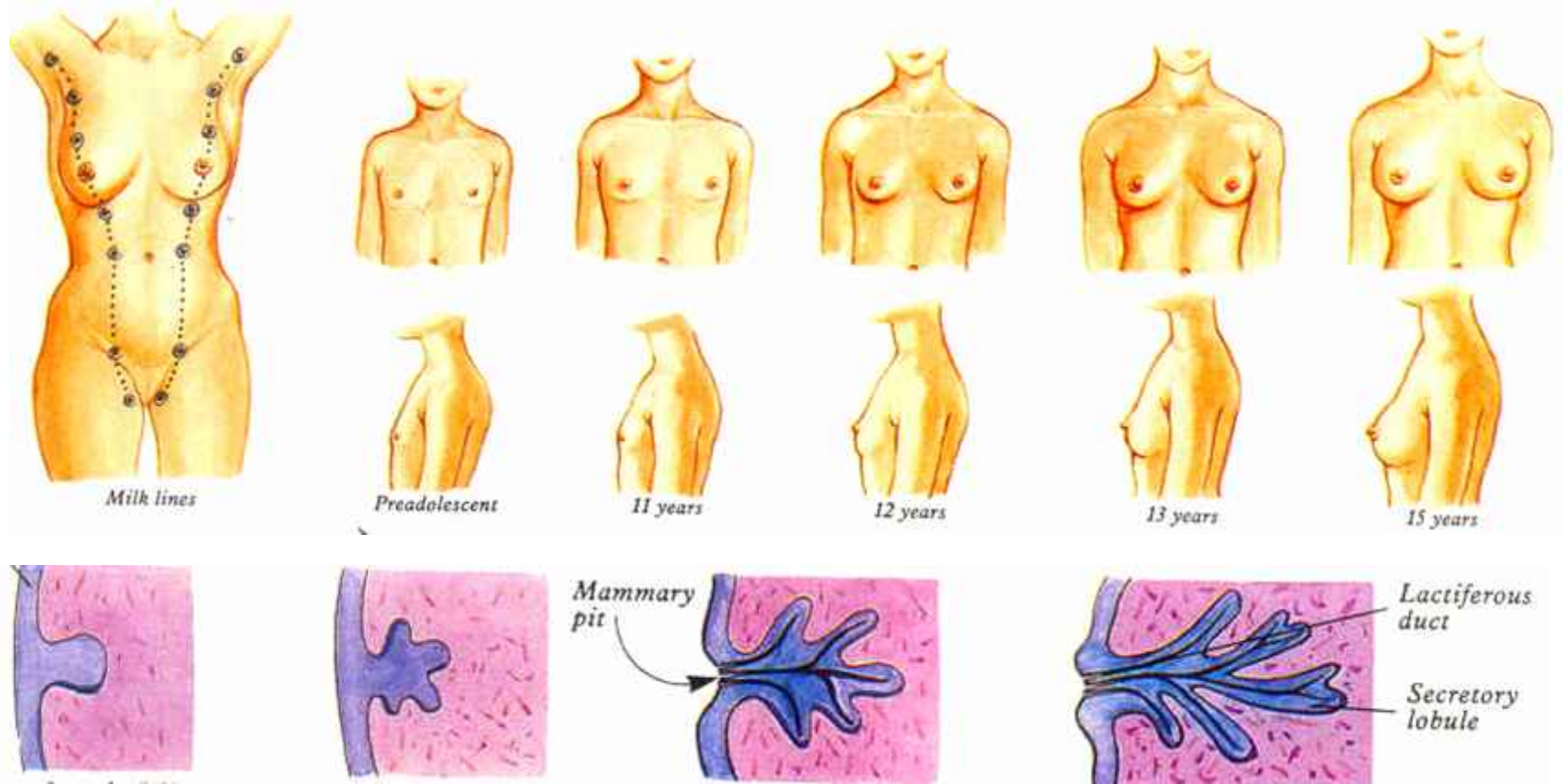
Maturation of the breast



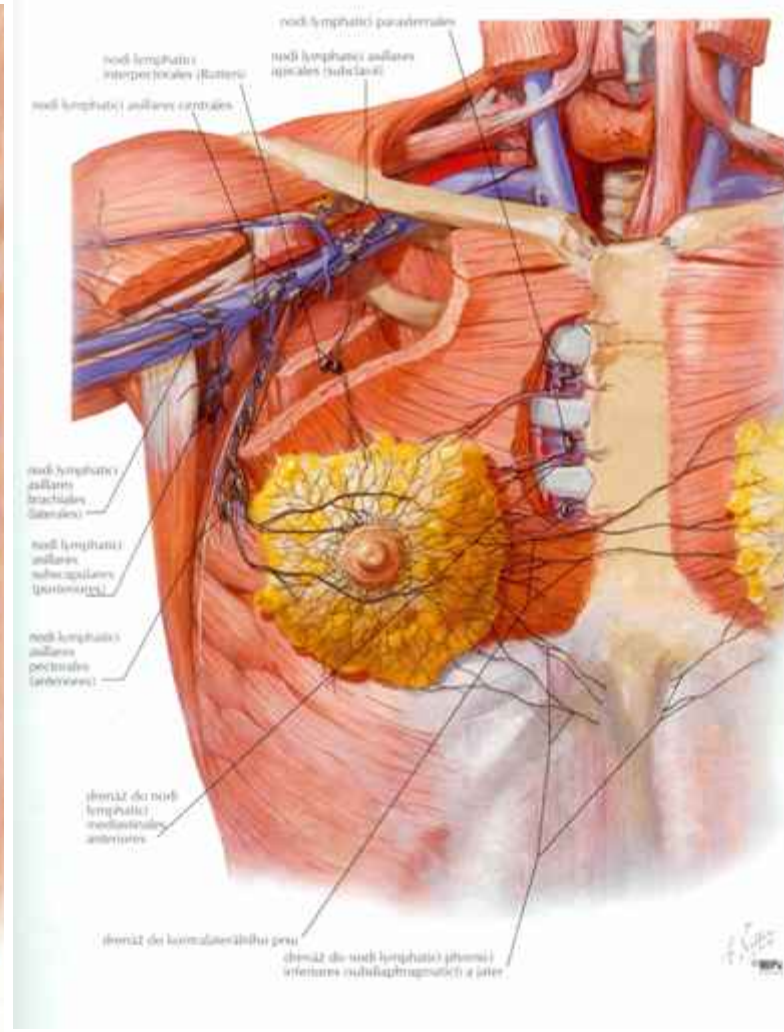
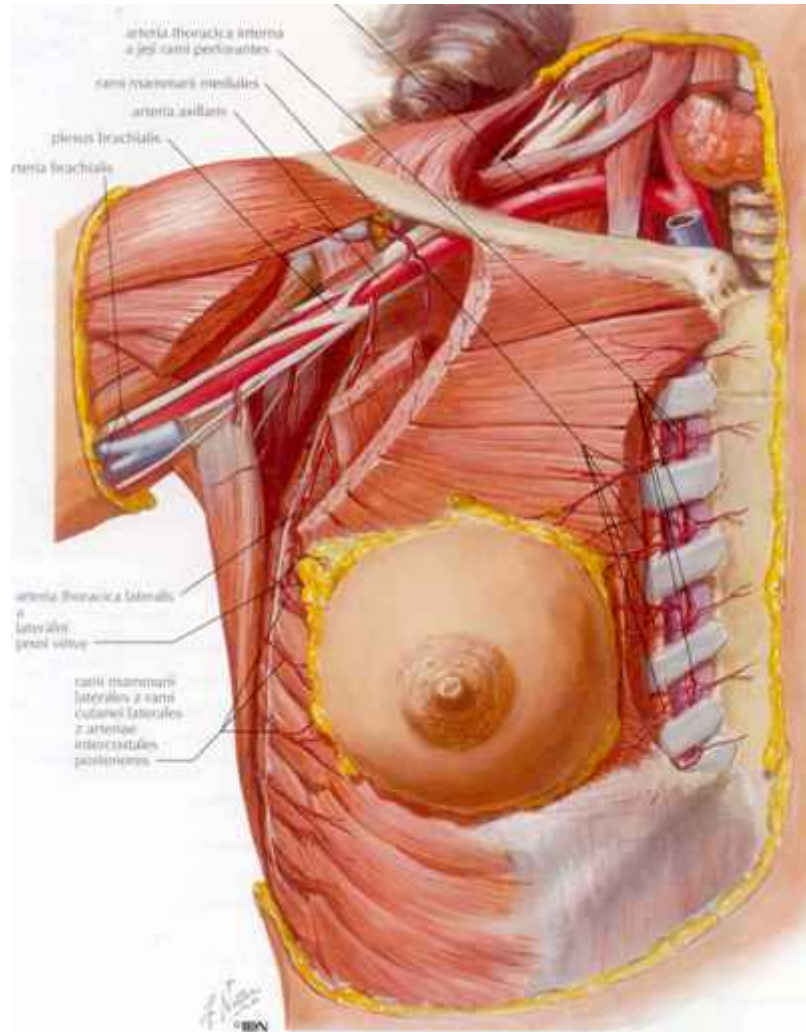
Mammary gland- Structure



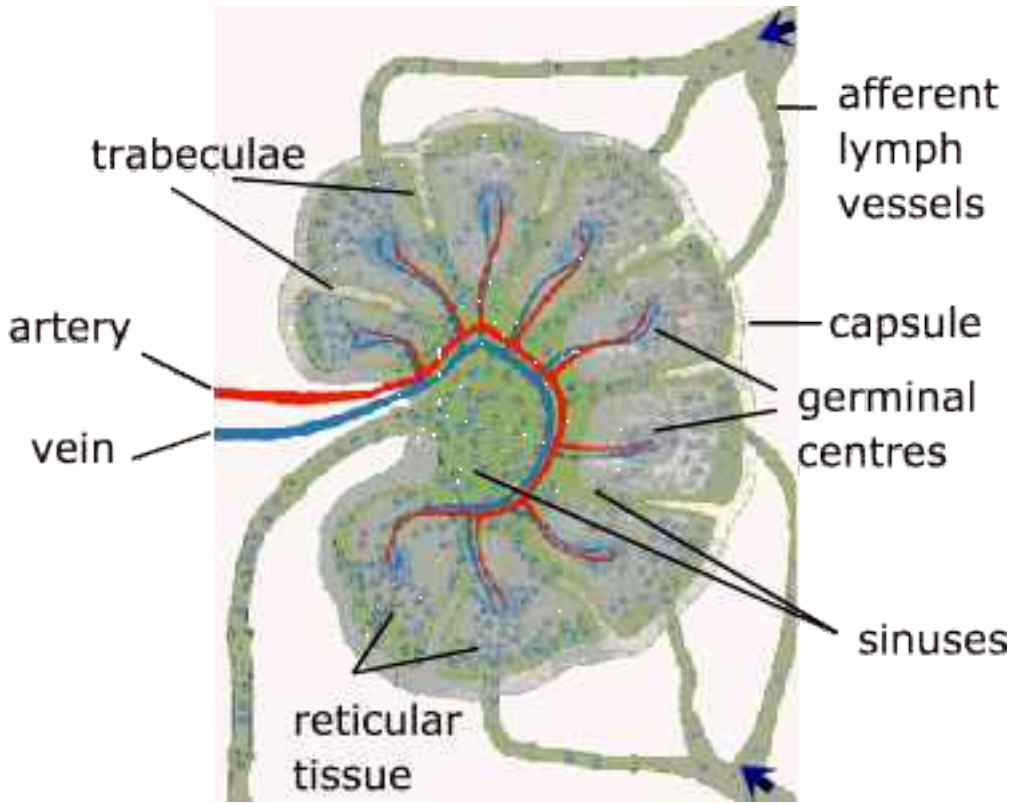
Mammary gland-development



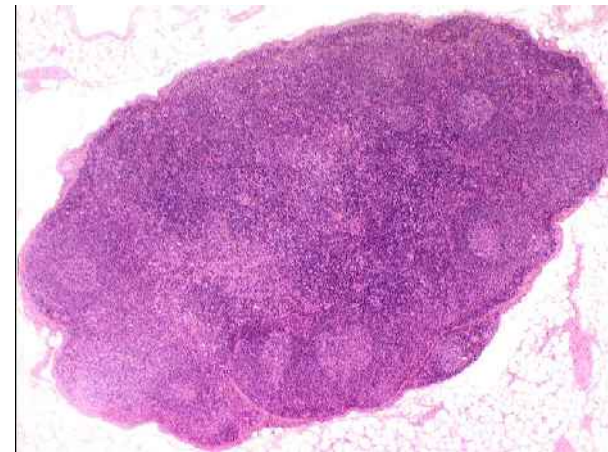
Mammary gland-blood supply and lymphatic drainage



Lymphatic node

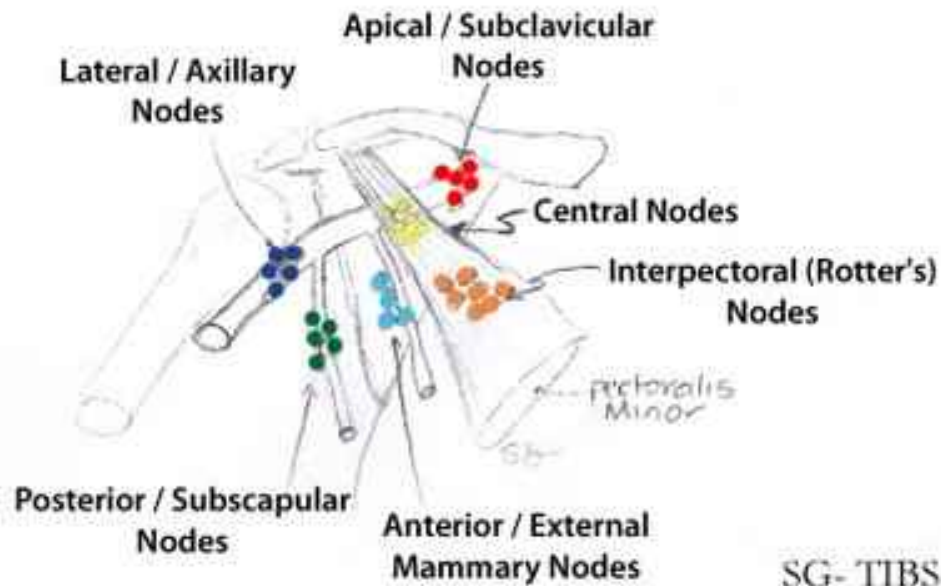


<http://lymphaticmassagenyc.com>

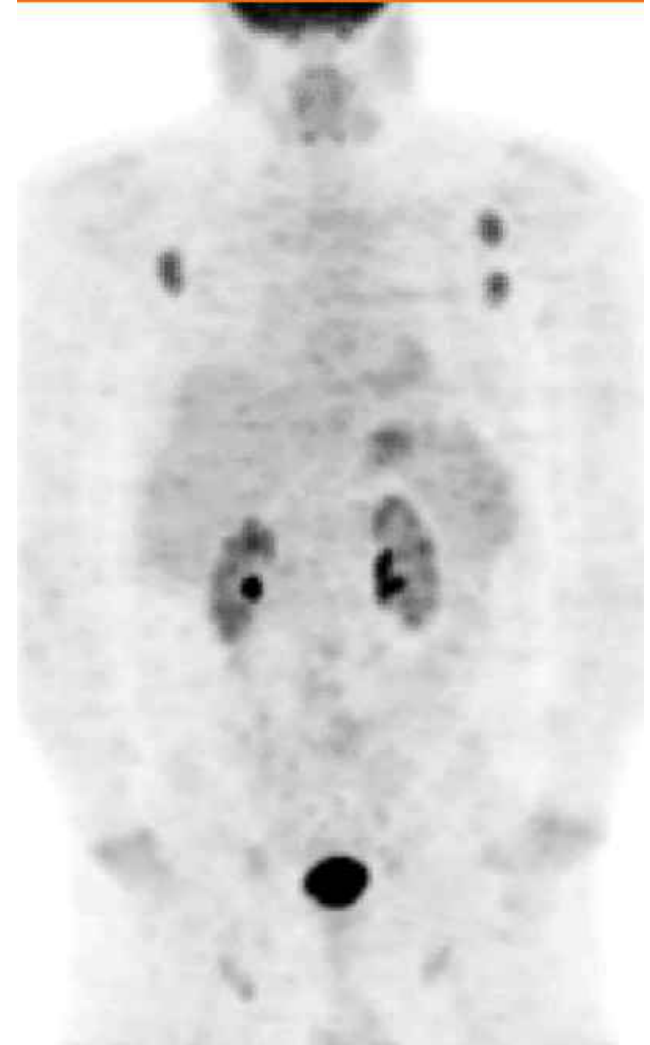


<http://education.vetmed.vt.edu>

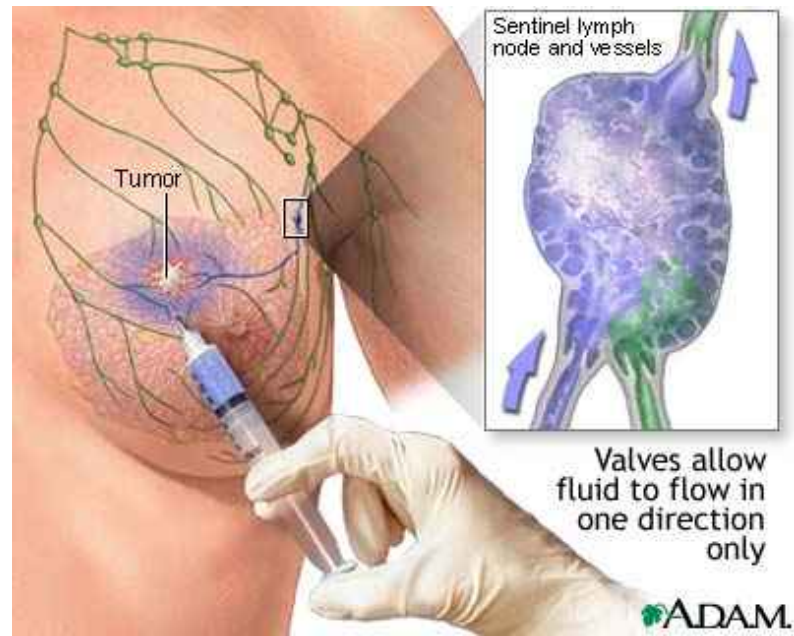
Axillary lymphatic nodes



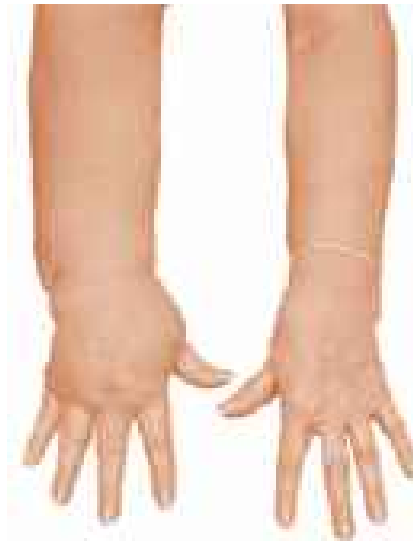<http://3.bp.blogspot.com>



<http://www.medscape.com/viewarticle/>

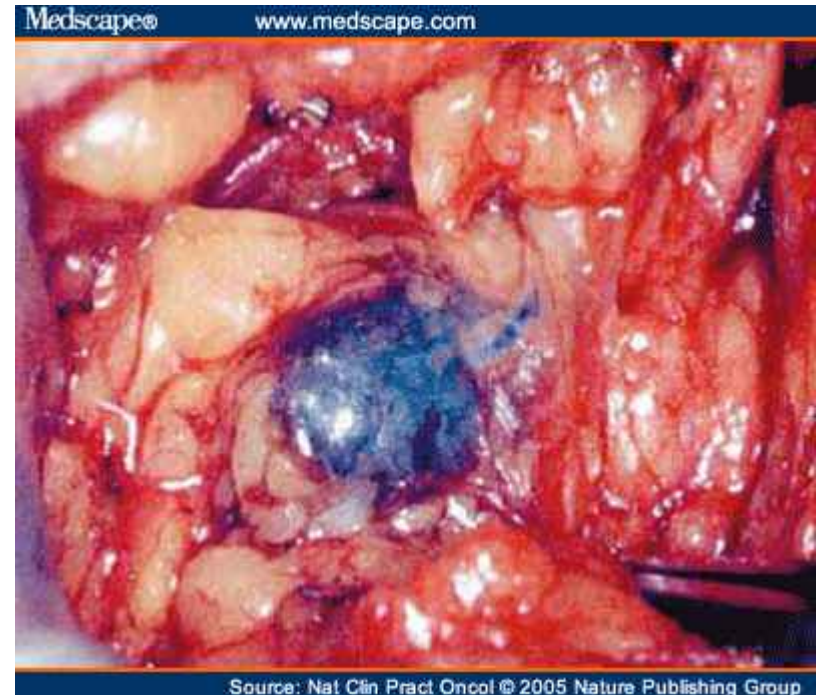


<http://www.clarian.org/>



<http://lymphedemaville.wordpress.com/>

Sentinel lymphatic node detection



<http://img.medscape.com>