

The lymph nodes in the head and neck.  
Lymph drainage in relation to the spreading  
of some pathologic processes.

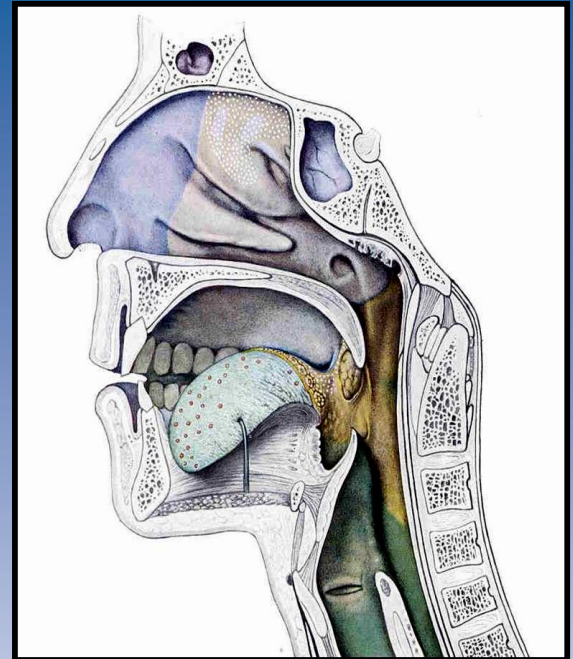
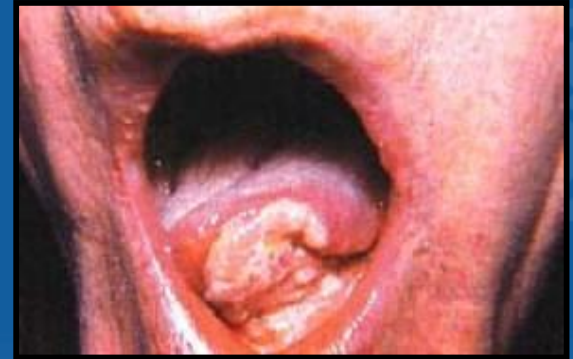Jan Plzák

*Department of Otorhinolaryngology and Head  
and Neck Surgery*

*1st Faculty of Medicine, Charles University, Prague*

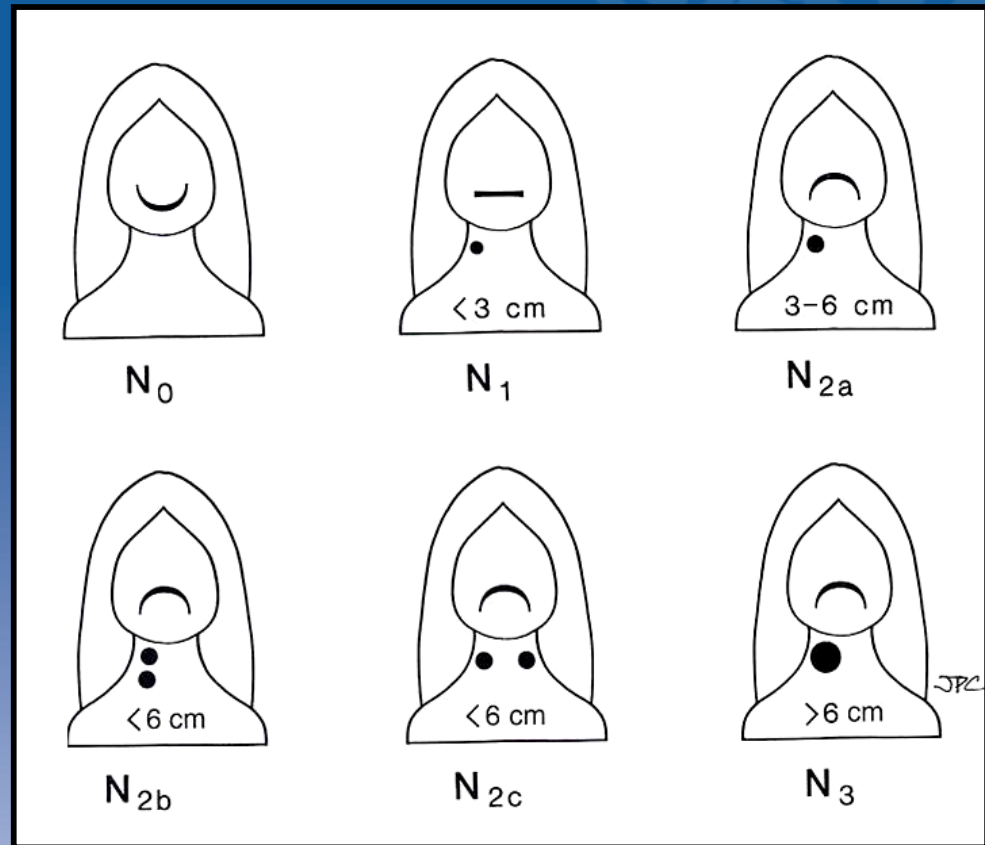
# Head and necks squamous cancer

- ↑ 5th most frequent malignancy
  - (500 000/year worldwide)
- risk factors: smoking, alcohol
- oral cavity, oropharynx, larynx, ...



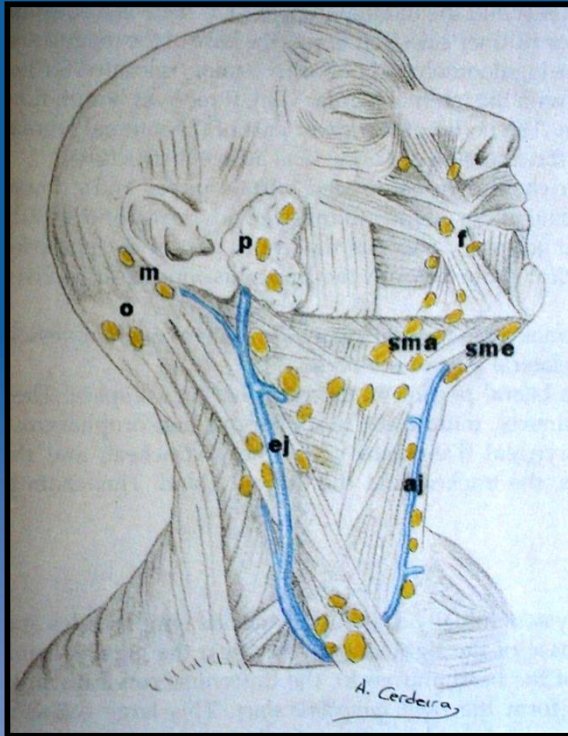
- Lymph node metastasis is the most important prognostic factor

- Survival N+ < N0 of 50%!
- Risk of meta  $\geq$  20% = indication for elective treatment

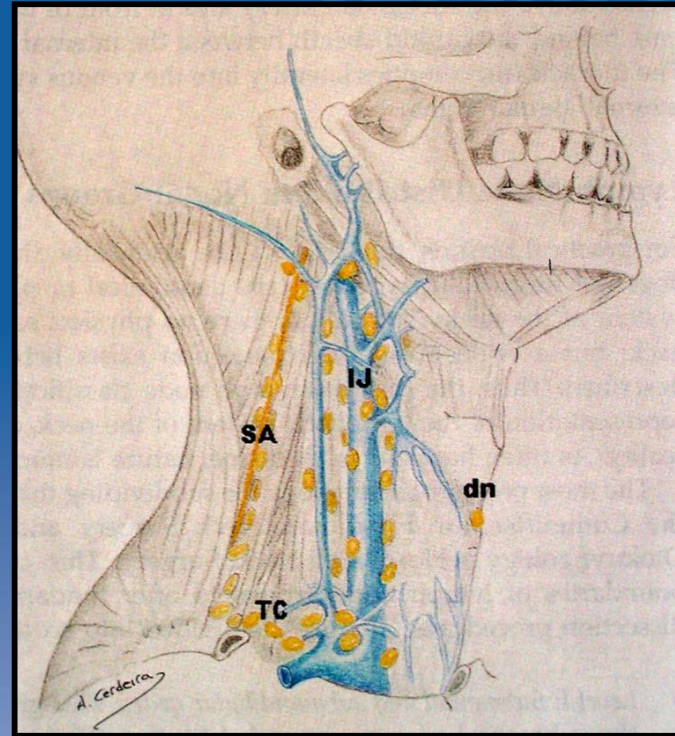


# Factors influencing the creation of lymphatic metastasis

- Location of primary tumor
- Size of primary tumor
- Depth of infiltration of primary tumor
- Differentiation grade
- Molecular parameters
- lymphatic metastasis process is predictable (localization, risk)

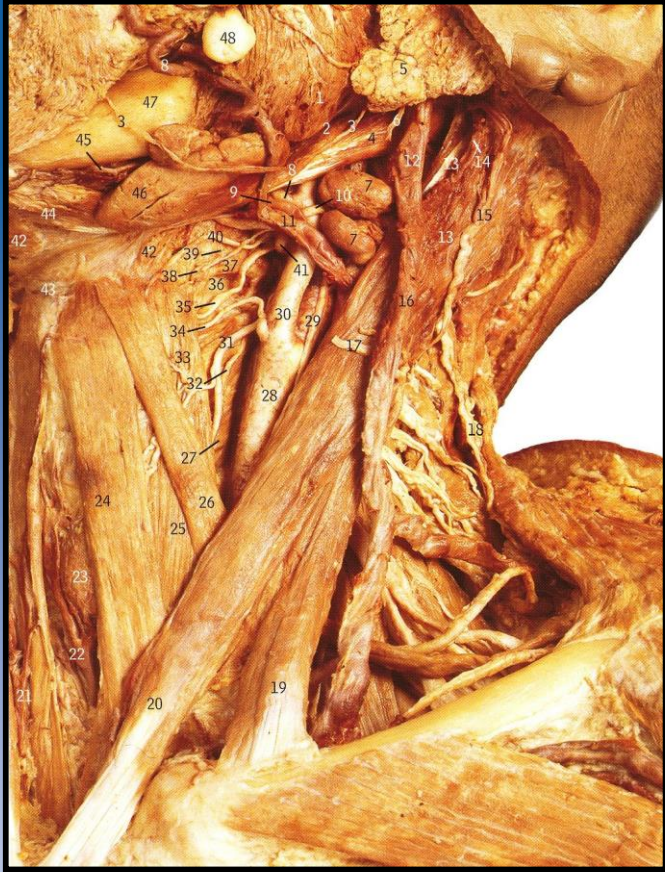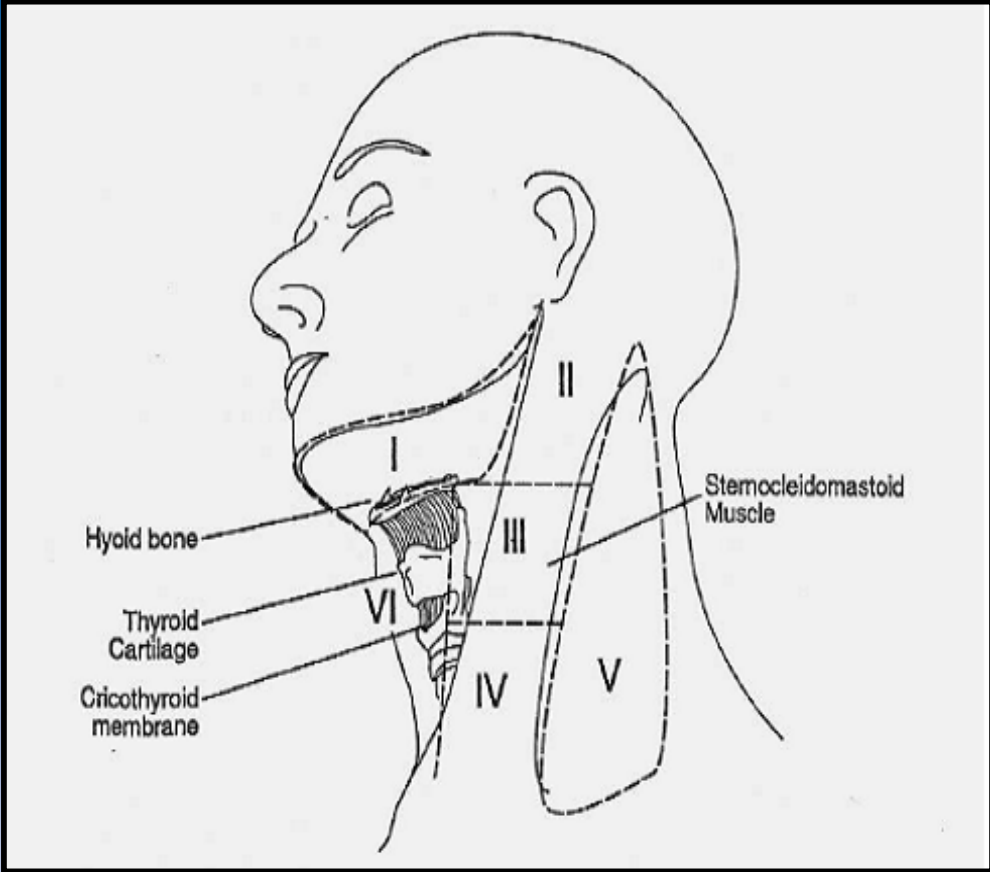


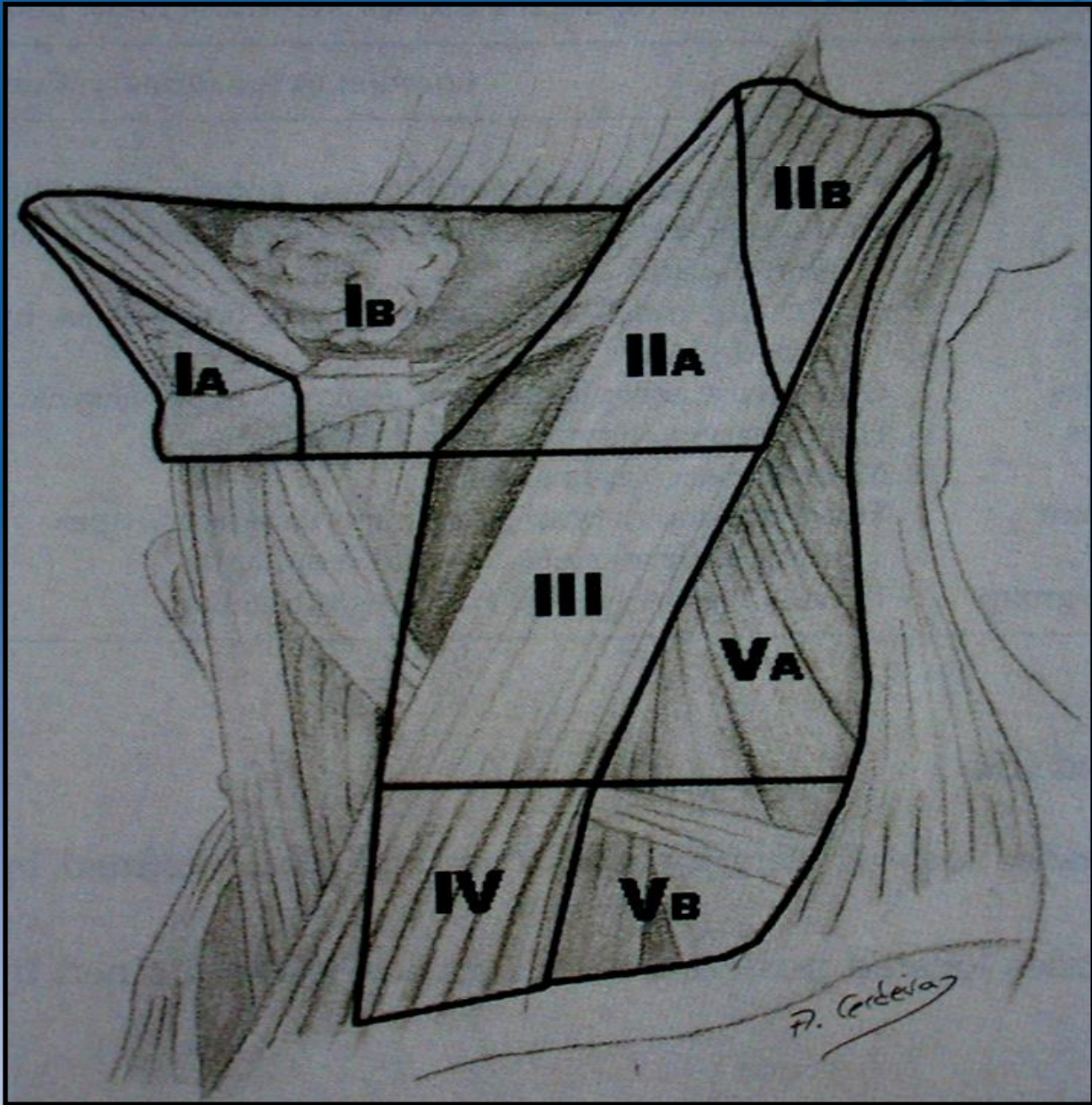
superficial system



deep system

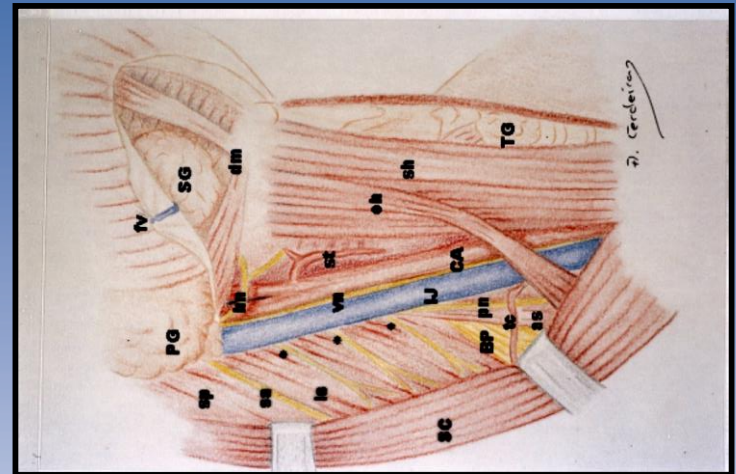
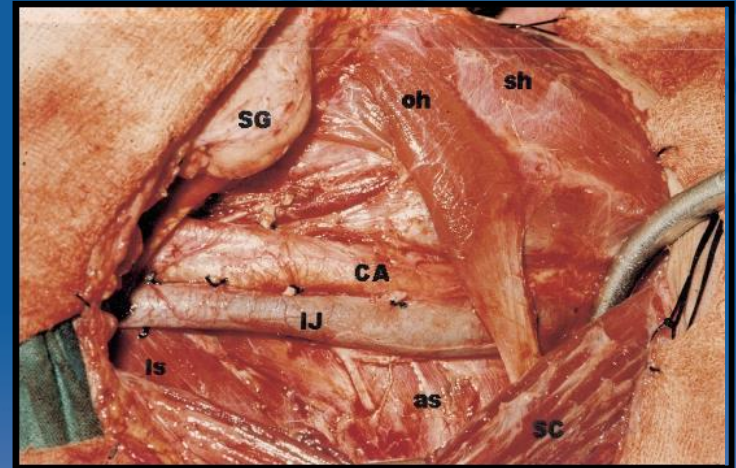
# Classification of neck lymph nodes





# Neck dissection

- Systematic removal of neck lymph nodes (+ non-lymphatic structures: SMG, SCM, IJV, AN, etc)
- Clearly defined anatomical borders - compartments

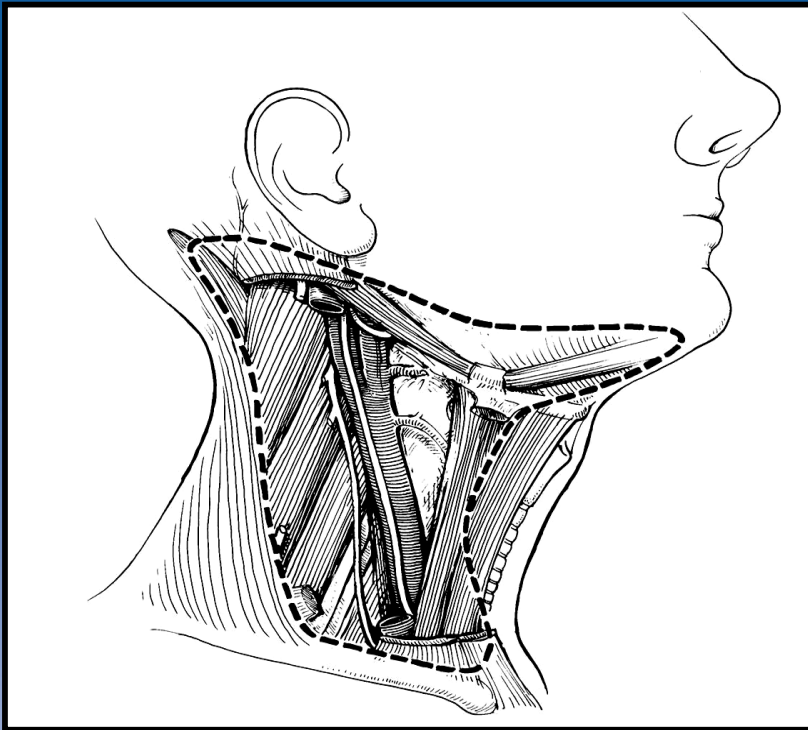




# Classification of ND

- Radical: I-V + SCM+IJV+N XI
- Modified: I-V with preservation of non-lymphatic structures (N XI, IJV, SCM)
- Selective: preservation of some level
- Extended: + resection of other non-lymphatic structure

# RADICAL NECK DISSECTION



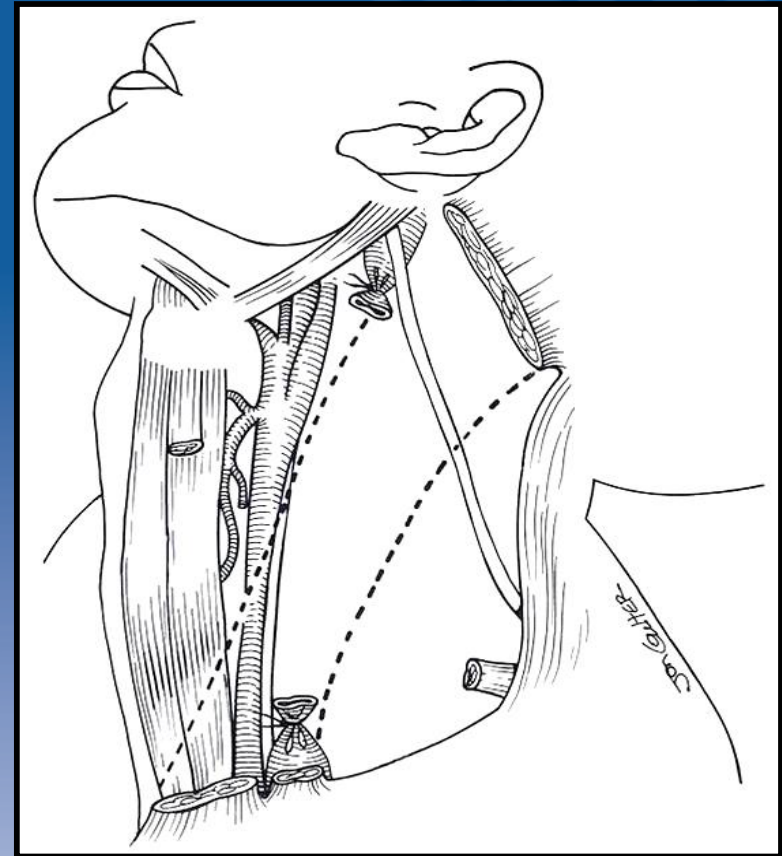
- RND: I-V + MSCM+VJI+N XI  
(I-V: comprehensive)

c TX N2b – N3

# MODIFIED RND TYPE I

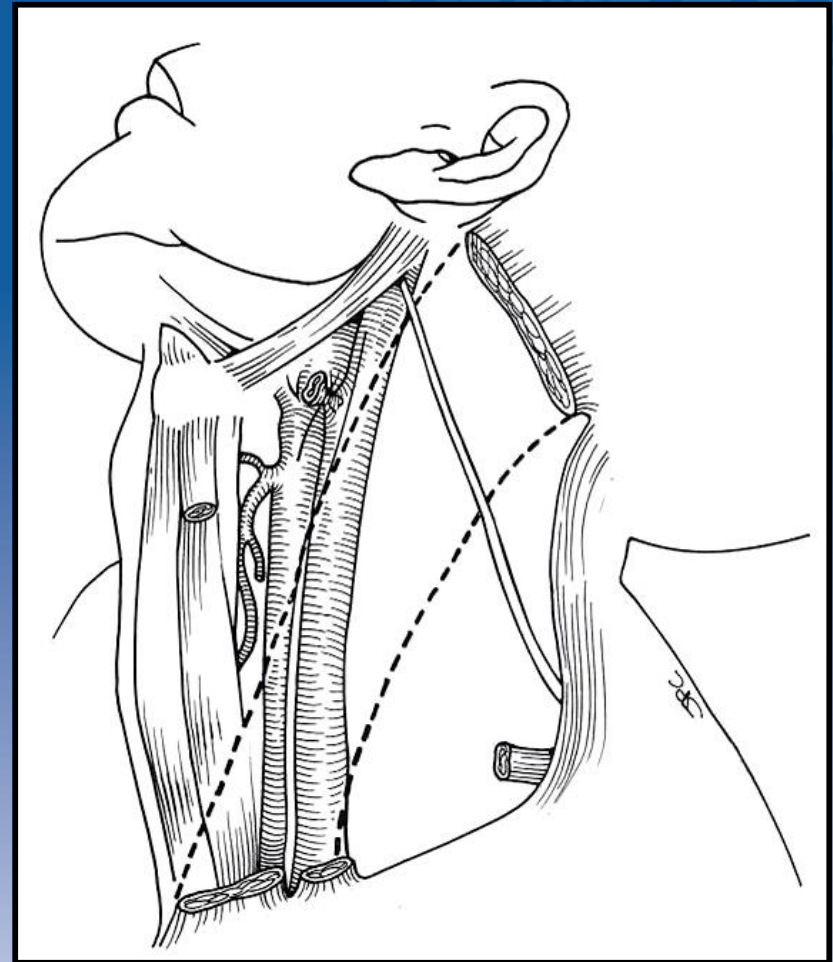
- MRND I: I-V + MSCM+VJI  
(I-V: comprehensive)

(in any **N+** if N. XI may be preserved)



# MODIFIED RND TYPE II

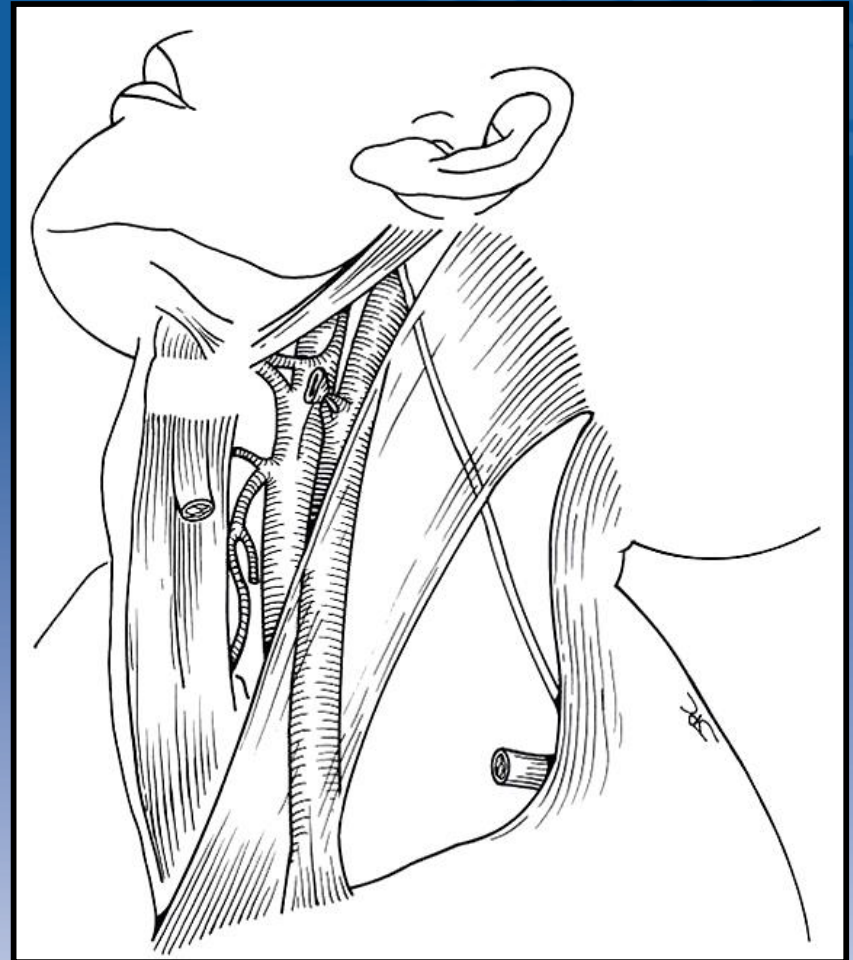
- MRND II: I-V + MSCM  
(I-V: comprehensive)



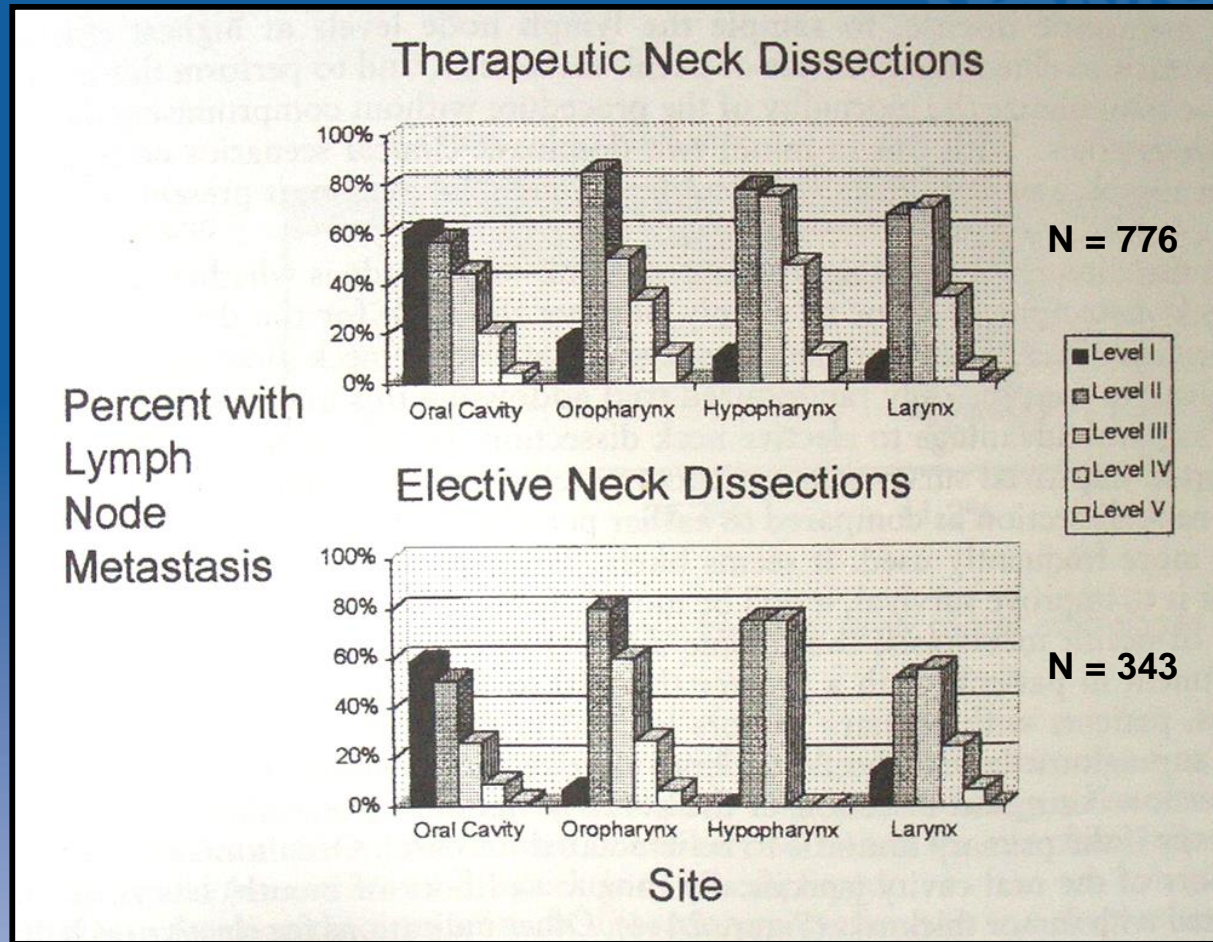
# MODIFIED RND TYPE III

- MRND III: I-V  
(I-V: comprehensive)

cTX N0



# Distribution of neck metastasis



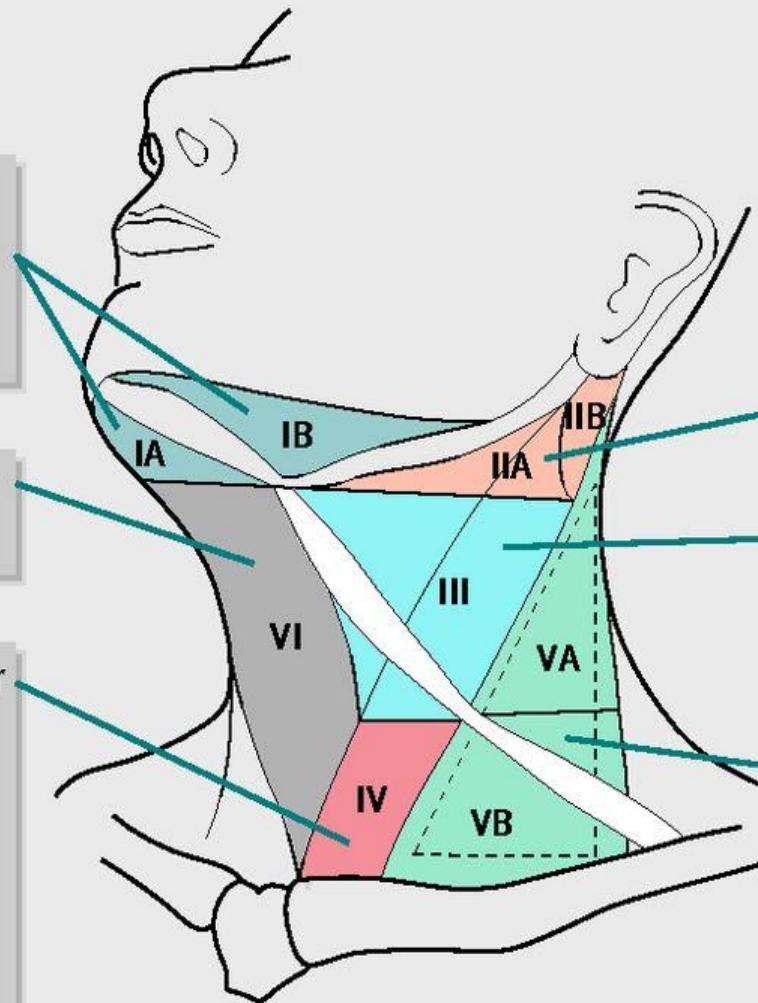
Shah, JP. Patterns of cervical lymph node metastases from squamous cell carcinomas of the upper respiratory and digestive tracts. Am J Surg. 1990 (160) 405-9.

# Distribution of neck metastasis

Level I or submental and submandibular nodes: lip, oral cavity, skin of lower face

Level VI or paratracheal nodes: thyroid, larynx

Level IV or supraclavicular nodes: larynx, hypopharynx, thyroid  
Non-head or neck sites: lung, breast, gastrointestinal or genito-urinary tract



Level II or upper jugular nodes: oropharynx (tonsil, tongue base), parotid

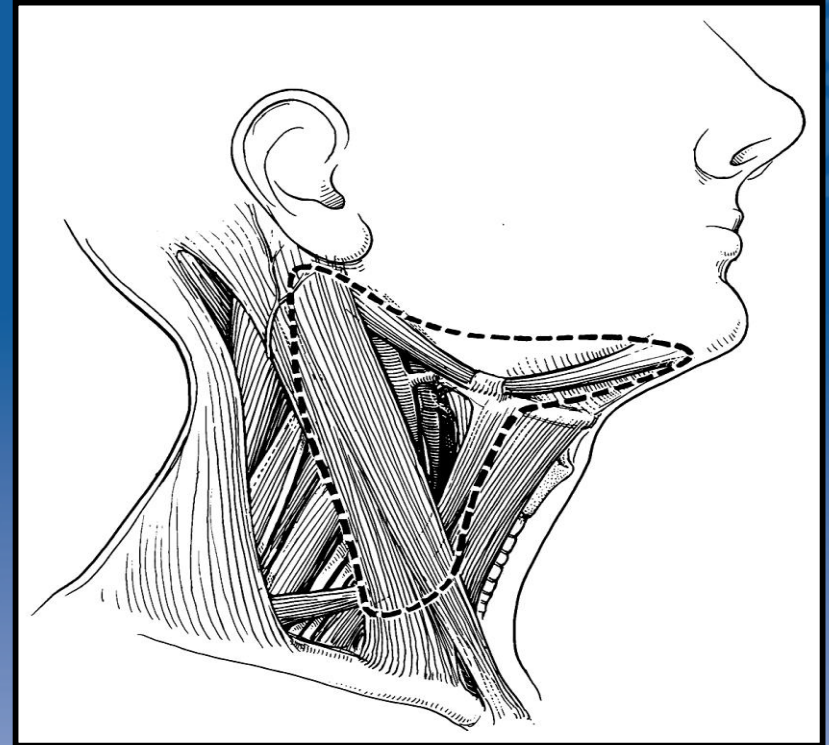
Level III or mid jugular nodes: hypopharynx, thyroid

Level V or posterior triangle nodes: scalp, lymphoma, nasopharynx

# SELECTIVE ND I-III

- SUPRAOMOHYOID  
I-III

cT2 - 4N0  
(oral cavity, oropharynx)



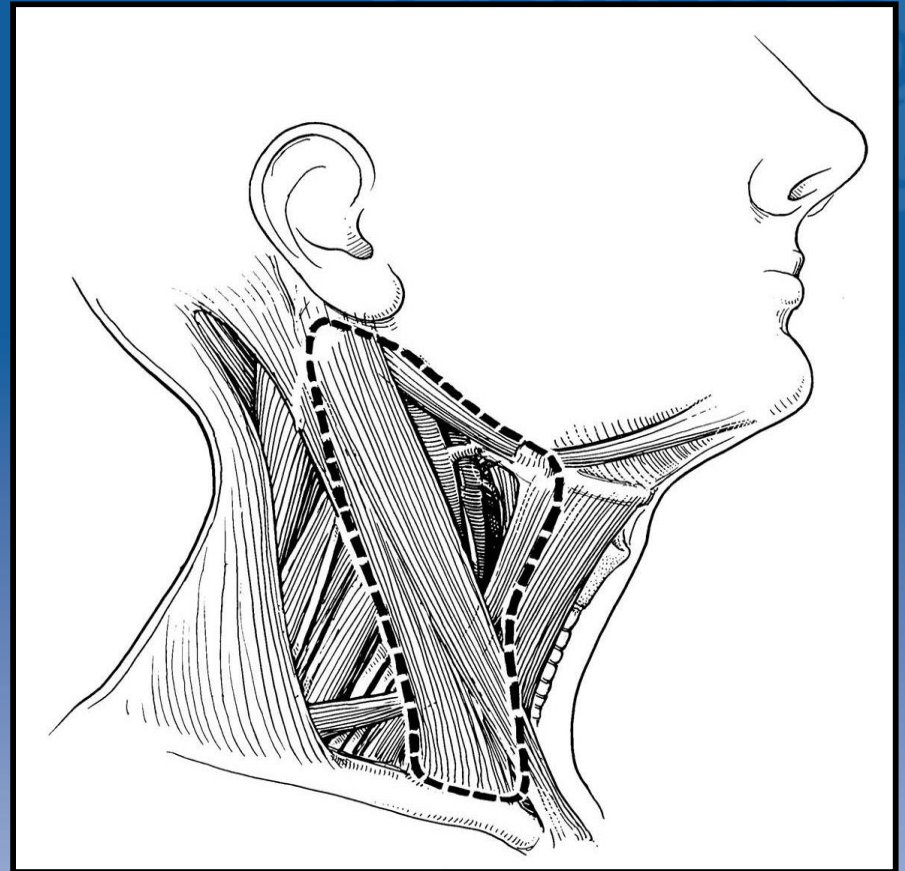


# SELECTIVE ND II-IV/V

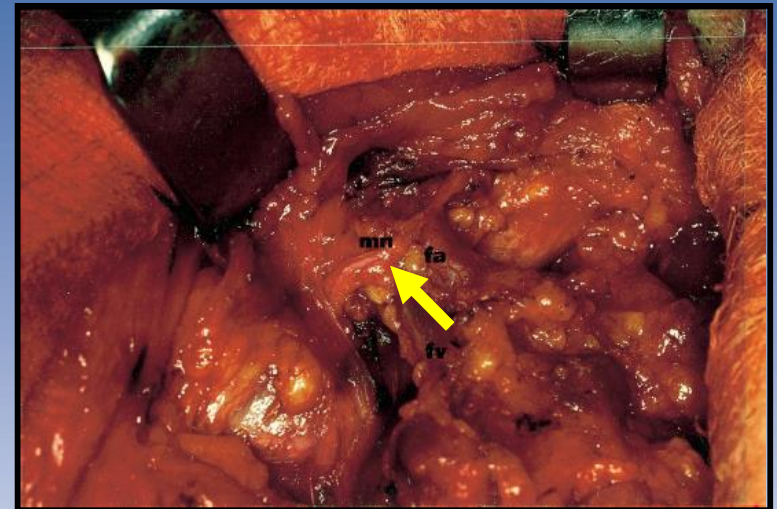
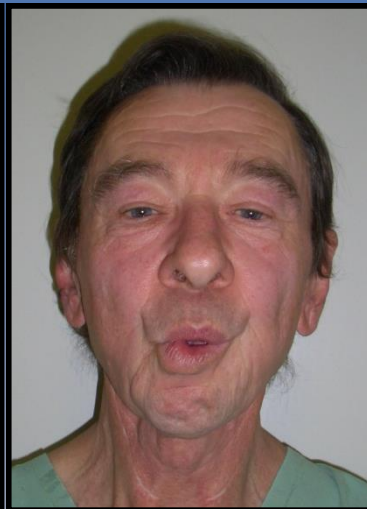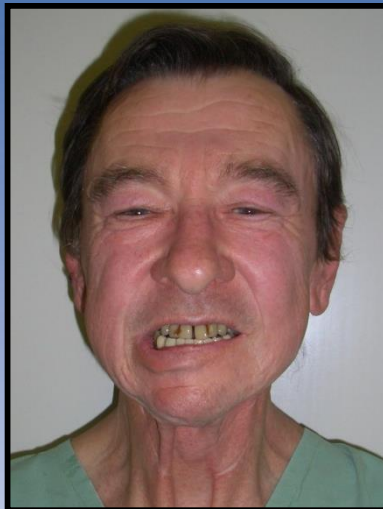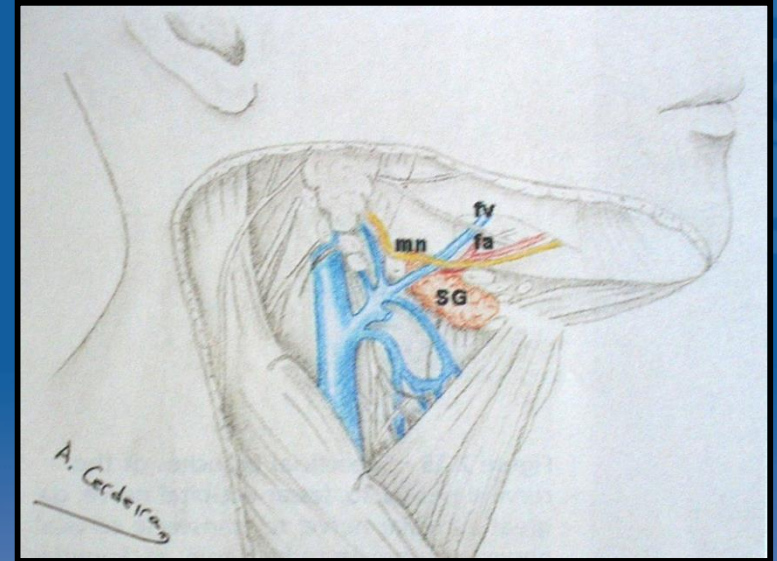
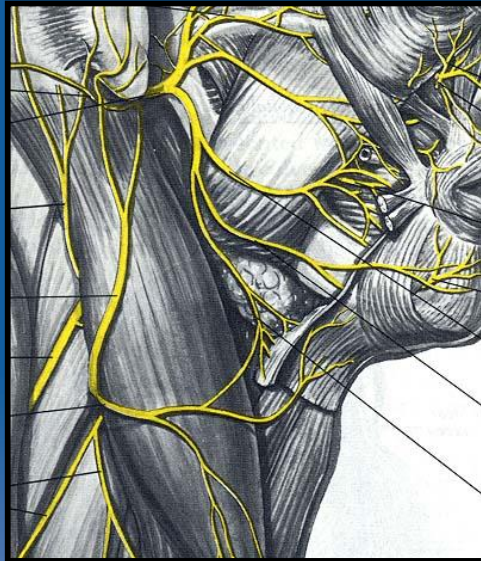
- LATERAL  
II-IV
- POSTEROLATERAL  
II-V

cT2 - 3N0  
(larynx, hypopharynx)

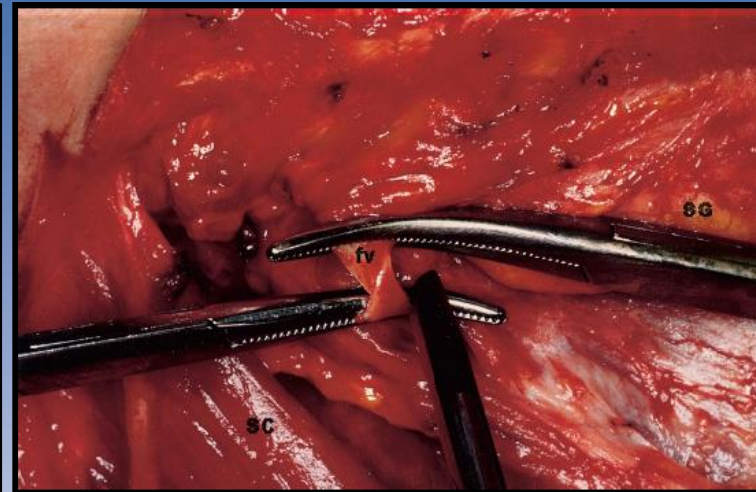
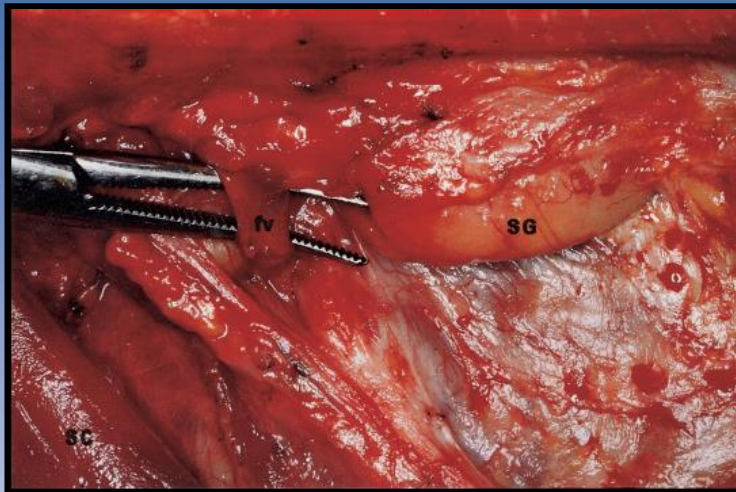
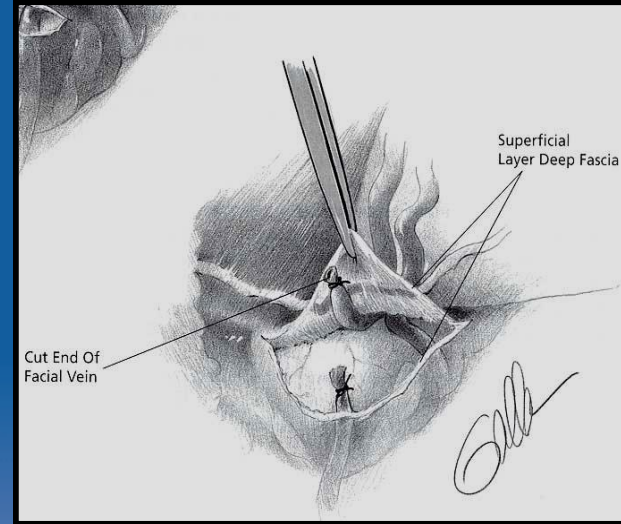
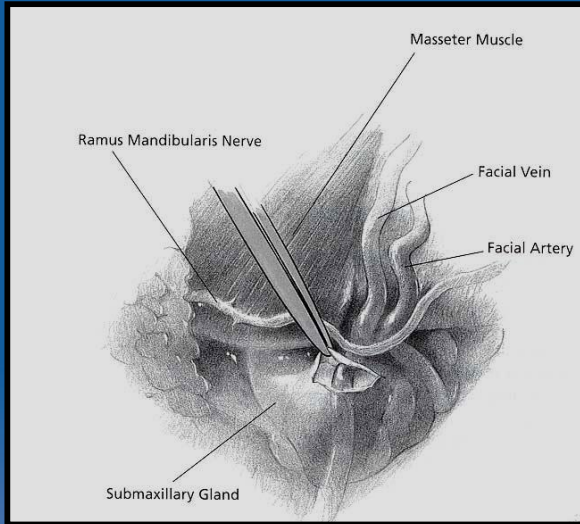
cTXN1



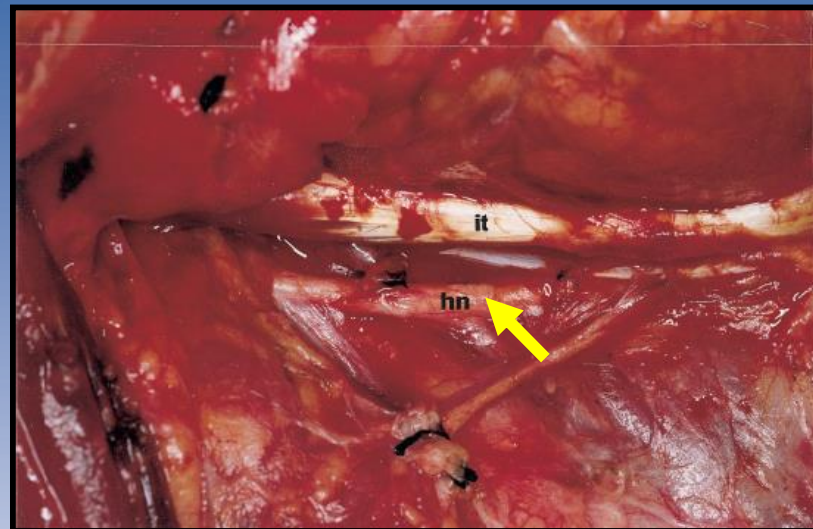
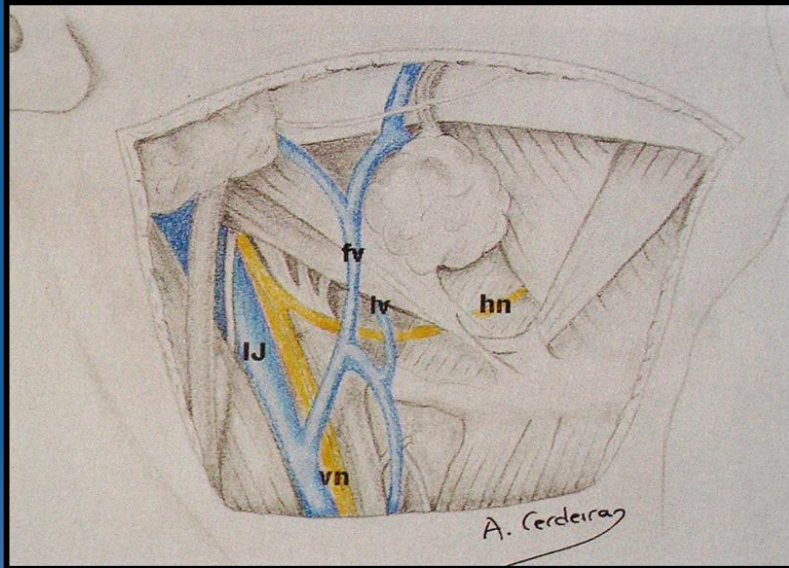
# R. MARGINALIS N. FACIALIS



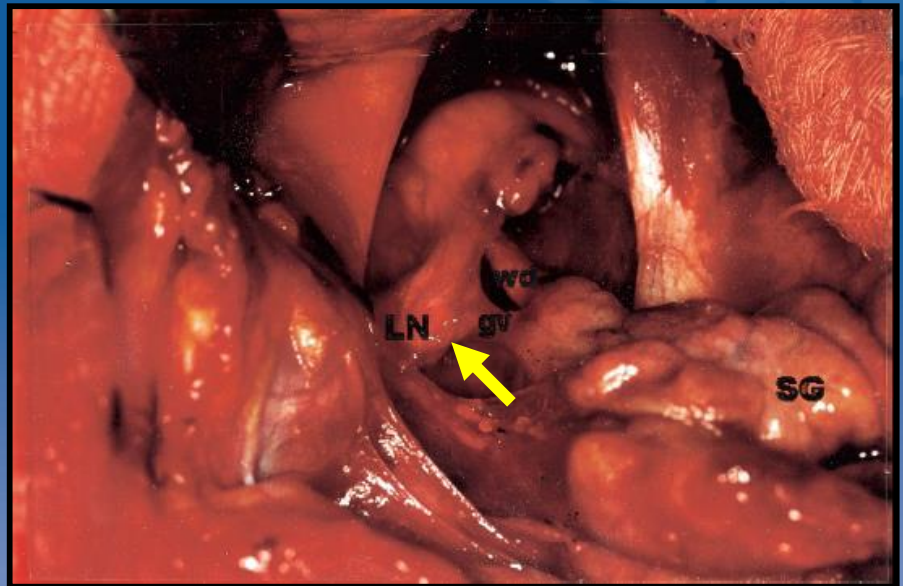
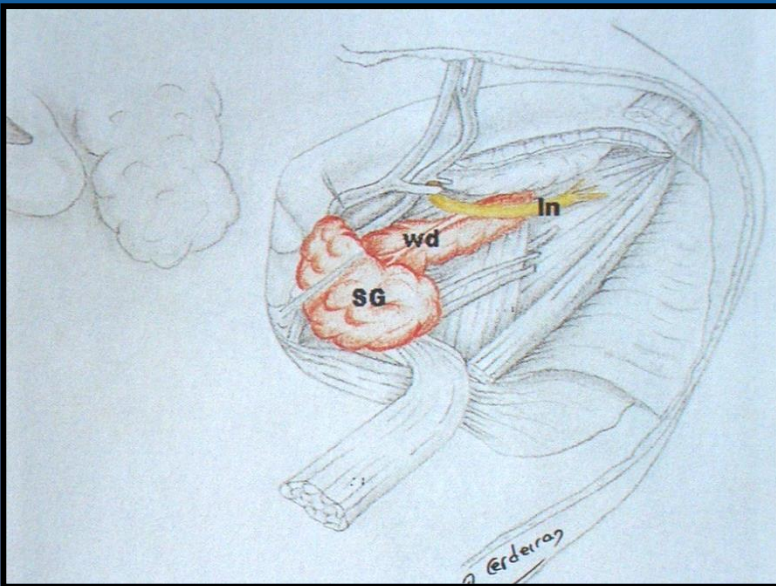
# R. MARGINALIS N. FACIALIS



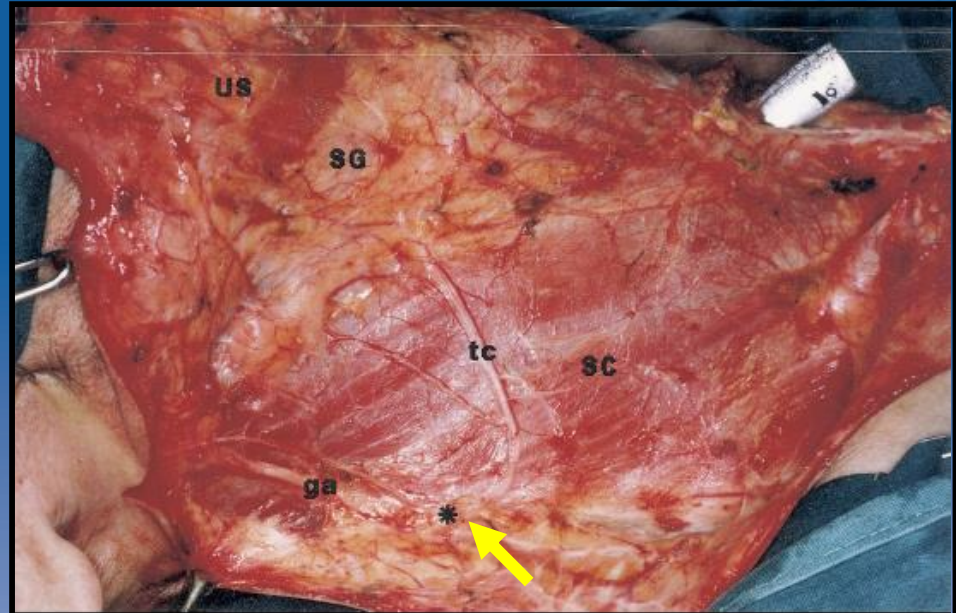
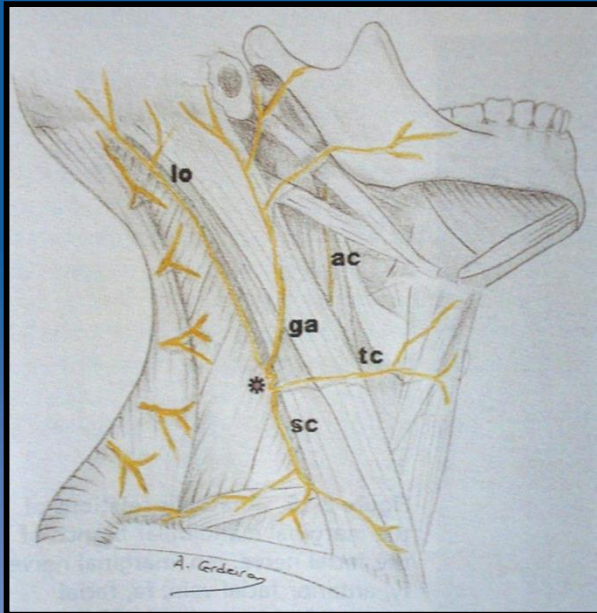
# N. HYPOGLOSSUS



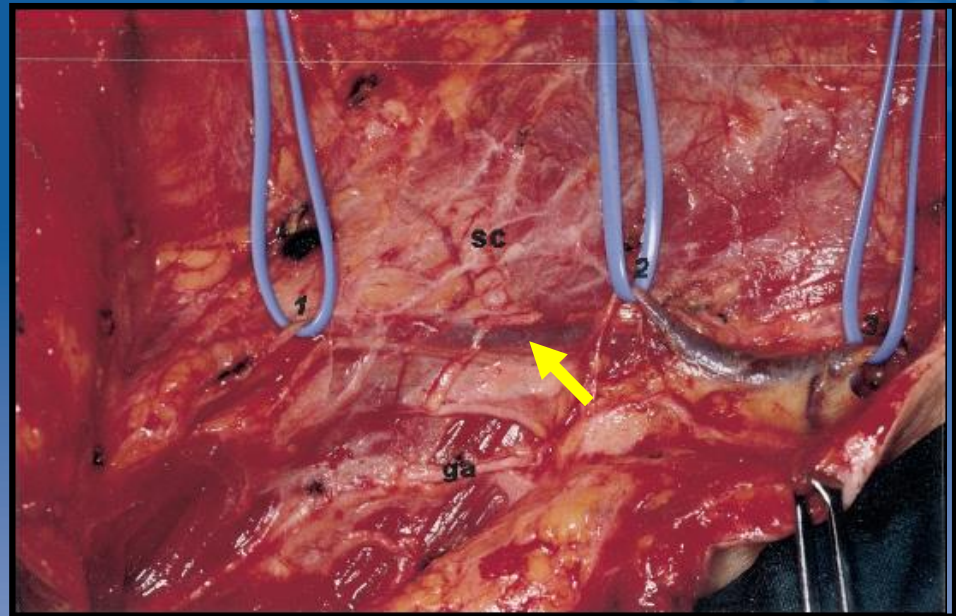
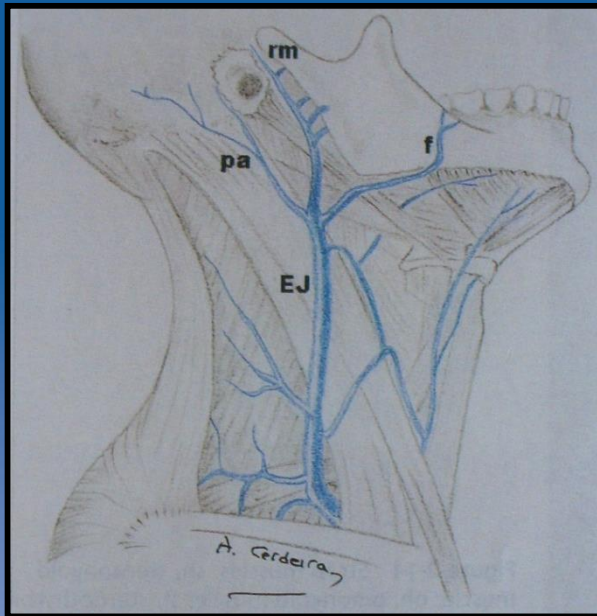
# N. LINGUALIS



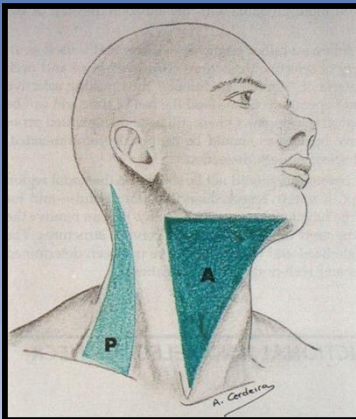
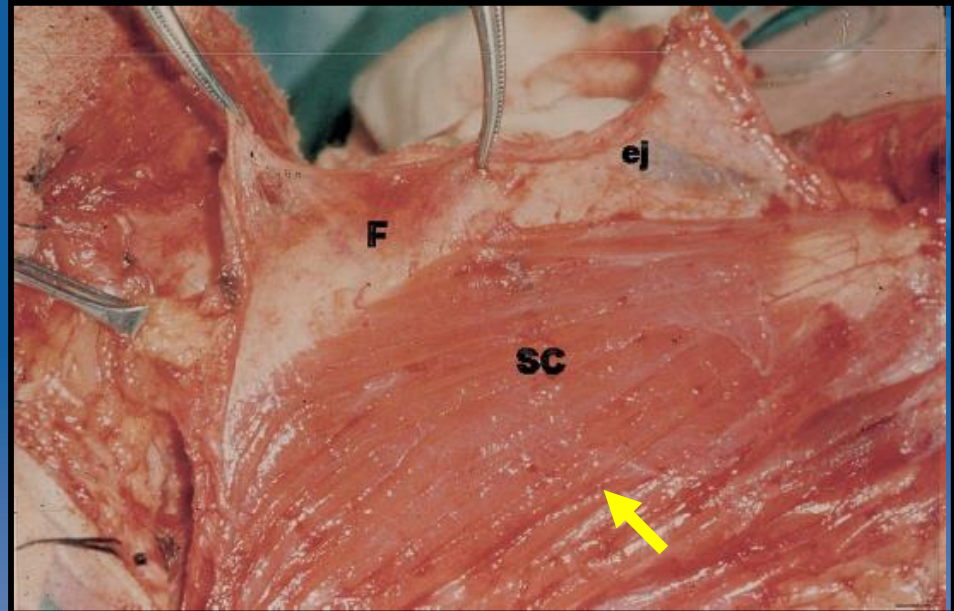
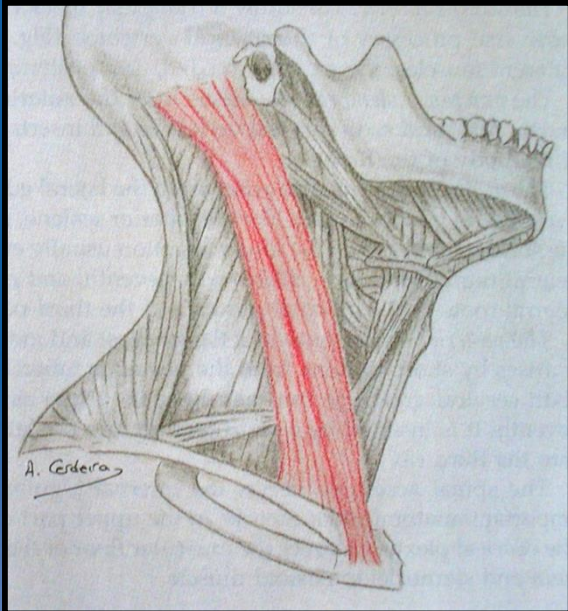
# PL. CERVICALIS



# V. JUGULARIS EXTERNA

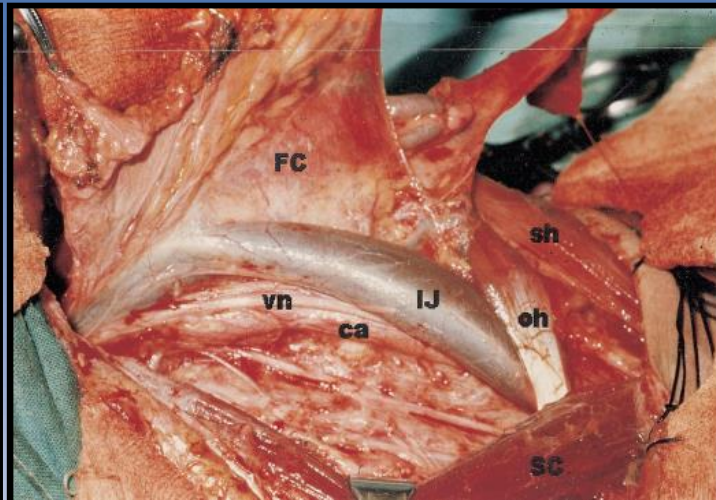
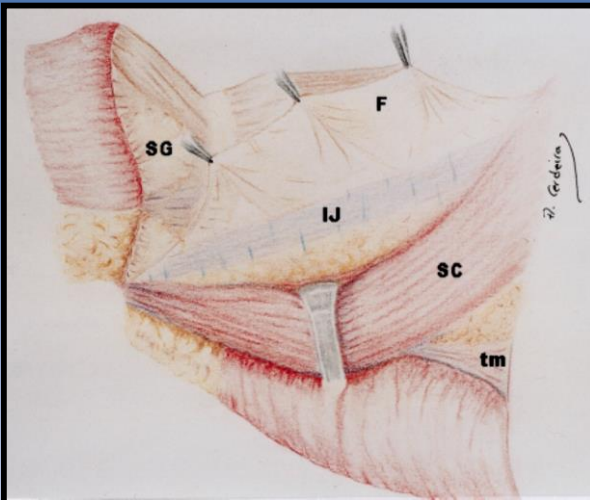
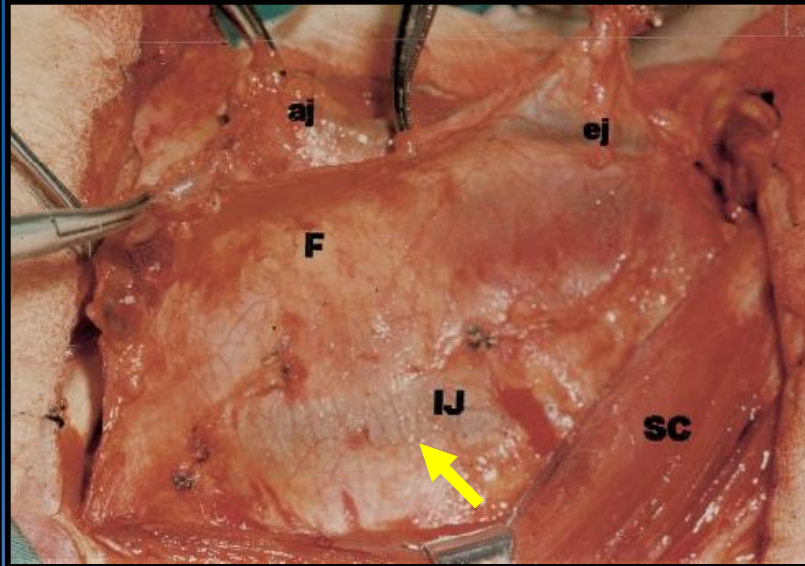
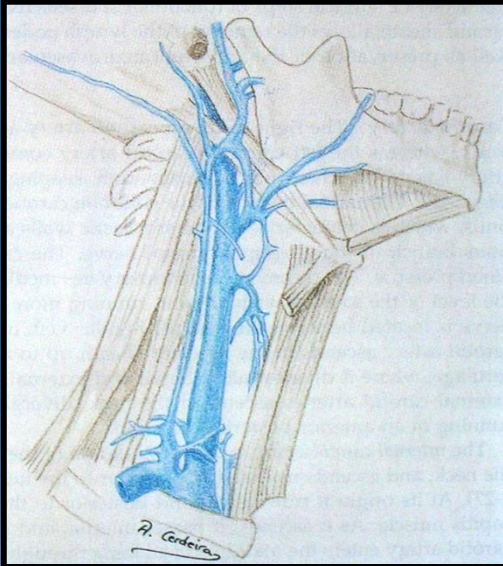


# M. STERNOCLEIDOMASTOIDEUS

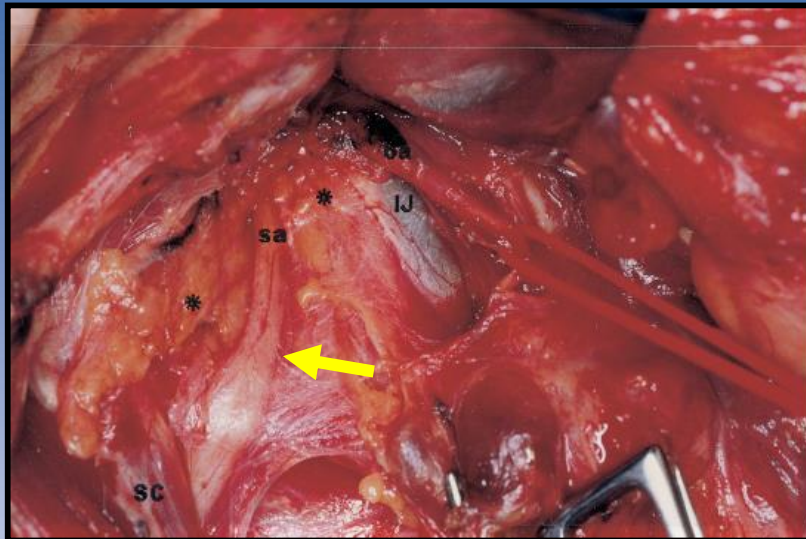





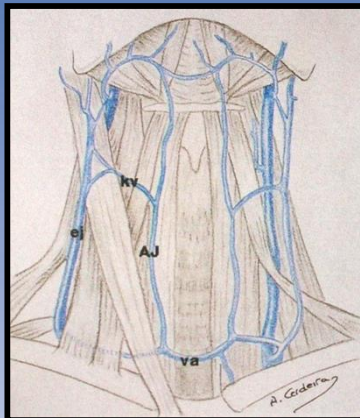
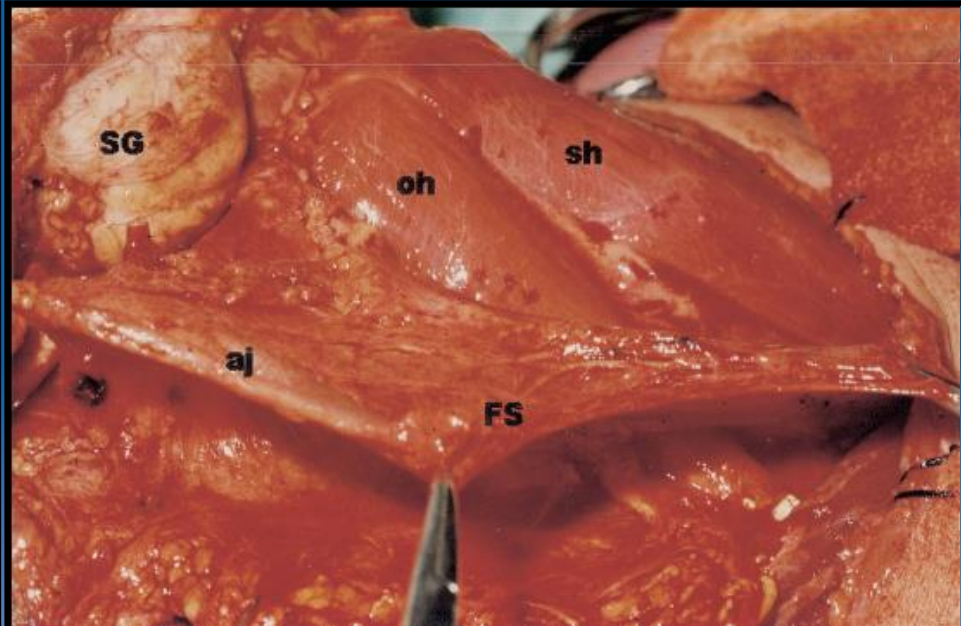
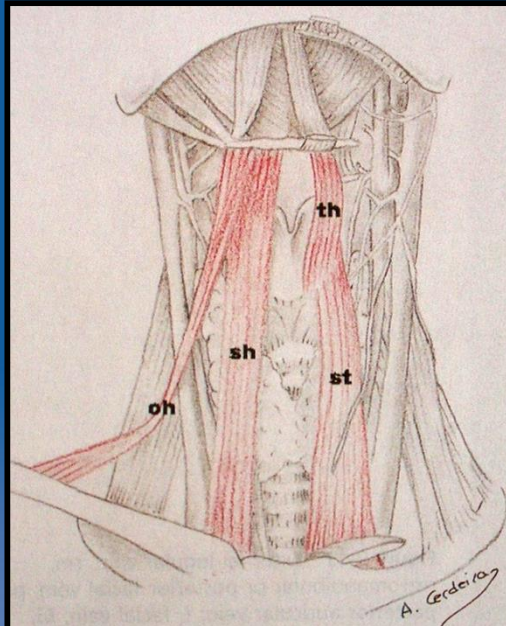
# V. JUGULARIS INTERNA



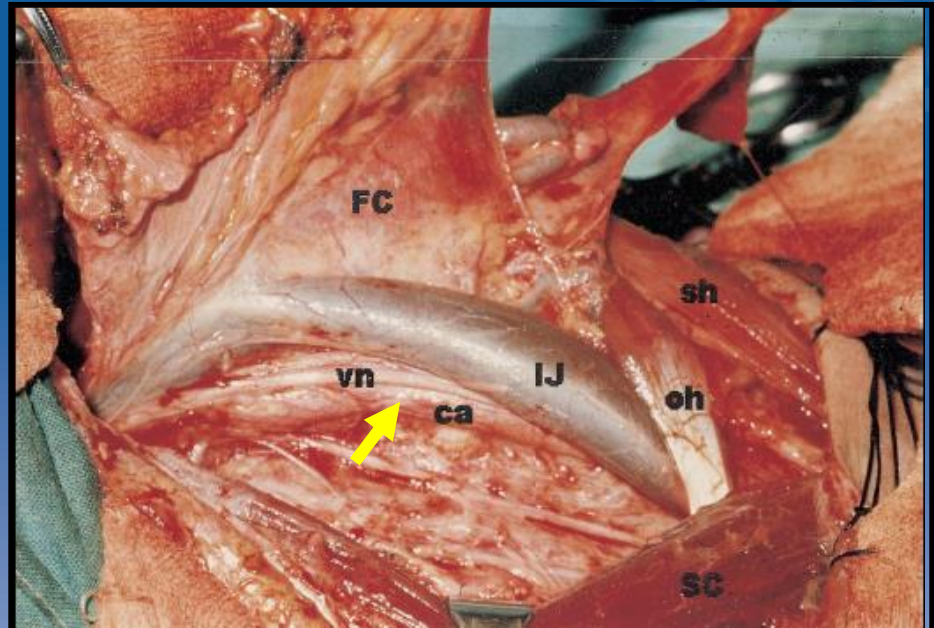
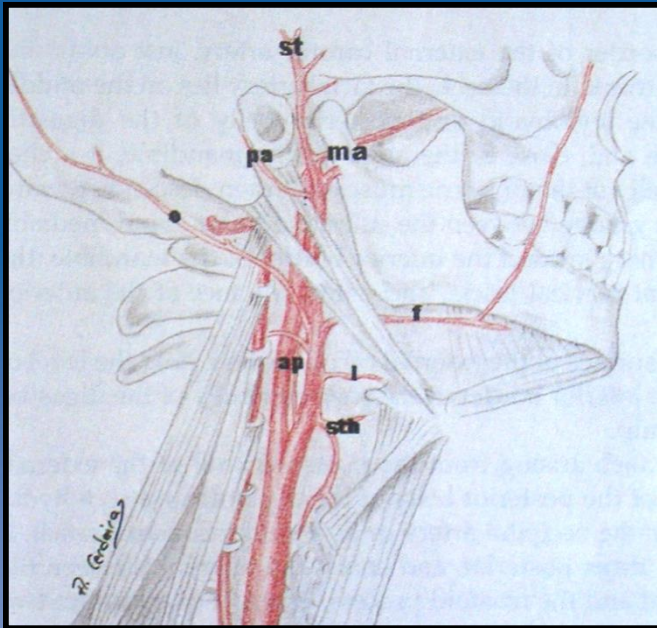
# N. ACCESSORIUS



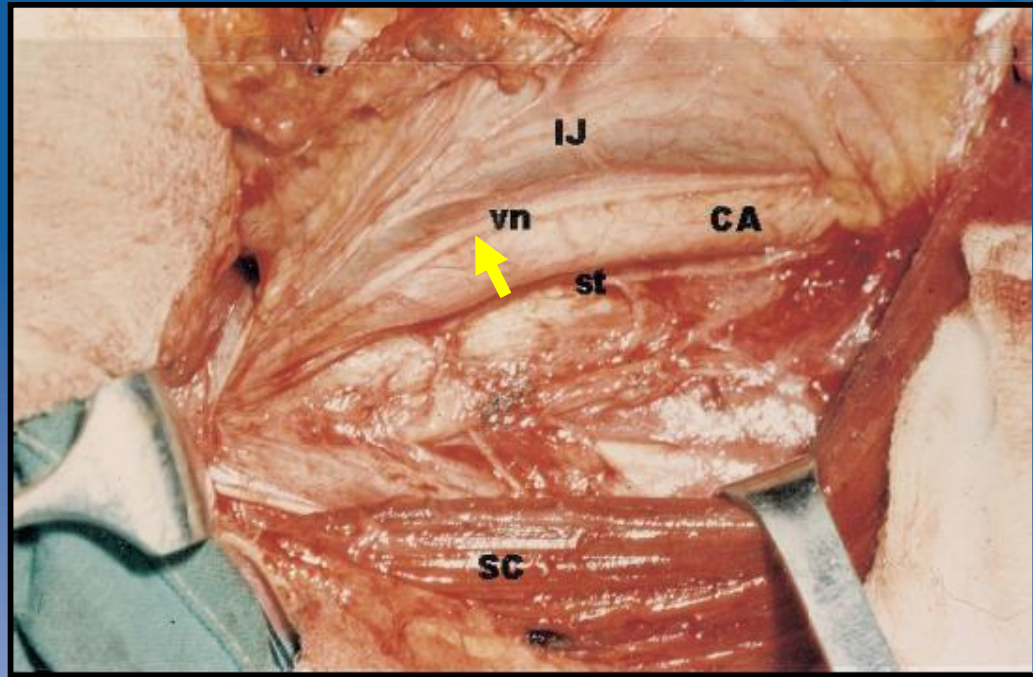
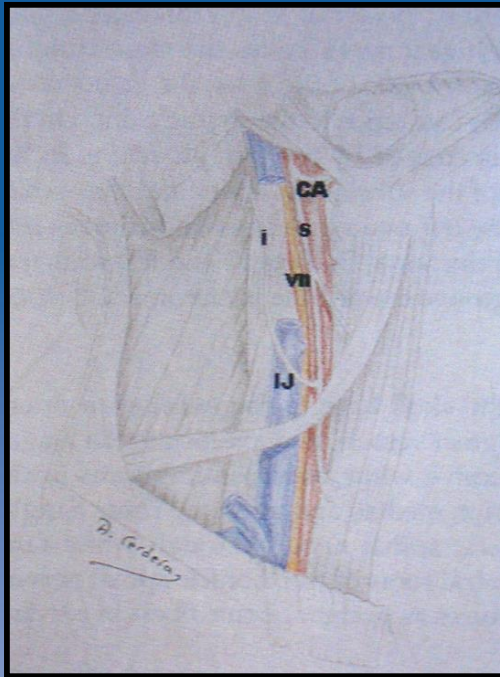
# INFRAHYOID MUSCLES



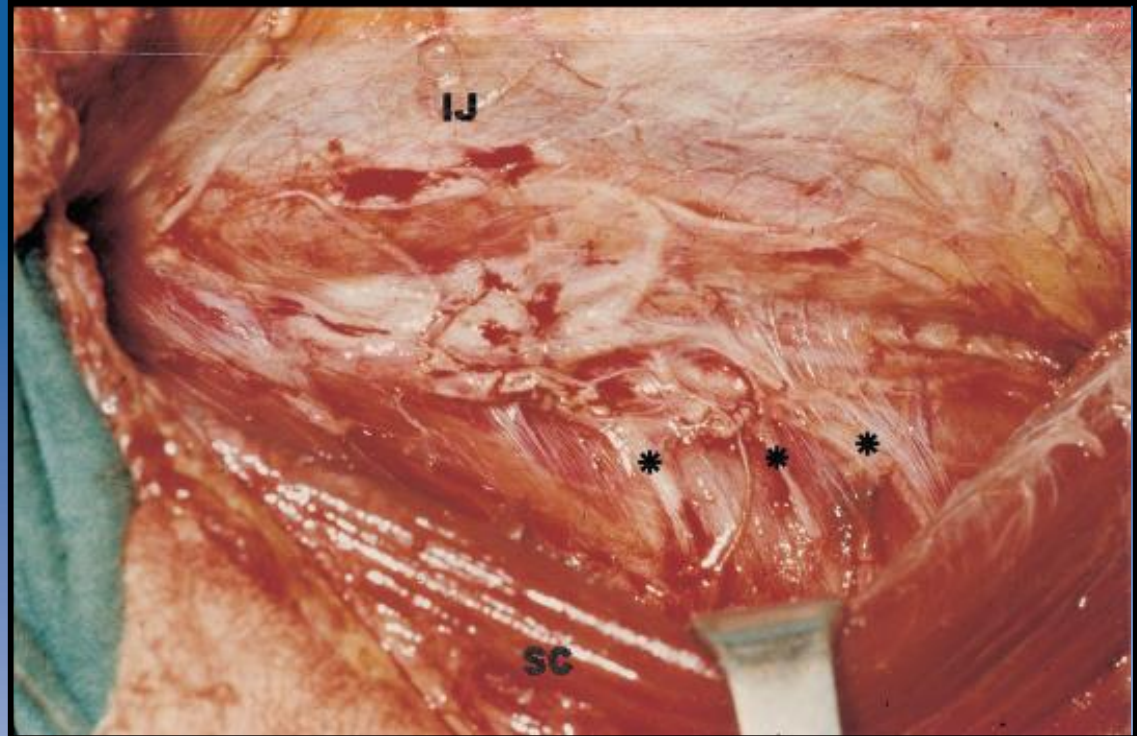
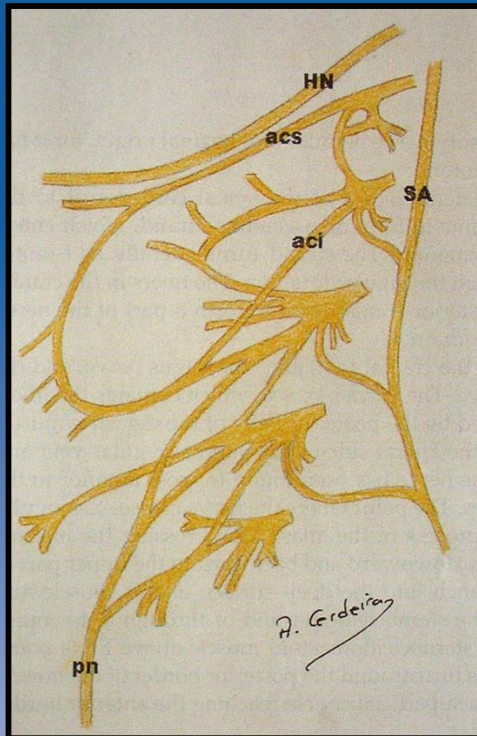
# A. CAROTIS



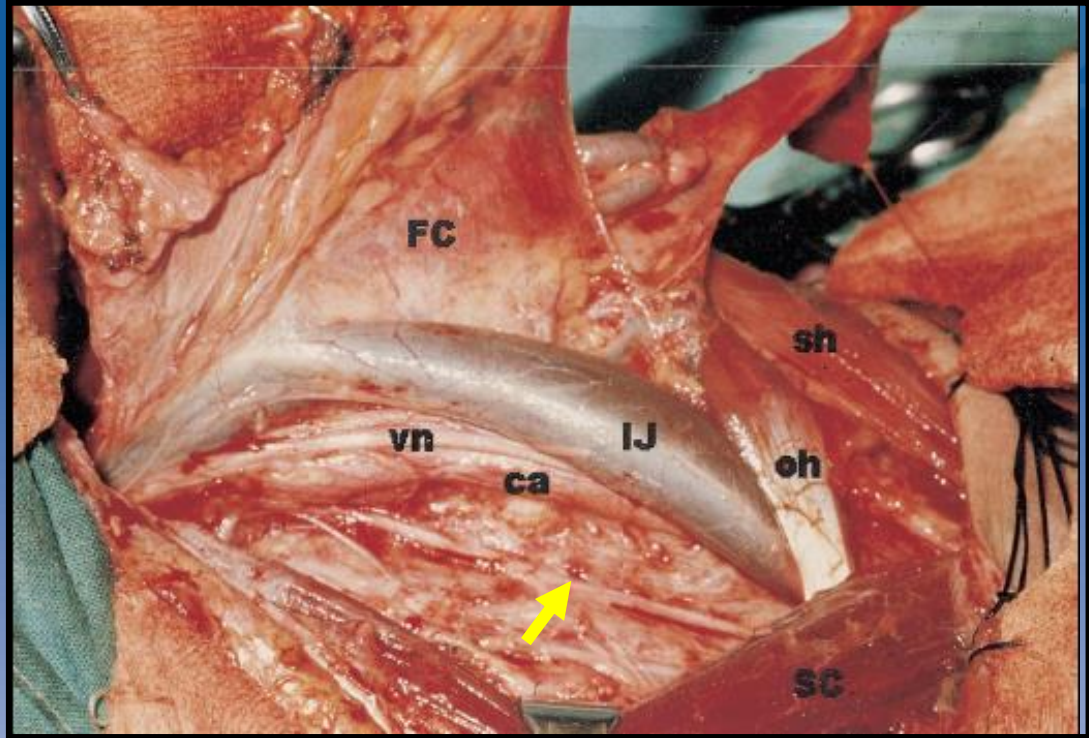
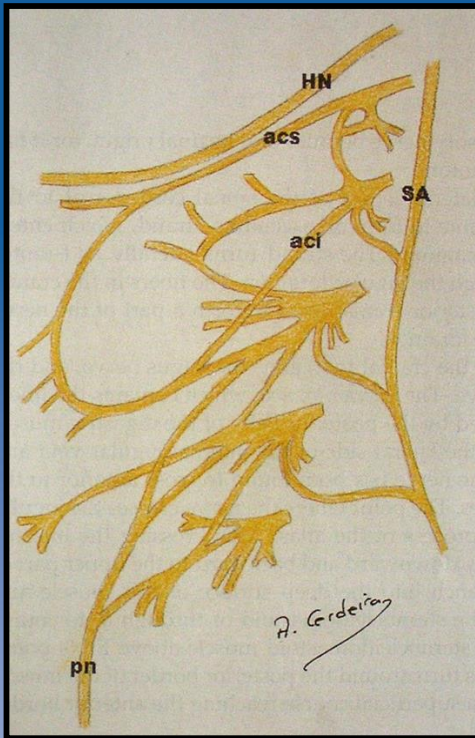
# N. VAGUS



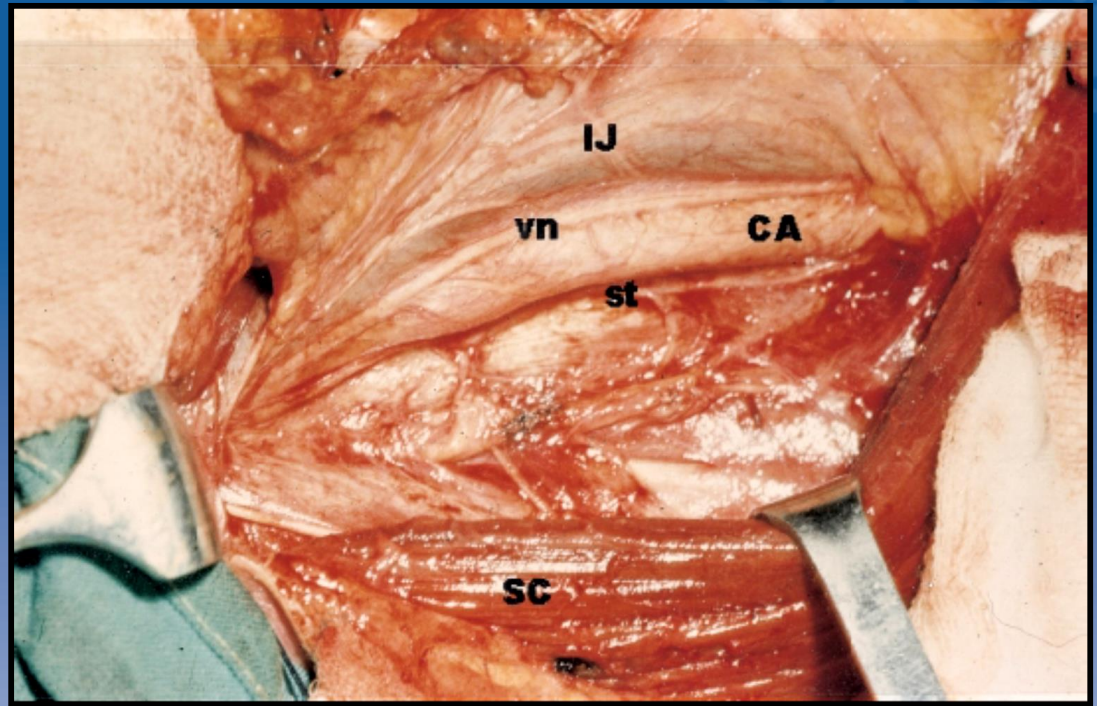
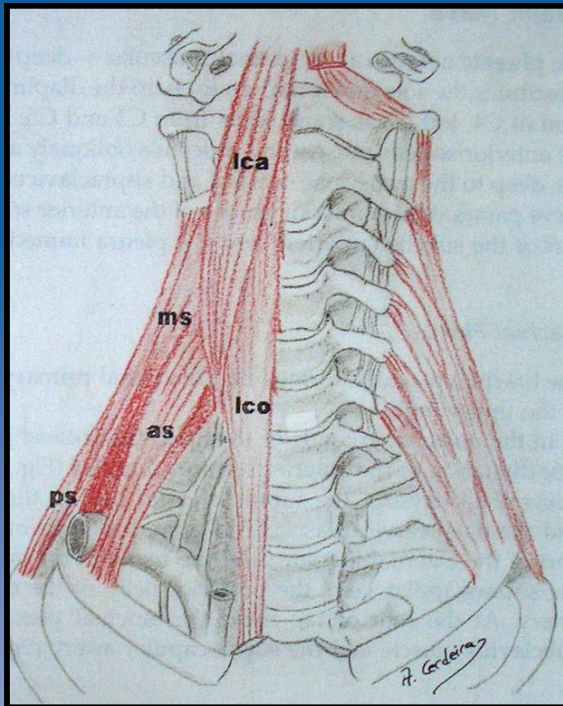
# PLEXUS CERVICALIS



# N. PHRENICUS

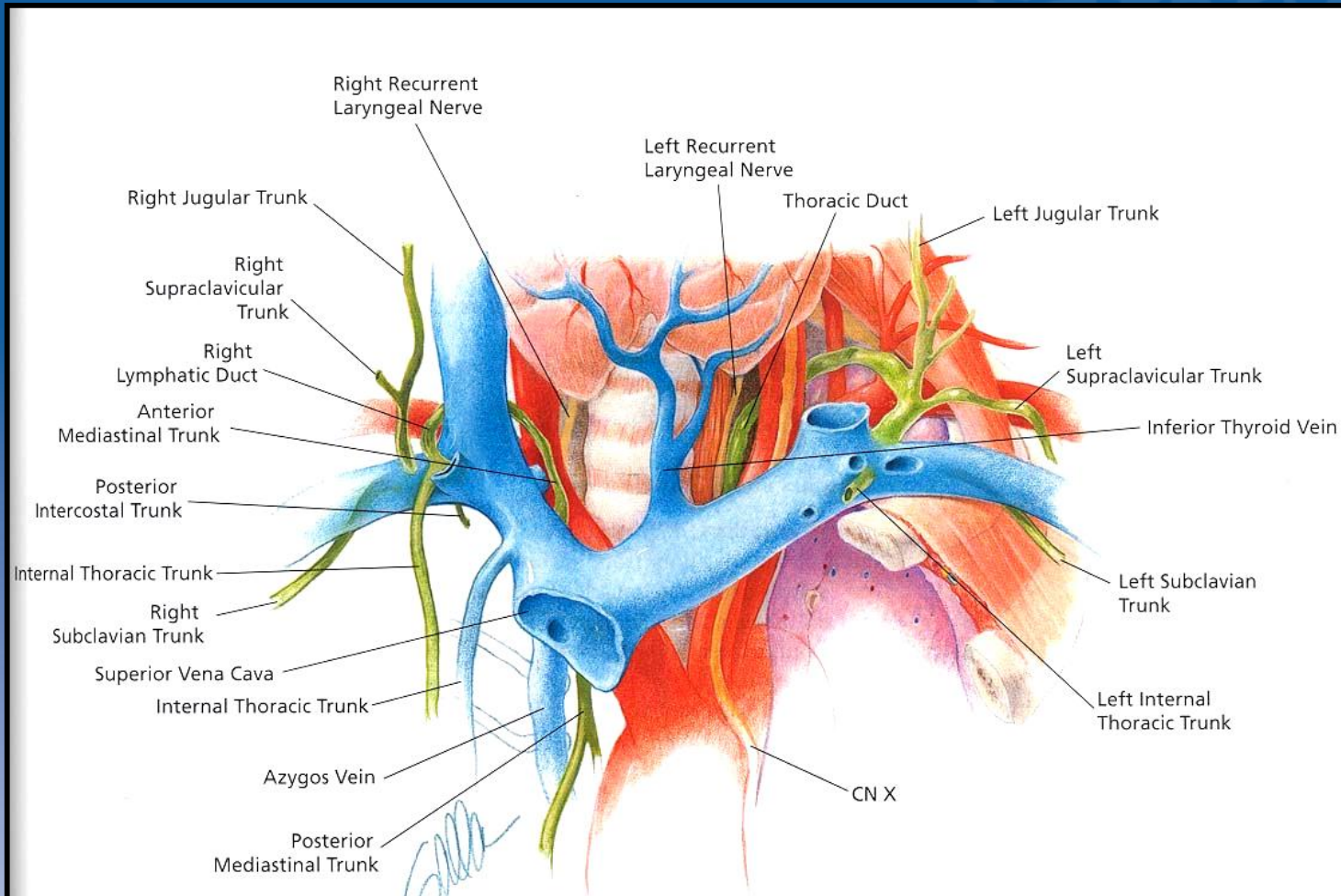


# DEEP CERVICAL MUSCLES

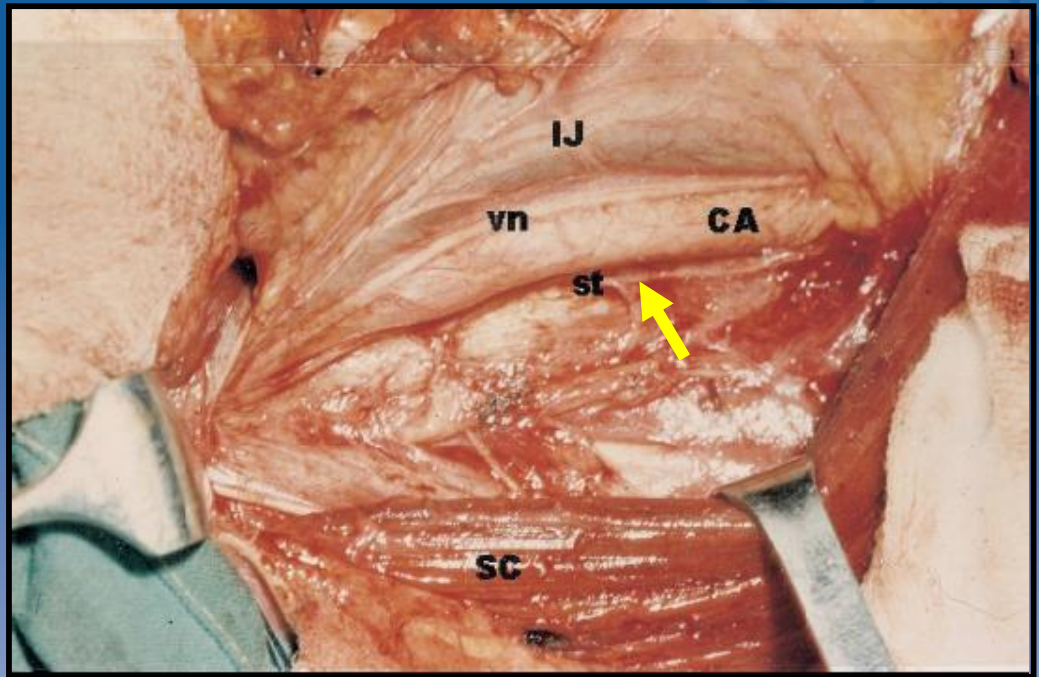
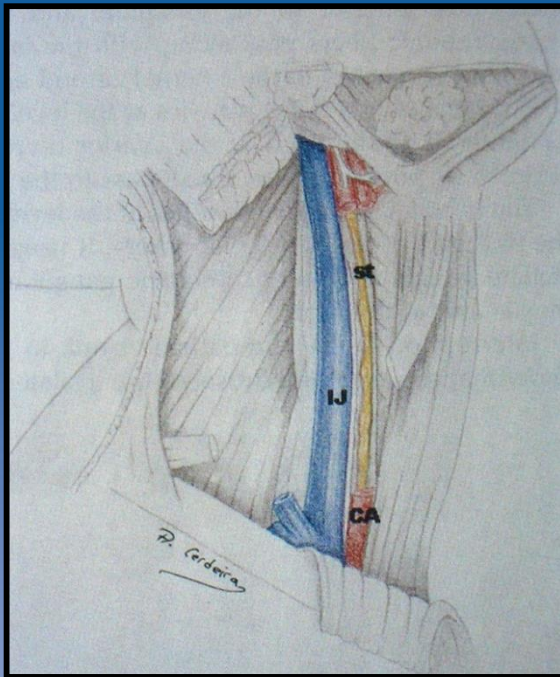




# DUCTUS THORACICUS



# TRUNCUS SYMPATHICUS



# PLEXUS BRACHIALIS VASA TRANSVERSA COLLI

