Immune-lymphatic system

Founders

Pasteur

http://diogenesii.files.wordpress.com

Metchnikoff

http://www.iemrams.spb.ru

Koch

http://www.wired.com

Ehrlich

http://media-2.web.britannica.com

Pavel Šnajdr
Karel Smetana

<u>Immune-lymphatic system</u> = primary + secondary organs

primary:bone marrow, thymus

secondary: lymph. nodes, spleen, tonsils, aggregates (MALT=BALT+GALT)

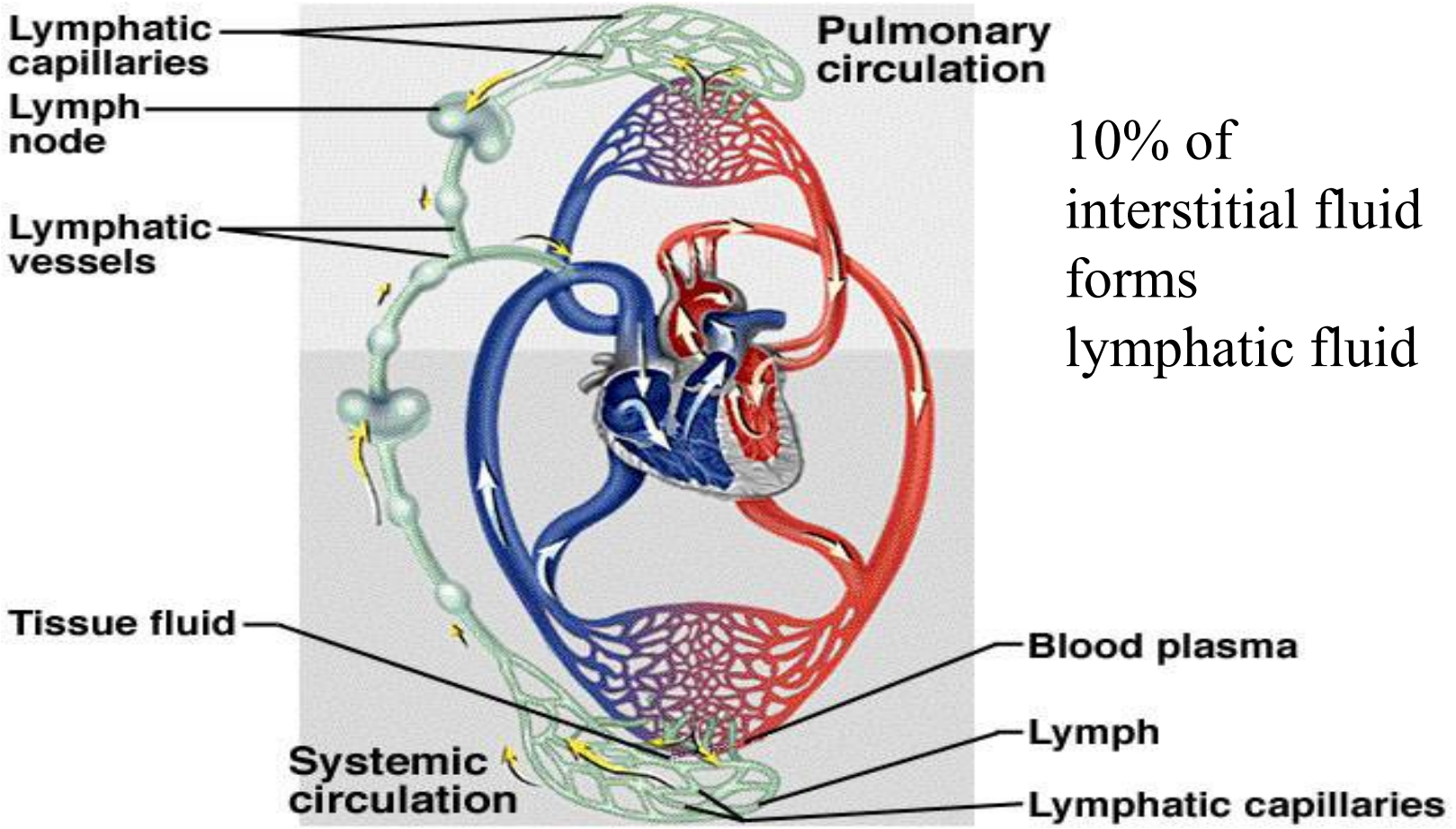

10% of interstitial fluid forms lymphatic fluid

10% of interstitial fluid forms lymphatic fluid

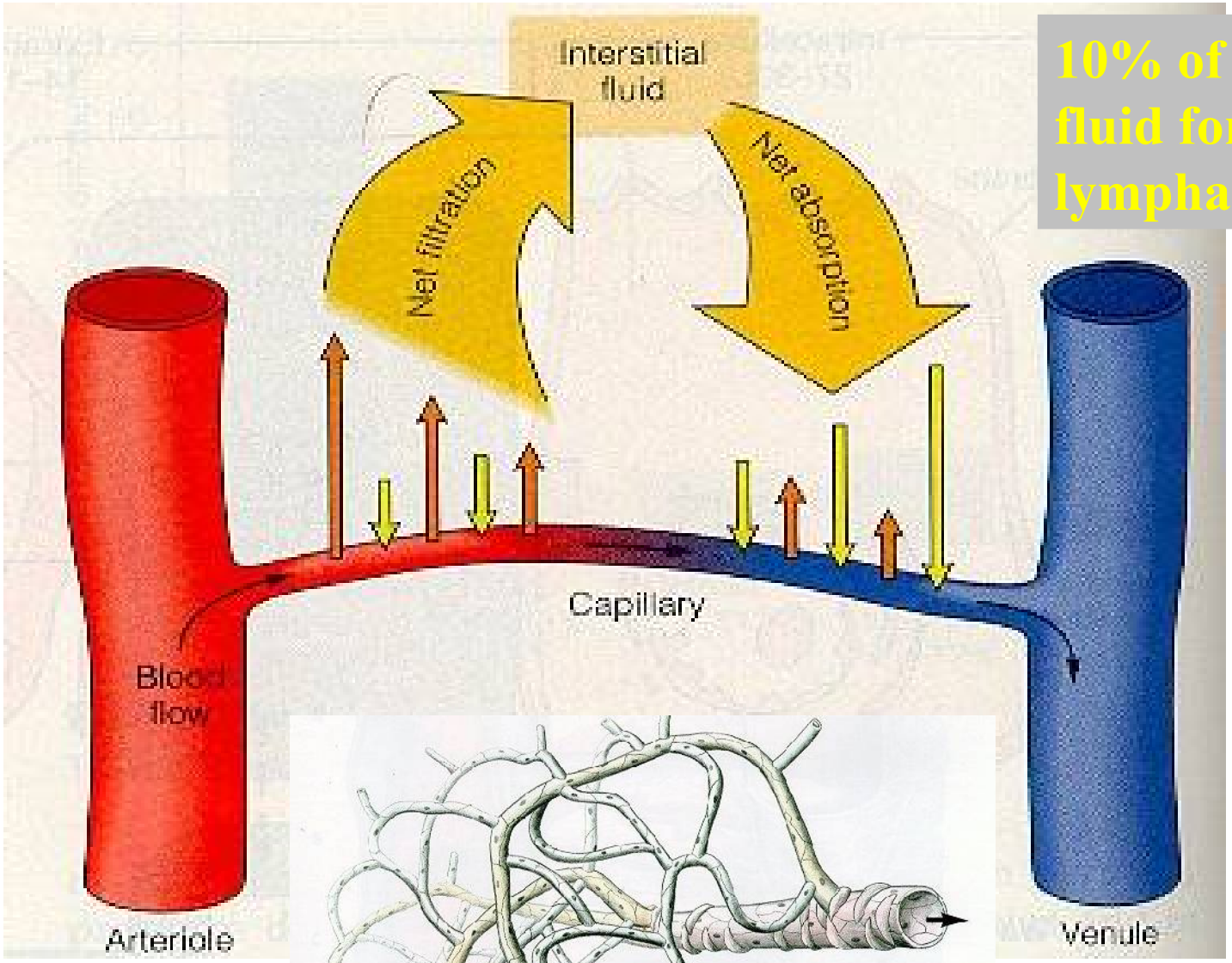

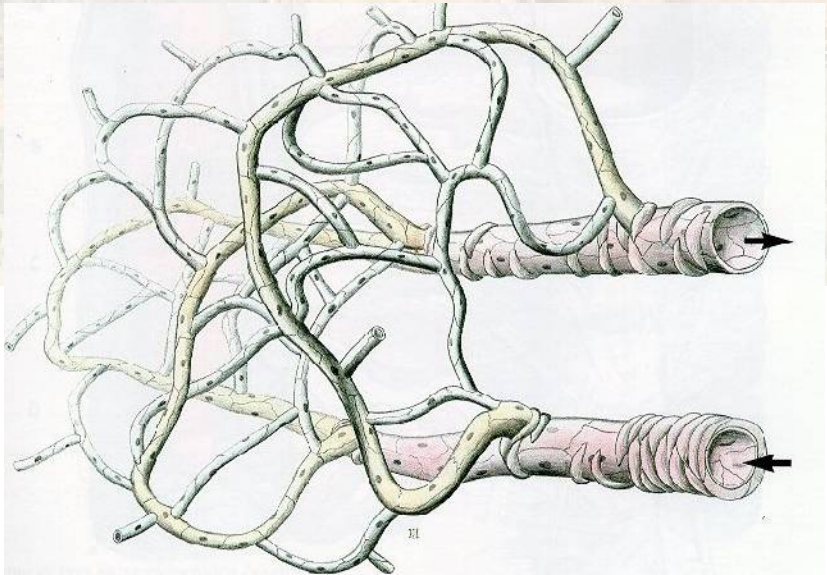

lymphatics

only limited no. of tissue without lymphatics ….

hair, epidermis, cornea, vitreous body, lens, cartilage, nervous tissue, bone marrow ?

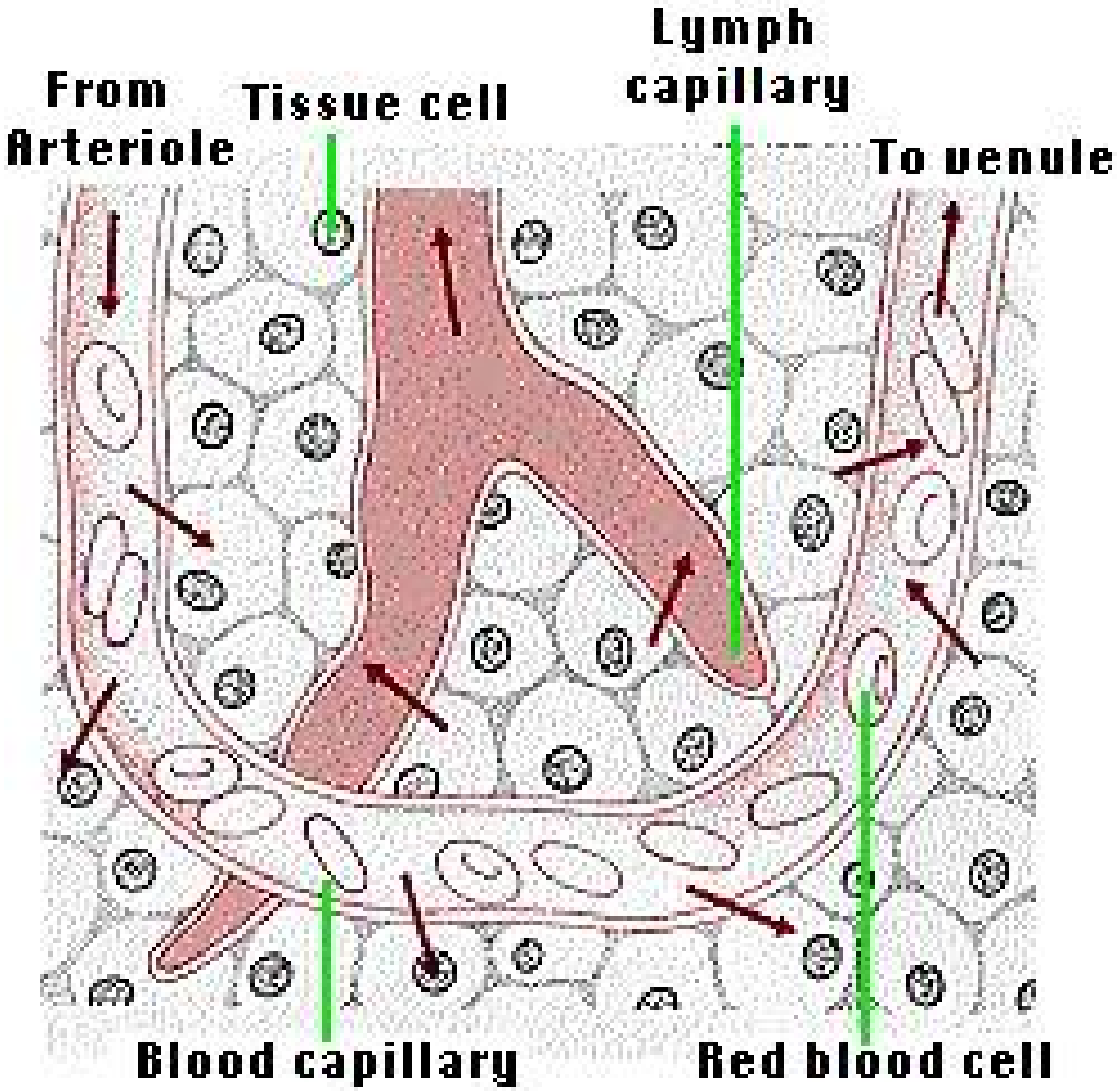
Lymph capillary
From Arteriole
Tissue cell
To venule
Blood capillary
Red blood cell

Lymphatic tissue represents a morphological substrate for the majority of immune reactions. Main components are originated from the pluripotent haematopoietic stem cell that is located in bone marrow- the most important primary lymphoid organ.

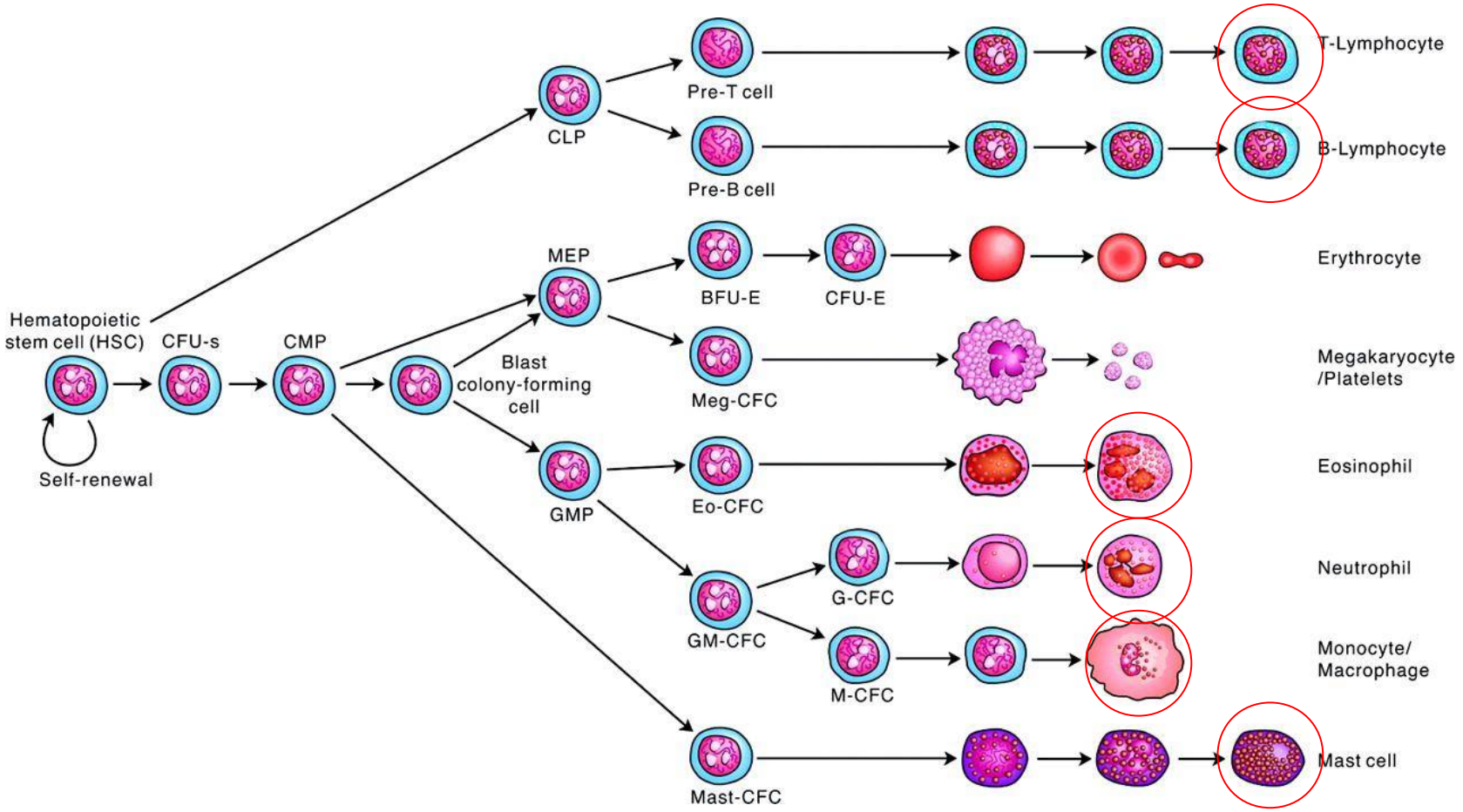

http://www.lifeethics.org

Neutrophil leukocytes and monocytes/macrophages are participating in innate (natural) immune repsonse. Lymphocytes (T/B) are the main representatives of the acquired (specific or adaoptive) immunity.

Neutrophil granulocytes

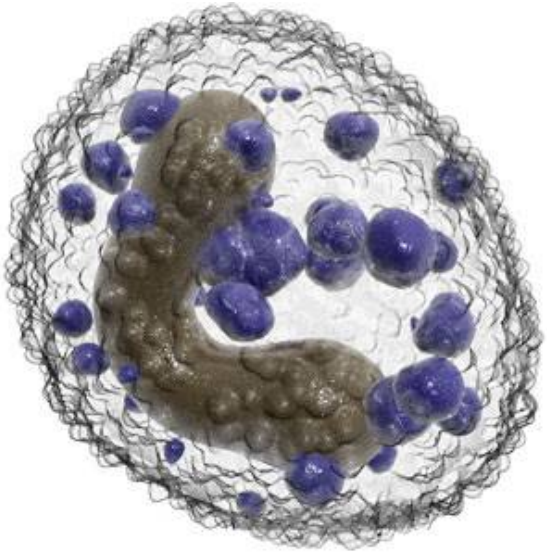

http://www.medicalmediakits.com

T-lymphocytes

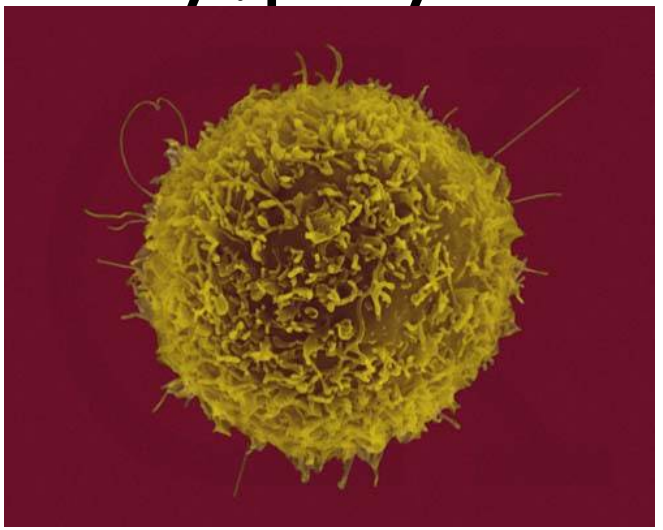

http://www.cartage.org.lb

Monocytes

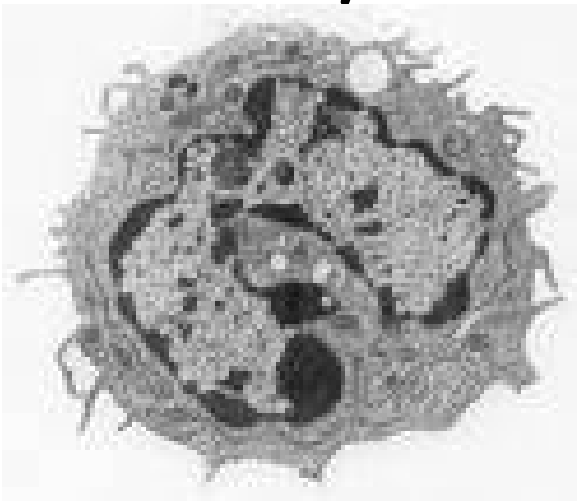

http://missinglink.ucsf.edu

B-lymphoocytes

www.jbc.org

Professional antigen-presenting dendritic cells represent a highly efficient chain of specific immune response. These elements are located in epithelia of body surfaces. They migrate to lymphatic nodes where they „teach“ theT-lymphocytes.

Dendritic cells in epidermis (Langerhans cells)

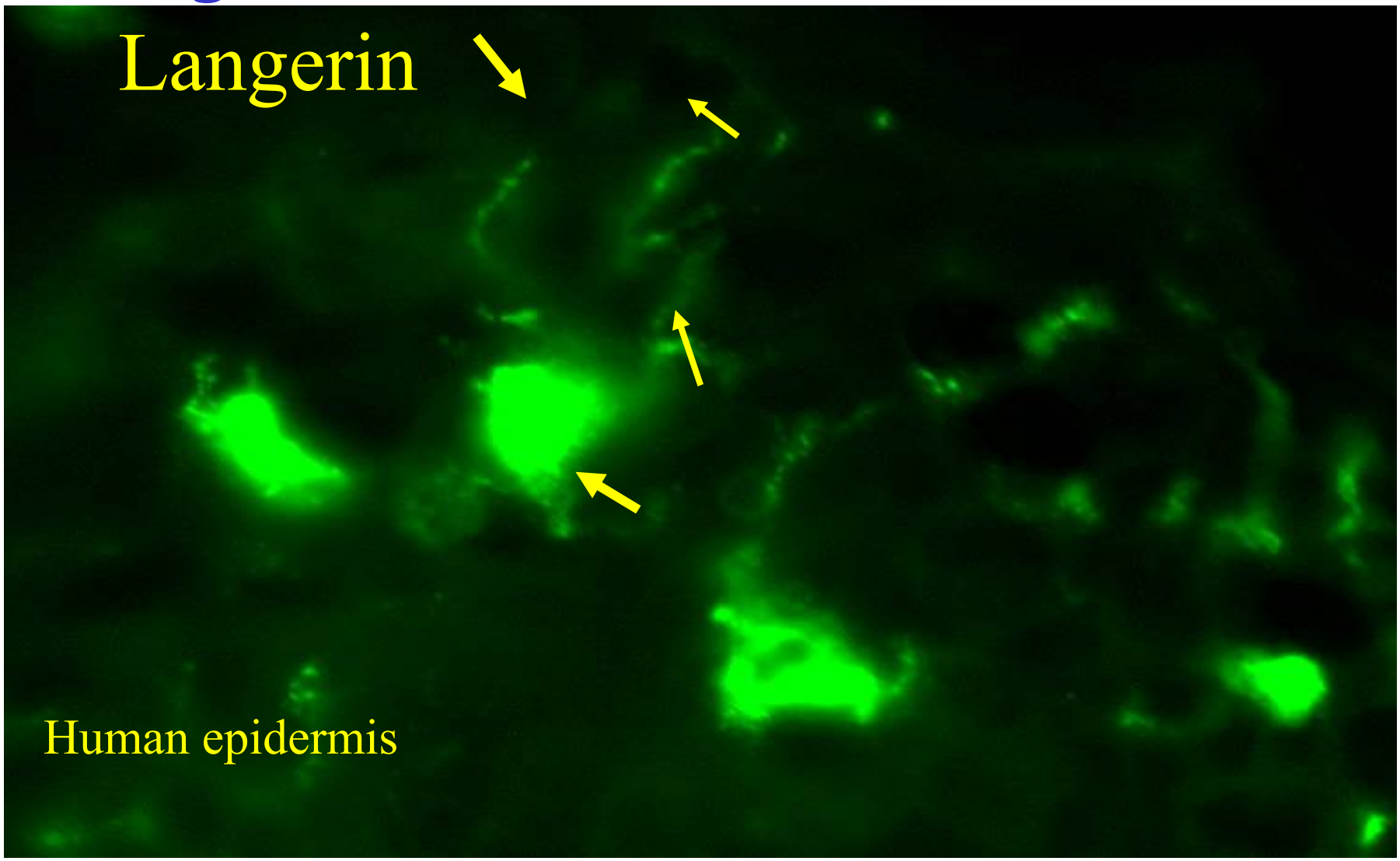

Cell interaction in immune system

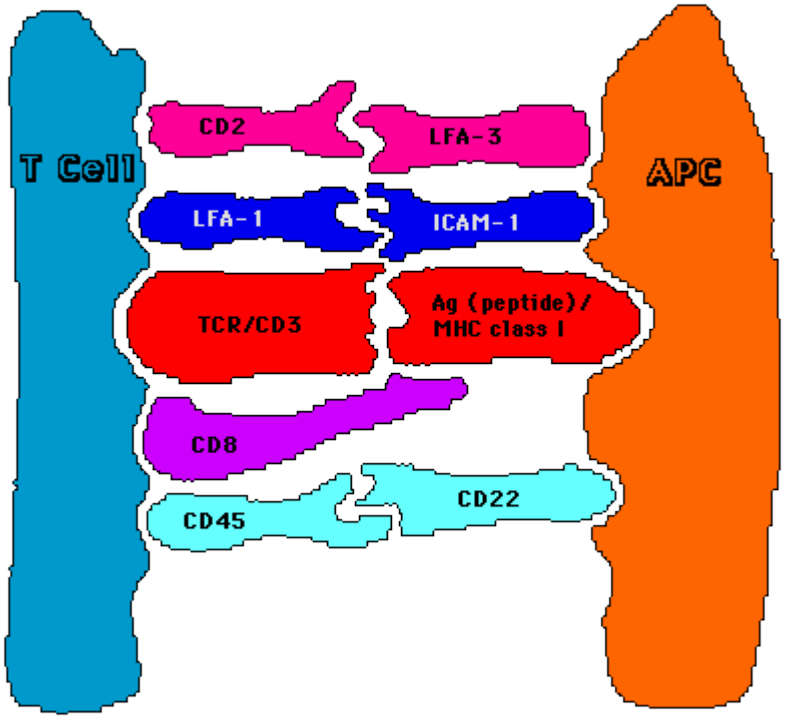

Antigen presentation needs a complicated molecular crosstalk between surface molecules of antigen presenting cells and lymphocytes.

www.microbiologybytes.com

MHC–major histocompatibility complex(mouse) = HLA-human leukocyte antigens
-specialized proteins on the surface of APC

Lymphocytes specifically activated by professional antigen-presenting cells participate not only in antiinfectious immunity but they are also important in anticancer immunological surveillance. They can be used in preparation of anticancer vaccines.

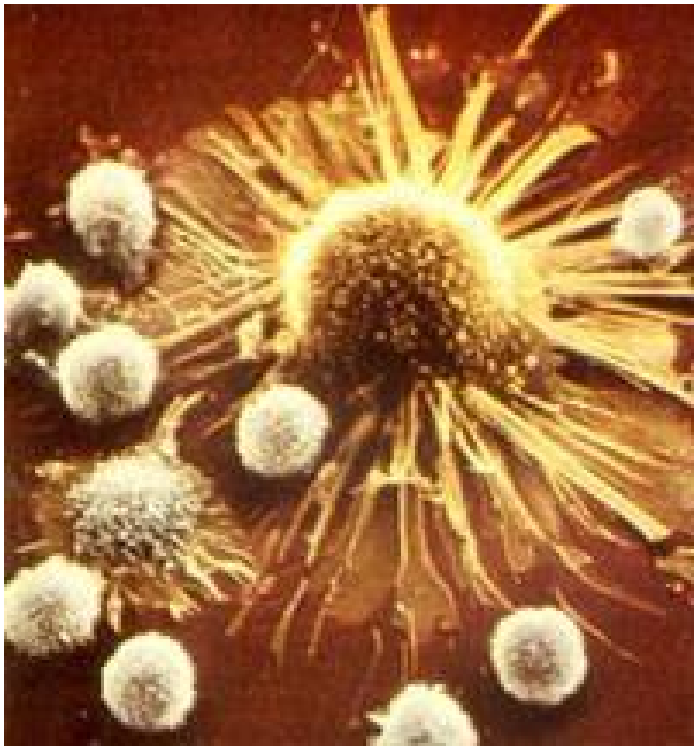

www.dkfz.de

CD8-positive toxic T-lymphocytes destroy cancer cells

Clinical Immunology (2009) 131, 1–10

FOCUS on FOCIS: Combined chemo-immunotherapy for the treatment of hormone-refractory metastatic prostate cancer

Daniela Rožková [a], Hana Tišerová [a], Jitka Fučíková [a], Jan Lašťovička [a], Michal Podrazil [a], Hana Ulčová [a], Vít Budínský [a], Jana Prausová [b], Zdeněk Linke [b], Ivo Minárik [a,c], Anna Šedivá [a], Radek Špíšek [a,1], Jiřina Bartůňková [a,*,1]

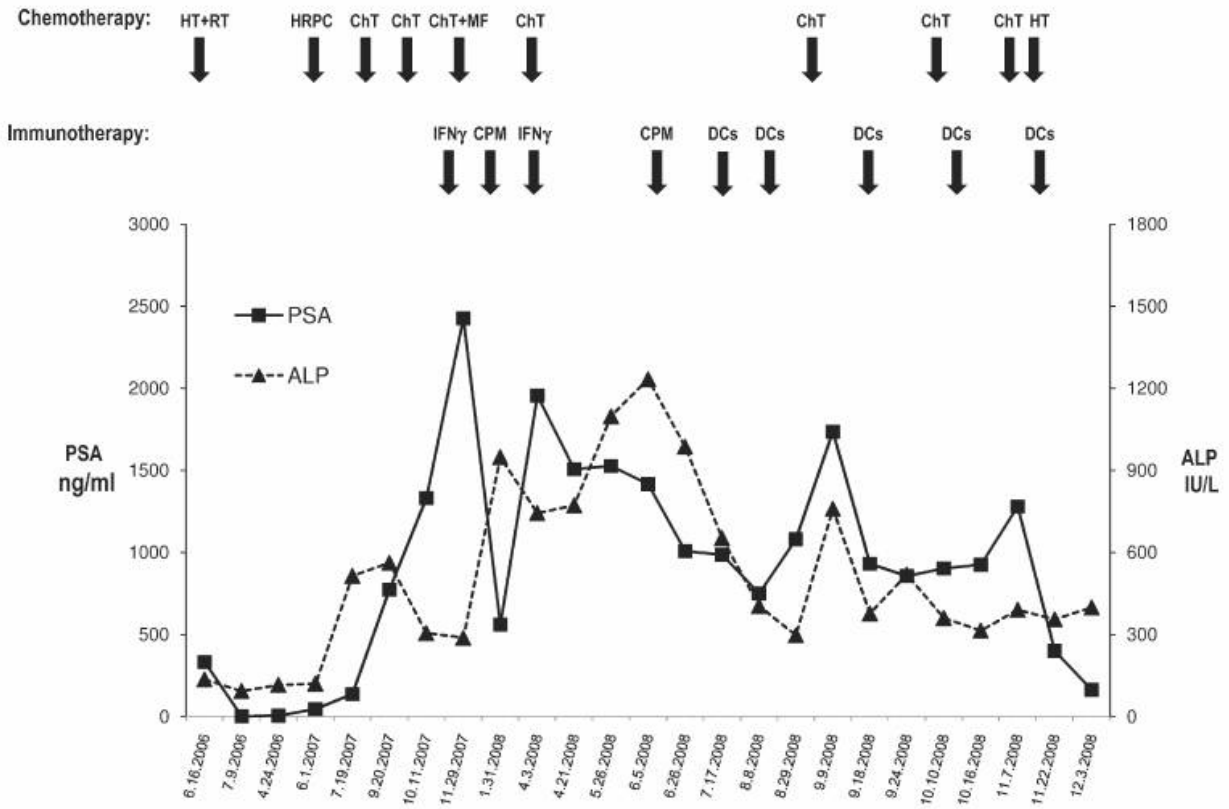

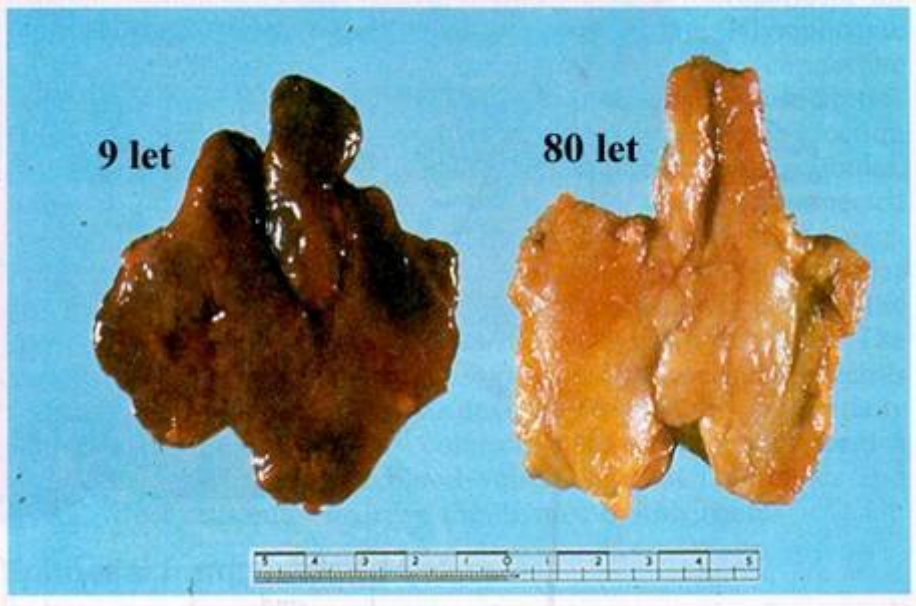

Thymus (brzlík)

Sup. mediastinum

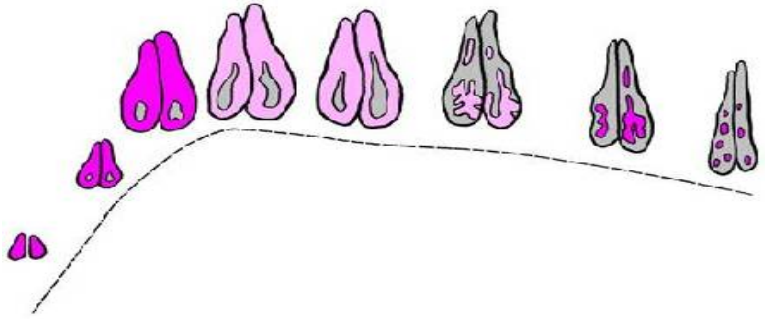

- *Involution of thymus*

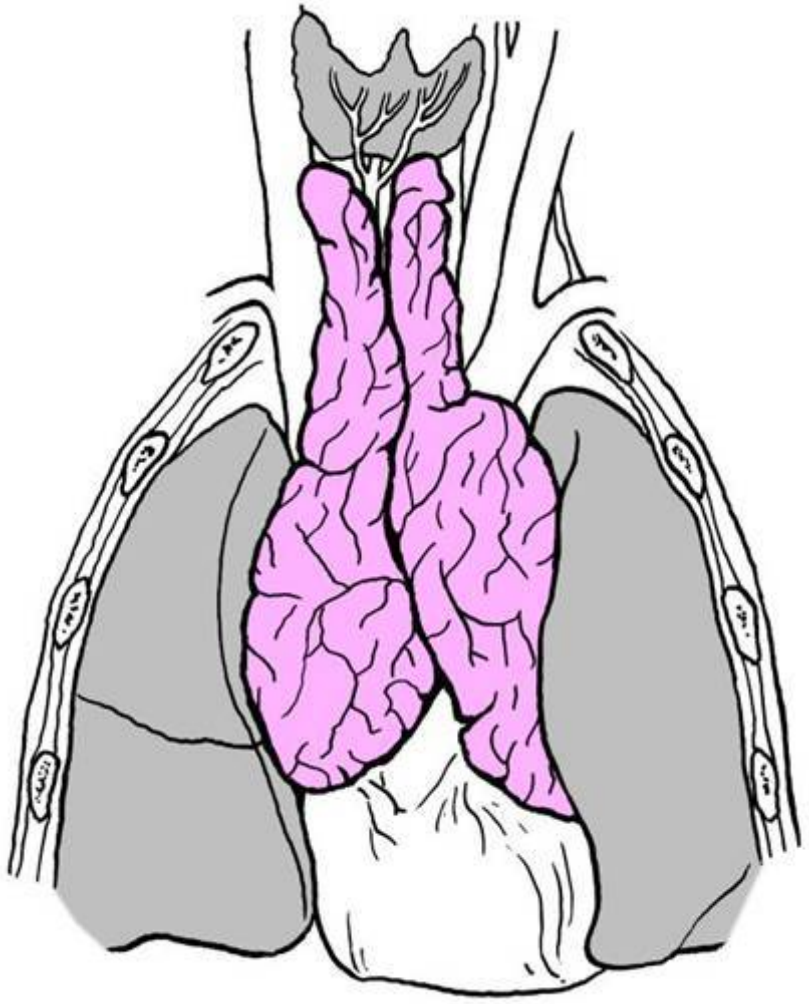

Thymus is primary lymphatic organ with a key role in the control of the differentiation of naive lymphocytes to the form of T-lymphocytes. Thymus is originated in embryonic pharynx. It is located in anterior mediastinum. Thymus is involuted during the postnatal development. It is free from the lyphatic afferents.

Origin of thymus

www.wsahs.nsw.gov.au

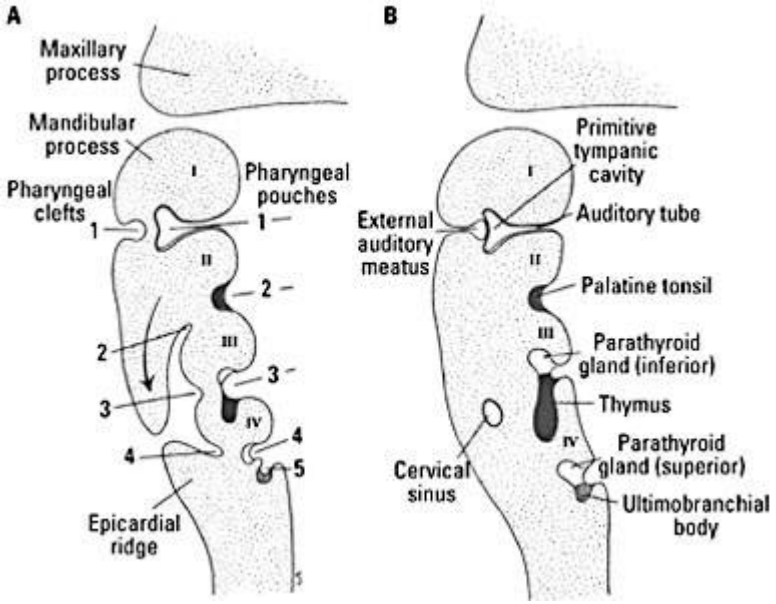

http://www.ehponline.org

3rd pharyngeal pouch
-process of migration (descent)

Ectopic thymic and parathyroid tissue

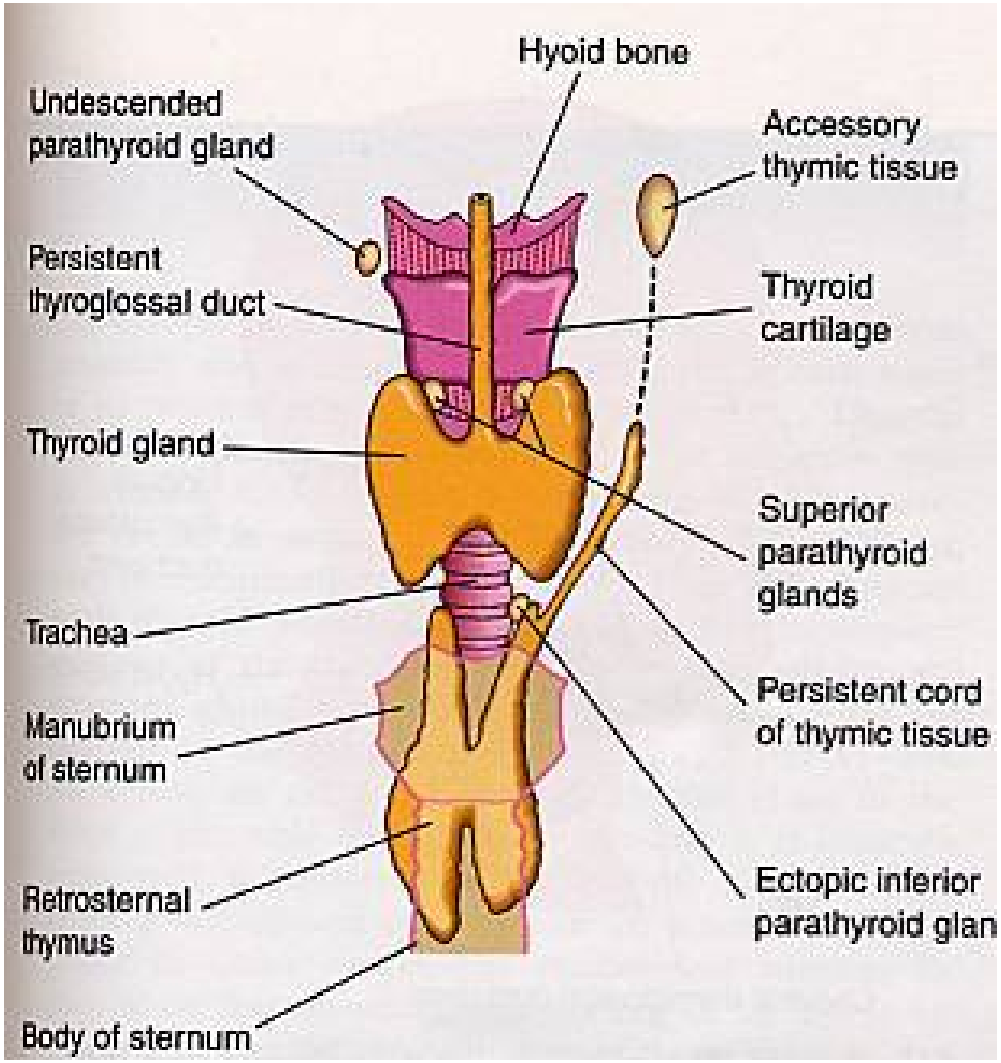

Thymus – stromal cells+developing T cells

several incomplete lobules
capsule -trabeculae
cortex with developing T-cells
medulla with Hassall´s corpuscles

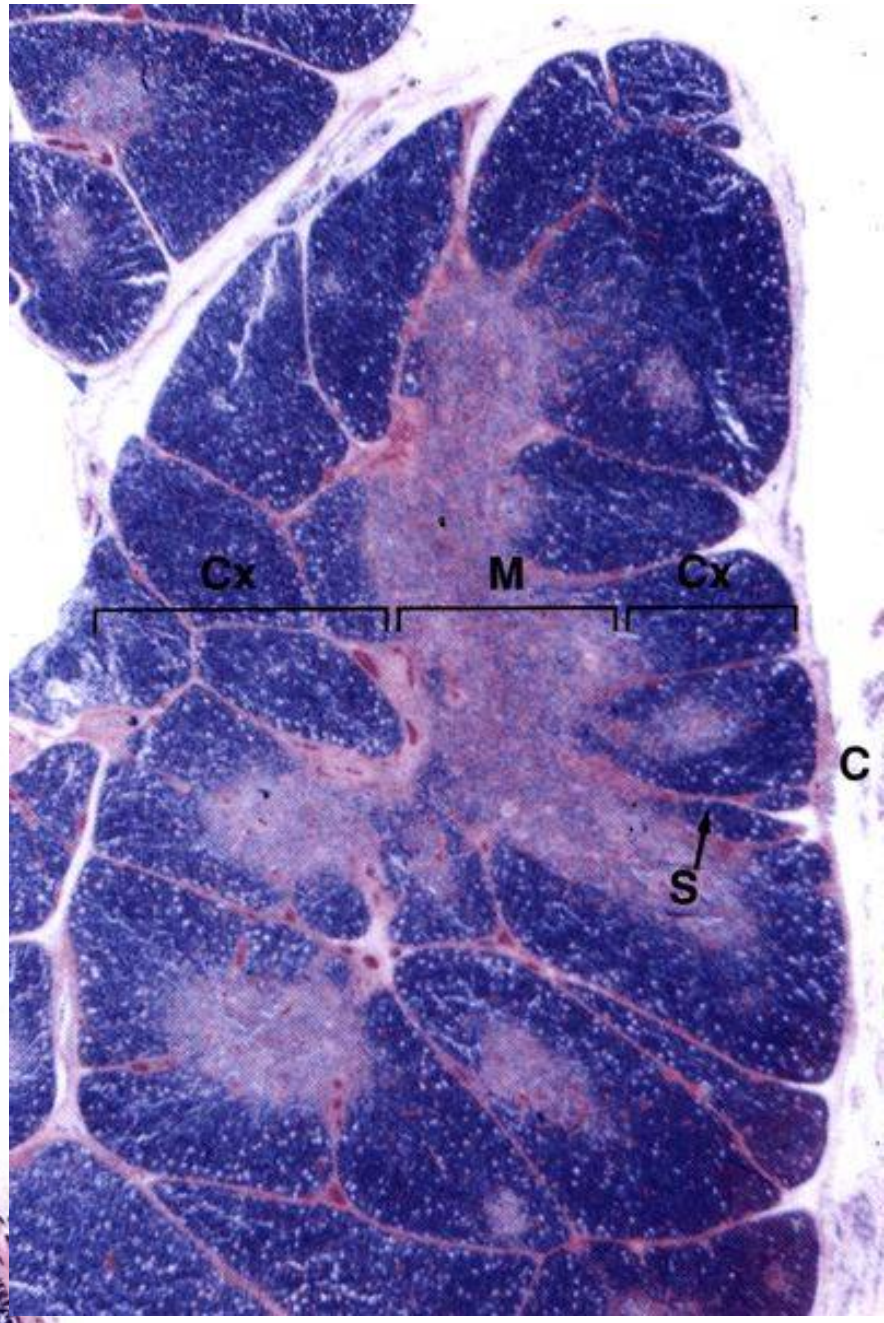

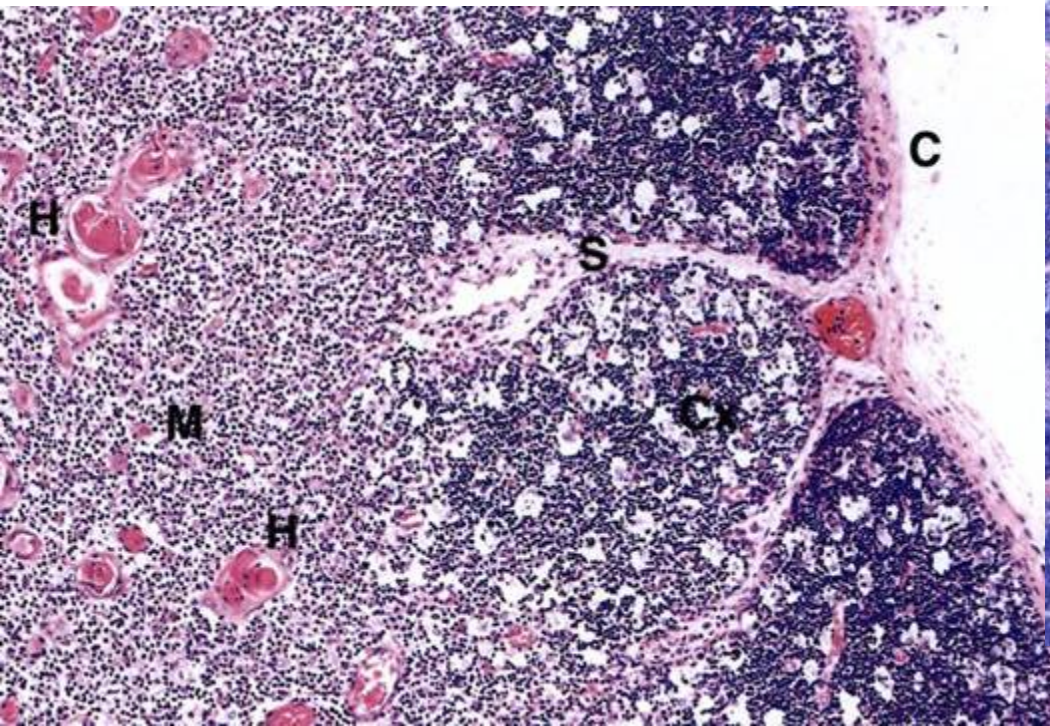

lymphonode

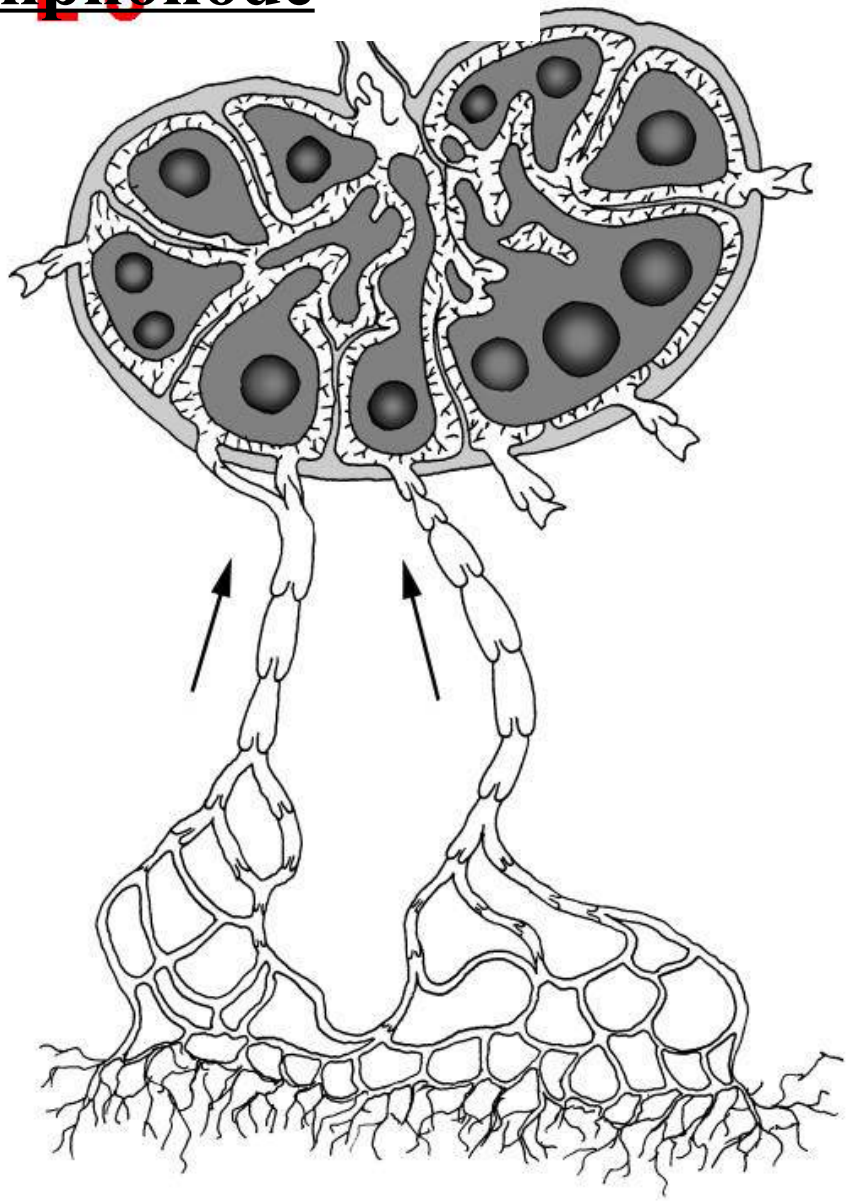

hilum

aff. et eff. vessels

capsula , trabeculae

sinuses –

Cortex - folliculi
paracortex,
medulla

Spleen

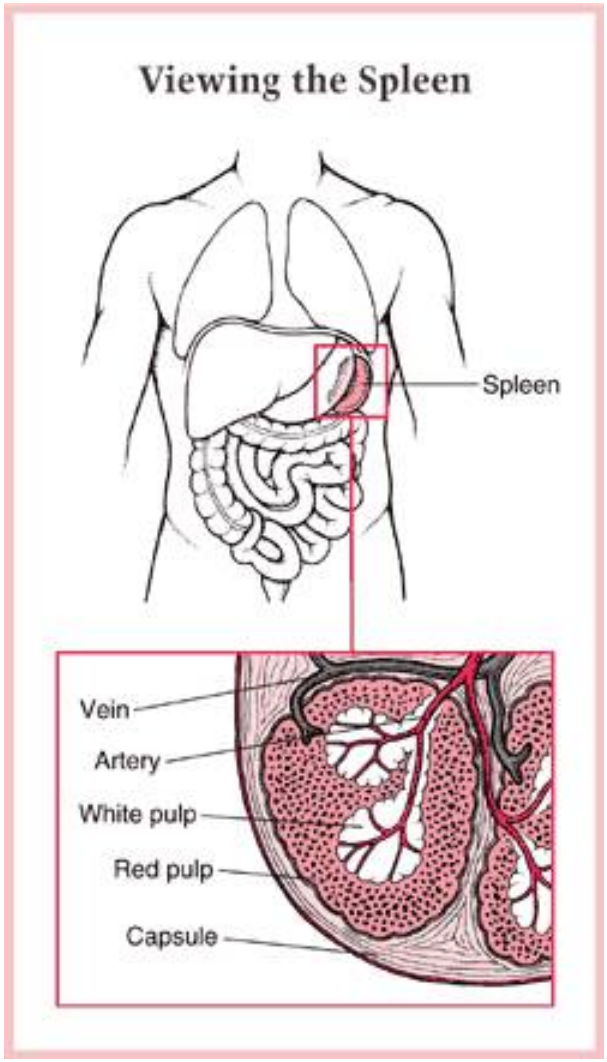

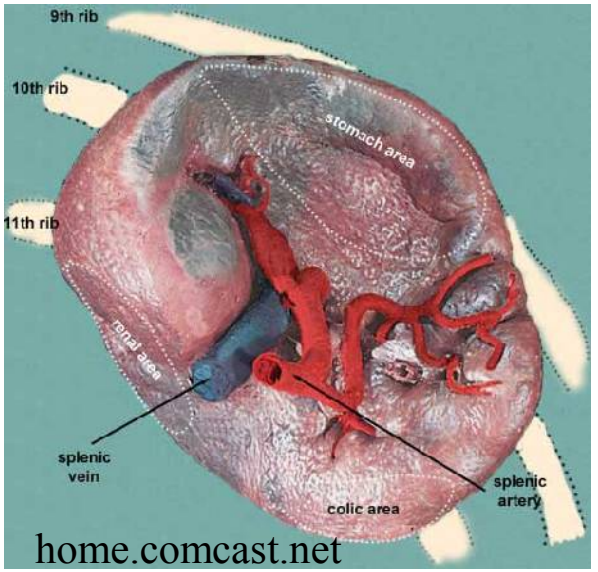

home.comcast.net

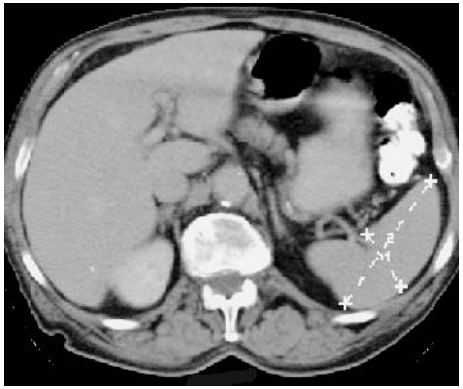
www.szote.u-szeged.hu

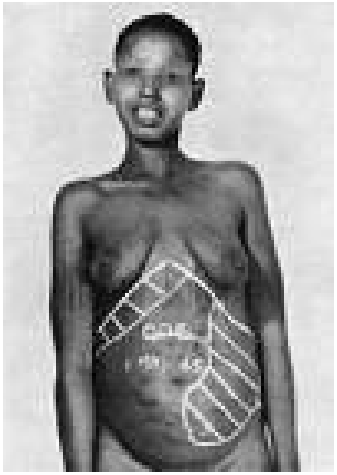
http://www.isradiology.org/

The spleen (lien) is one of the most important secondary lymphatic organs. It is located in abdoinal cavity. In addition to immune function it is reponsible for destruction of old erythrocytes. The hematopoiesis was prenataly located in the spleen.

Spleen

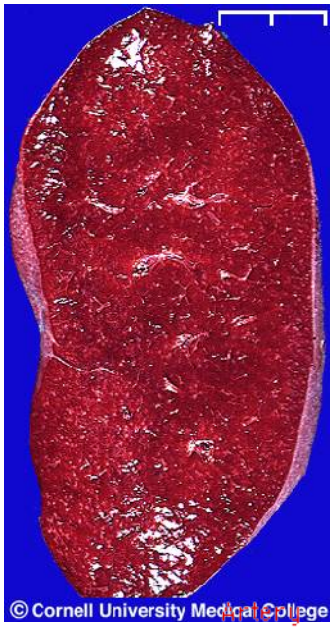

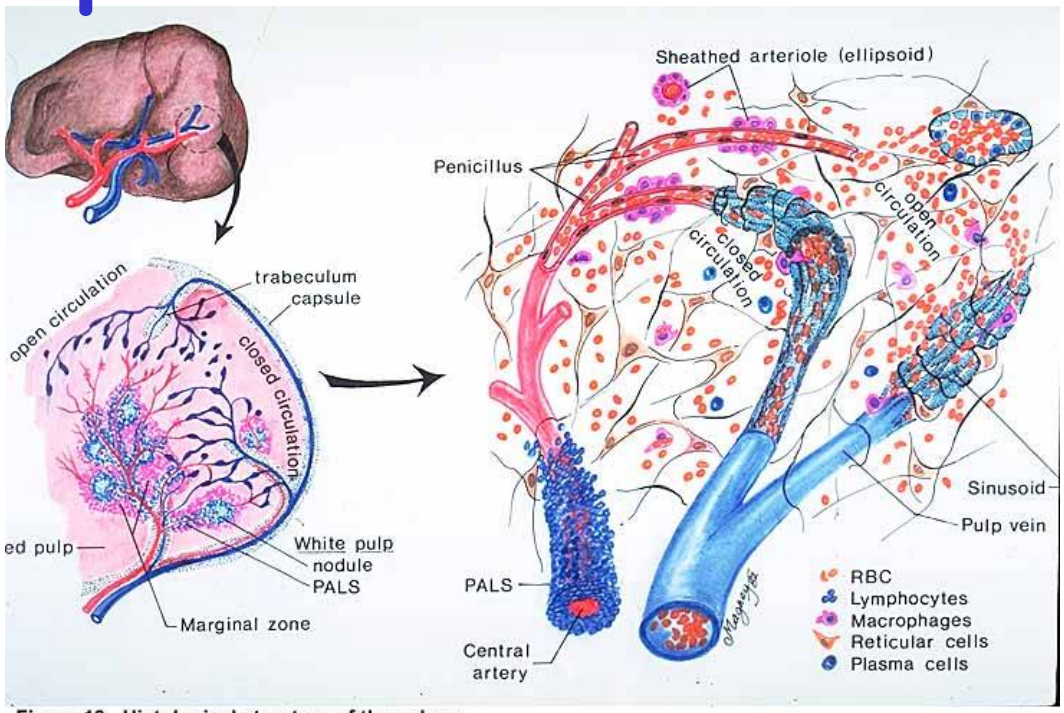

Figure 18. Histological structure of the spleen.

mednote.co.kr

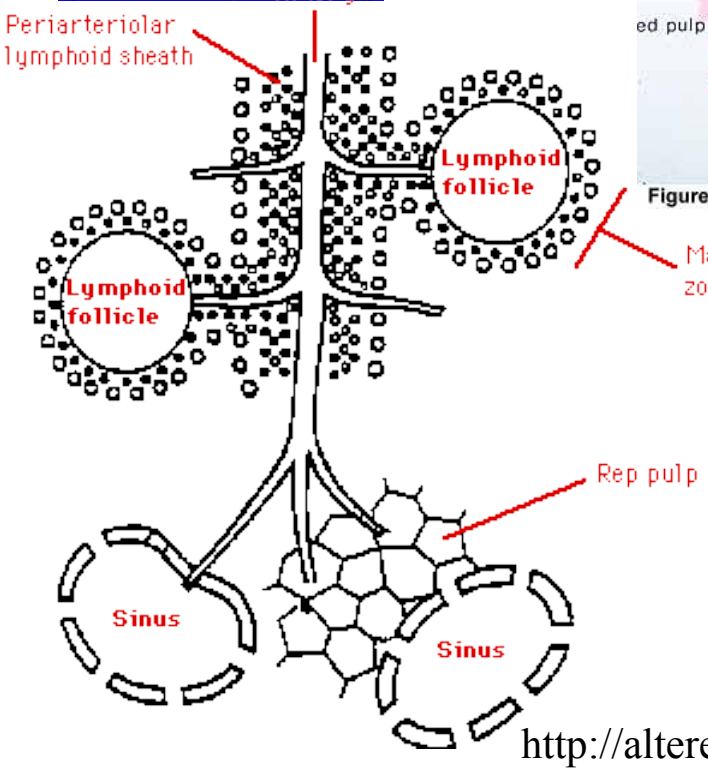

http://altered-states.net

Stroma consists of:
white pulp=central arteriole + PALS+ corona (B, T cells)
red pulp=sinusoids and cords

Spleen (12x)

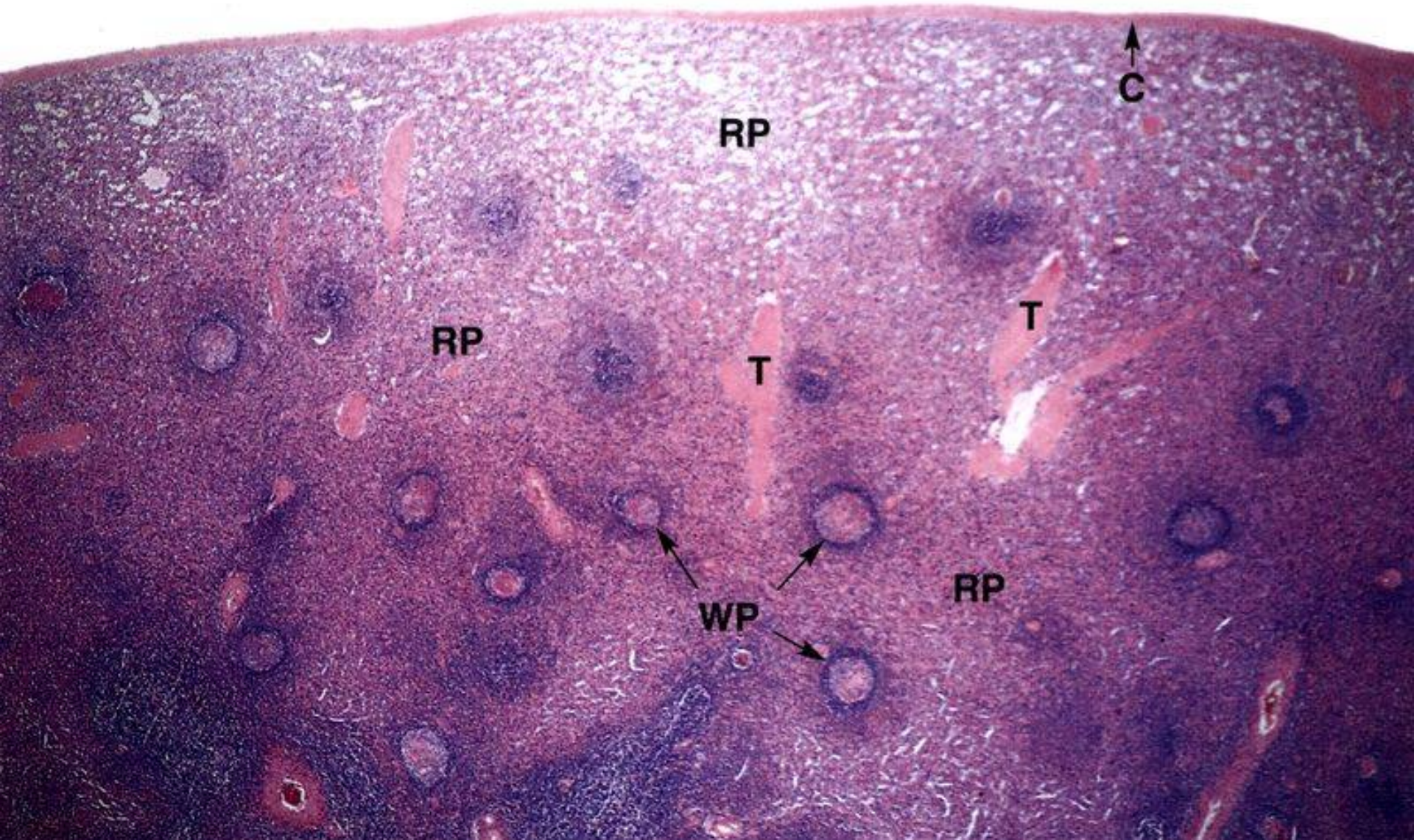

Lesser peritoneal cavity (Bursa omentalis)

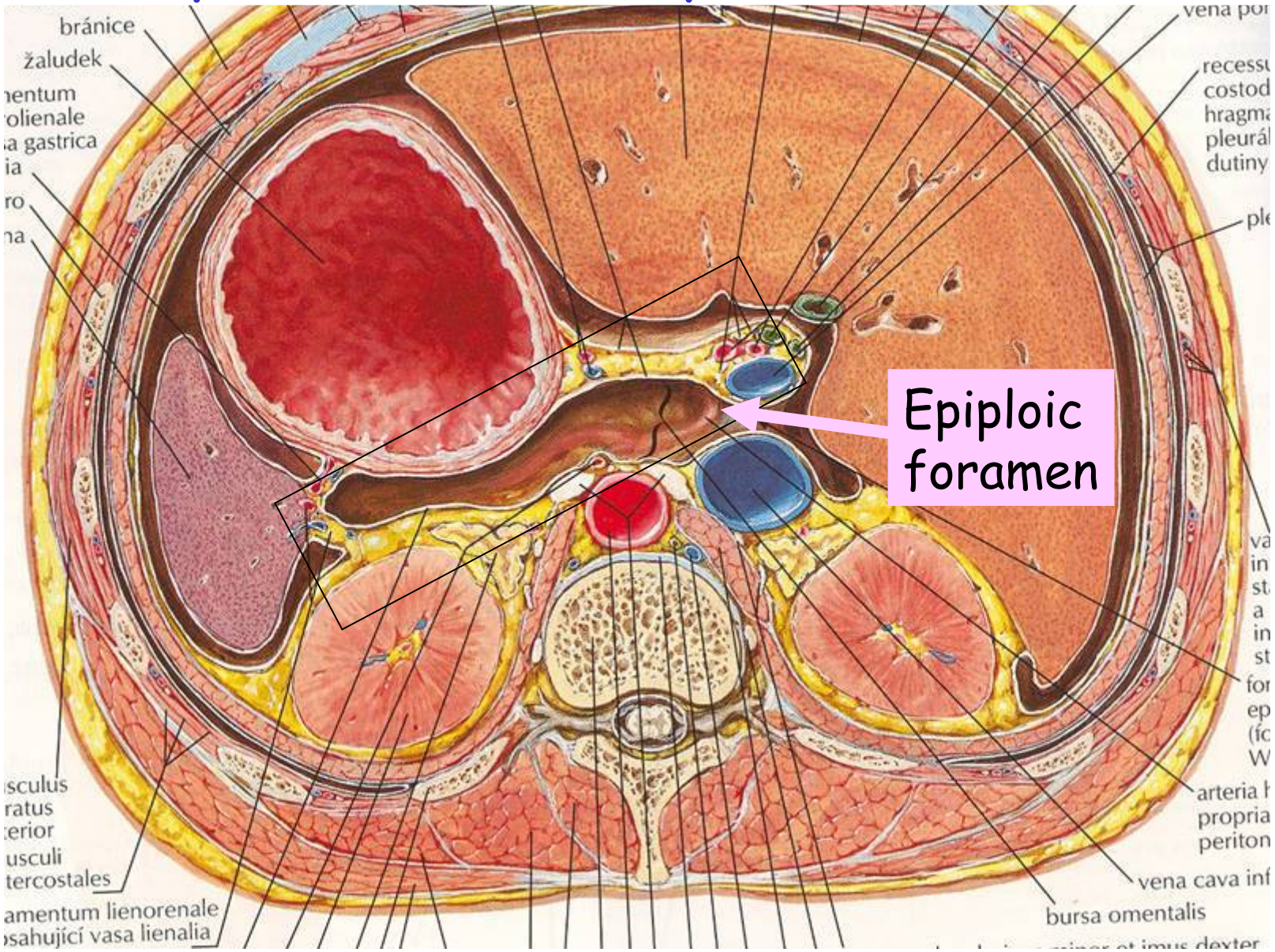

F. H. Netter: Anatomický atlas člověka. Grada/Avicenum, Praha, 2003

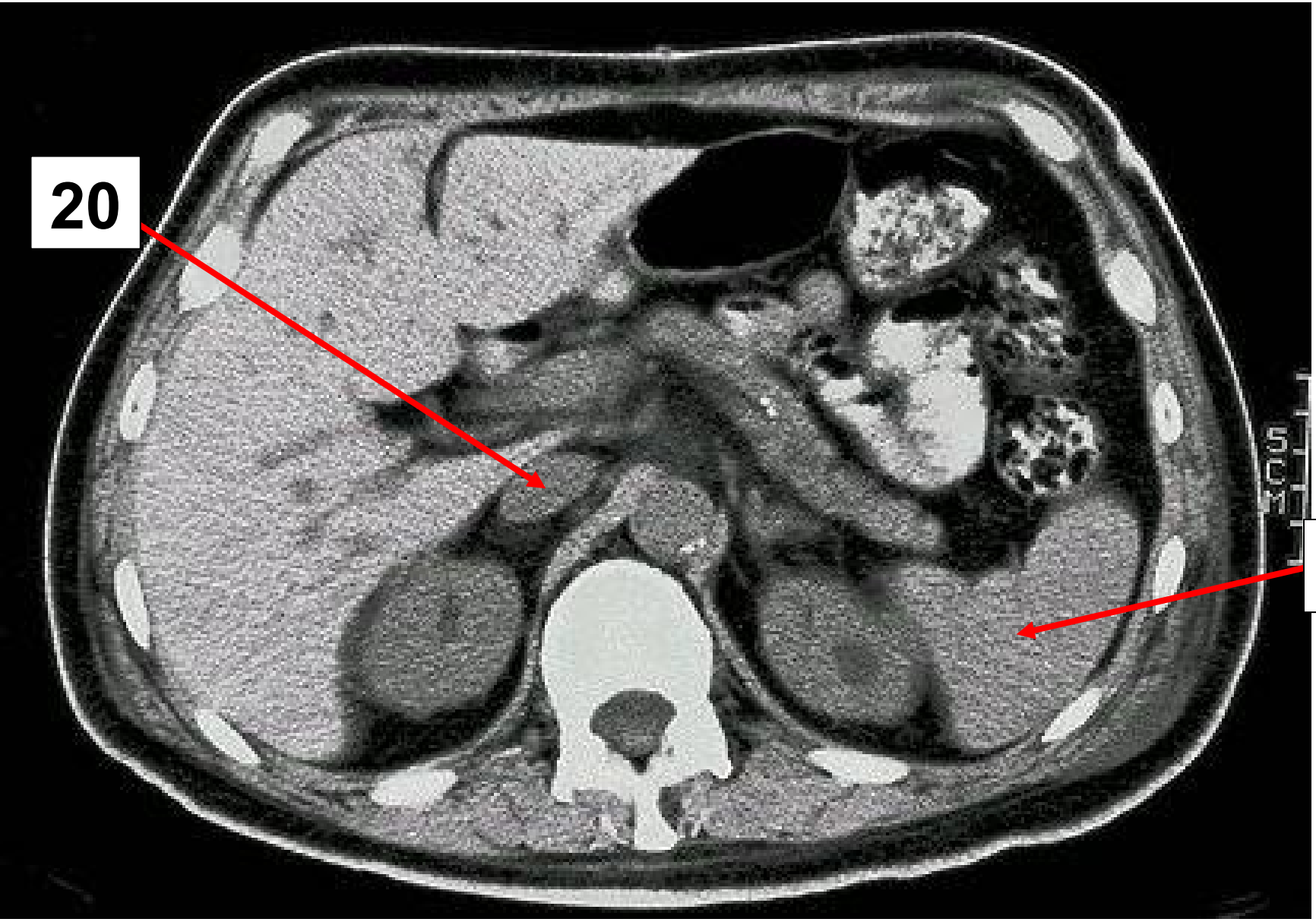
20
19

Lymphatic nodes are also the secondary lyphatic otrgan. They are included into the lymphatic vessels. The represent a site of active antigen presentation. Both T/B lymphocytes are actively proliferating inside the lymph nodes in course of immune reaction.

Lymphatic node

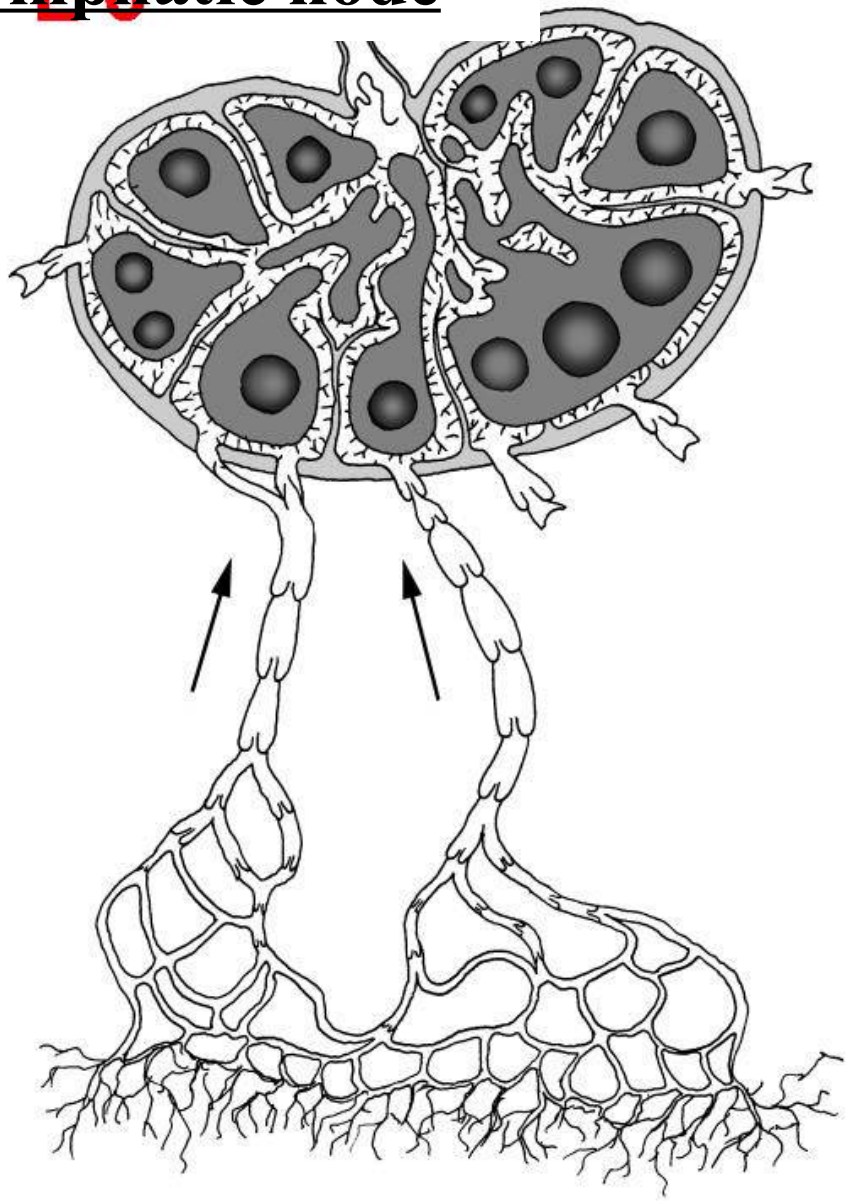

hilum

aff. et eff. vessels

capsula , trabeculae

sinuses –

Cortex - folliculi
paracortex,
medulla

Lymphatic node

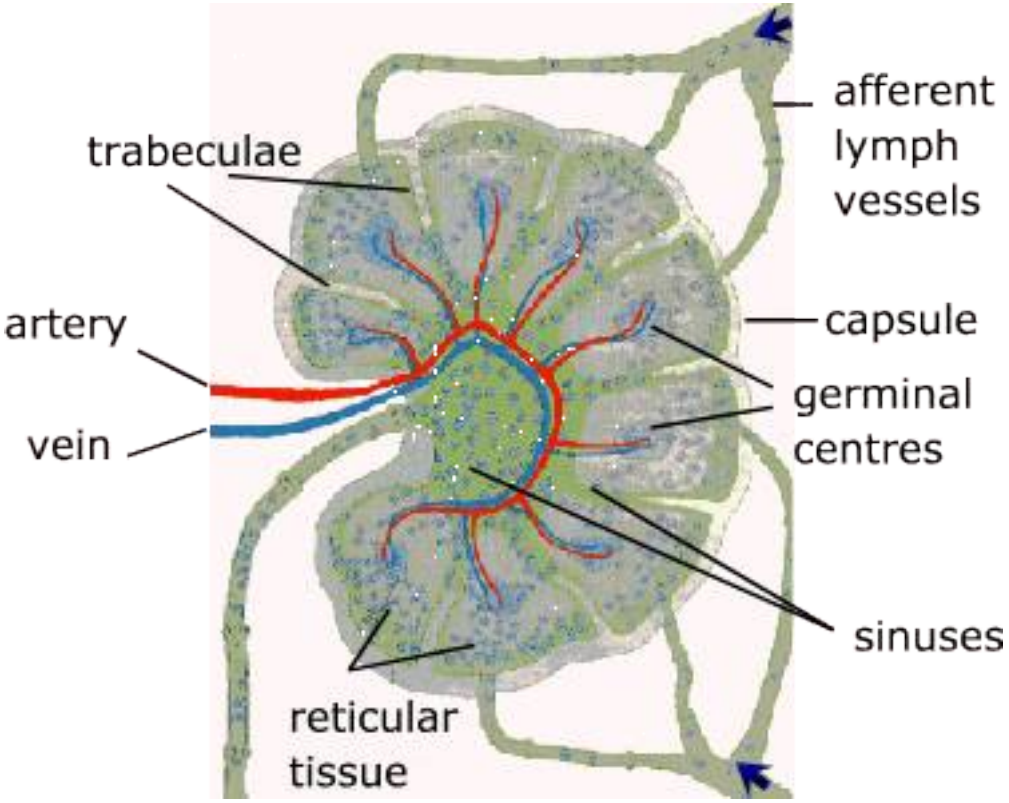

http://lymphaticmassagenyc.com

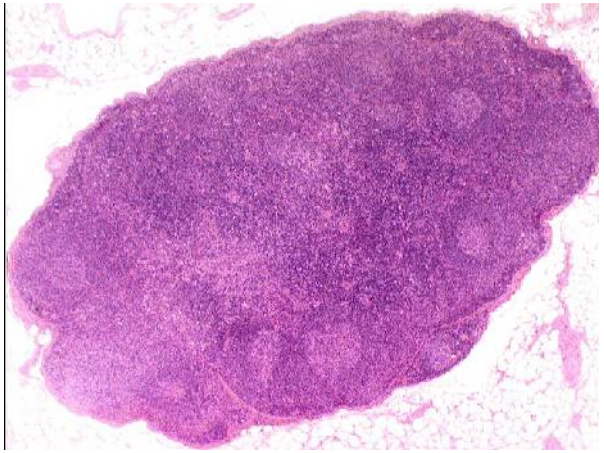

http://education.vetmed.vt.edu

Lymphatic node (x 8)

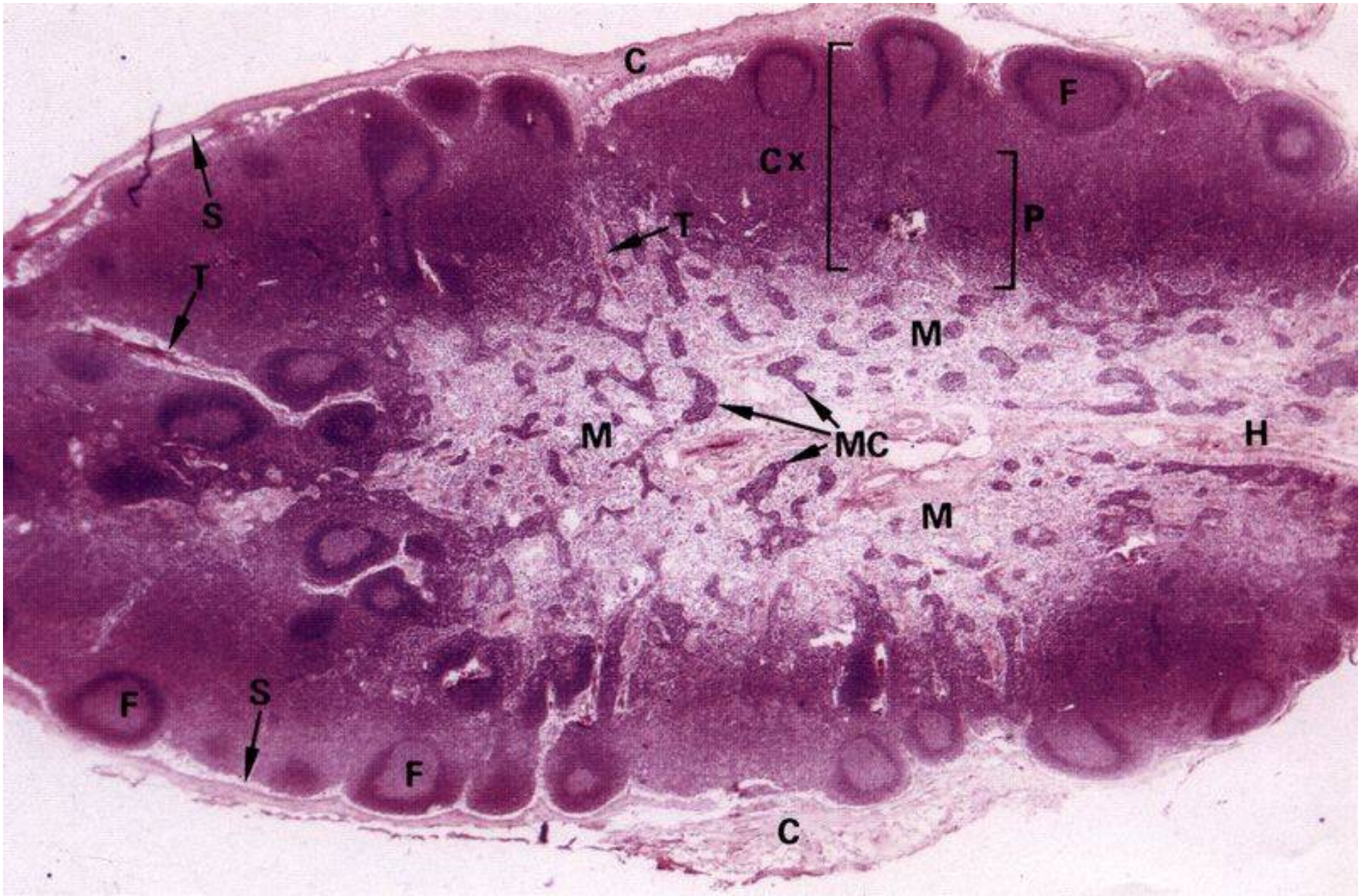

Follicle with germinal centre and mantle (x 50)

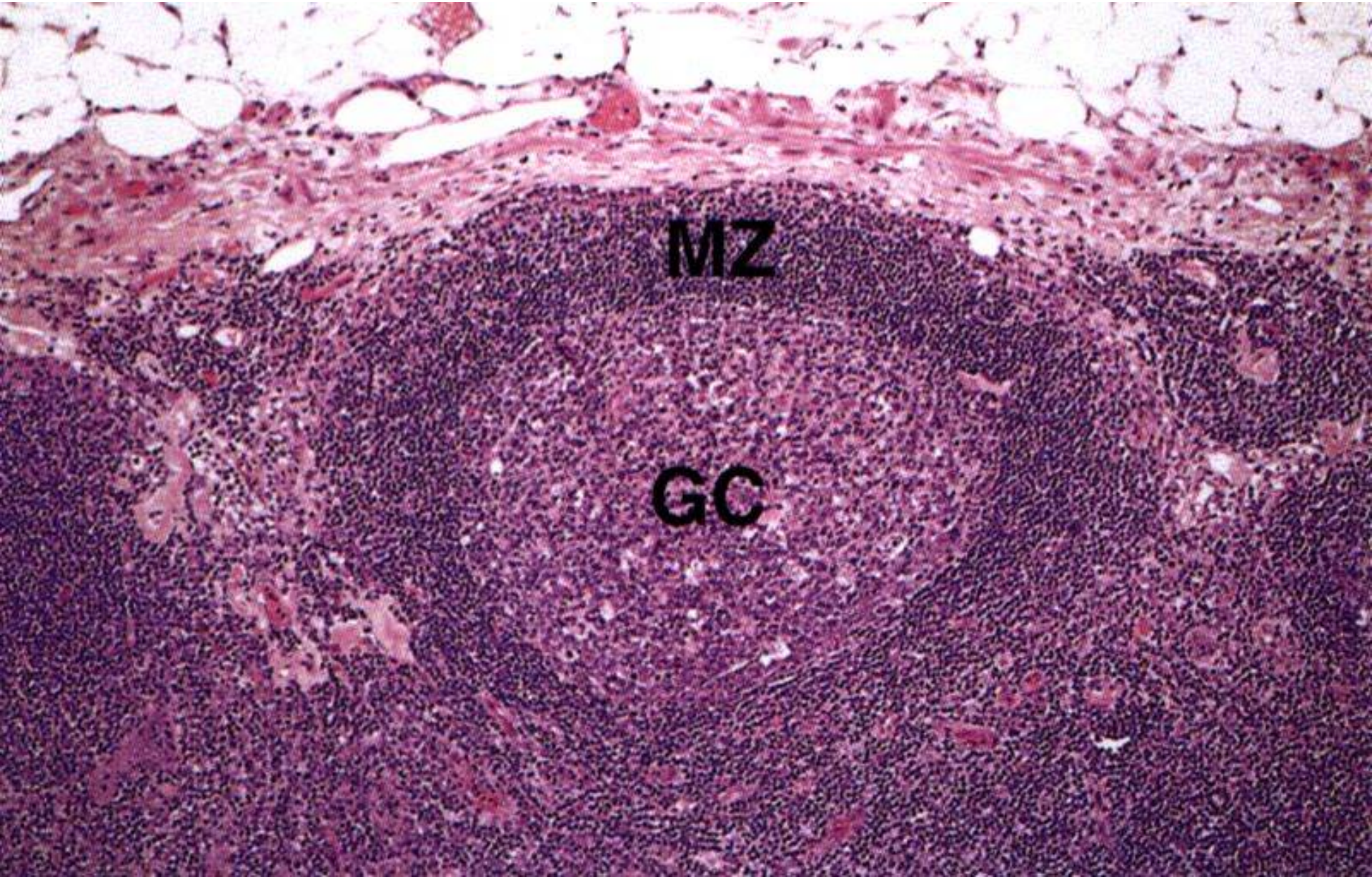

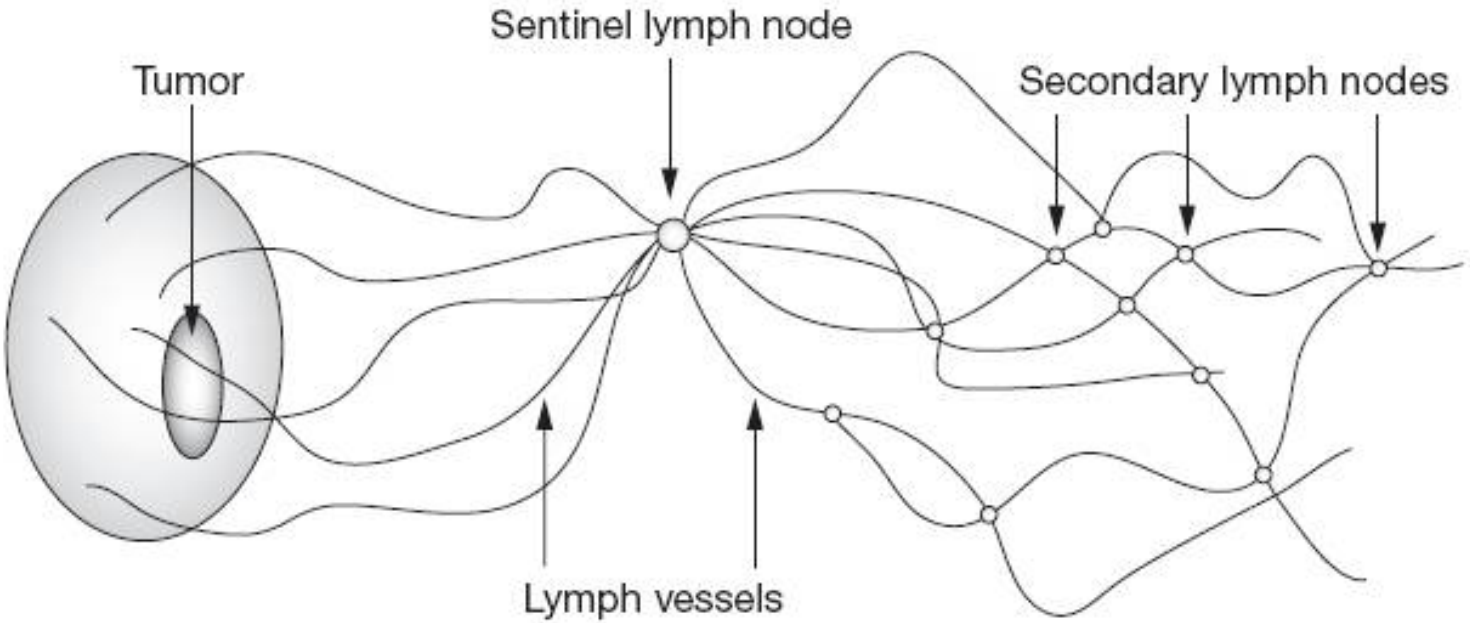

Figure 1 Schematic illustration of the sentinel lymph node concept. The sentinel lymph node (SLN) is the primary lymphatic drainage center from a tumor-bearing organ. The SLN should be the first, and can be the only, site of lymphatic metastasis. A tumor-negative result from the SLN negates the possibility of more-distant lymphatic metastatic spread.

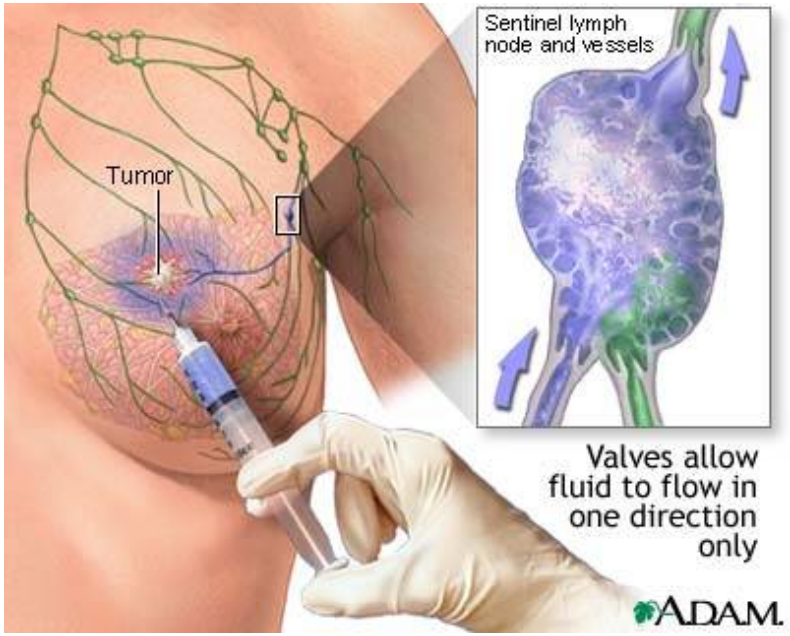

http://www.clarian.org/

Method of sentinel node decreases an occurrence of complications connected with radical surgery of of breast cancer such as a lympoedema.

http://lymphedemaville.wordpress.com/

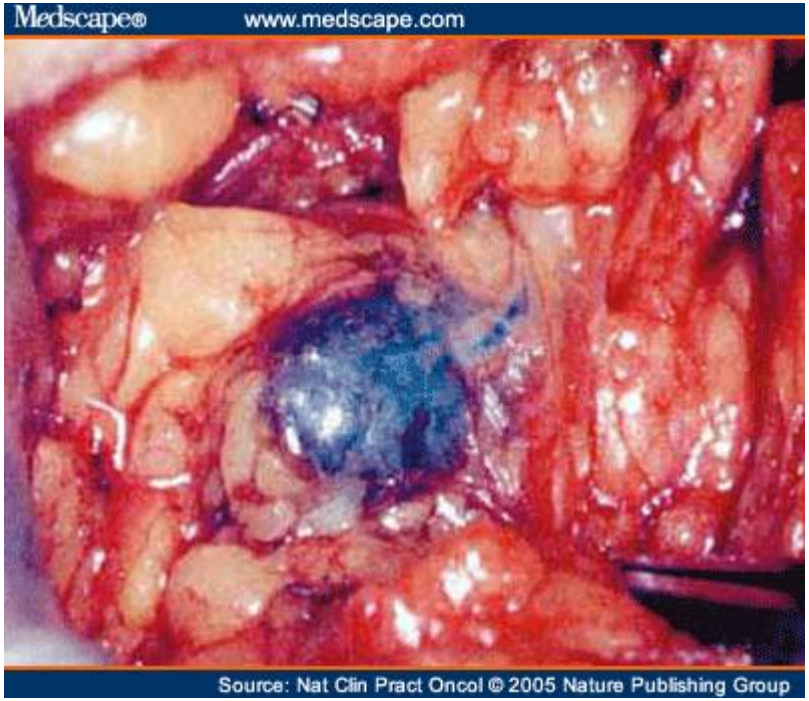

http://img.medscape.com

Lymphatic tissue is accumulated in the wall of internal organs that are in contact with factors of macroenvironment (for example digestive or respiratory system).

MALT (Mucosa associated lymphatic tissue)

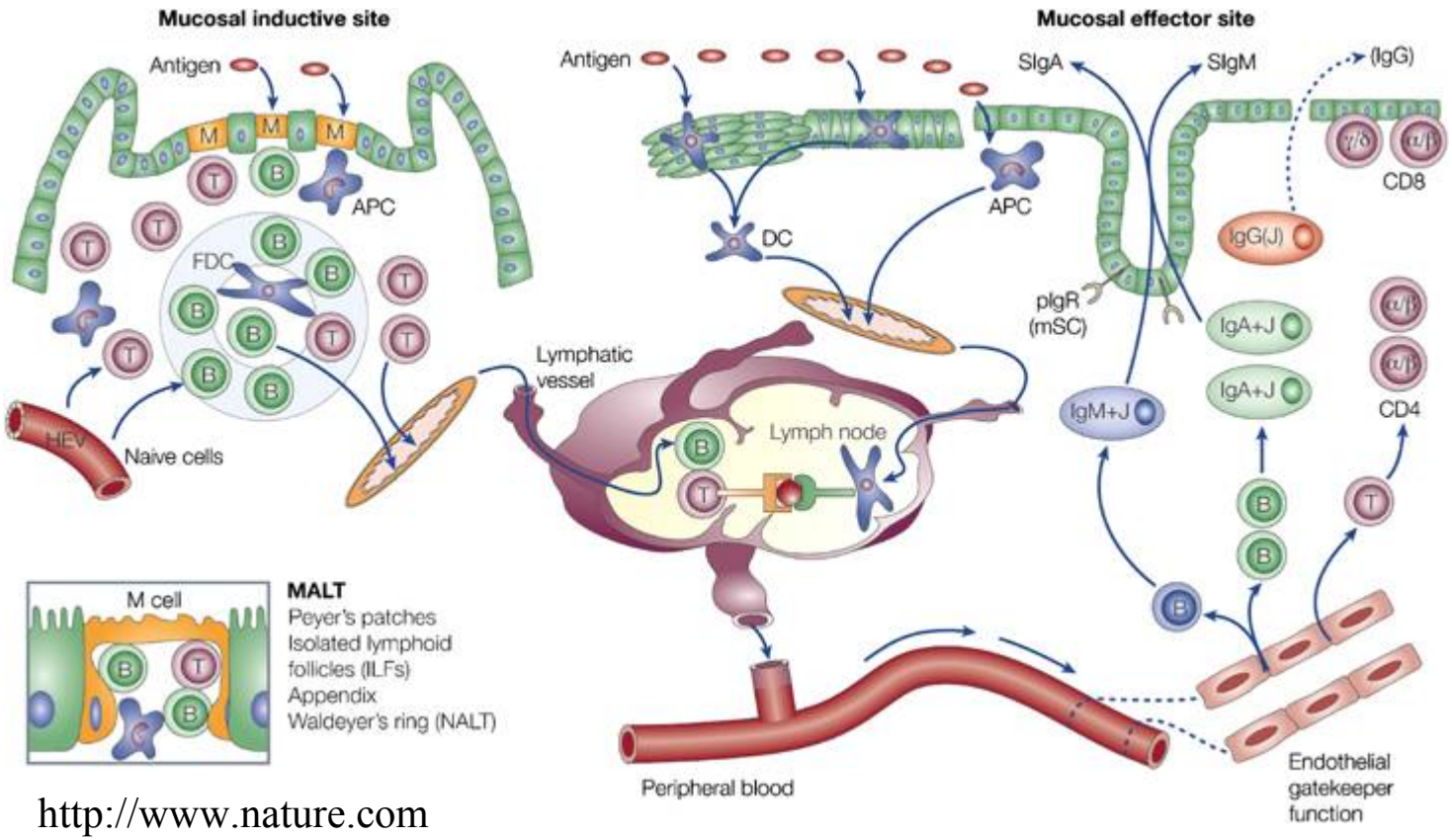

http://www.nature.com

Appendix vermiformis

http://www.mghradrounds.org/

http://www.anatomie.net

Accumulation of lymphatic tissue in the specific sites of oro/nasopharynx: tonsils

Tonsila palatina-origin

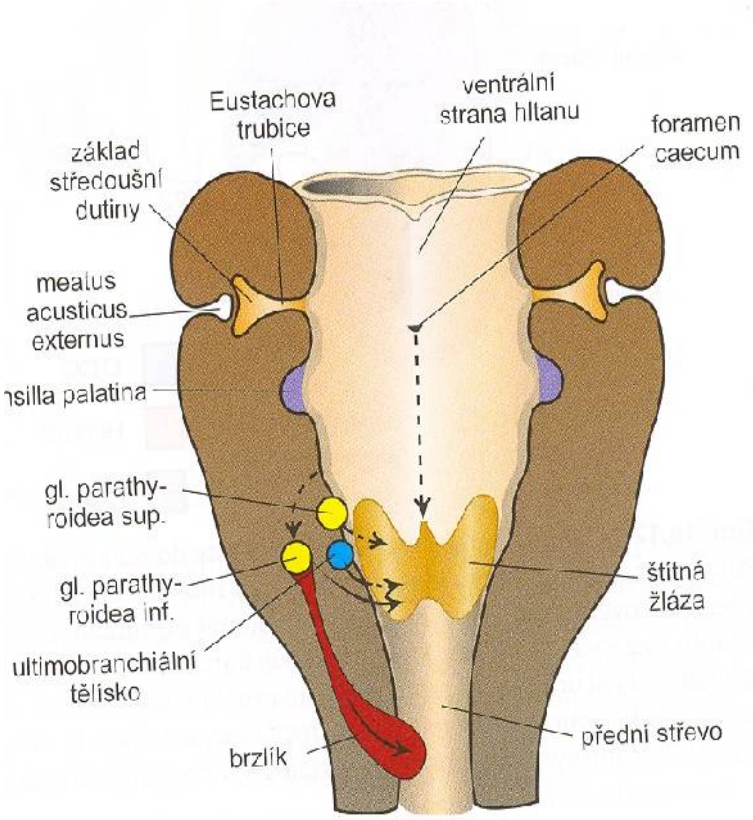

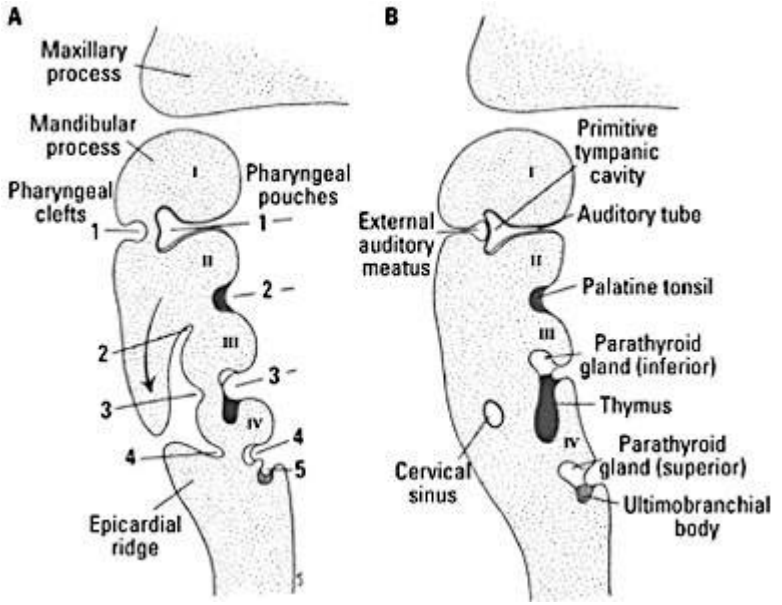

Sadlet TW: Langmanova lékařská embryolopgie, Grada, 2011, Praha

Lamphatic circle of Waldeyr

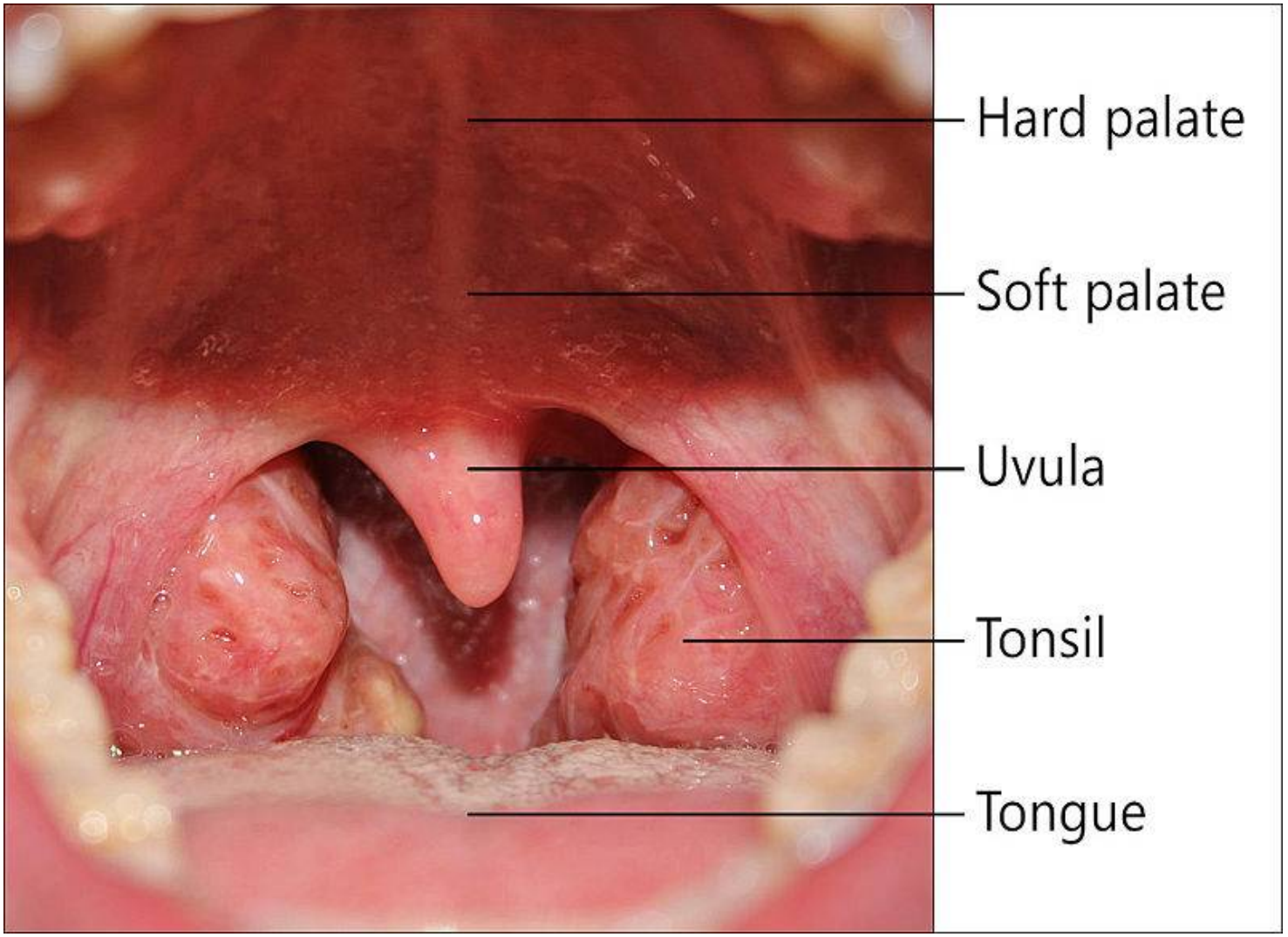

http://www.dentalarticles.com/images/throat-tonsils.jpeg

Tonsila palatina

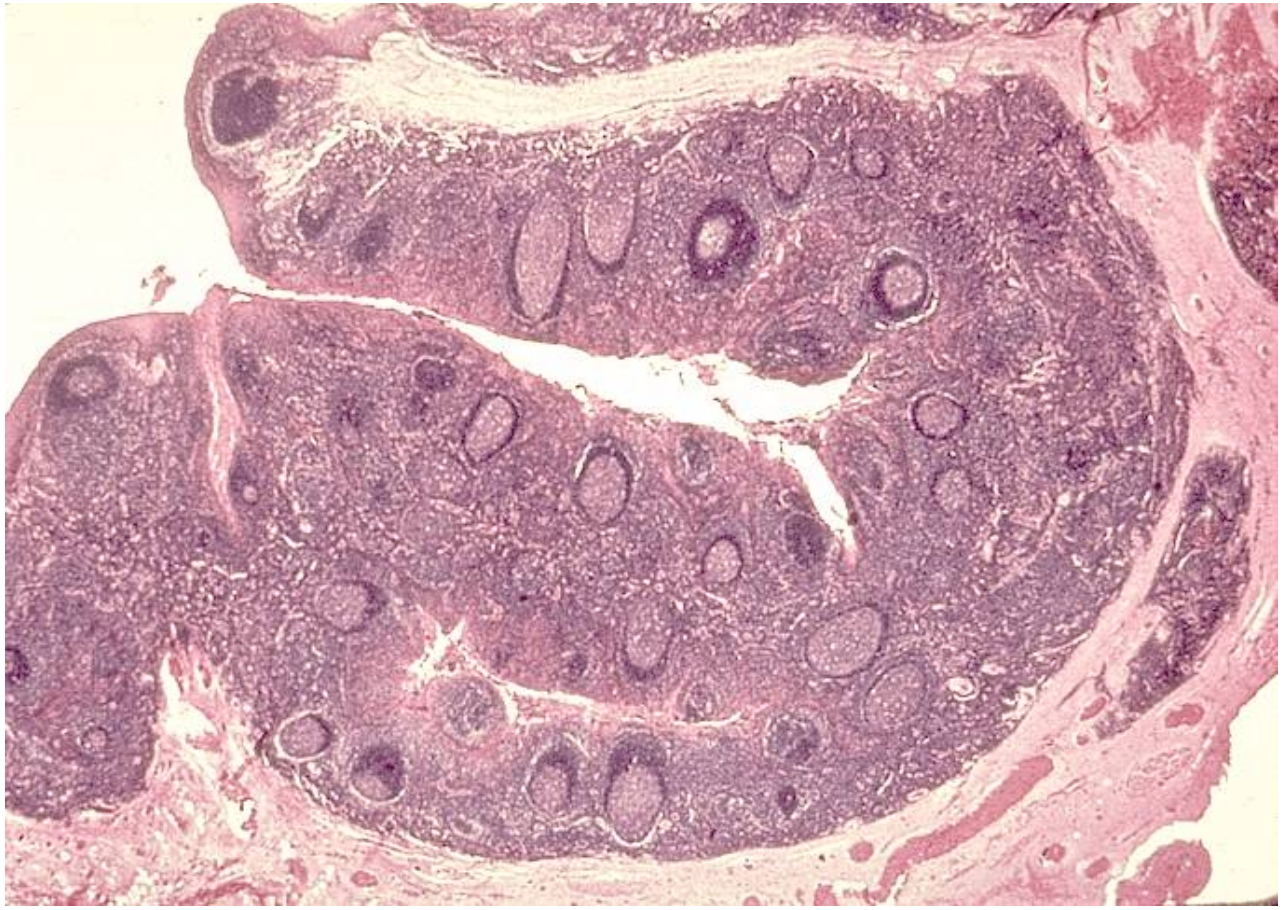

www.udel.edu

Tonsila lingualis

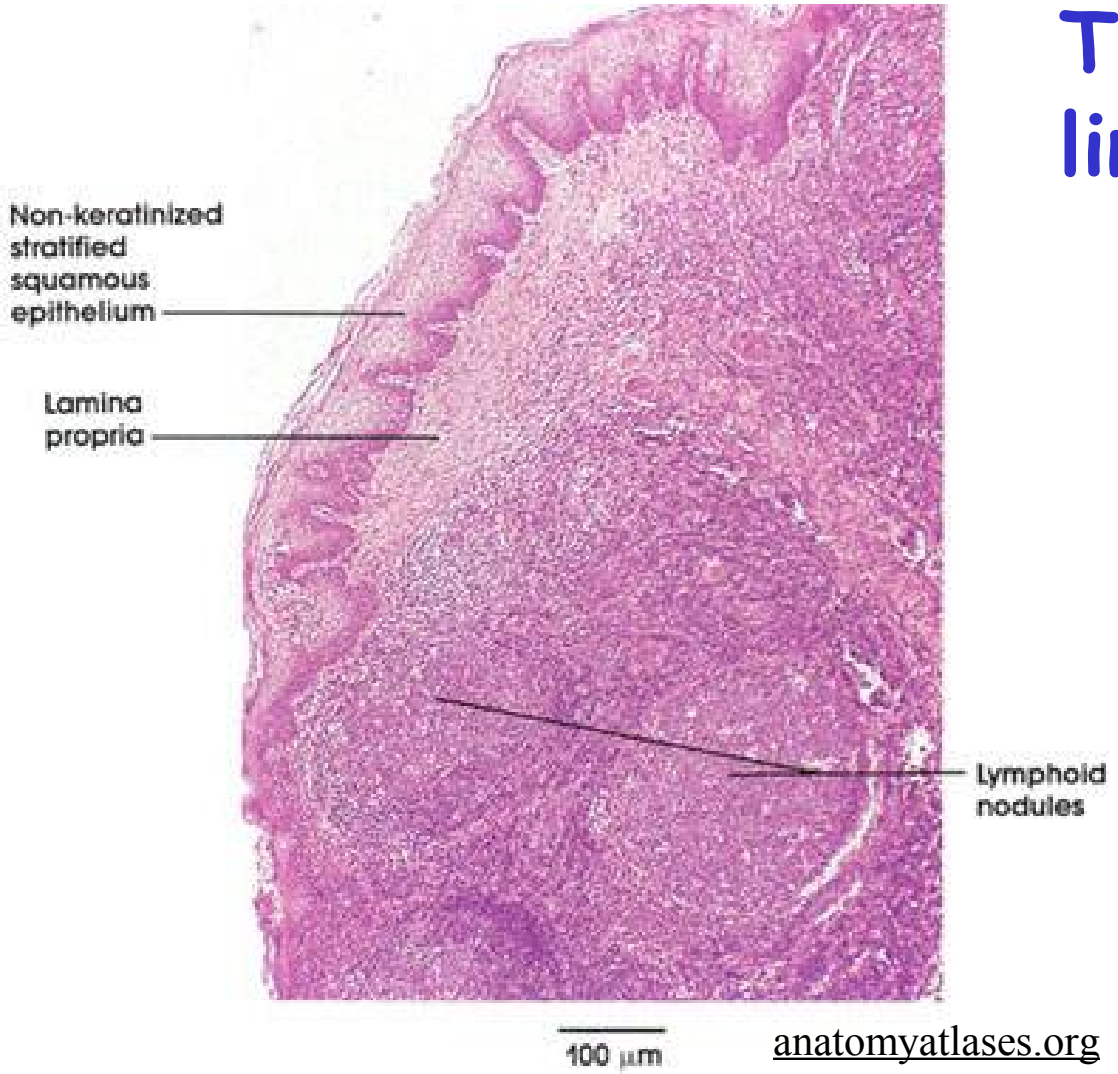

anatomyatlases.org

Tonsila pharyngea

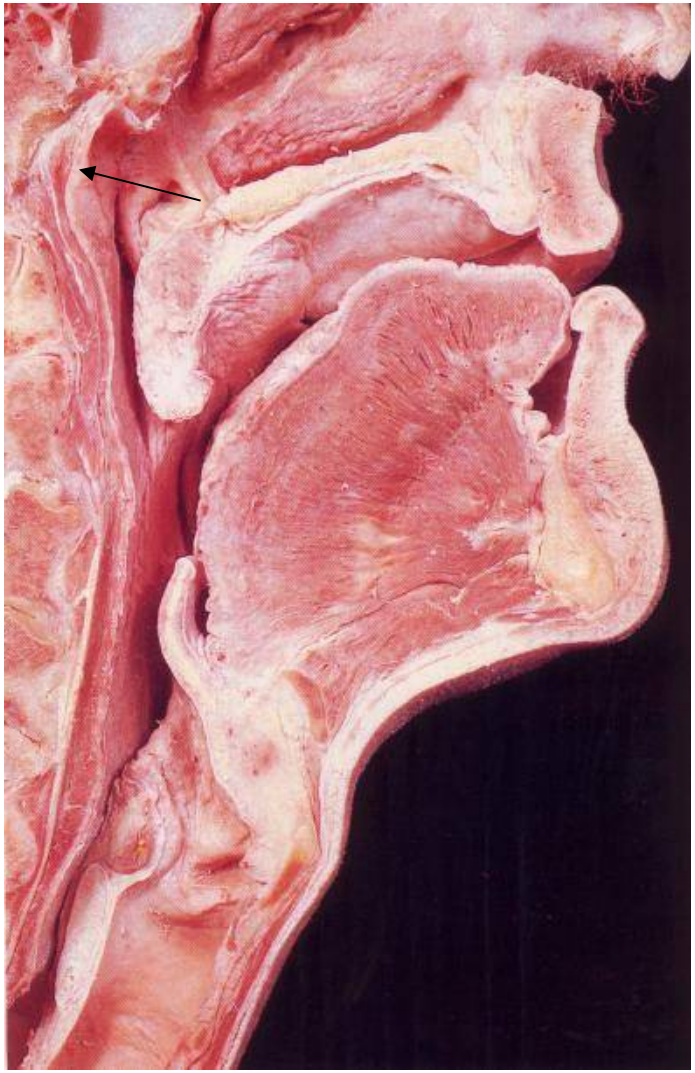

http://www.esg.montana.edu

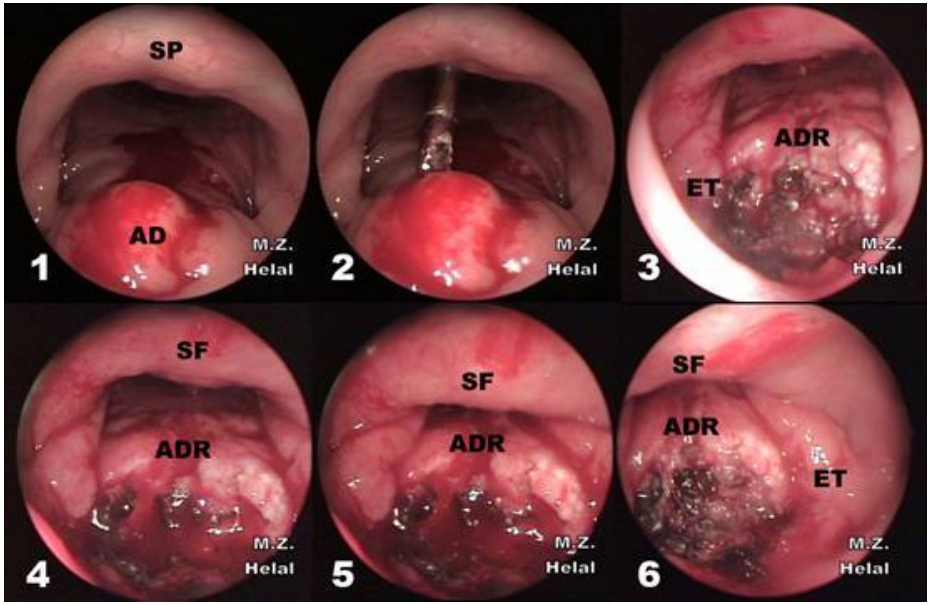

http://www.mzhelal.com

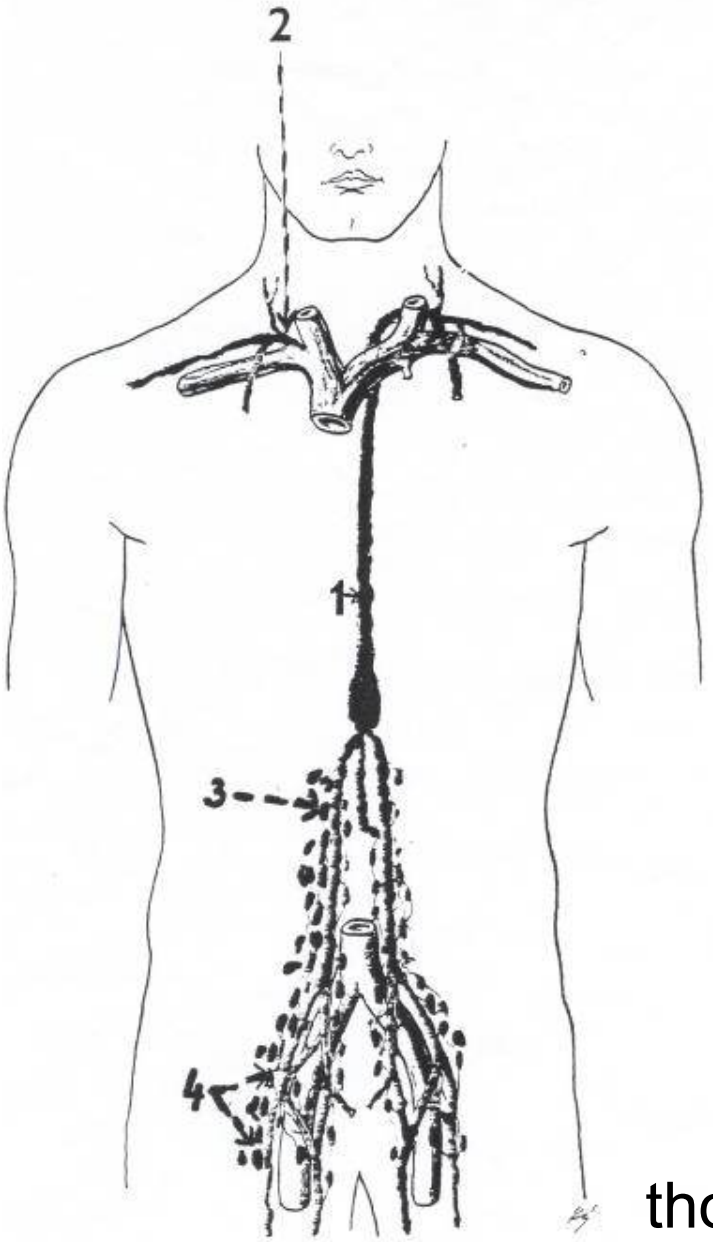

1.ductus thoracicus
2.truncus lymphaceus dexter
3.nodi lymphatici lumbales
4. nodi lymphatici iliaci

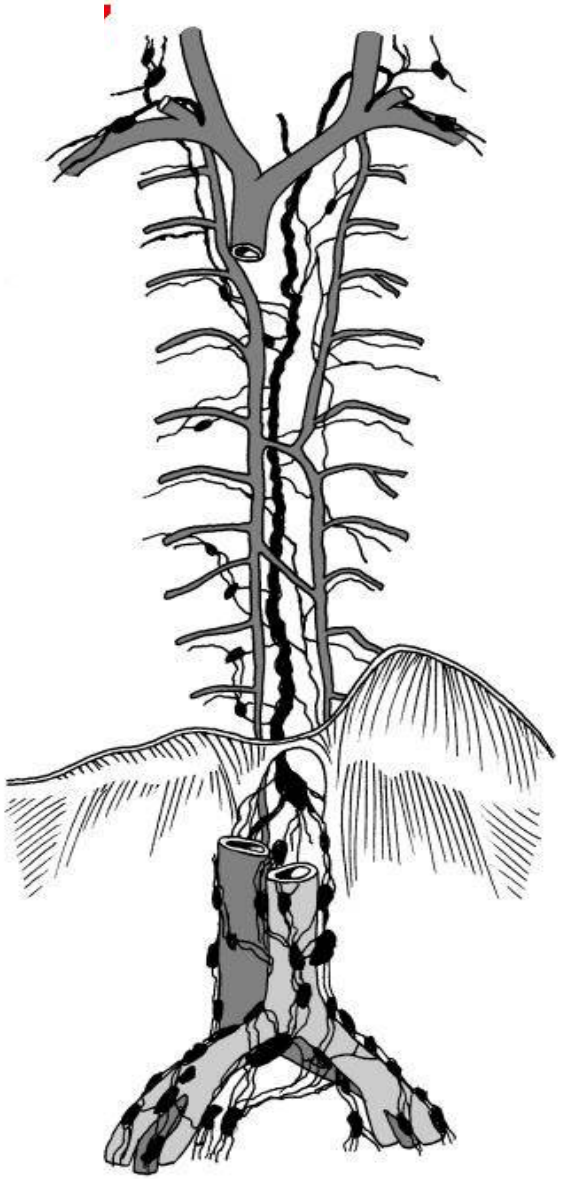

thoracic d., right lymph. tr, jugular tr., subclavian tr., bronchomediastinal tr., intestinal tr., lumbar tr.

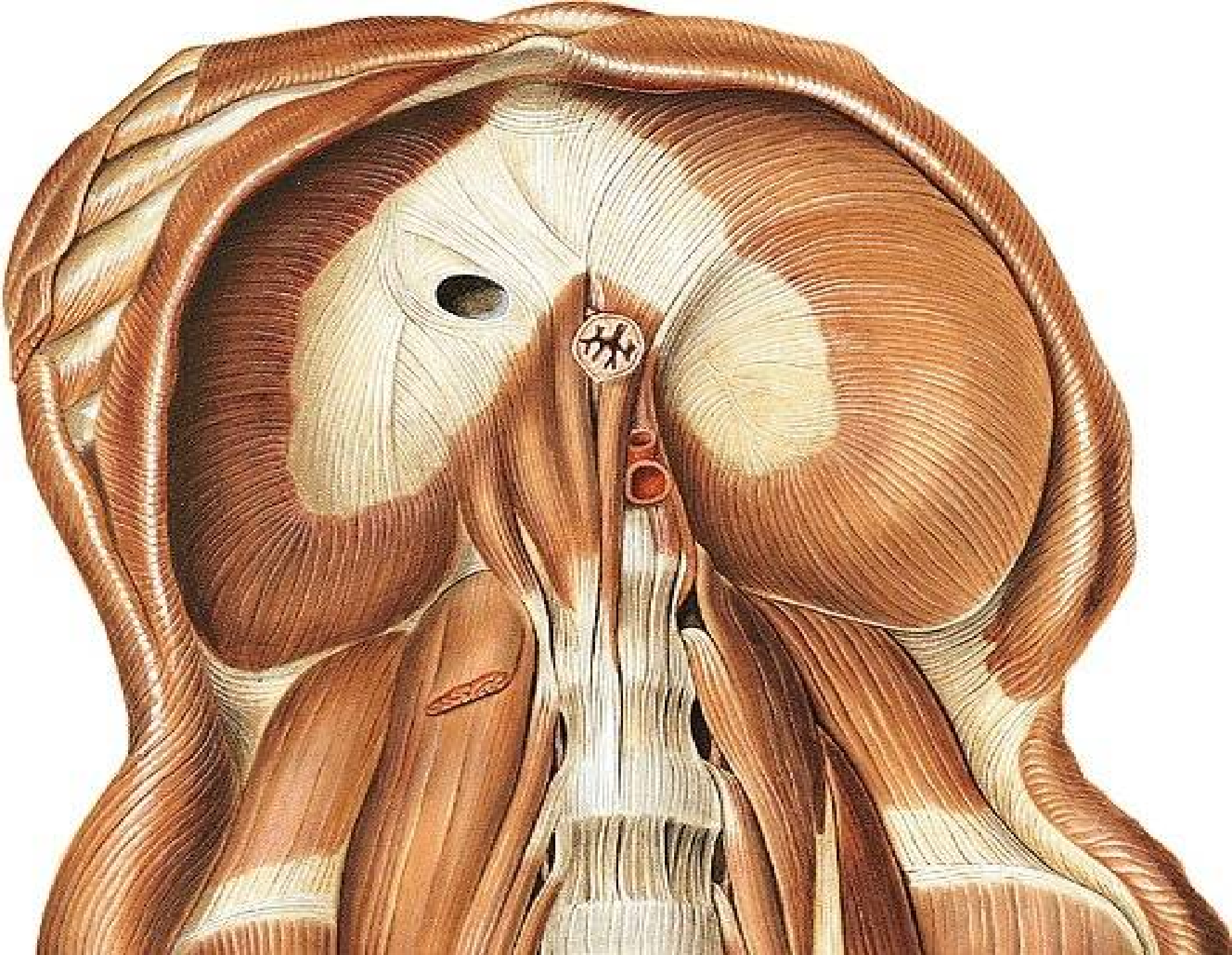

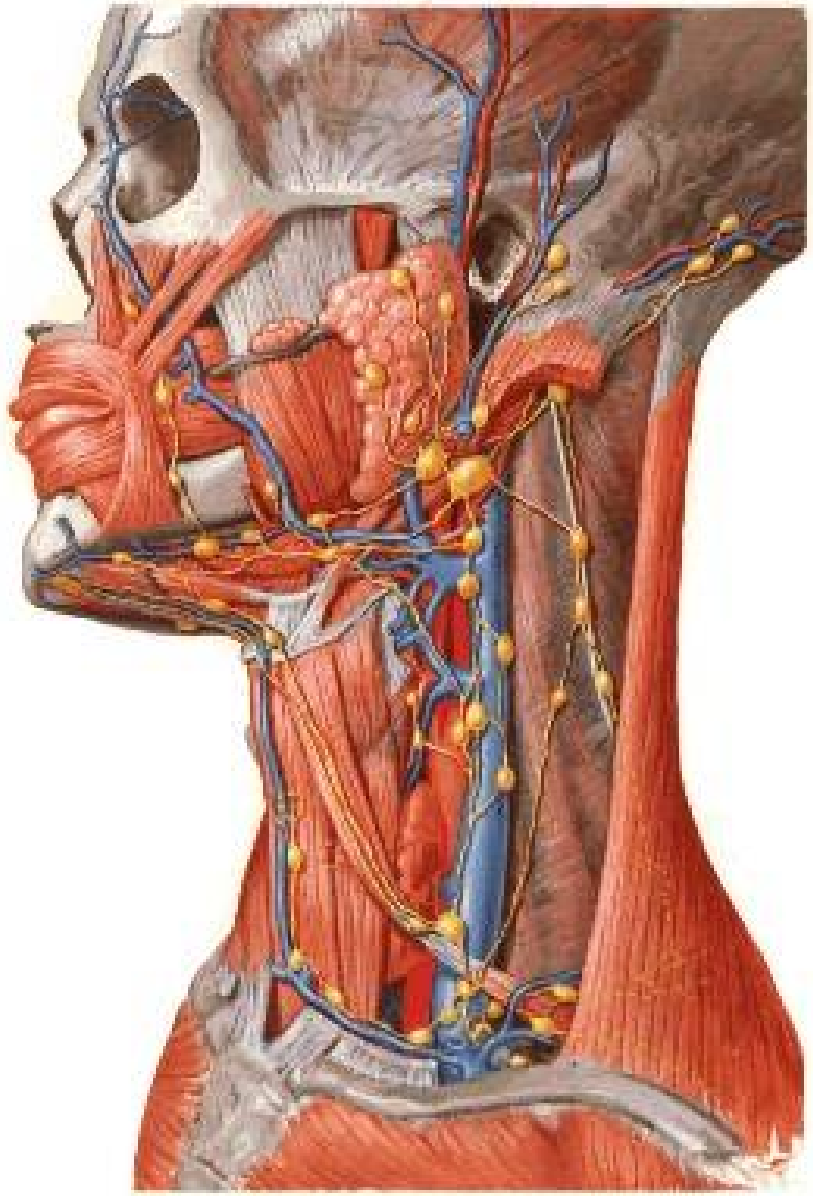

Lymphatic nodes of the head

occipital, retroauricular, parotid,
submental submandibular

Superficial cervical

-anteriores –along AJV
-laterales – along EJV
-posteriores – along n XI

Deep cervical- along IJV

Küttner´s-jugulodigastric
Kocher¨s- juguloomohyoid

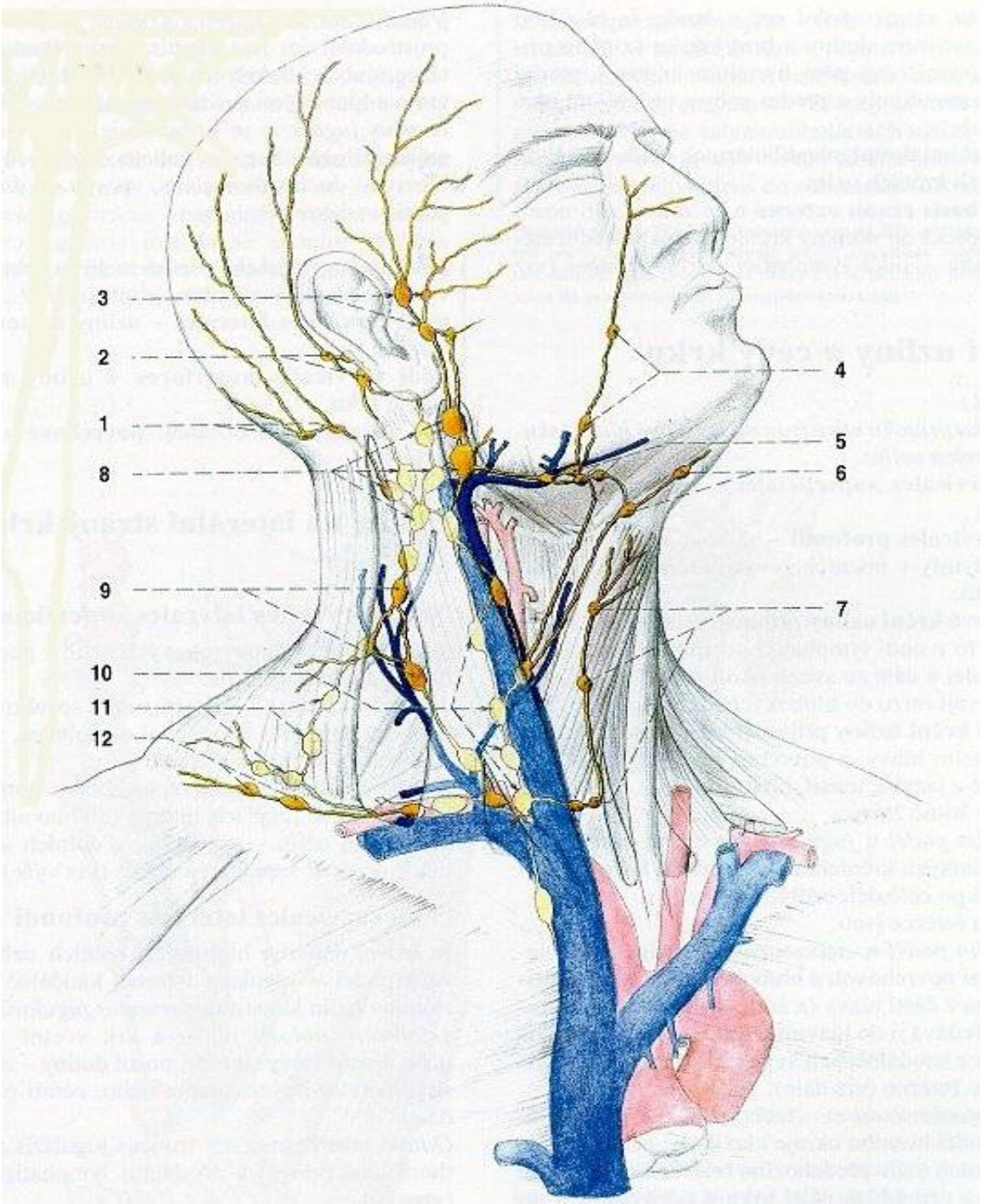
3
2
1
8
9
10
11
12
4
5
6
7

breast cancer

9% of female population

clinical examination: palpation, ultrasound, mammografy

importance of its lymphatic drainage !!!

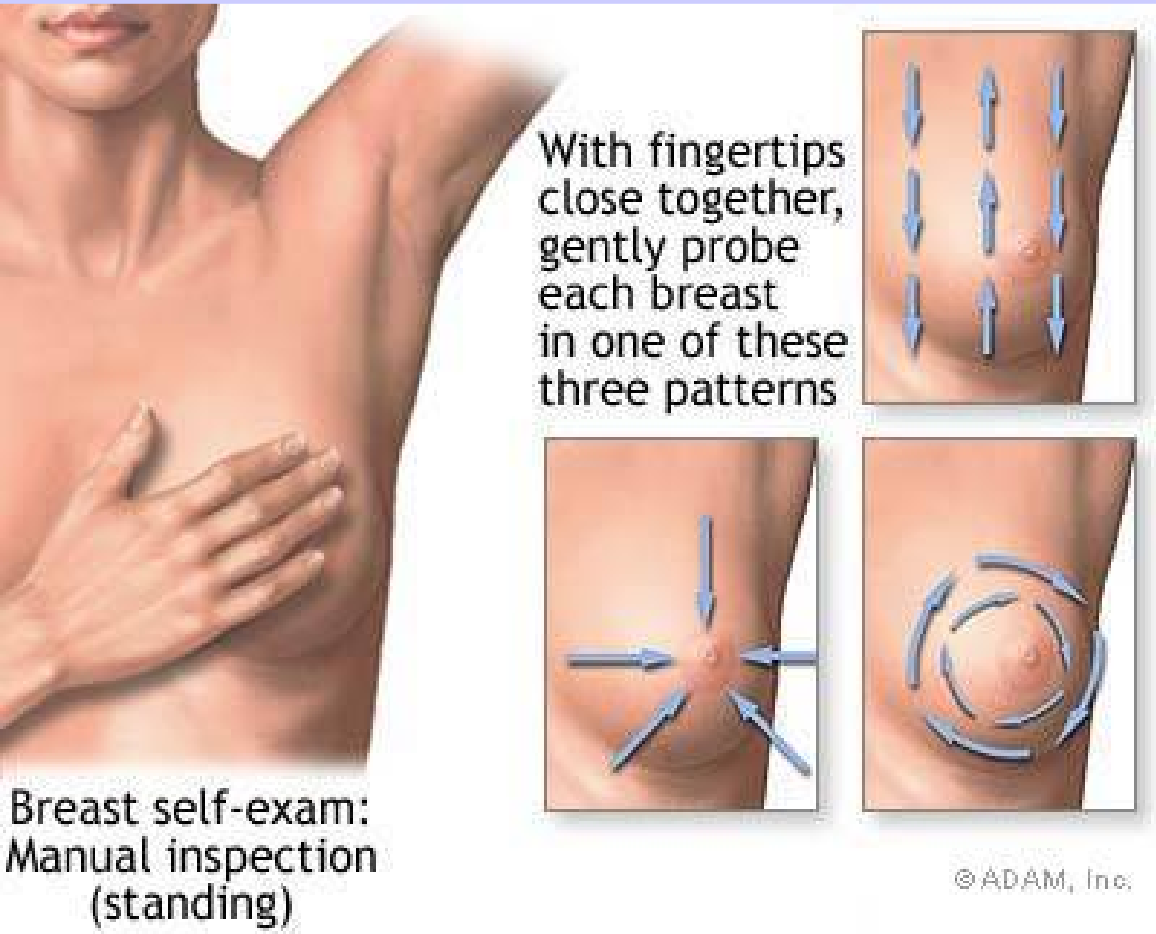

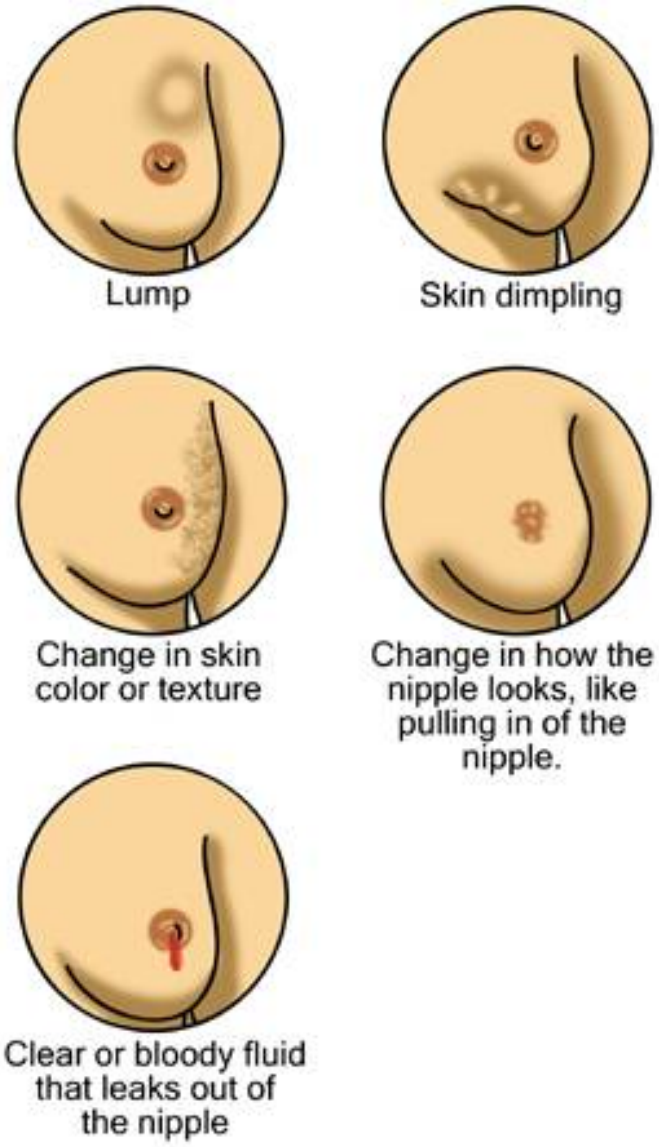

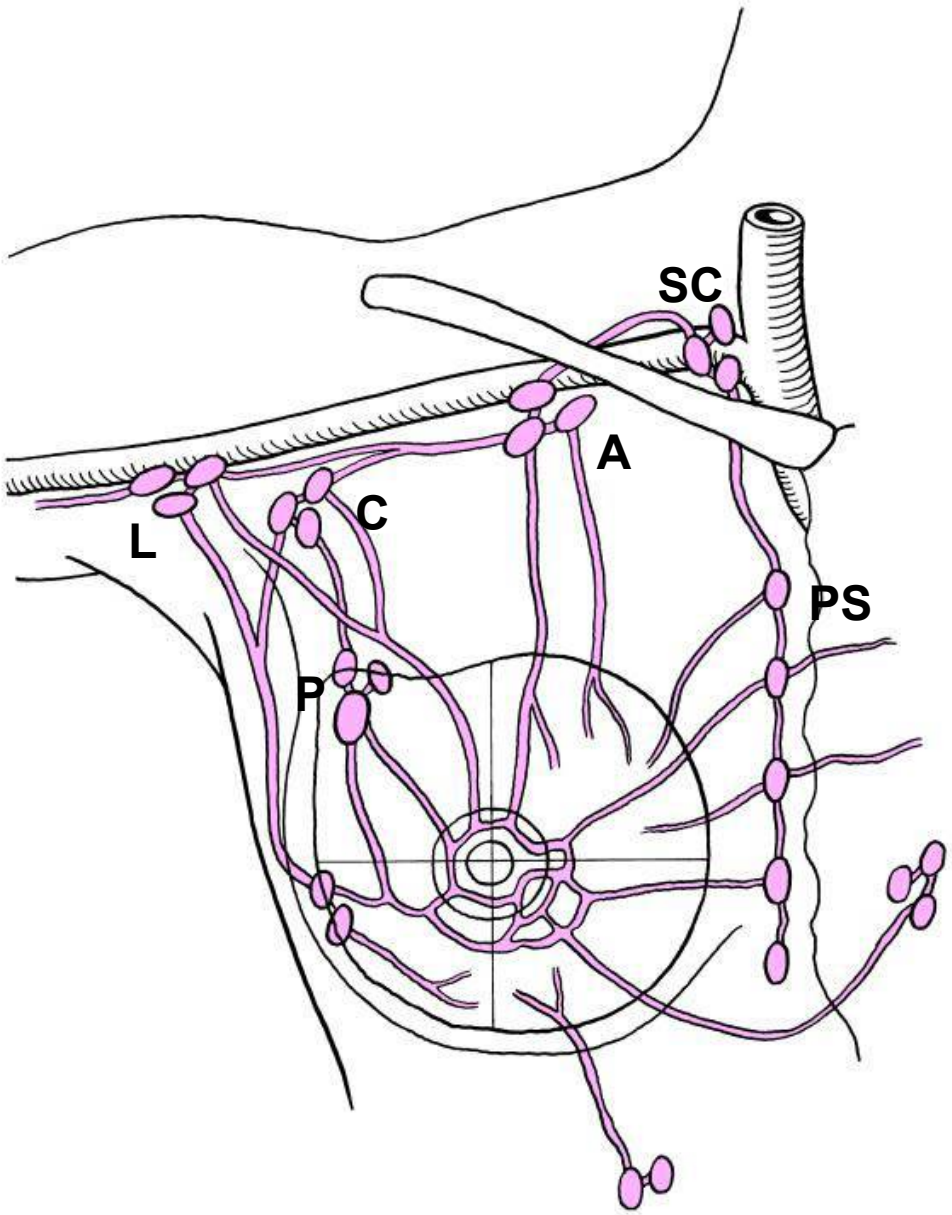

subareolar plexus,
circumareolar plexus

<u>axillary nodes</u>
pectoral (Sorgius)
subscapular
interpectoral
lateral
central
apical (infraclavicular)

<u>parasternal nodes</u>

<u>supraclavicular nodes</u>

<u>abdominal connections</u> (alongside epigastric vessels)

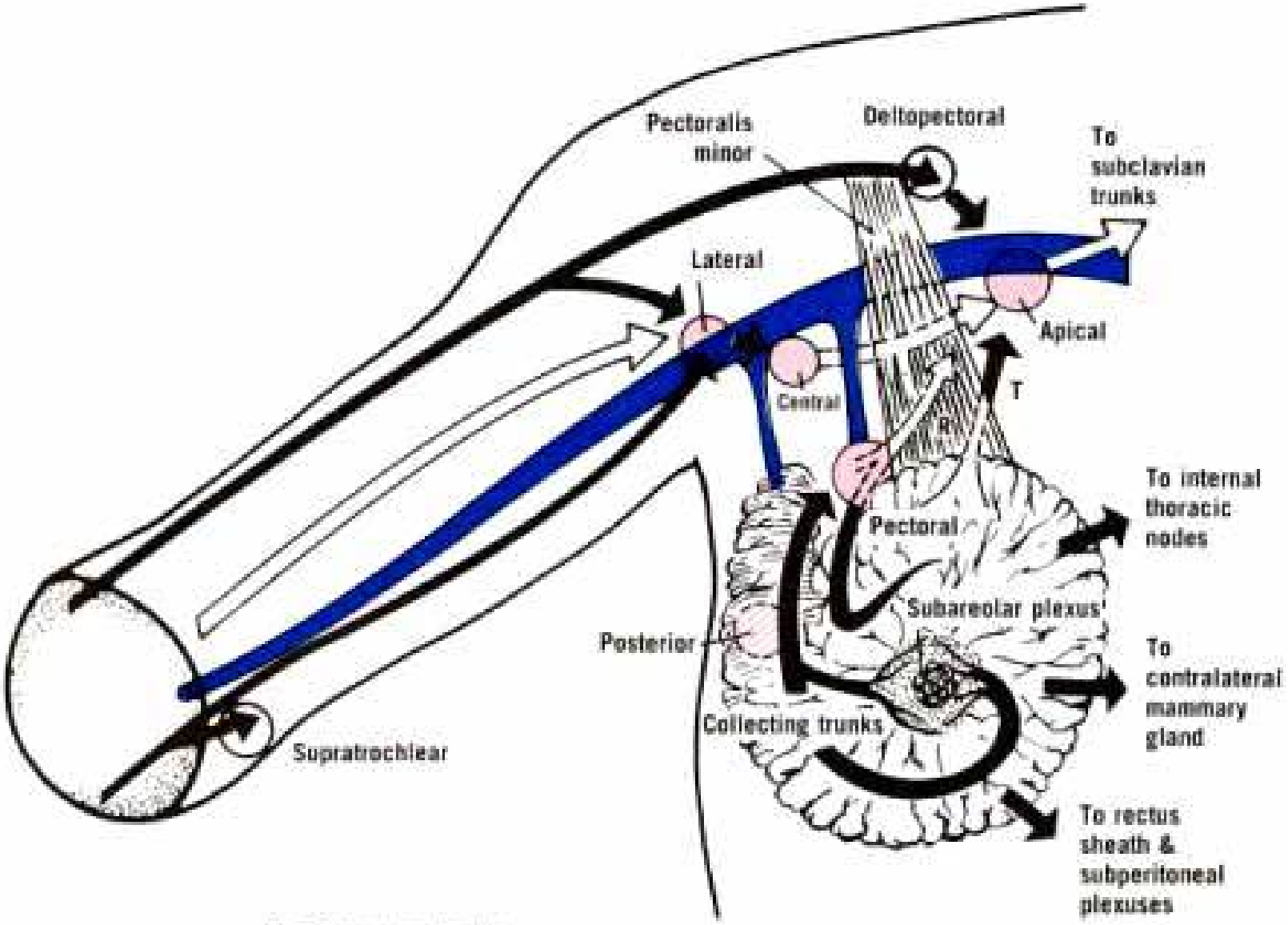

R: Retropectoral route
T: Transpectoral route

lymphoedema of upper limb after breast cancer surgery
(axillary lymphonodes removal is an unavoidale part of the procedure)

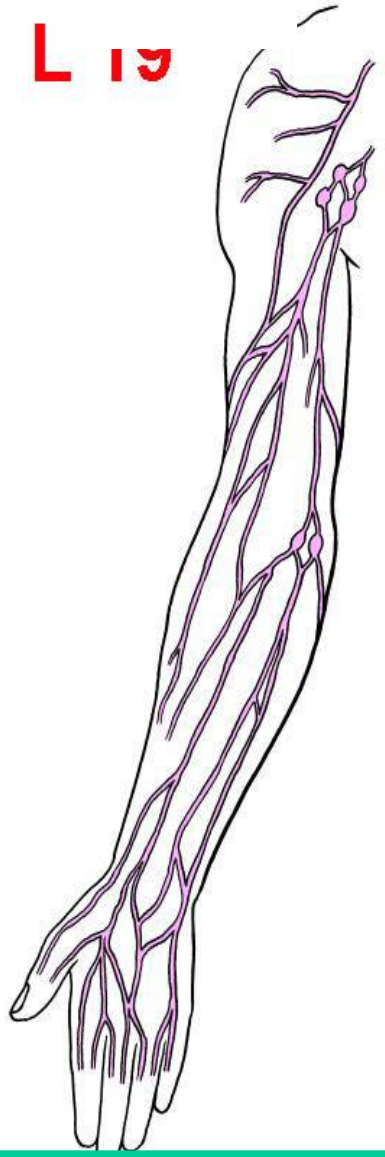

axillary nodes

lymphatic drainage of upper limb

lymphatic drainage of lower limb

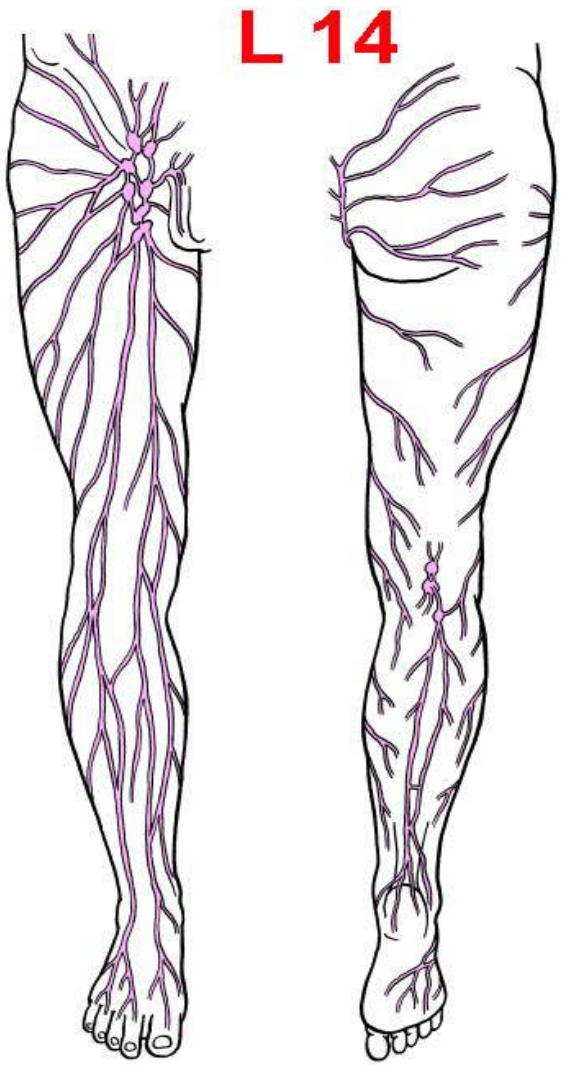

spf. et deep inguinal lymph. nodes
lower limb+ext. genital, lower third of vagina, anal part of rectum recti

lymphatic drainage of lungs

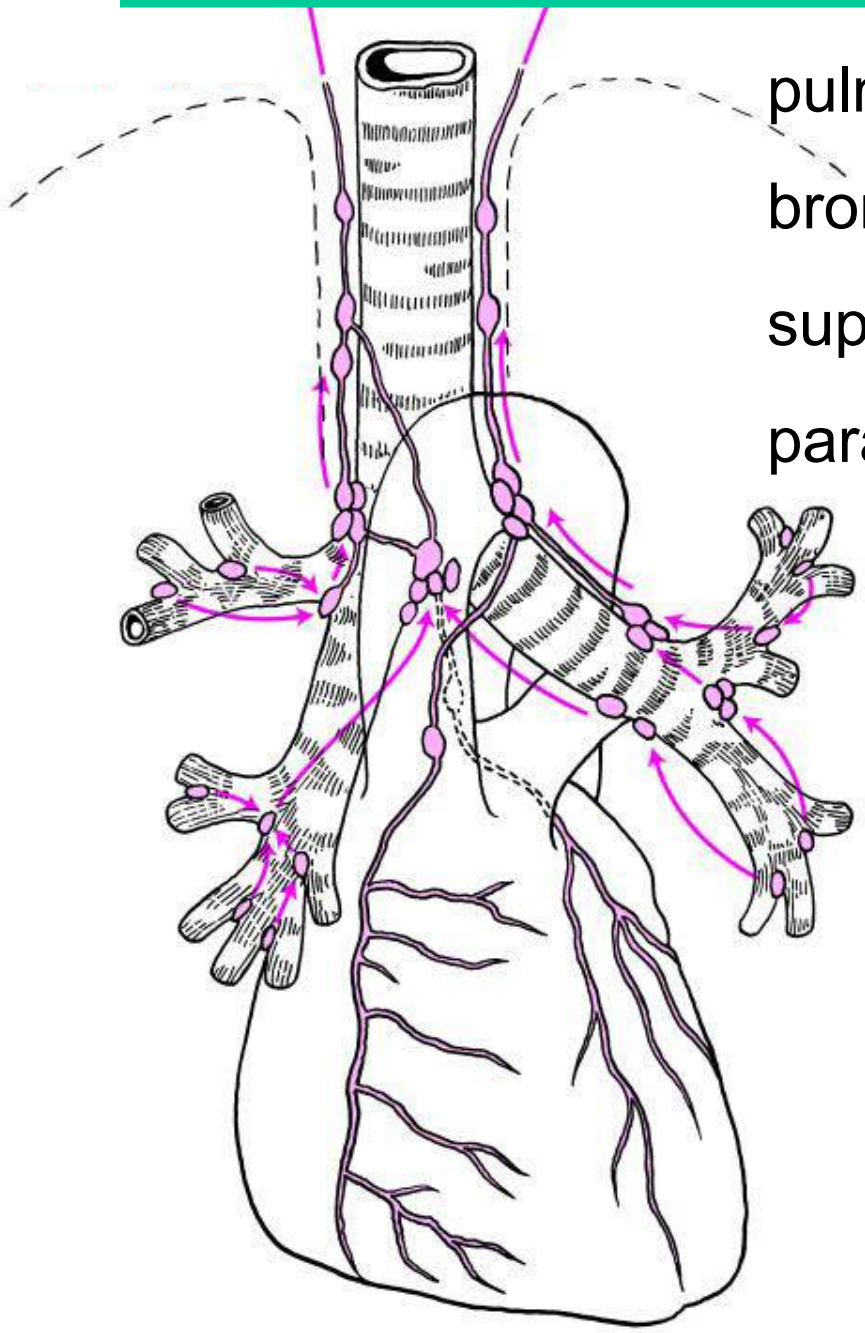

pulmonary nodes

bronchopulmonary nodes

sup. et inf. tracheobronchial nodes

paratracheal nodes

bronchomediastinal tr.

ant. mediastinal nodes
post mediastinal nodes

lymphatic drainage of GIT

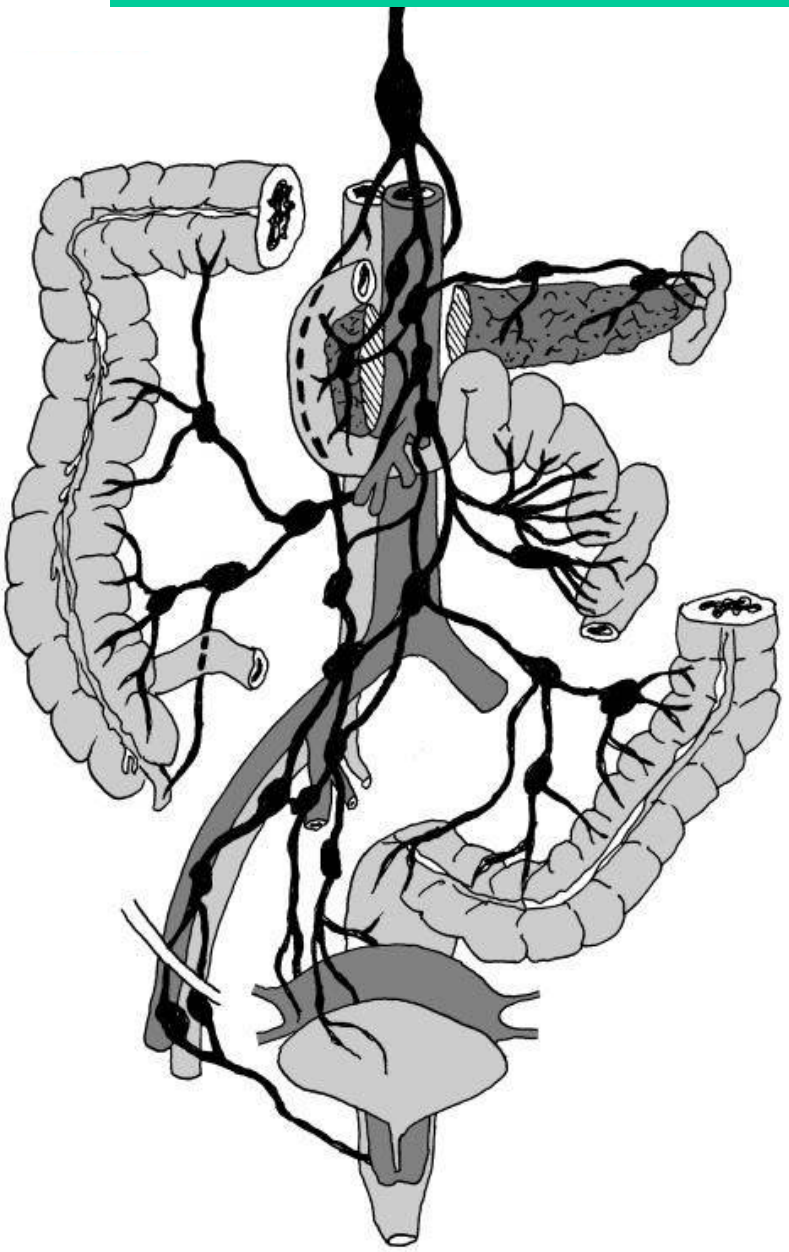

gastric, pyloric, **nodes**
pancreaticolienal
pancreaticoduodenal
hepatic
mesenteric
colic et paracolic
rectal et pararectal

lymphatic drainage of genitals

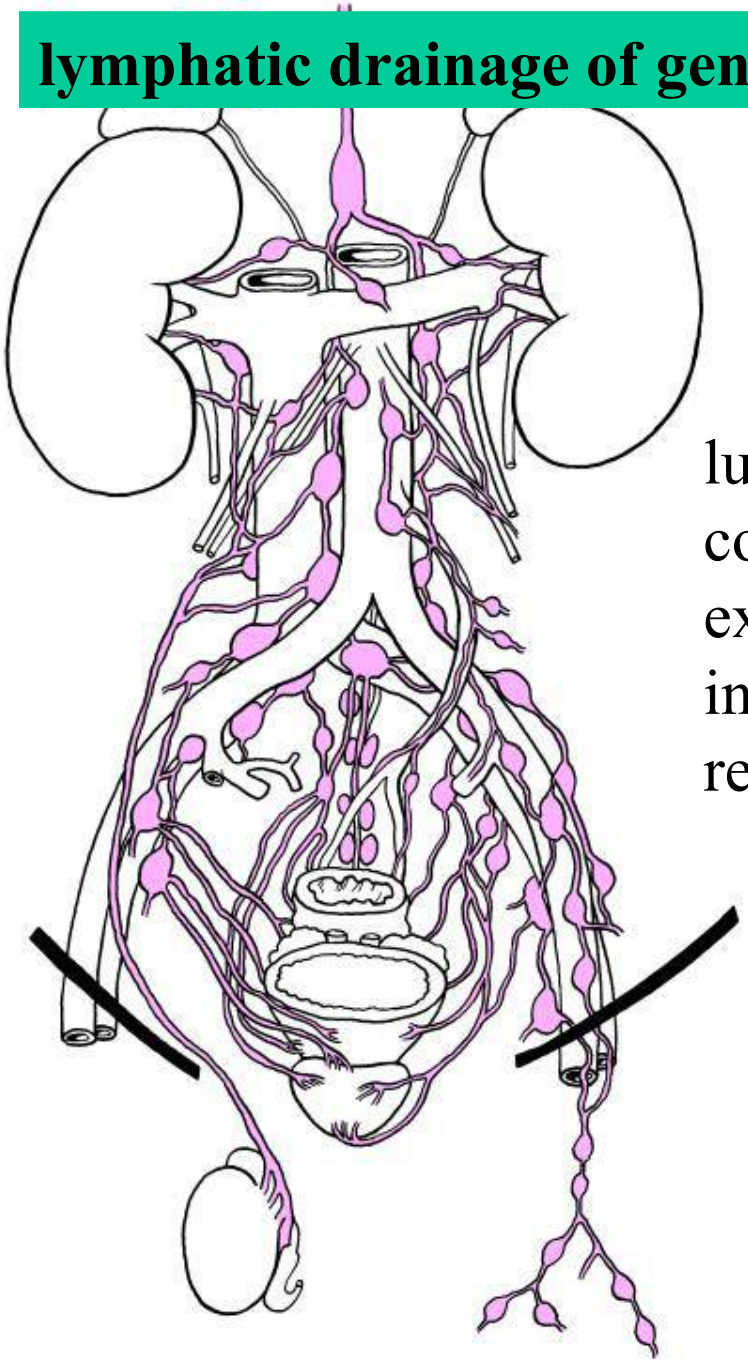

nodes

lumbar
comm. iliac
ext. iliac
int. iliac - parauterine (Bayer) / retroprostatic