Brain stem

Veronika Němcová

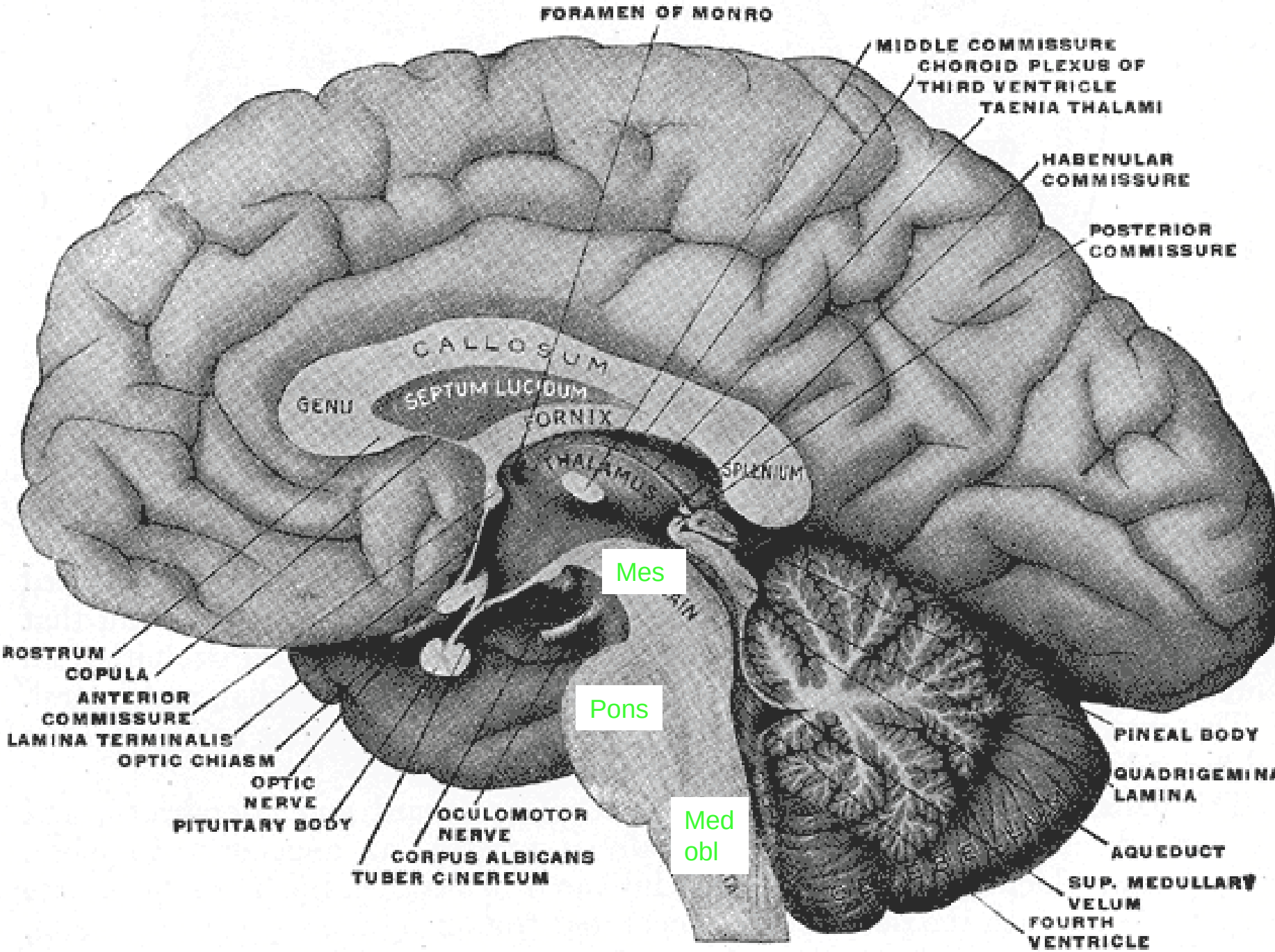
FORAMEN OF MONRO
MIDDLE COMMISSURE
CHOROID PLEXUS OF THIRD VENTRICLE
TAENIA THALAMI
HABENULAR COMMISSURE
POSTERIOR COMMISSURE
CALLOSUM
GENU
SEPTUM LUCIDUM
FORNIX
THALAMUS
SPLENIUM
Mes
Pons
Med obl
ROSTRUM
COPULA
ANTERIOR COMMISSURE
LAMINA TERMINALIS
OPTIC CHIASM
OPTIC NERVE
PITUITARY BODY
OCULOMOTOR NERVE
CORPUS ALBICANS
TUBER CINEREUM
PINEAL BODY
QUADRIGEMINA LAMINA
AQUEDUCT
SUP. MEDULLARY VELUM
FOURTH VENTRICLE

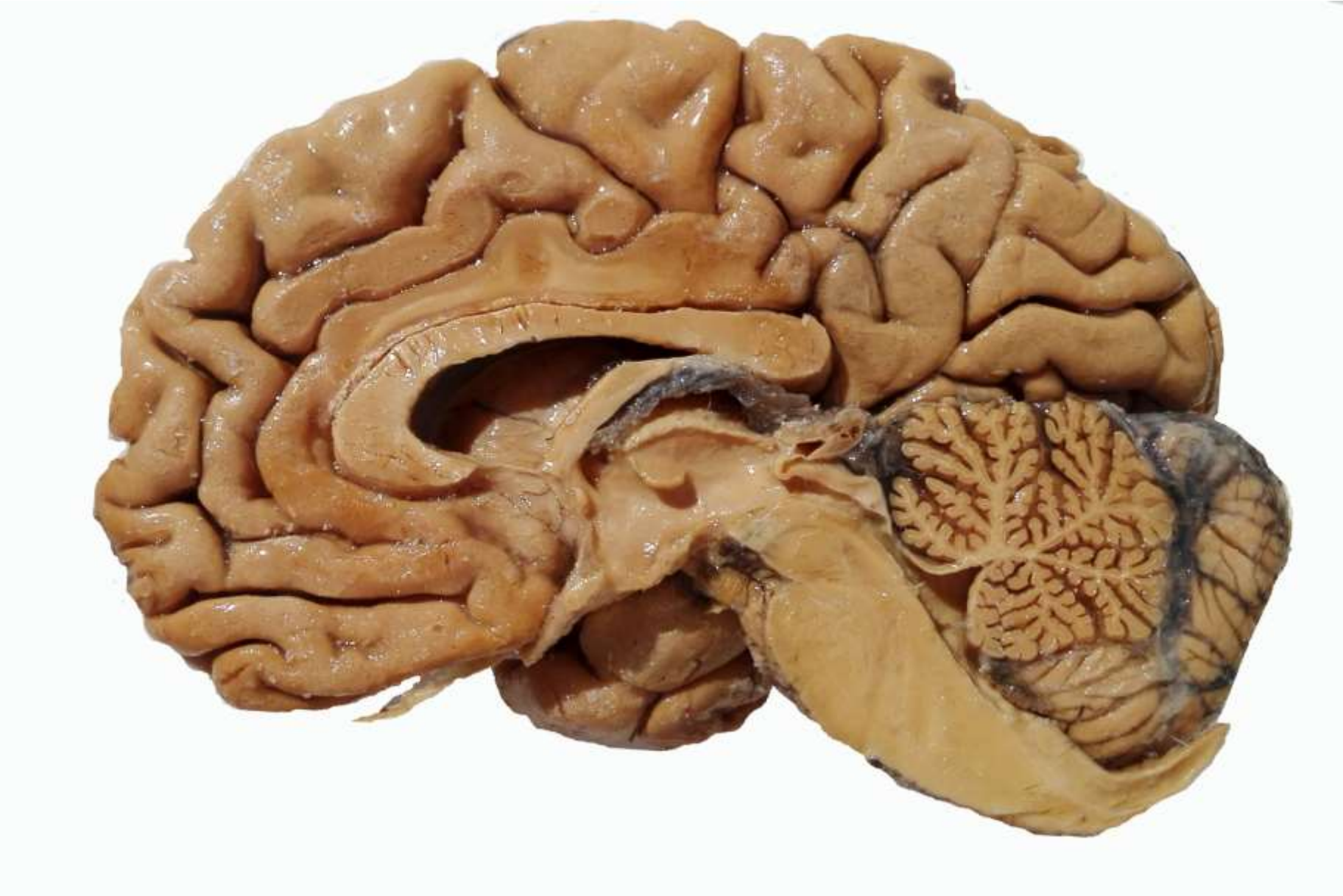

Brain stem ventral side – plastinated

1- a. basilaris
2-superior cerebellar art.
3- AICA
4-a. vertebralis

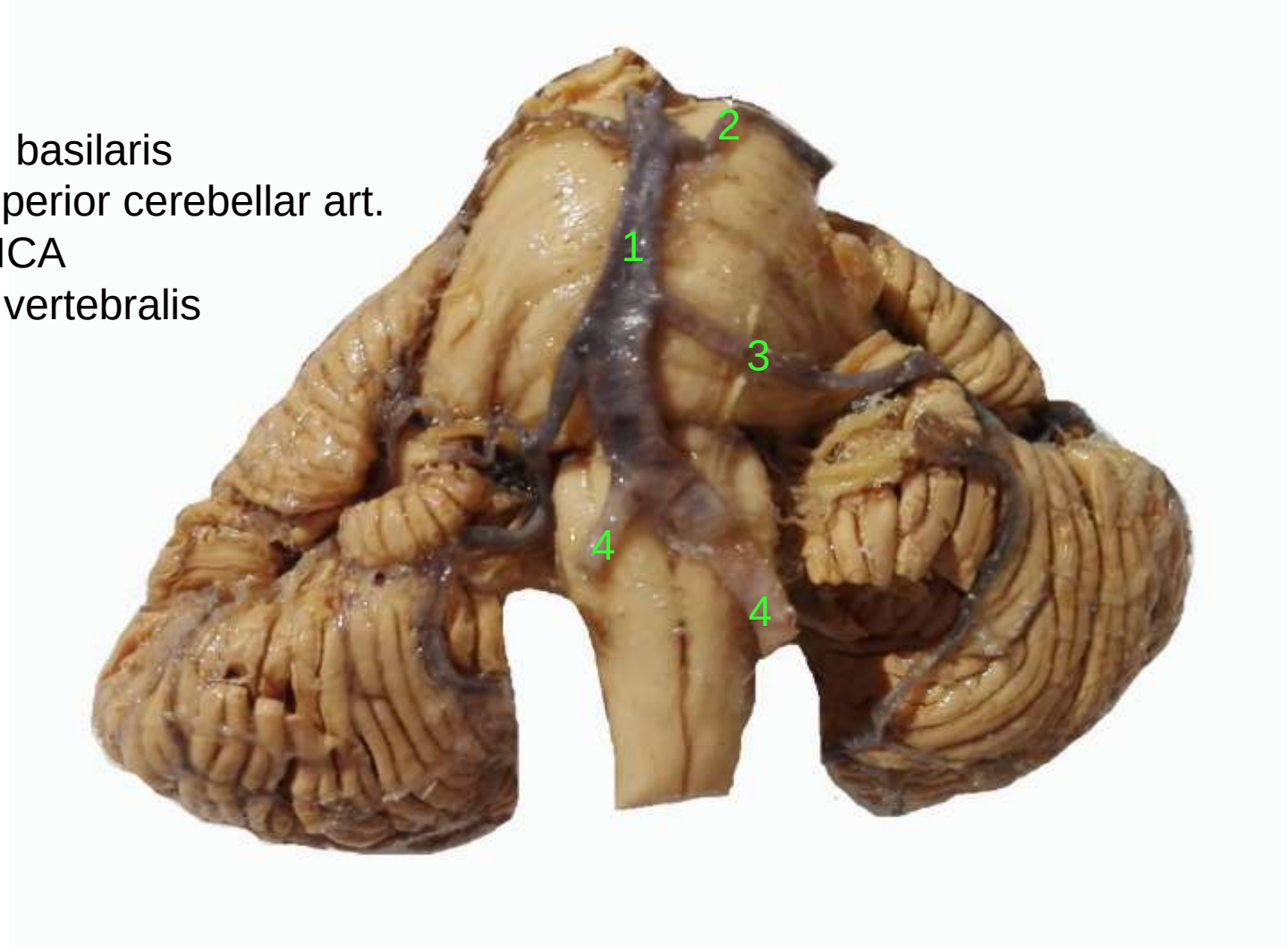

Ventral site of the brainstem cranial nerves

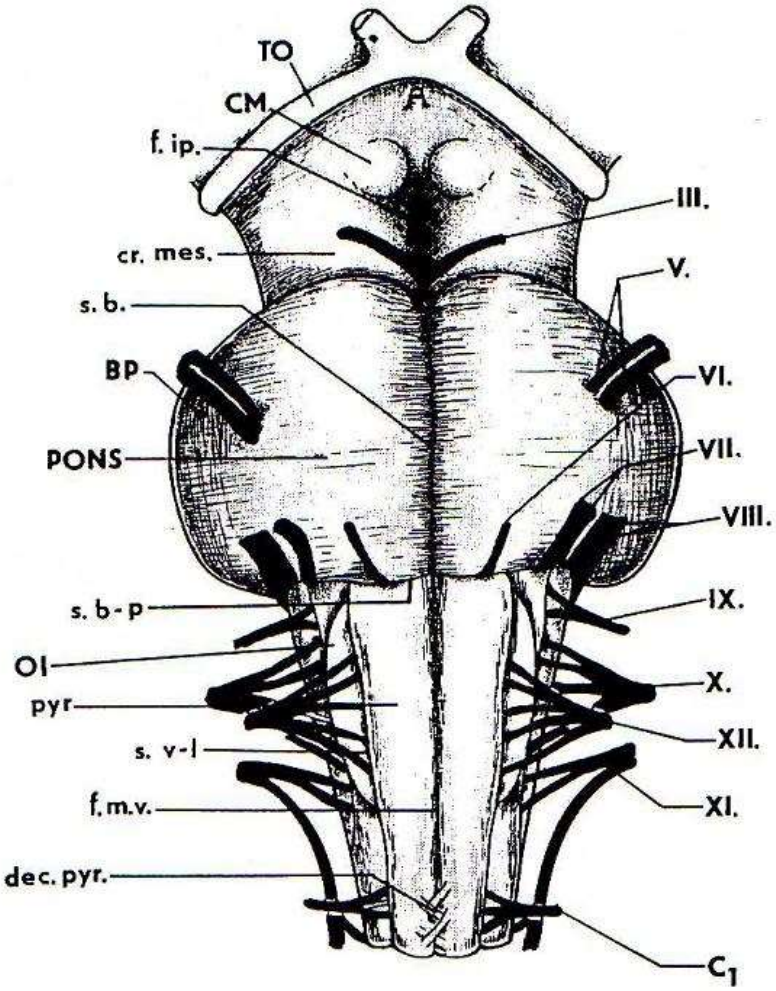

Ventral site of the brainstem cranial nerves

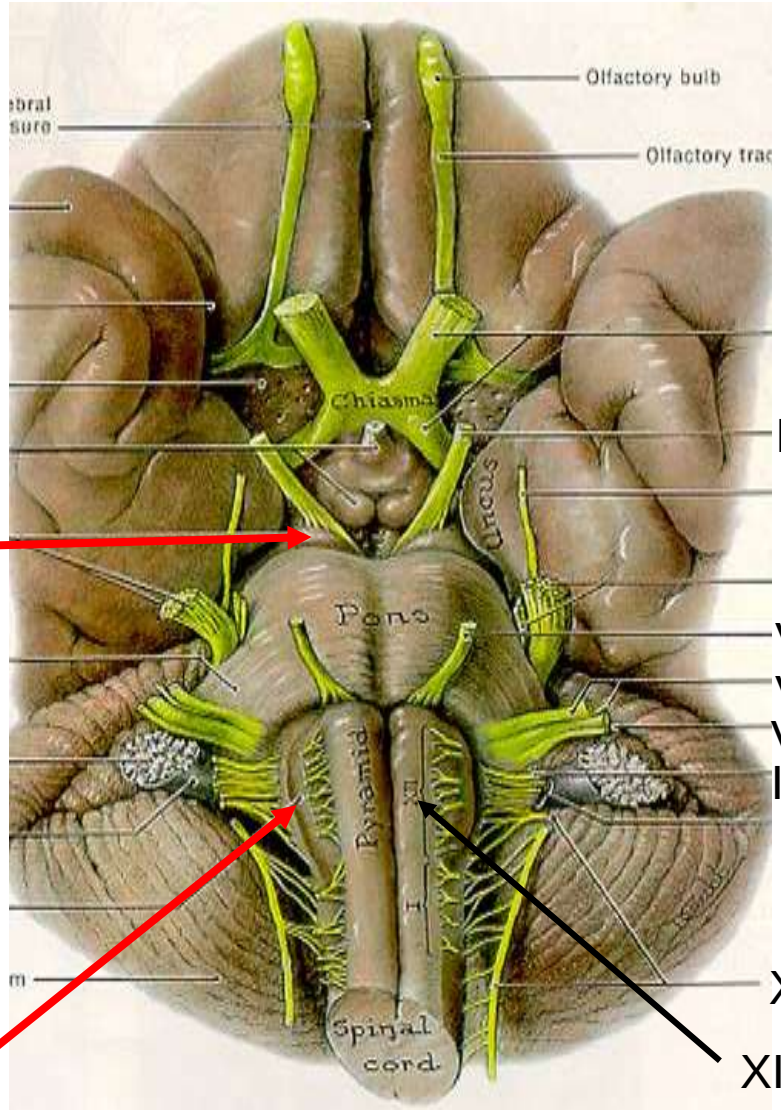

pedunculus cerebri

oliva inferior

Ventral site of the brainstem cranial nerves and arteries

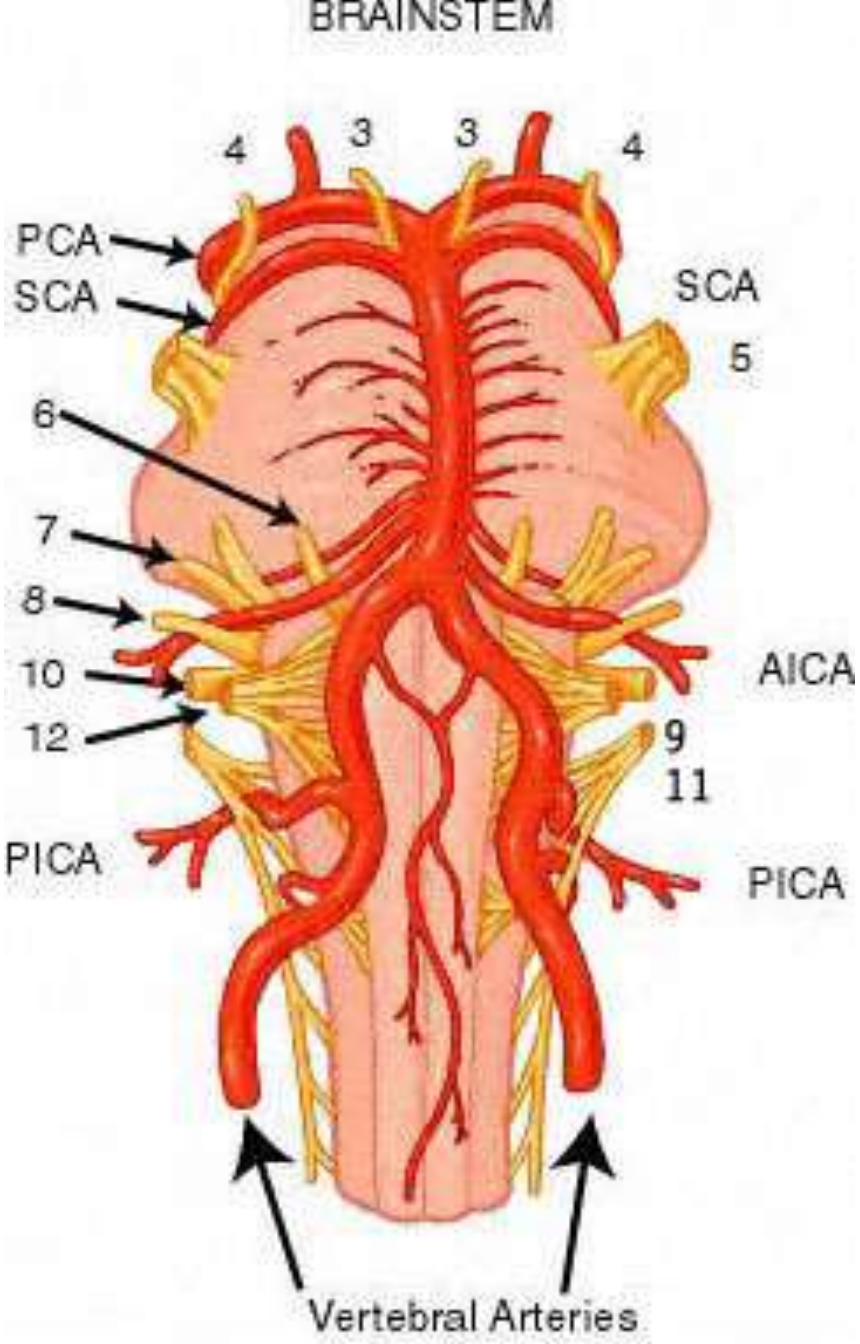

(c)Northestern University, 2001

Brainstem lateral aspect

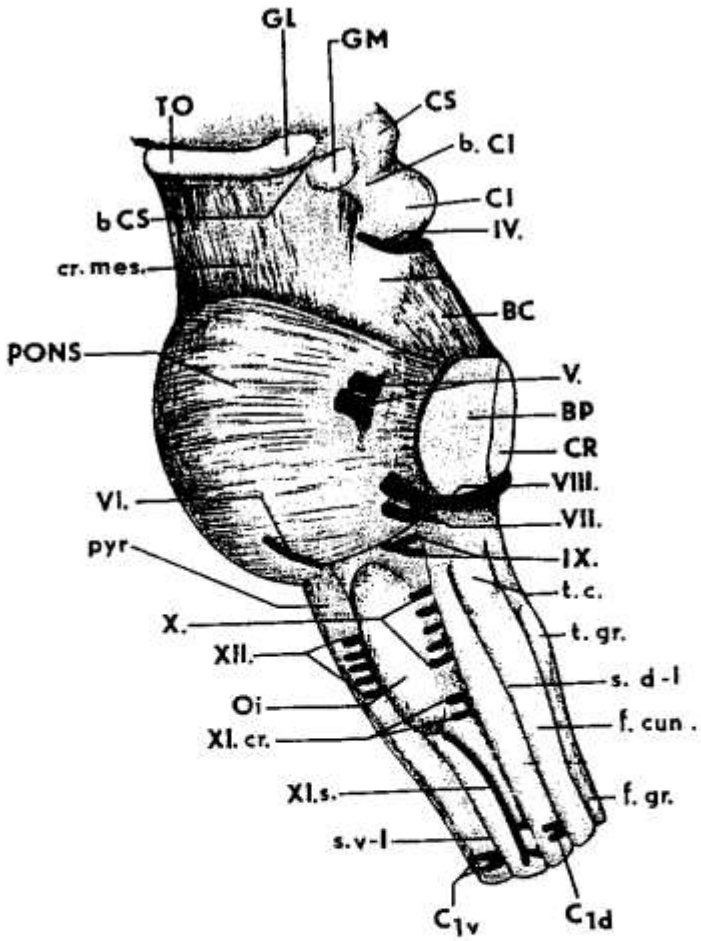

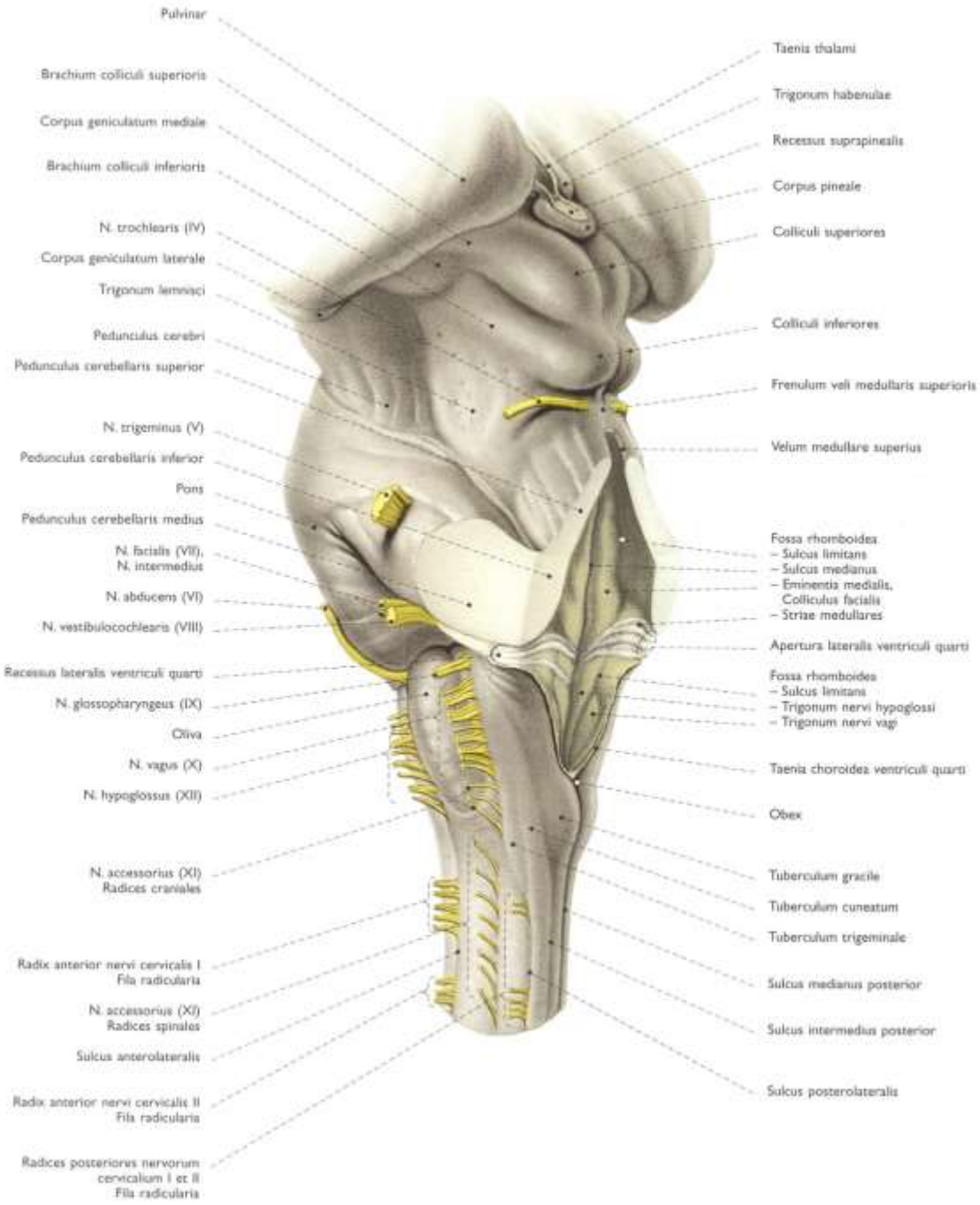
Pulvinar
Brachium colliculi superioris
Corpus geniculatum mediale
Brachium colliculi inferioris
N. trochlearis (IV)
Corpus geniculatum laterale
Trigonum lemniści
Pedunculus cerebri
Pedunculus cerebellaris superior
N. trigeminus (V)
Pedunculus cerebellaris inferior
Pons
Pedunculus cerebellaris medius
N. facialis (VII),
N. intermedius
N. abducens (VI)
N. vestibulocochlearis (VIII)
Recessus lateralis ventriculi quarti
N. glossopharyngeus (IX)
Oliva
N. vagus (X)
N. hypoglossus (XII)
N. accessorius (XI)
Radices craniales
Radix anterior nervi cervicalis I
Fila radicularia
N. accessorius (XI)
Radices spinales
Sulcus anterolateralis
Radix anterior nervi cervicalis II
Fila radicularia
Radices posteriores nervorum
cervicalium I et II
Fila radicularia
Taenia thalami
Trigonum habenulae
Recessus suprapinealis
Corpus pineale
Colliculi superiores
Colliculi inferiores
Frenulum veli medullaris superioris
Velum medullare superius
Fossa rhomboidea
– Sulcus limitans
– Sulcus medianus
– Eminentia medialis,
Colliculus facialis
– Striae medullares
Apertura lateralis ventriculi quarti
Fossa rhomboidea
– Sulcus limitans
– Trigonum nervi hypoglossi
– Trigonum nervi vagi
Taenia choroidea ventriculi quarti
Obex
Tuberculum gracile
Tuberculum cuneatum
Tuberculum trigeminale
Sulcus medianus posterior
Sulcus intermedius posterior
Sulcus posterolateralis

Sagittal section of the rostral part of the brain stem

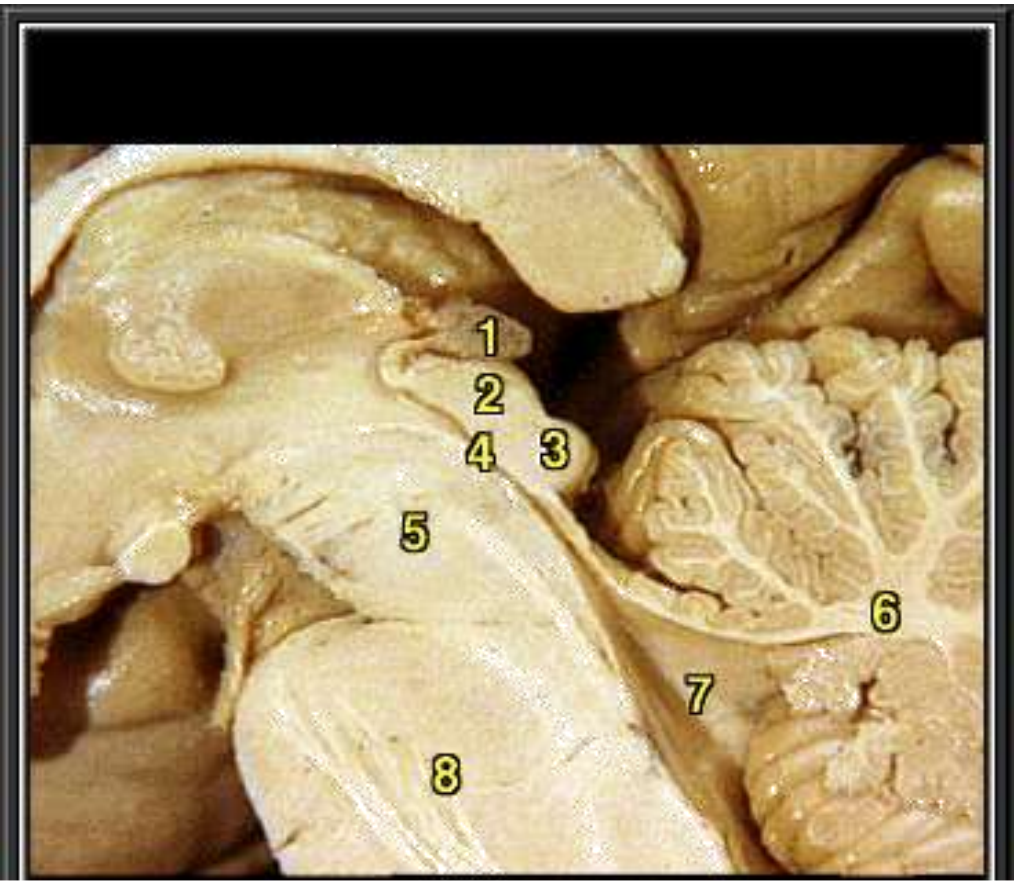

1-epiphysis -melatonine
2-colliculus superior –visual center
3-colliculus inferior- acoustic center
4-aquaeductus mesencephali
5-tegmentum mesencephali
6-cerebellum
7-ventriculus IV.
8-pons Varoli

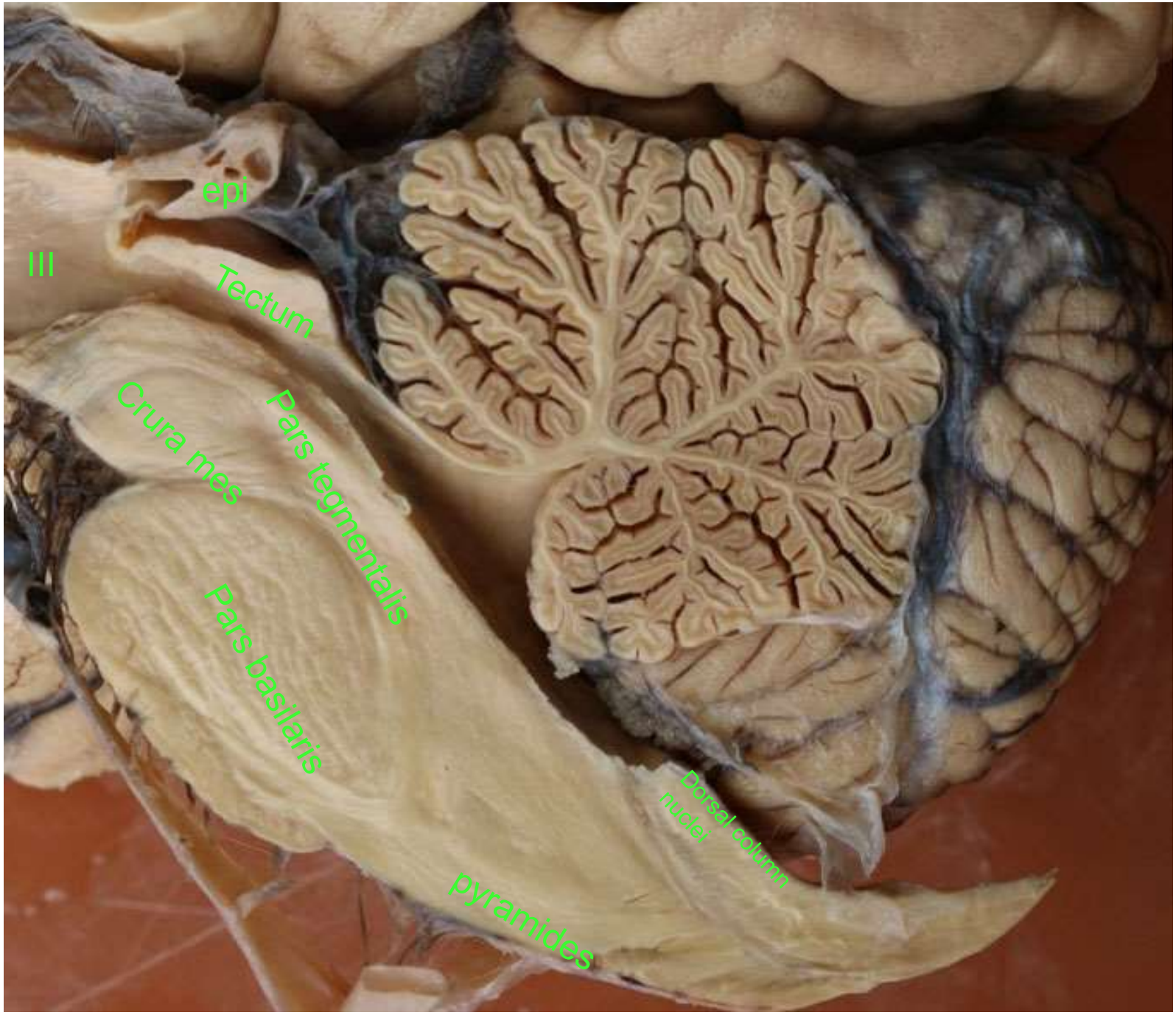
epi
III
Tectum
Crura mes
Pars tegmentalis
Pars basilaris
Dorsal column nuclei
pyramides

Sagittal section of brainstem- impregnation

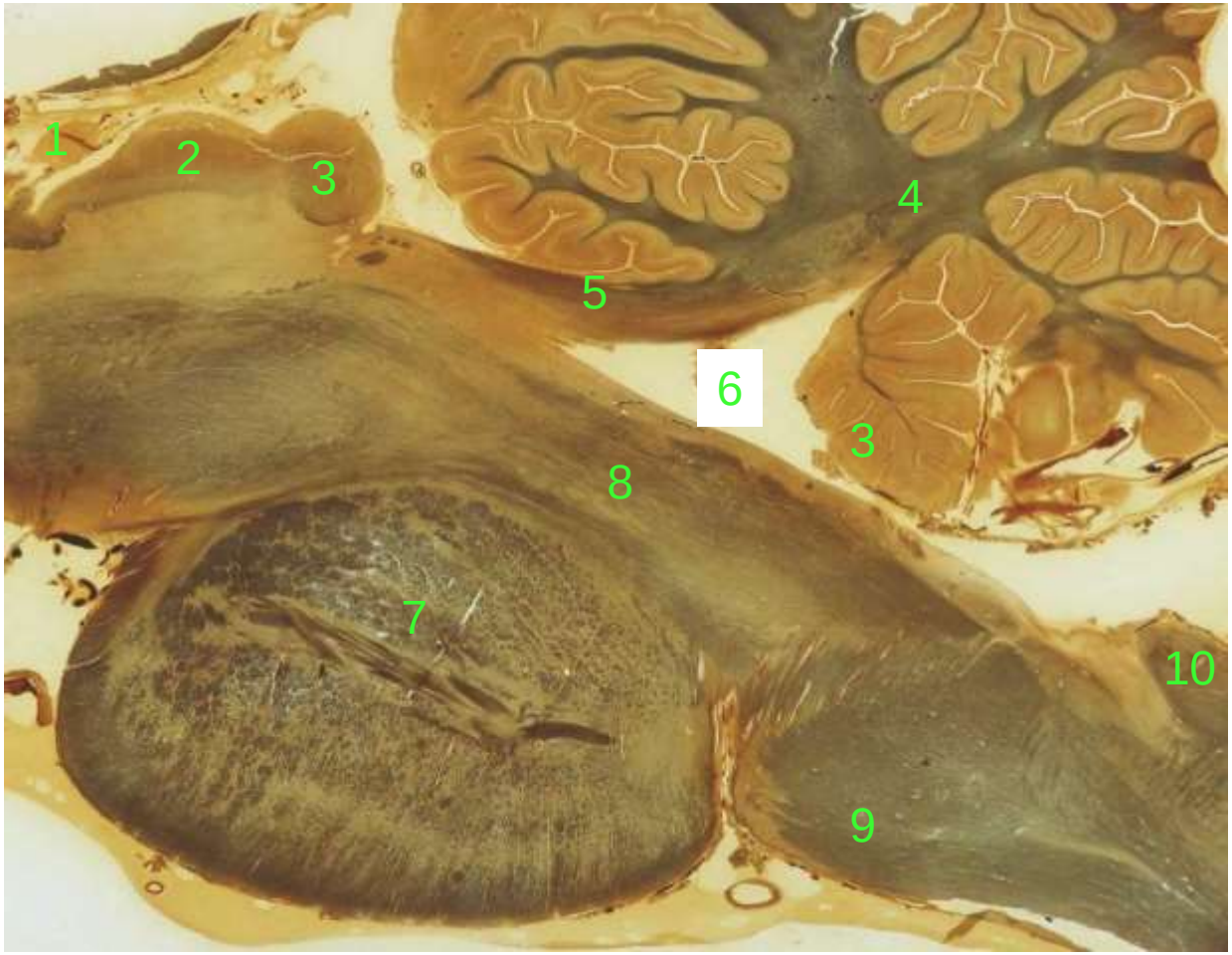

1-epiphysis -melatonin
2-colliculus superior -visual
3-colliculus inferior- acoustic
4-cerebellum
5-brachia conjunctiva
6-ventriculus IV.
7-pons Varoli – pars basilaris
8-tegmentum
9- pyramides
10- dorsal column nuclei

Rhomboid fossa – floor of the IV. ventricle

Brainstem – dorsal aspect

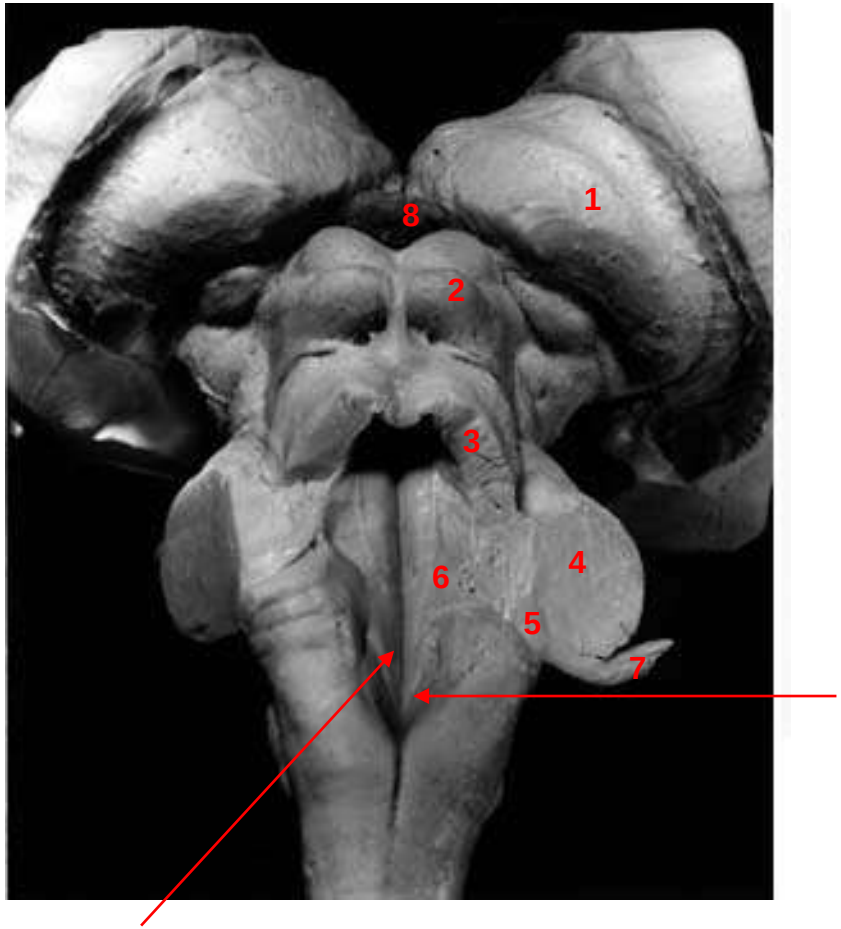

1- thalamus
2- tectum
3- brachia conjuntiva = PCS
4- brachia pontis = PCM
5- corpora restiformia = PCI
6- floor of the IV. ventricle
7- nervus vestibulocochlearis
8- epiphysis

▲ Nervi vagi

trigonum nervi hypoglossi

Brainstem – dorsal aspect

Lamina quadrigemina = tectum mesencephali = colliculi sup et inf

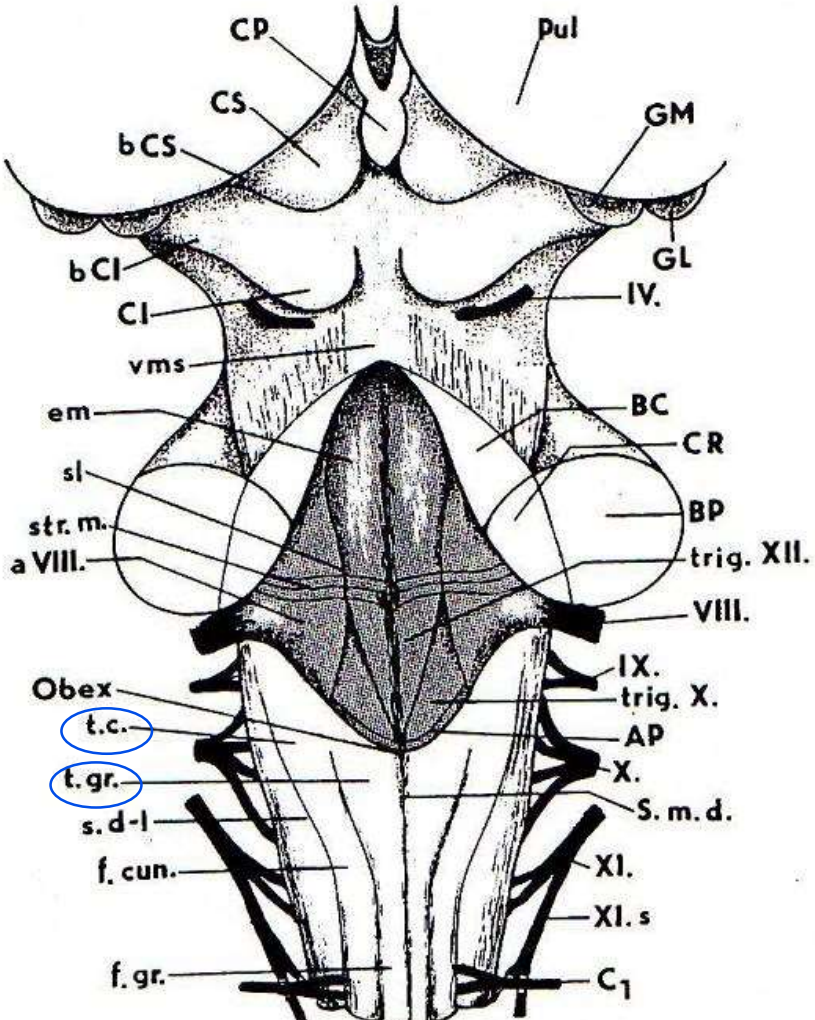

Cranial nerves nuclei on the floor of the IV. ventricle

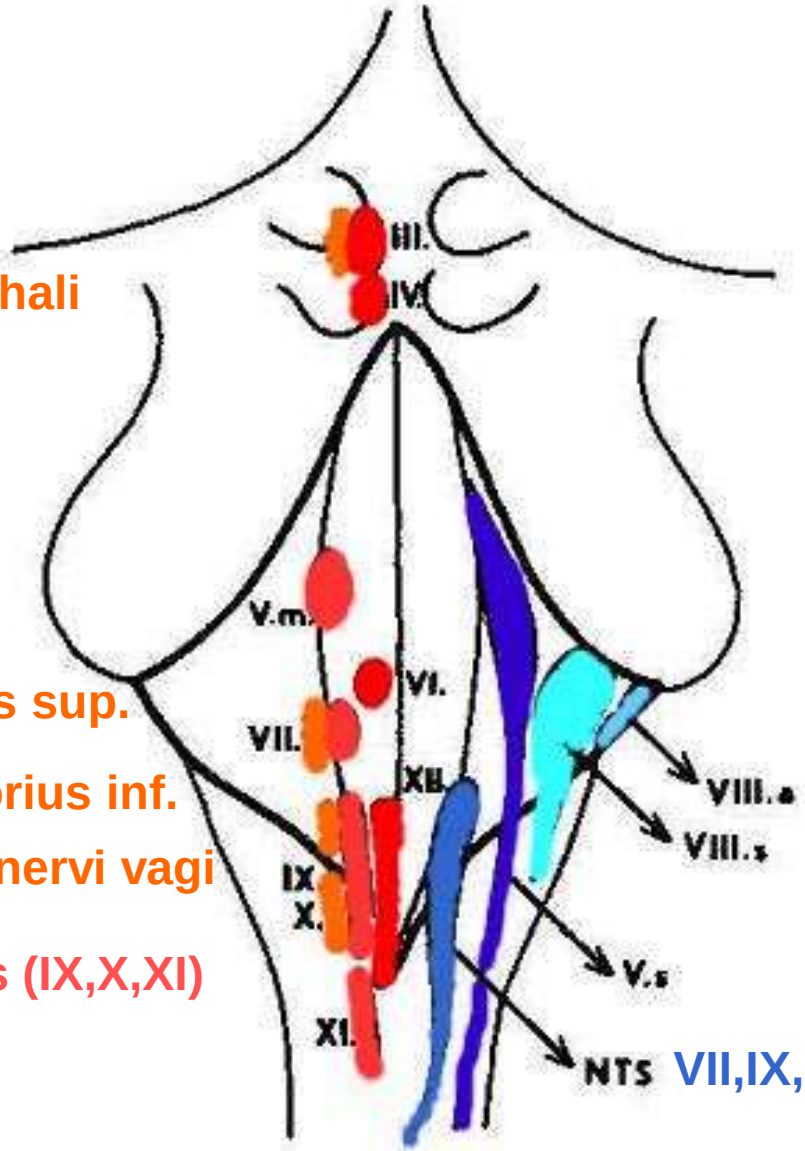

Ncl. Edinger-Westphali

Ncl. salivatorius sup.

Ncl. salivatorius inf.

Ncl. dorsalis nervi vagi

Ncl ambiquus (IX,X,XI)

Somatomotor
Visceromotor
Viscerosensory
Somatosensory
Sensory

VII,IX,X:

SM, VM, VS a SS nuclei of cranial nerves on the floor of the IV. ventricle

NUCLIE ORIGINIS
NUCLEI TERMINATIONIS

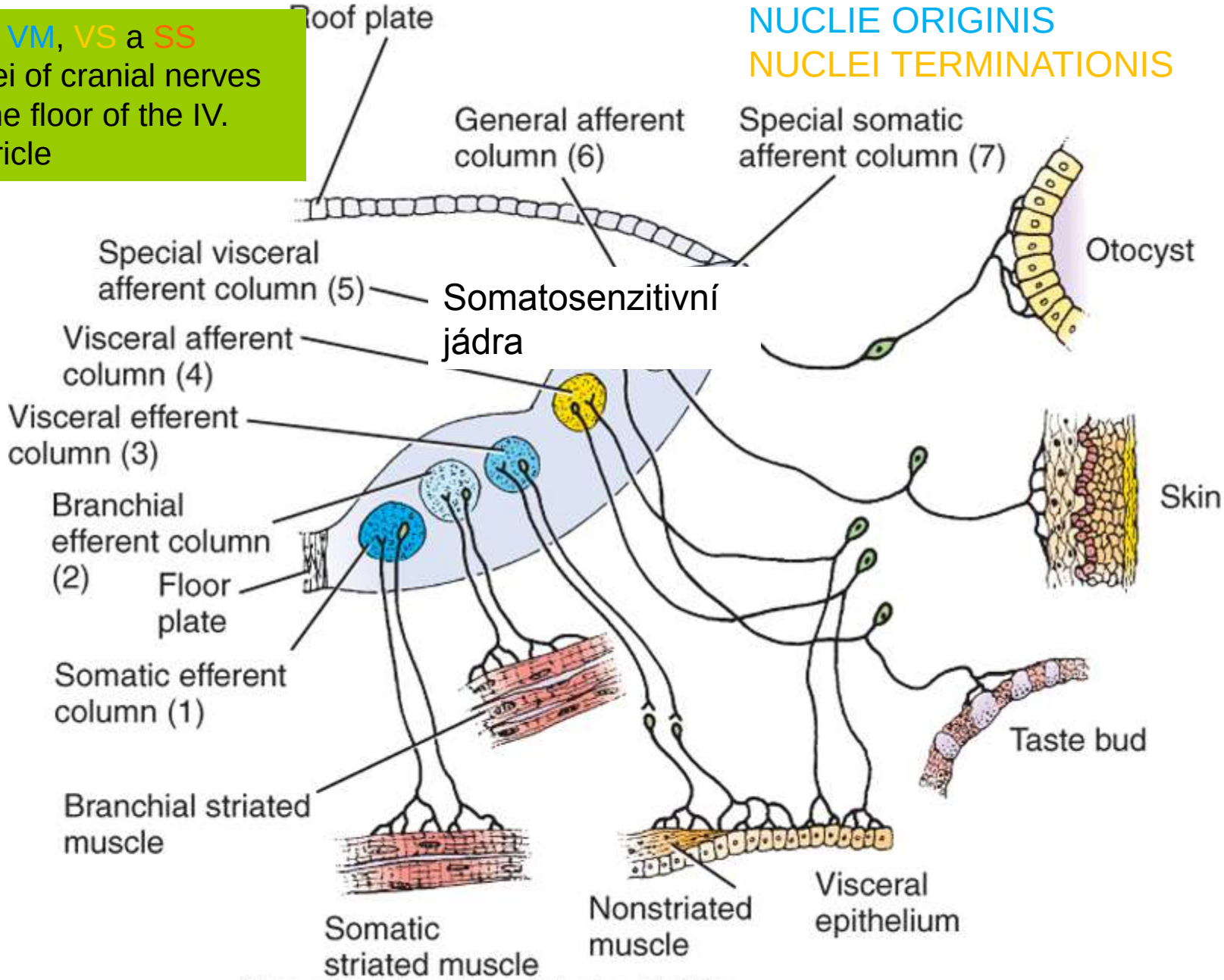

Schoenwolf et al: Larsen's Human Embryology, 4th Edition.
Copyright © 2008 by Churchill Livingstone, an imprint of Elsevier, Inc. All rights reserved

Reticular formation

(Moruzzi and Magoun, 1949)

brain stem grey matter without cranial nerve nuclei and nuclei of various functional systems (e.g. acoustic, eye movement coordination, motor)

1) Medial system large cell nuclei, long connections
2) Lateral systém small cell nuclei , connections to the medial system
3) Rapheal systém, in the midline , serotonine
4) Precerebellar nuclei (ncl. olivaris inferior, ncl. tegmenti pontis Bechtěrevi)
5) Chemical systems: A1-10, B1-9, Ch1-6

   glutamate, aspartate, GABA, peptids, NO

Scheme of the RF intrinstic connections

mesencephalon

Pons Varoli

Medulla oblongata

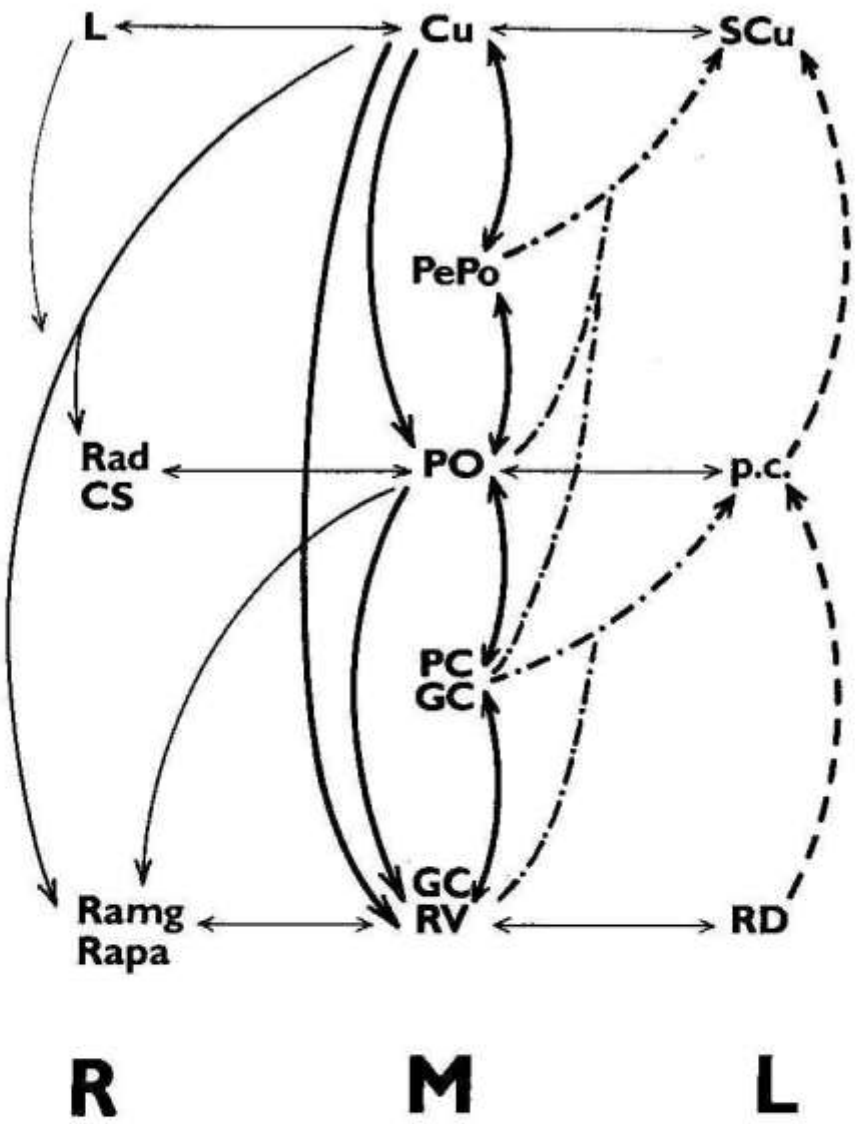

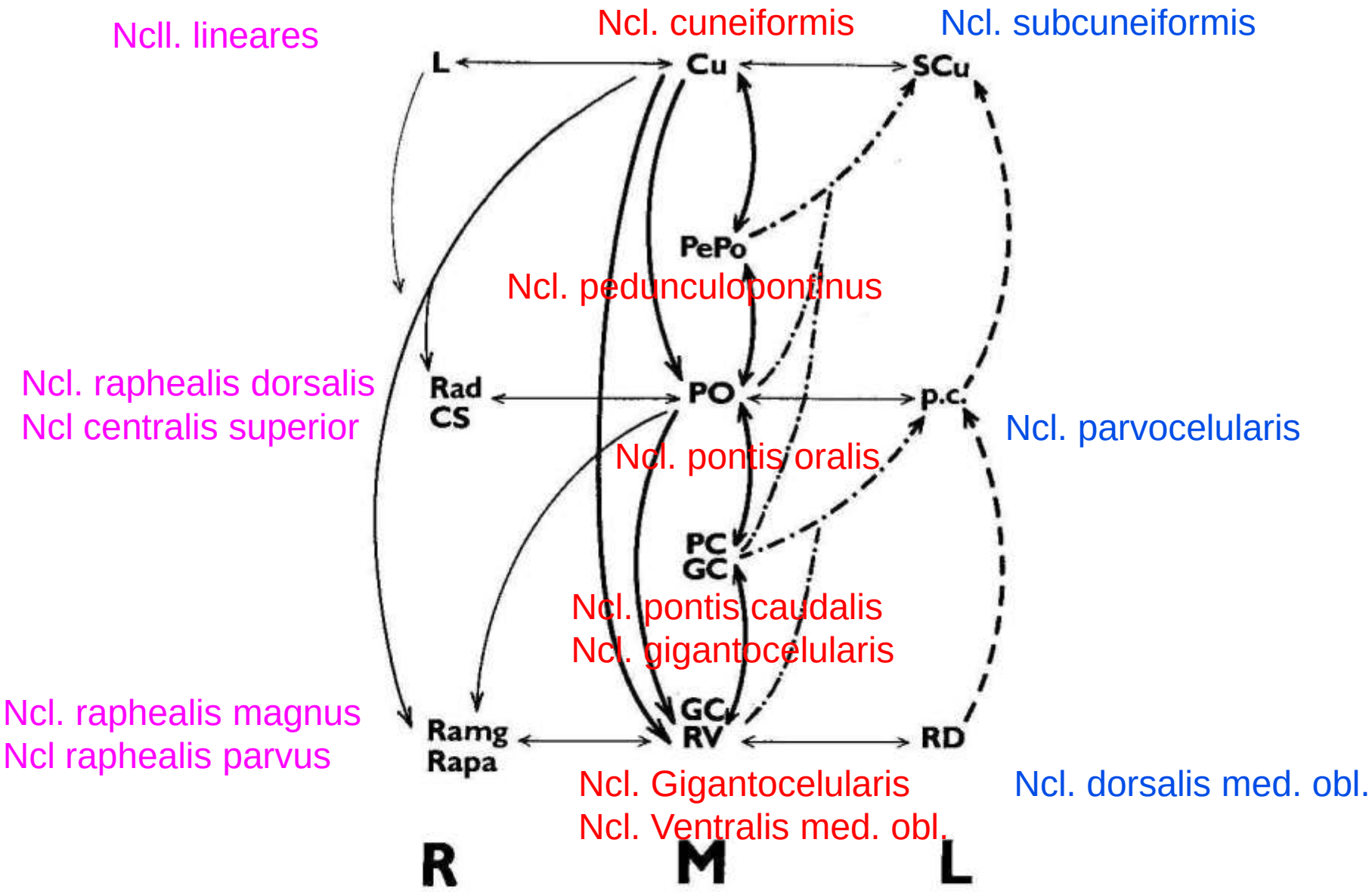
Ncll. lineares
Ncl. cuneiformis
Ncl. subcuneiformis
L
Cu
SCu
PePo
Ncl. pedunculopontinus
Ncl. raphealis dorsalis
Ncl centralis superior
Rad
CS
PO
p.c.
Ncl. parvocelularis
Ncl. pontis oralis
PC
GC
Ncl. pontis caudalis
Ncl. gigantocelularis
Ncl. raphealis magnus
Ncl raphealis parvus
Ramg
Rapa
GC
RV
RD
Ncl. Gigantocelularis
Ncl. Ventralis med. obl.
Ncl. dorsalis med. obl.
R
M
L

RF connections

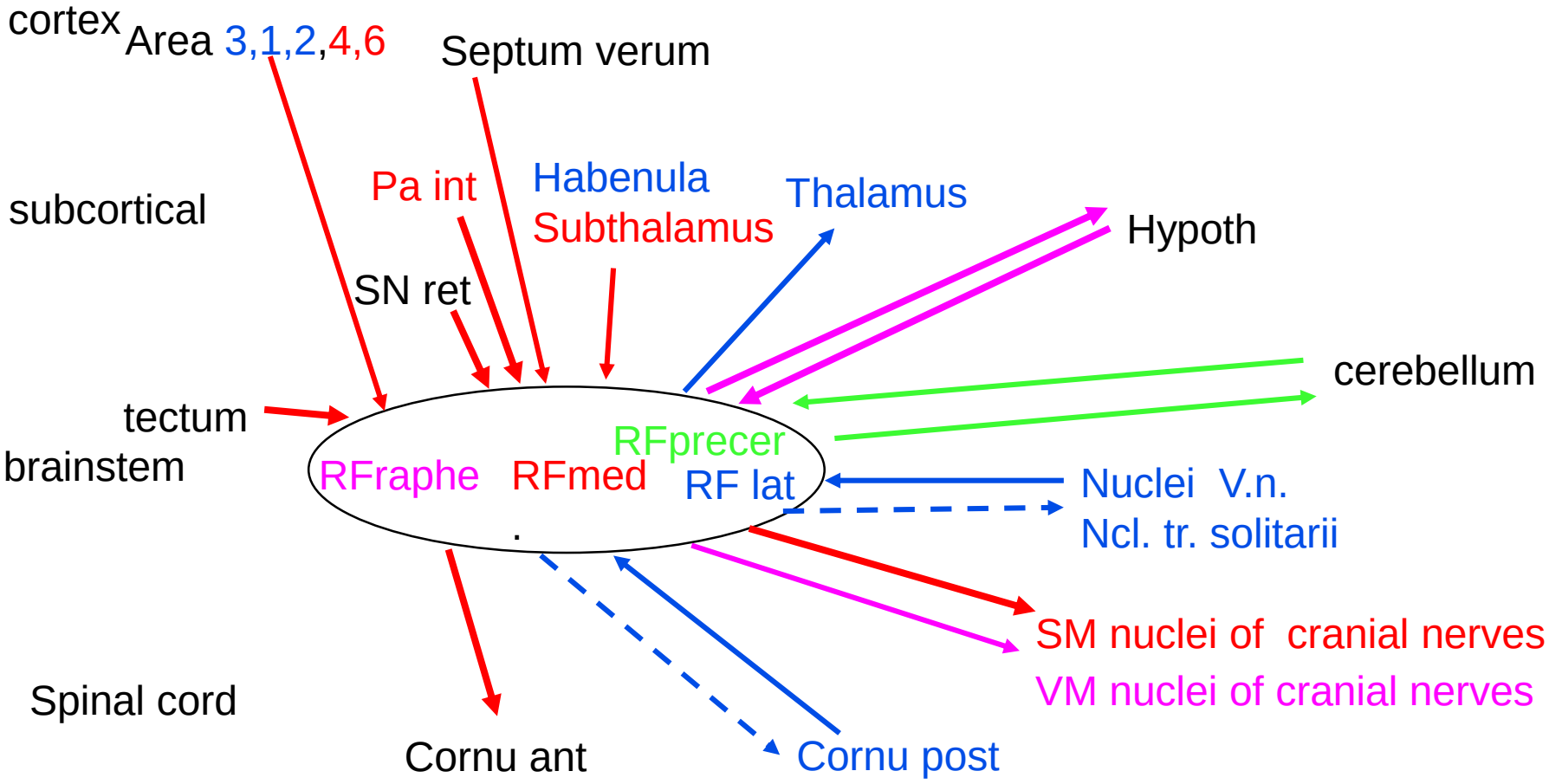

RF connections– afferents and efferents + branches of sensory and motor tracts

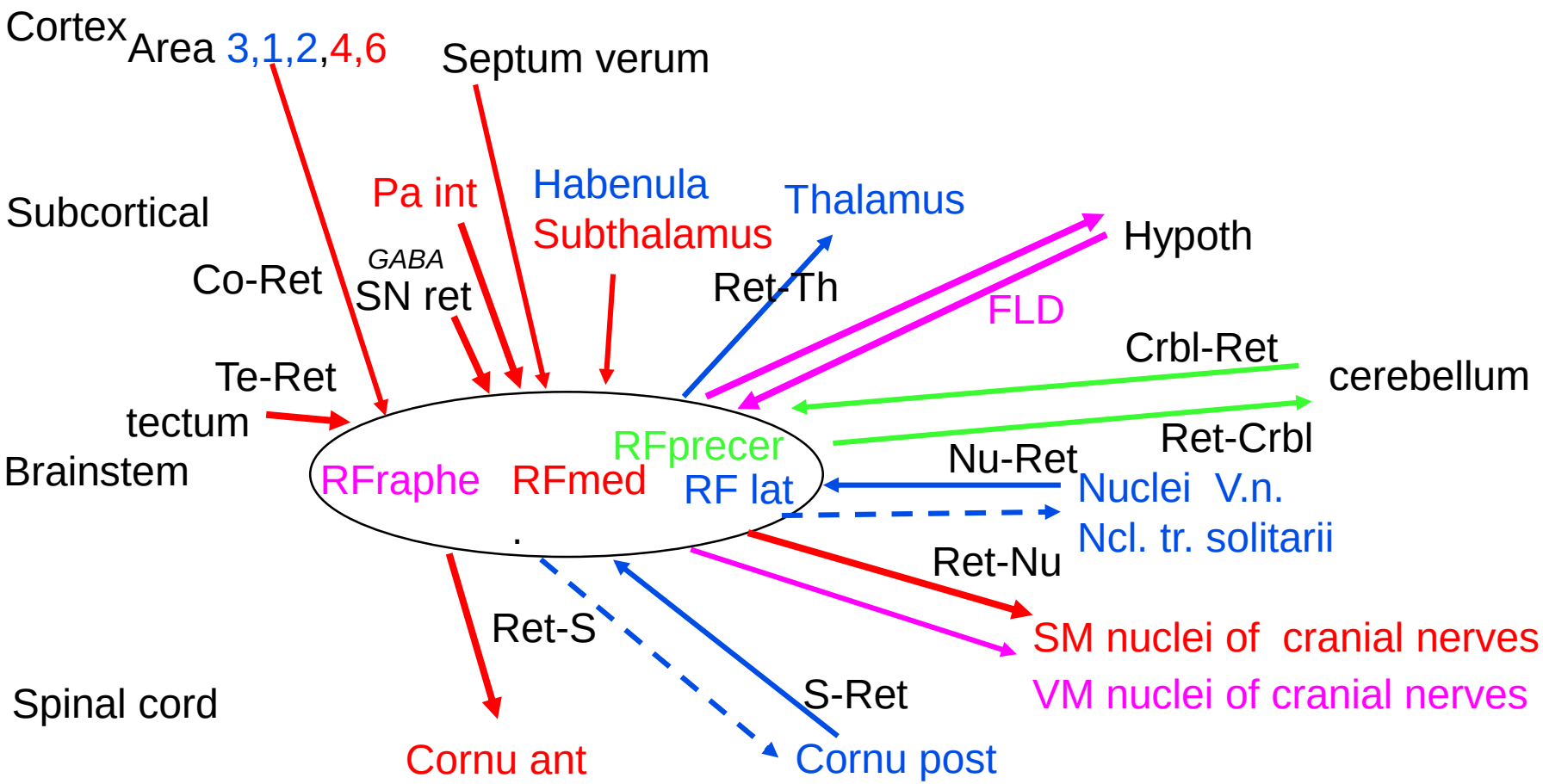

Some functions of RF nuclei

- Inspiration center – ncl. gigantocellularis ventral part
- Exspiration center – ncl. paragigantocellularis dorsalis
- Pneumotaxic center – ncl. pontis oralis
- Vasomotor center – ncl. ventralis med. obl.,
- Heart rate center – dorsal part of ncl. ventralis med obl and ncl. dorsalis med. obl.
- Ascendending activation system – mainly „chemical systems“- ncl.laterodorsalis a pedunculopontinus, locus coeruleus
- Inhibitory system – caudally, ventral part of ncl. gigantocelularis, ncl. ventralis med. obl.

Micture center in rostral dorsolateral tegmentum

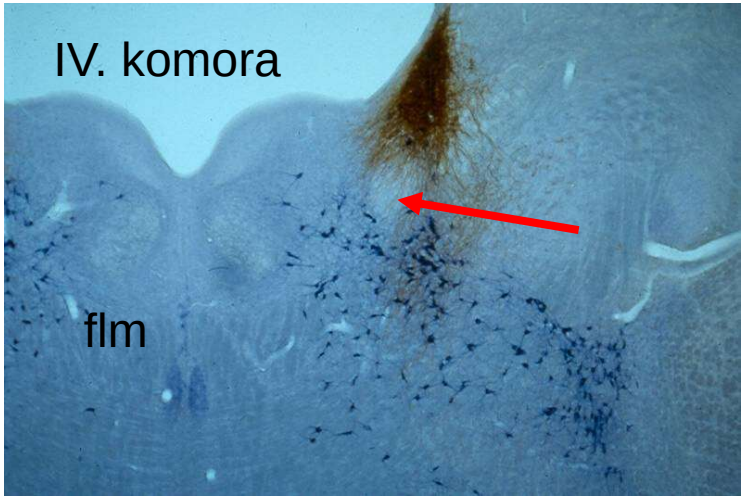

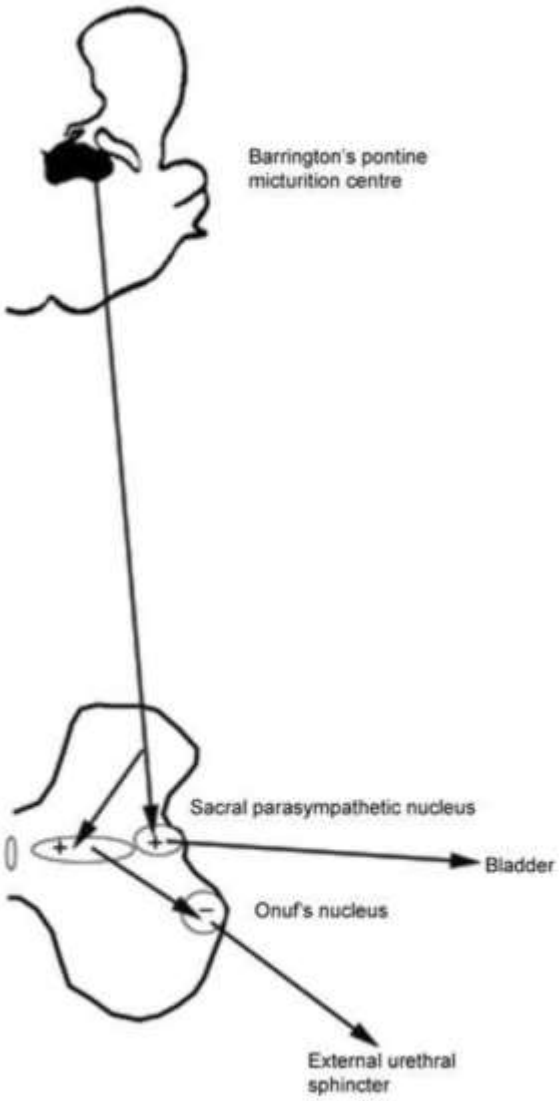

In bilateral lesion of this center– cruel urine retention
Barrington 1925

Horizontal eye movements

Cortex (FEF)

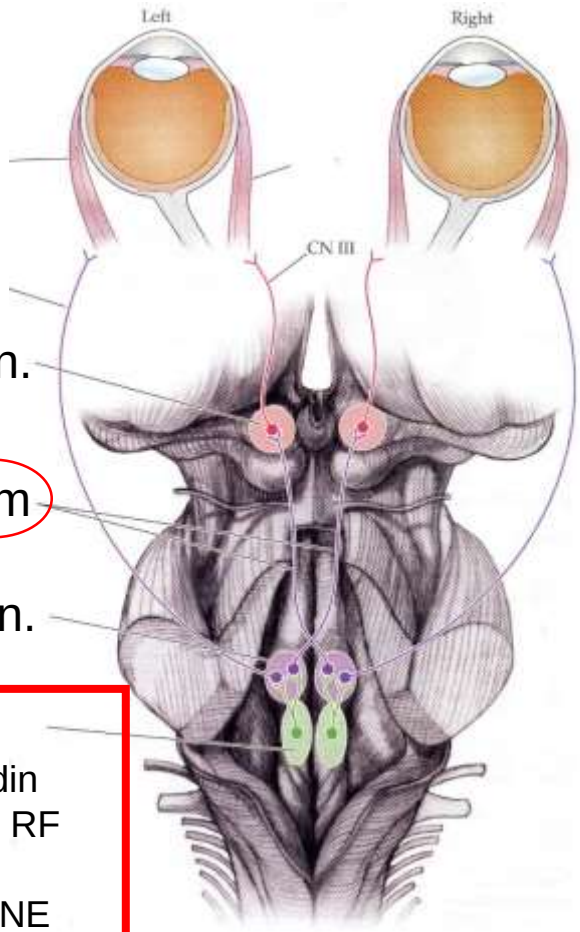

III.n.

flm

VI.n.

PPRF
Paramedin pontinne RF
=
PONTINNE GAZE CENTRUM

Vestibular nuclei

Poruchy řízení horizontálních očních pohybů - pons

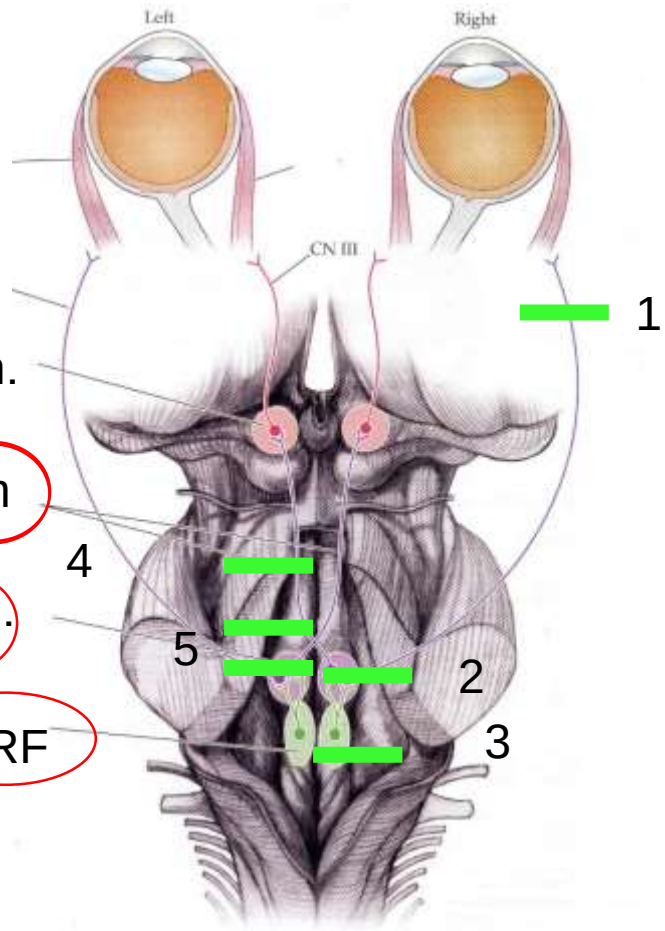

Jádro III.n.

flm

Cortex

Jádro VI.n.

PPRF

Vestibulární jádra

1-obrna pravého VI.n.
2-obrna pohledu doprava
3-obrna pohledu doprava
4-INO –oslabená addukce doprava
nystagmus

5- INO –oslabená addukce doprava
nystagmus
+ obrna pohledu doleva

INO- internukleární obrna

INTERNUCLEAR OFTHALMOPLEGIA

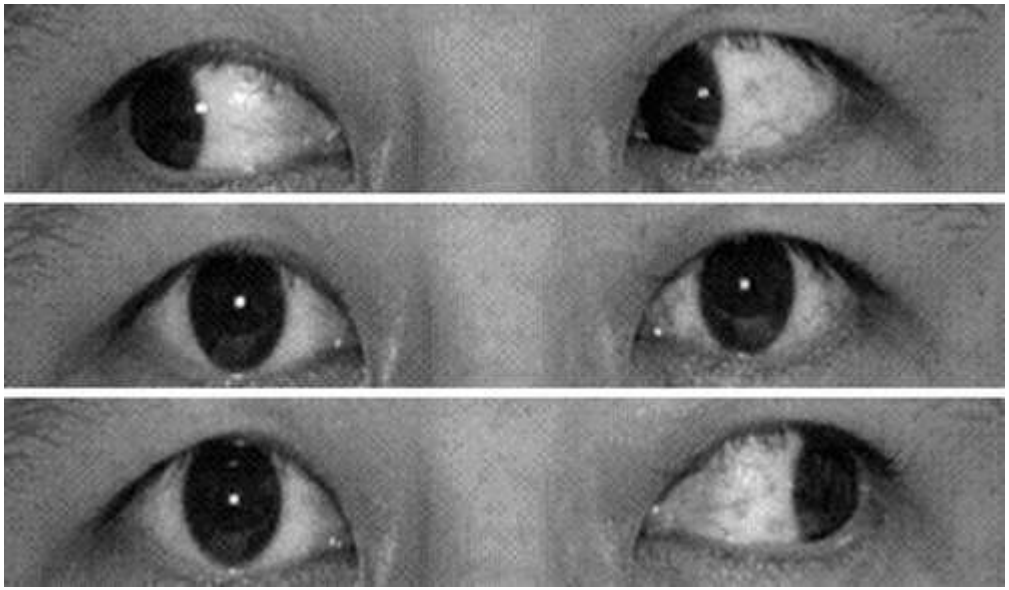

Paresis of right mlf – on the side of lesion is no adduction

http://pubs.rsna.org/doi/10.1148/rg.331125033?url_ver=Z39.88-2003&rfr_id=ori:rid:crossref.org&rfr_dat=cr_pub%3dpubmed

Vertical eye movements

Center in midbrain

FEF
CS
Vest.

→

Ncl.intersticialis rostralis
Ncl intersticialis Cajali
Ncl. Darkševiči

→

Jádra III., IV., VI.n
Cervical spinal cord

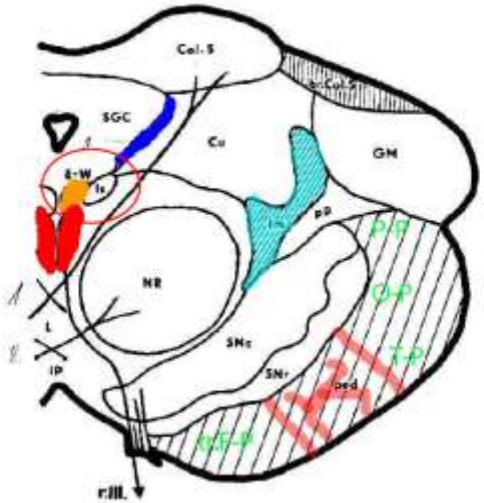

Area pretectalis

- Pupillary reflex center

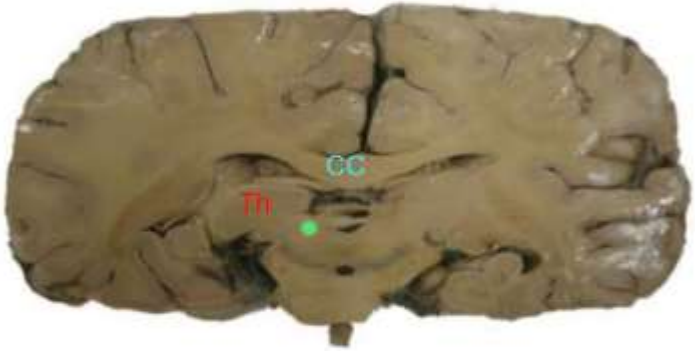

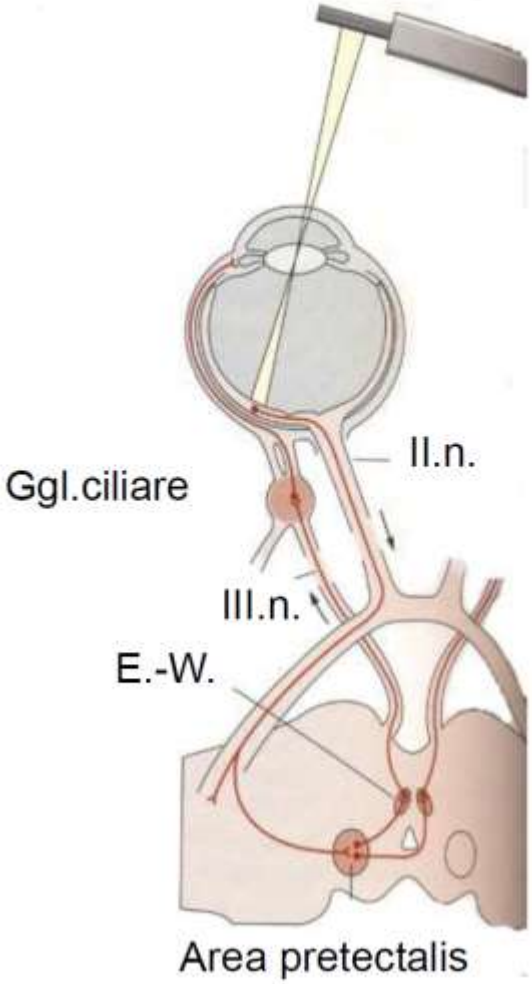

Precerebellar nuclei

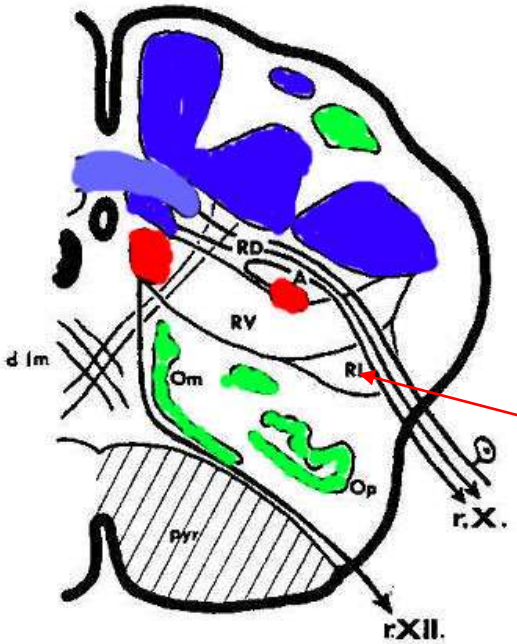

Ncl basalis tegmenti pontis Bechterevi

ncl. reticularis lateralis

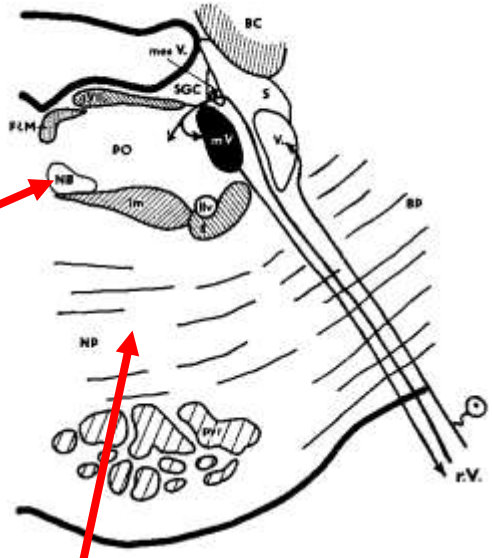

Ncl. Olivaris principalis
Ncl. Olivaris accessorius medialis
Ncl. Olivaris accessorius dorsalis

Ncll. Pontis

Cervae isole –section between colliculi

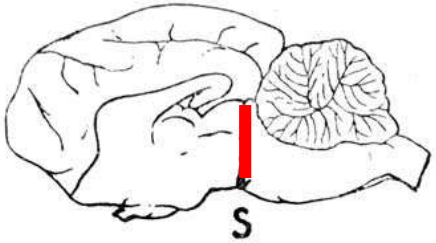

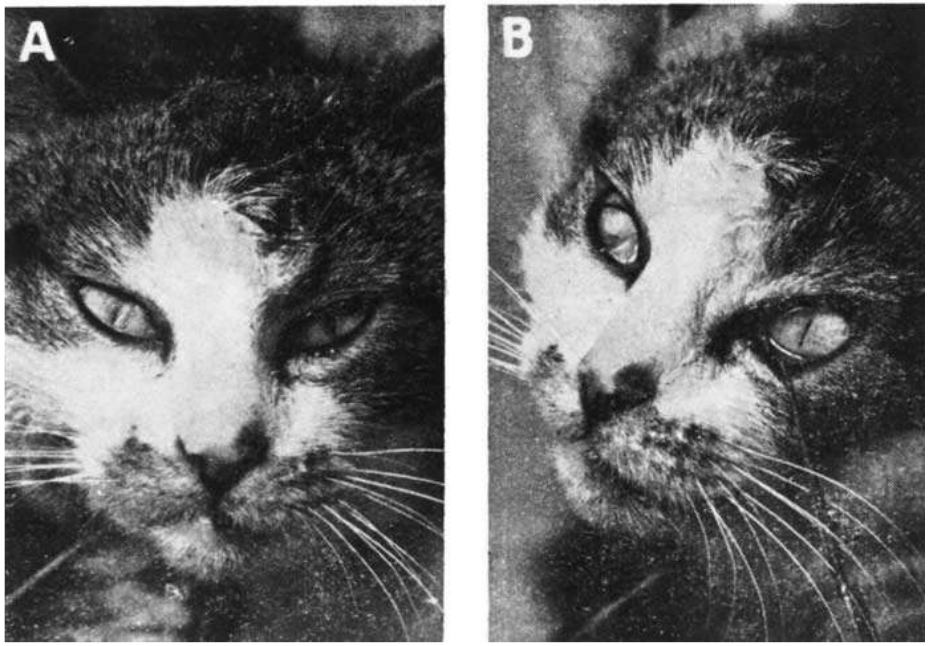

Cat slept all time
Extreme miosis
Loss of olfactory and visual reflexes

Frédéric Bremer 1892–1982

Encephale isole

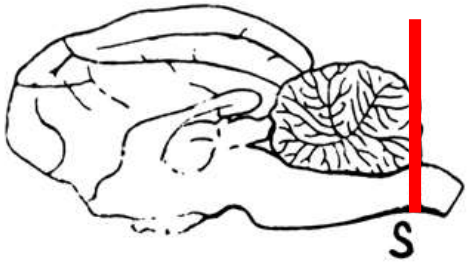

Cat slept or was awake
It was possible to wake it up

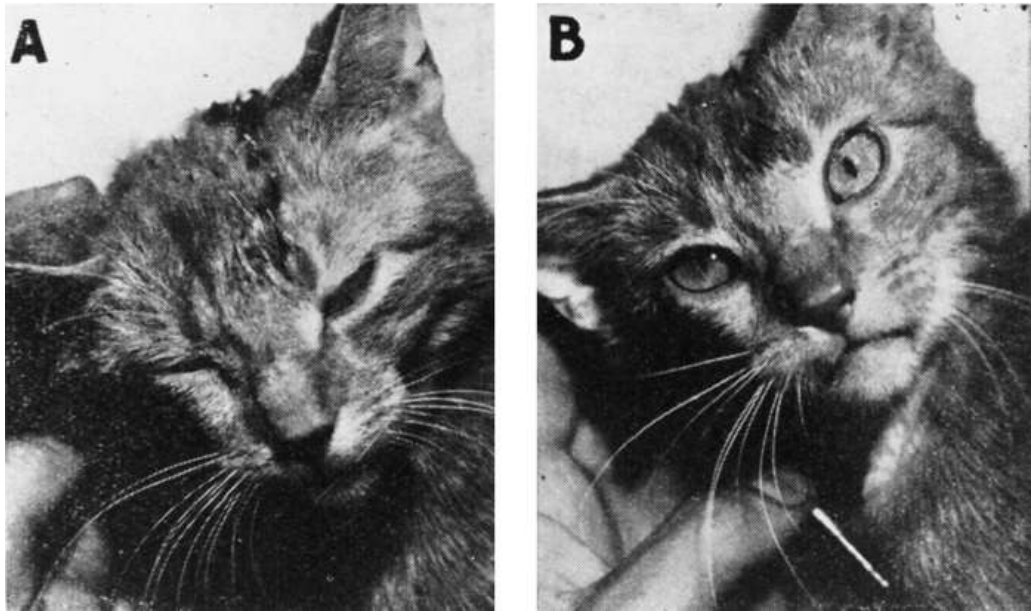

from the *Bull Acad Roy Med Belg*
1937; **4:** 68–86).

Inner structures of brainstem

- Cranial nerves nuclei
- Reticular formation nuclei
- Specific nuclei

  connected in the motor, sensory

  or cerebellar circuits

White matter – visible fascicles
motor, sensory and cerebellar

1) crura cerebri – cortex – brainstem and spinal cord connections

2) pedunculi cerebellares brainstem – cerebellum connections

3) pyramides medullae oblongatae – cortico-spinal tract

4) fibrae arcuatae internae and lemniscus medialis, tr. spino-thalamicus – thalamic connections

5) corpus trapezoideum a lemniscus lateralis – part of the acoustic tract

6) fasciculus logitudinalis medialis – coordination of eye movements – eye movement nerve nuclei, vestibular nuclei and neck muscles nuclei connection

7) fasciculus longitudinalis dorsalis hypothalamus- CGM – VM nerve nuclei connection

8) tr. spinalis n. trigemini, tr. mesencephalicus n. trigemini

tr. solitarius – fibres to sensory nerve nuclei

9) commissura posterior crossed fibers from Darksevic and Cajal nuclei

10) Fasciculus centralis tegmenti a) from the mesencephalon (red nucleus) to the amiculum olivae inferioris a the RF nuclei b) from RF to thalamus and subthalamus

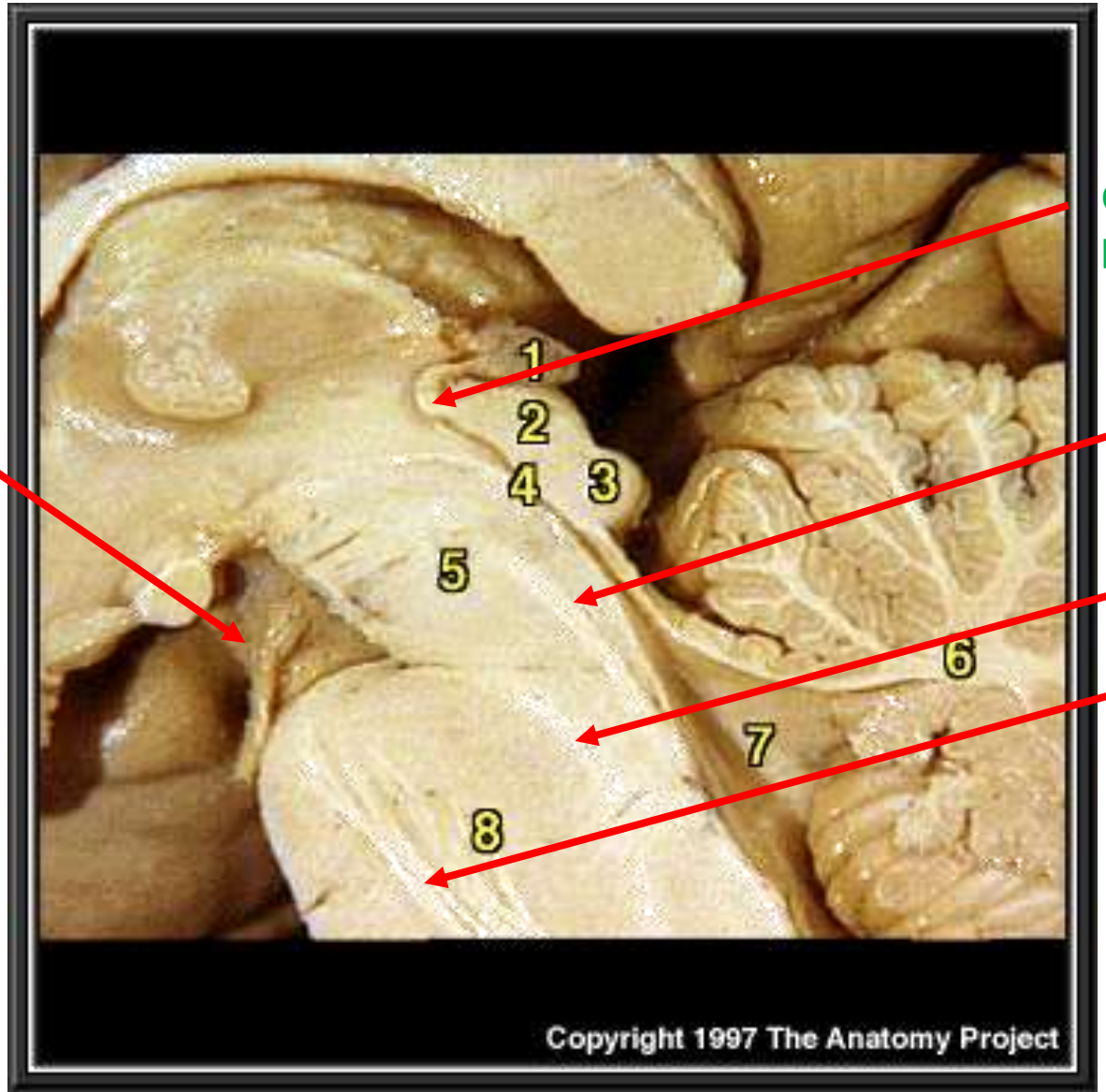

Commissura posterior

Fasciculus longitudinalis medialis

Lemniscus medialis

Pyramidal tract

Pedunculus cerebri

Macroscopic sections

MEDULLA SPINALIS

MEDULLA OBLONGATA

Brainstem sections – Nissl staining

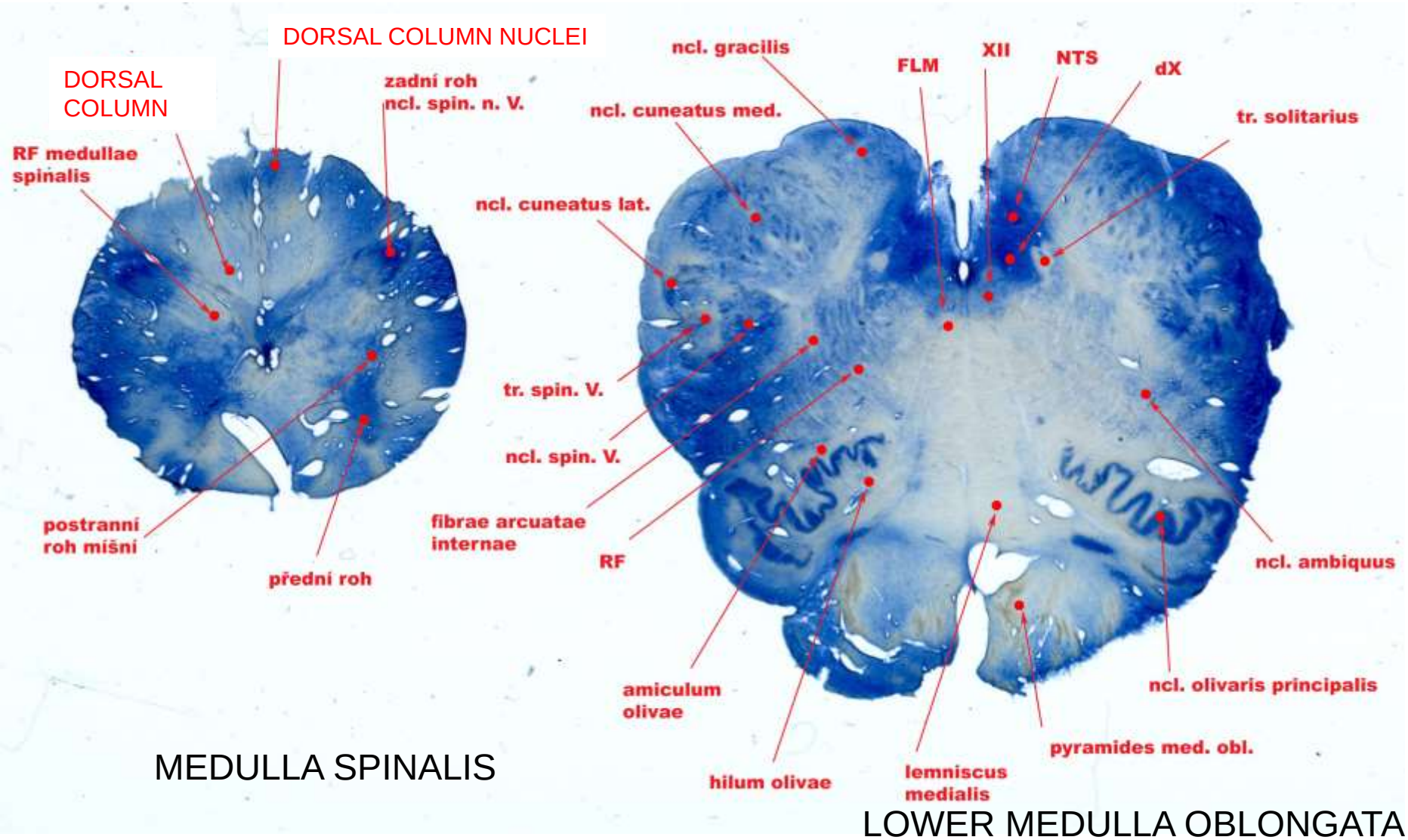

MEDULLA SPINALIS

LOWER MEDULLA OBLONGATA

Řez dolní oblongatou

SENSORY
MOTOR
CEREBELLAR

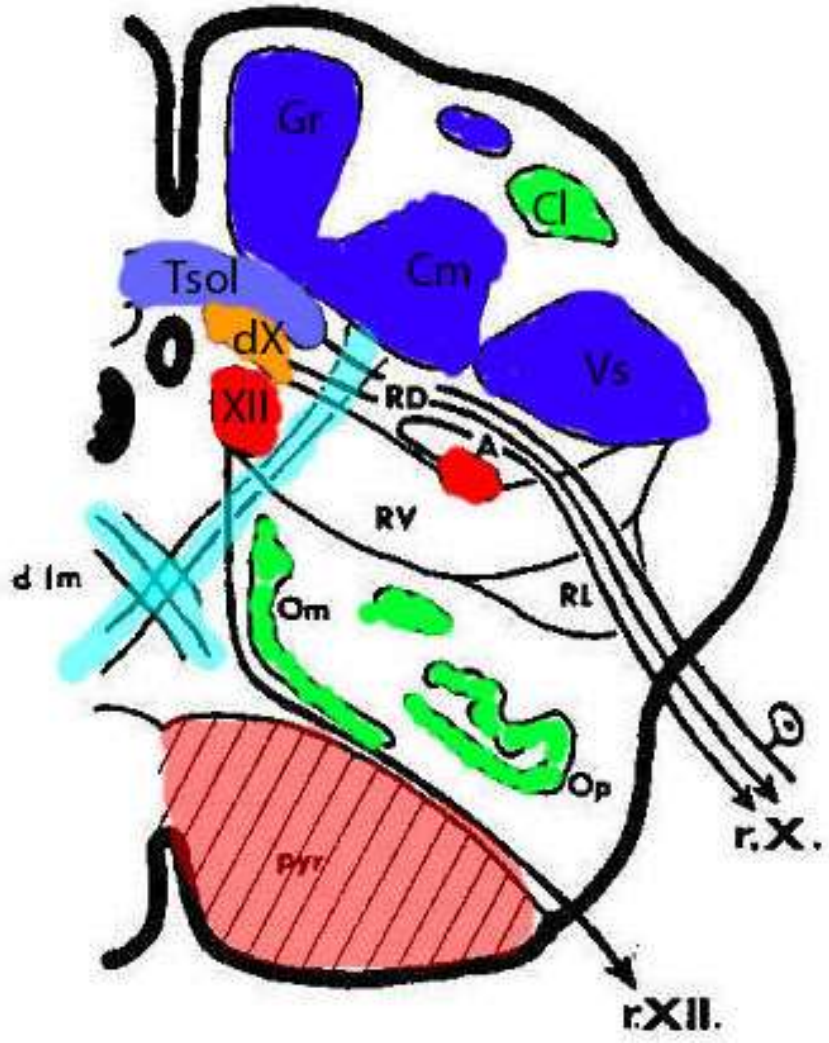

Basal and alar plate development in the brainstem

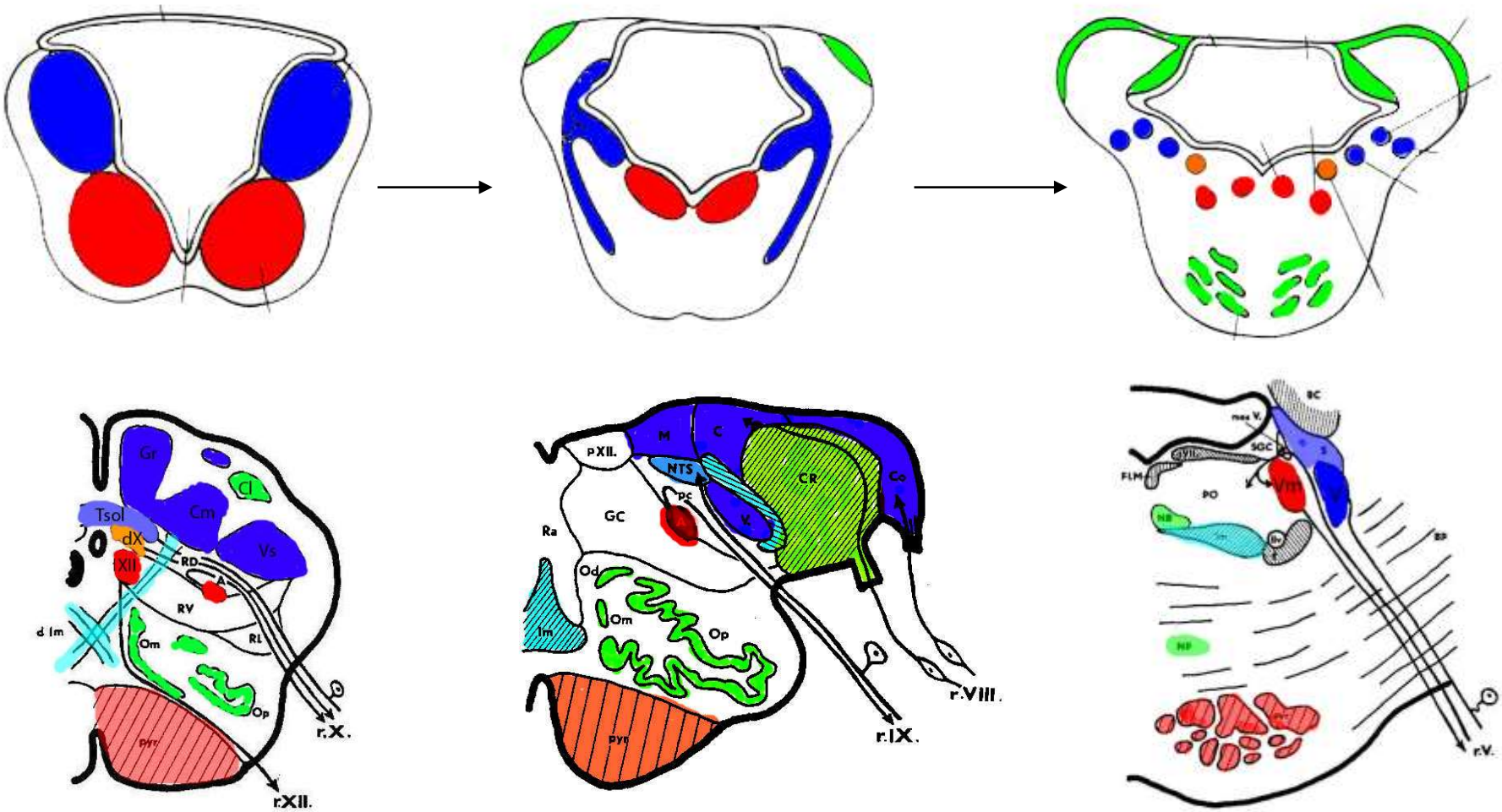

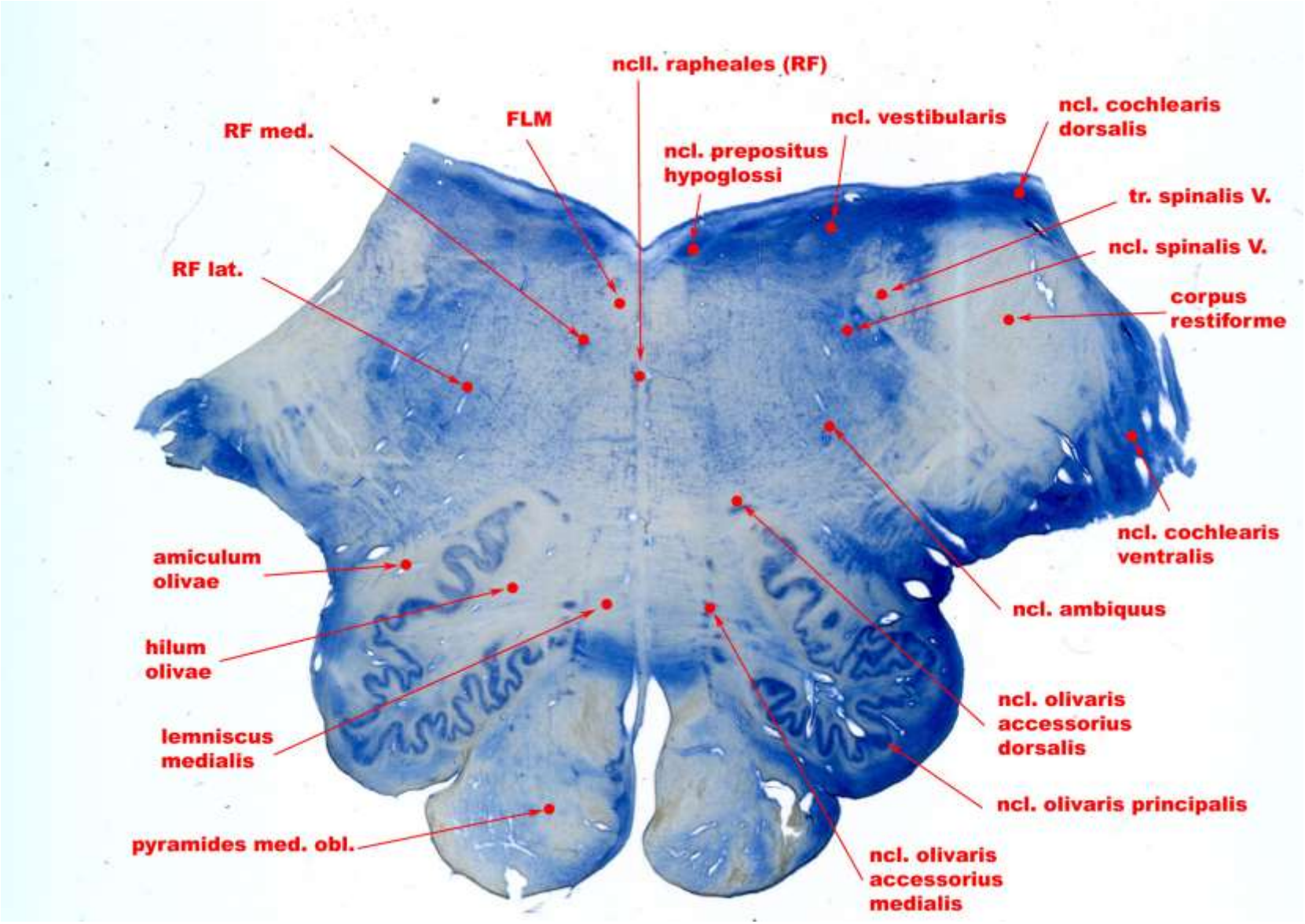

UPPER MEDULLA OBLONGATA

UPPER OBLONGATA SECTION

SENSORY
MOTOR
CEREBELLAR

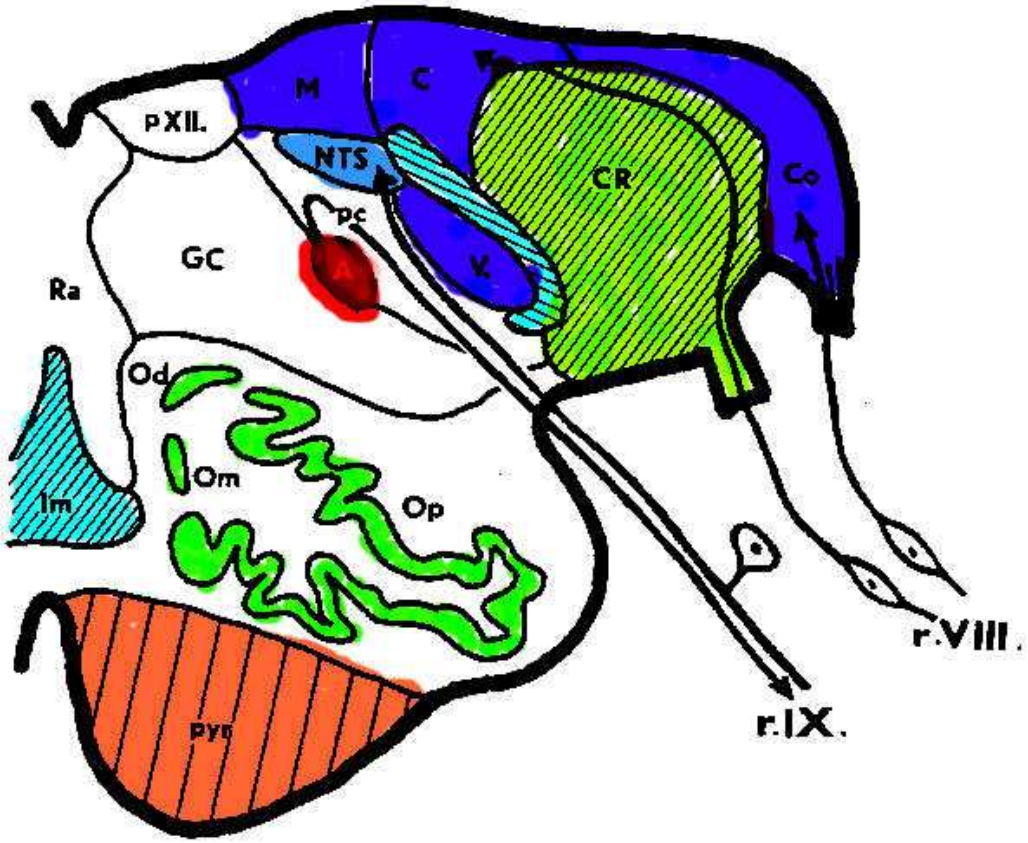

LOWER PONS SECTION

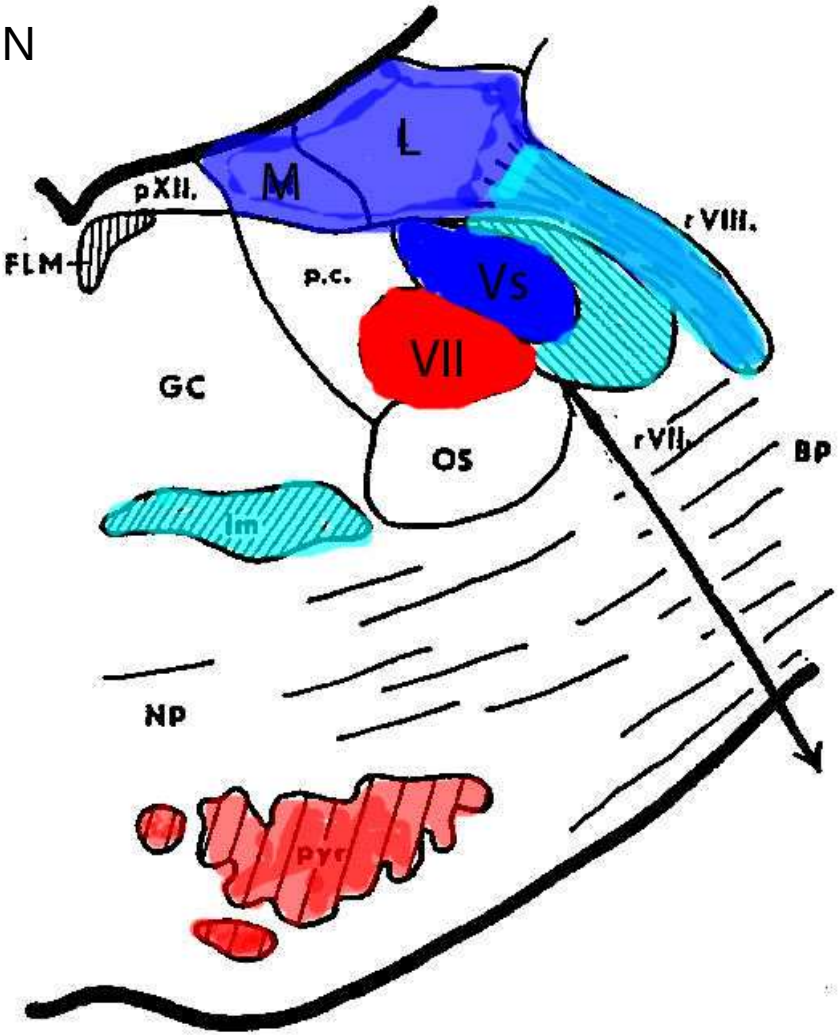

UPPER PONS SECTION

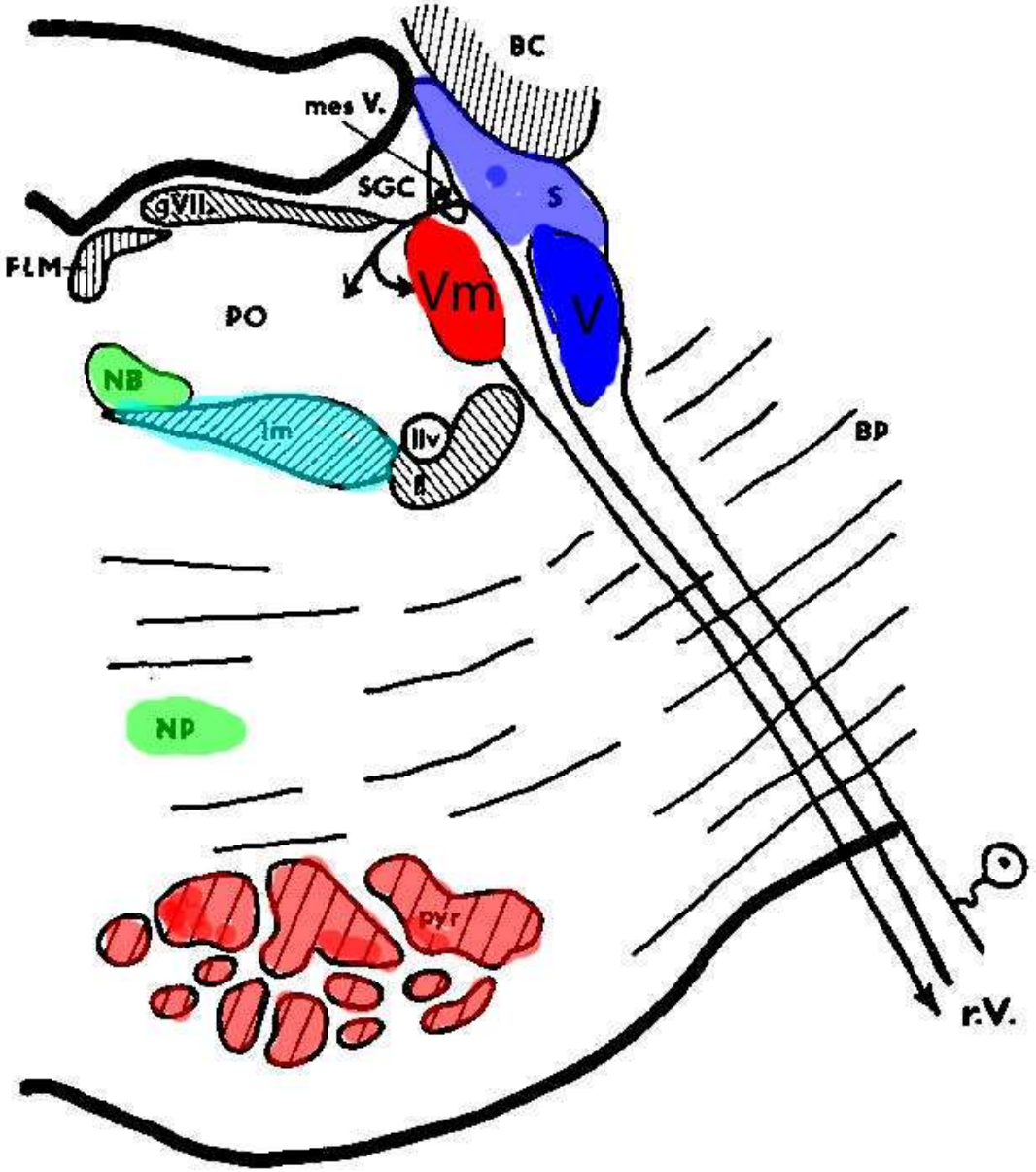

Ponto-mesencephalic junction

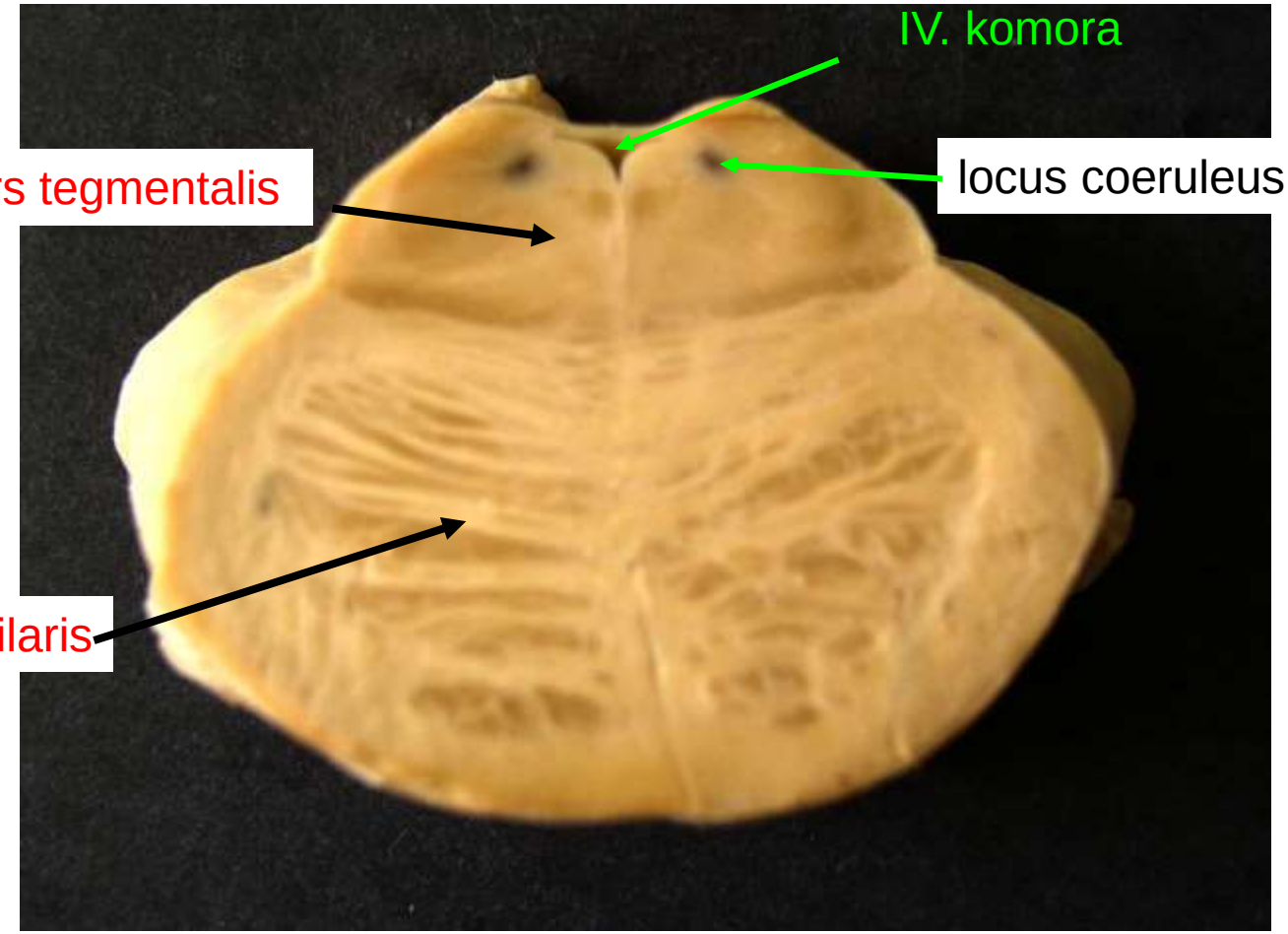

Pontomesencephalic junction section

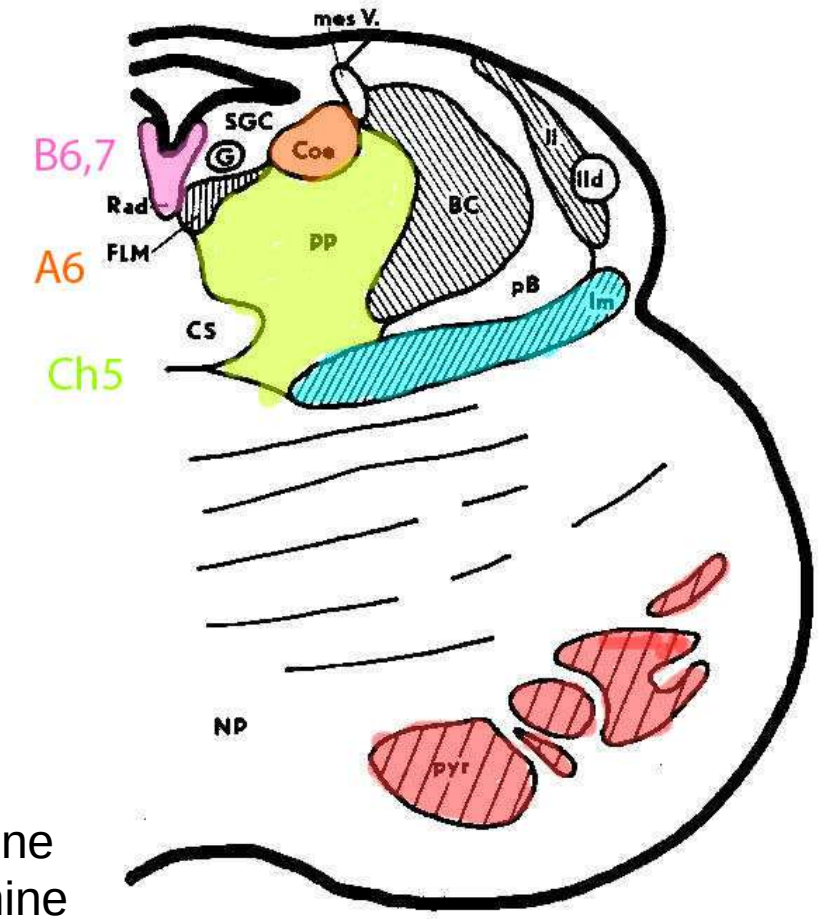

Neurotransmitters

A6 – locus coeruleus – noradranaline
B6,7 –ncl. raphe dorsalis – serotonine
Ch5 – ncl pedunculo pontinus acetylcholine, NO

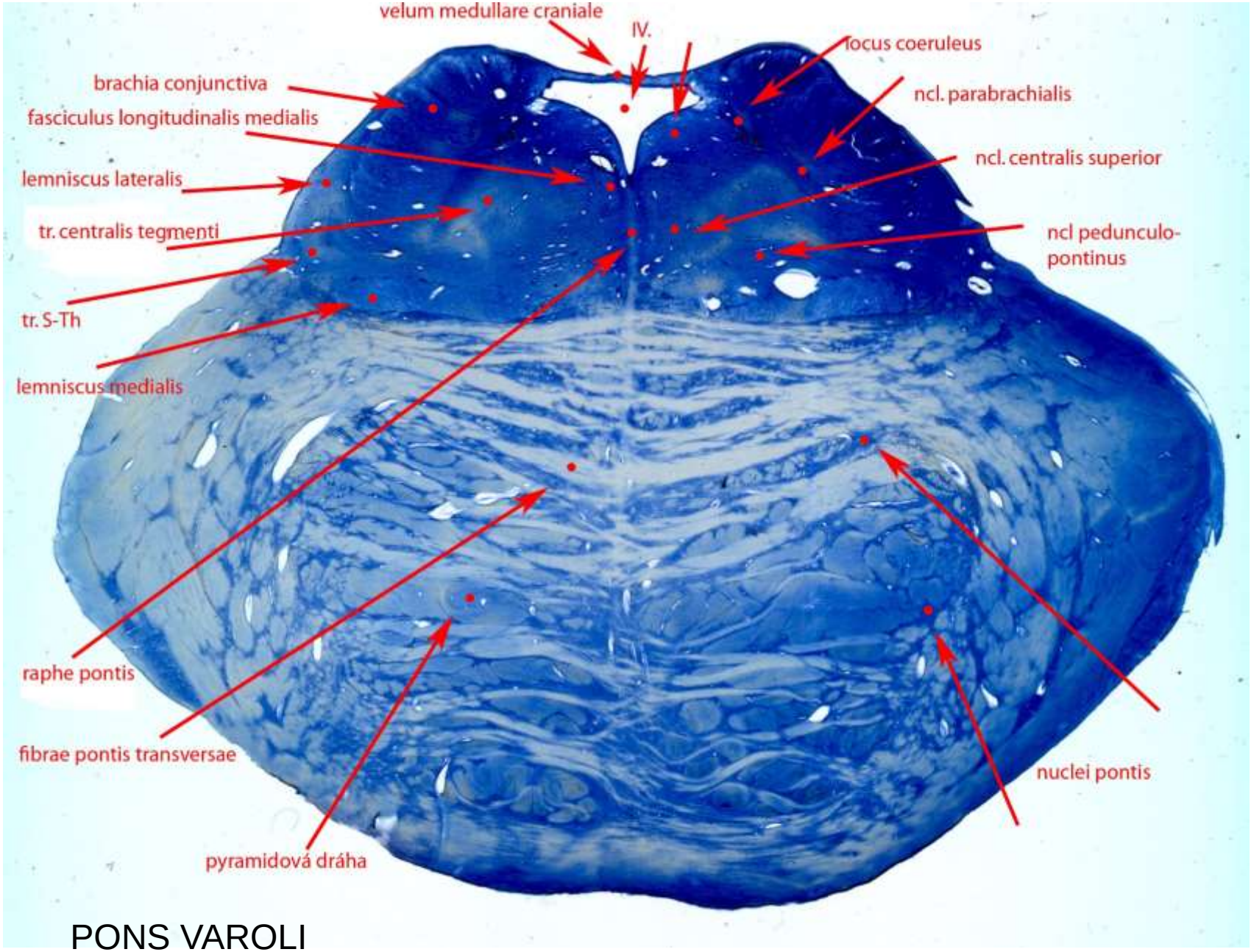
velum medullare craniale
IV.
locus coeruleus
brachia conjunctiva
ncl. parabrachialis
fasciculus longitudinalis medialis
ncl. centralis superior
lemniscus lateralis
tr. centralis tegmenti
ncl pedunculo-
pontinus
tr. S-Th
lemniscus medialis
raphe pontis
fibrae pontis transversae
nuclei pontis
pyramidová dráha

PONS VAROLI

Pontomesencephalic junction section

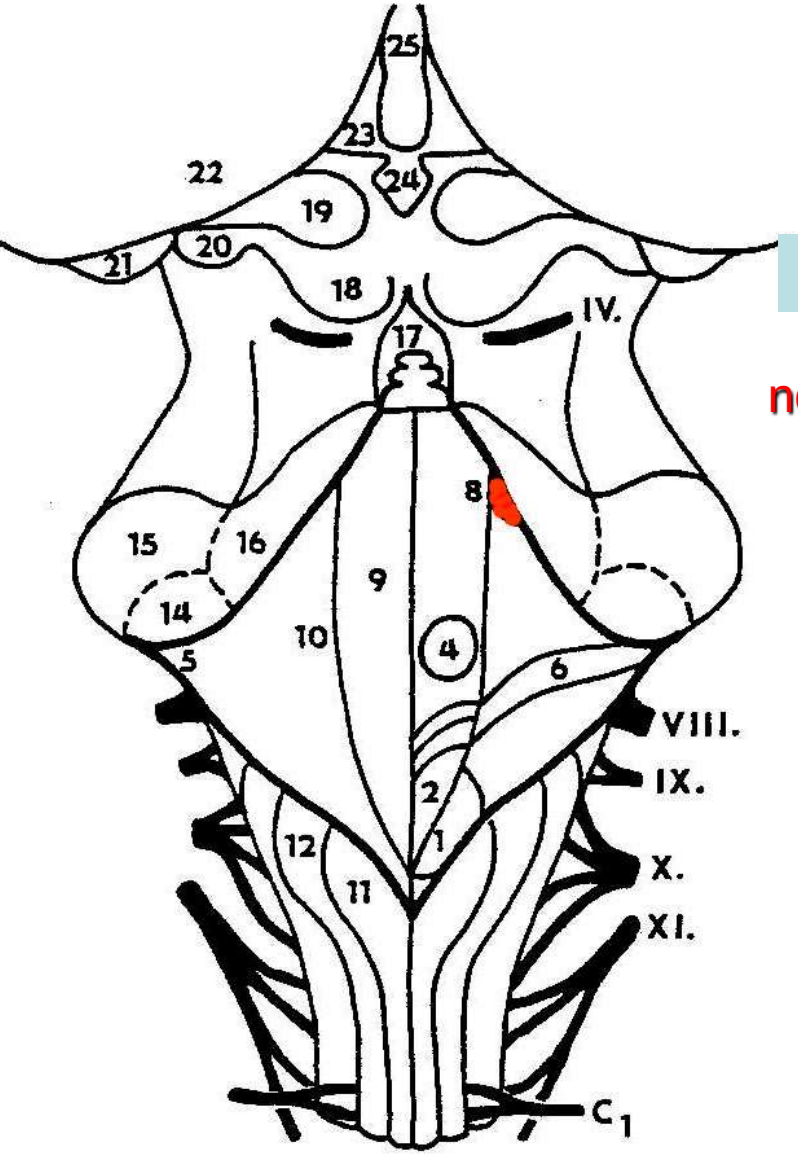

B6,7

serotonin

A6

noradrenalin

Ch5

acetylcholin

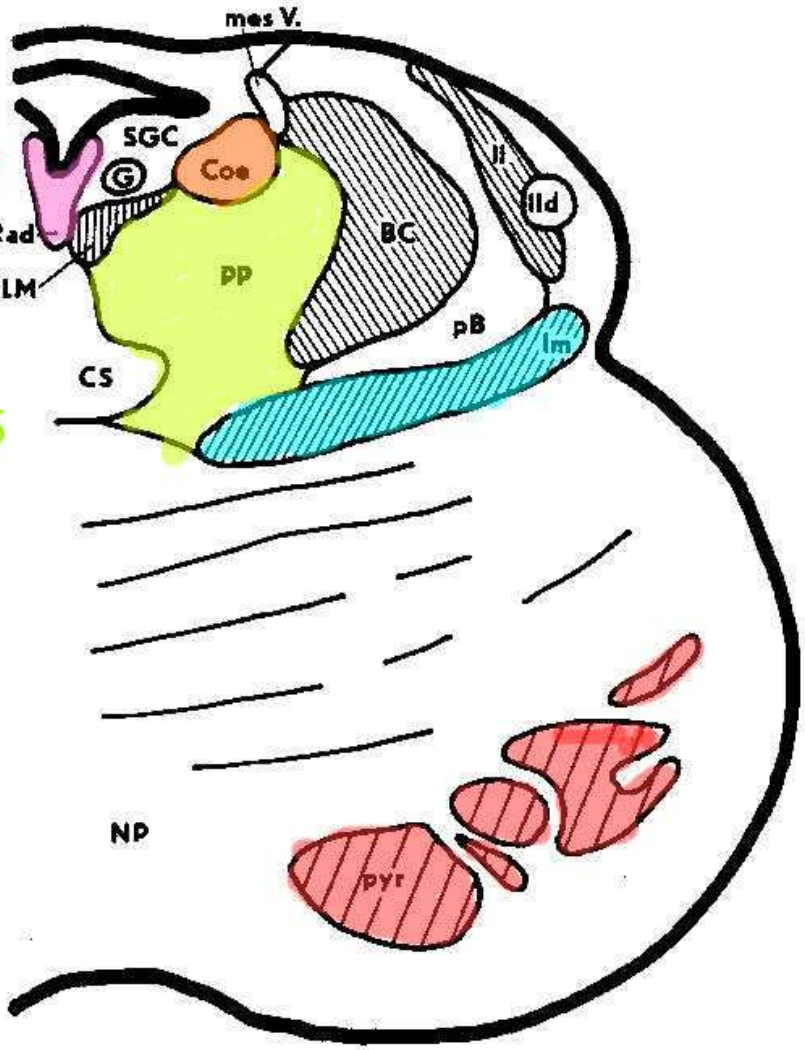

Pontomesencephalic junction section - rat
tyrosin hydroxylase and NADPHdiaphorase labelling

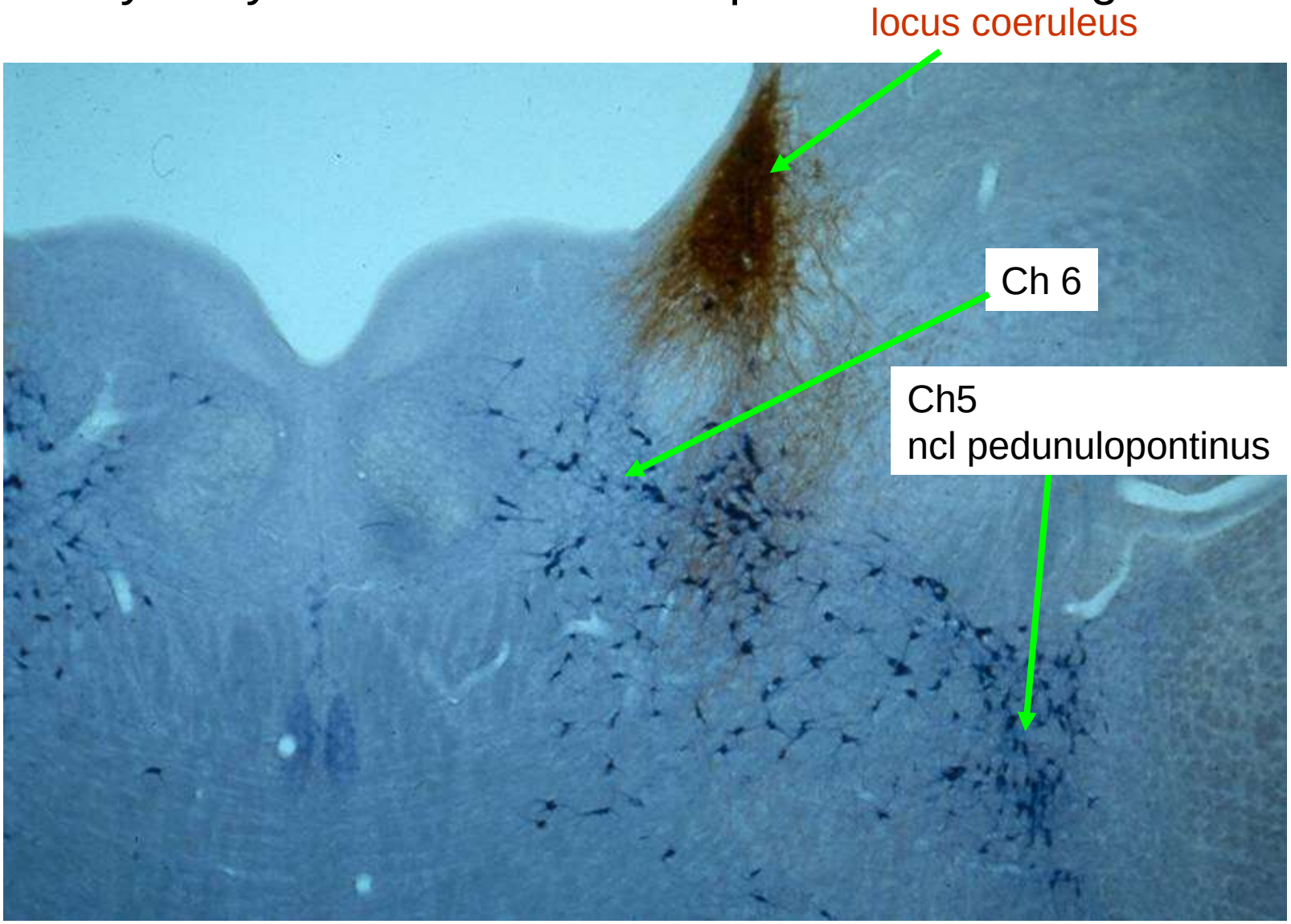

Mesencephalon - lower

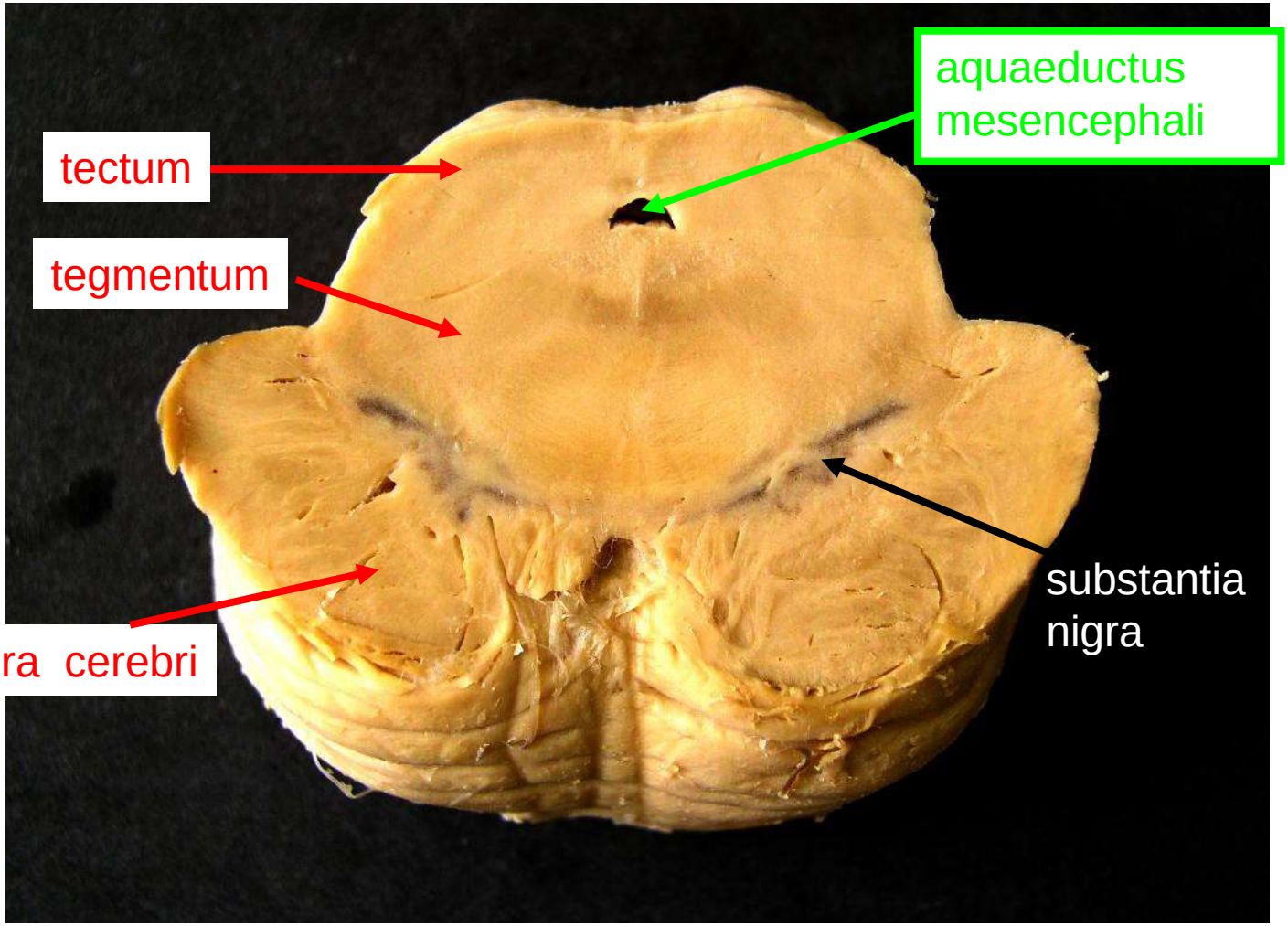

Mesencephalon - upper

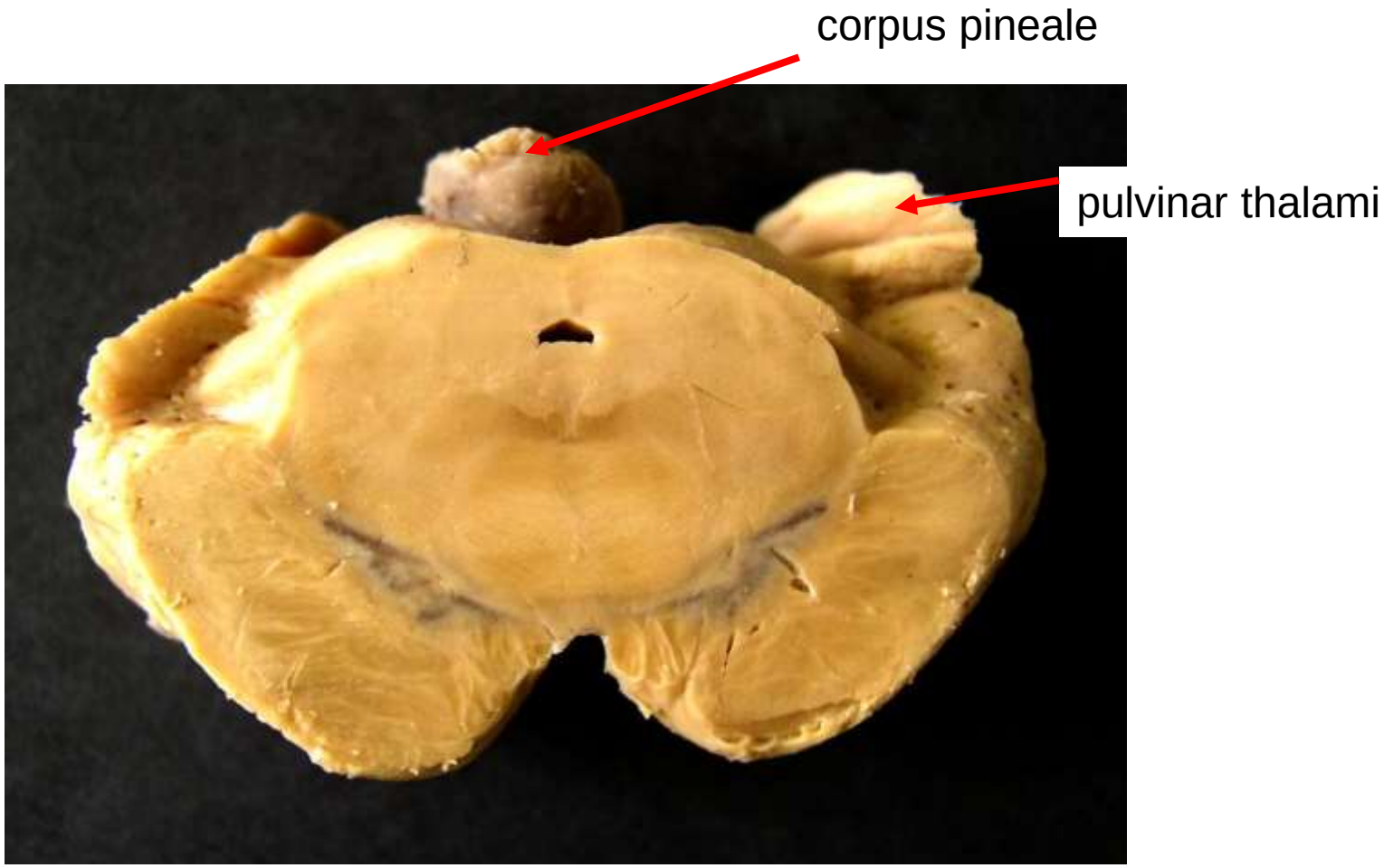

Upper mesencephalon section

1-decussatio tegmenti dorsalis –tr. tecto-spinalis
2-decussatio tegmenti ventralis- tr.rubro-spinalis
3-ncl. mesencephalicus n. trigemini

Substantia nigra (A9group)
dopamin to basal ganglia
(Parkinson disease – lack of dopamine)

Nucleus ruber
Part of the cerebellar circuits and Motor Rubro-spinal tract

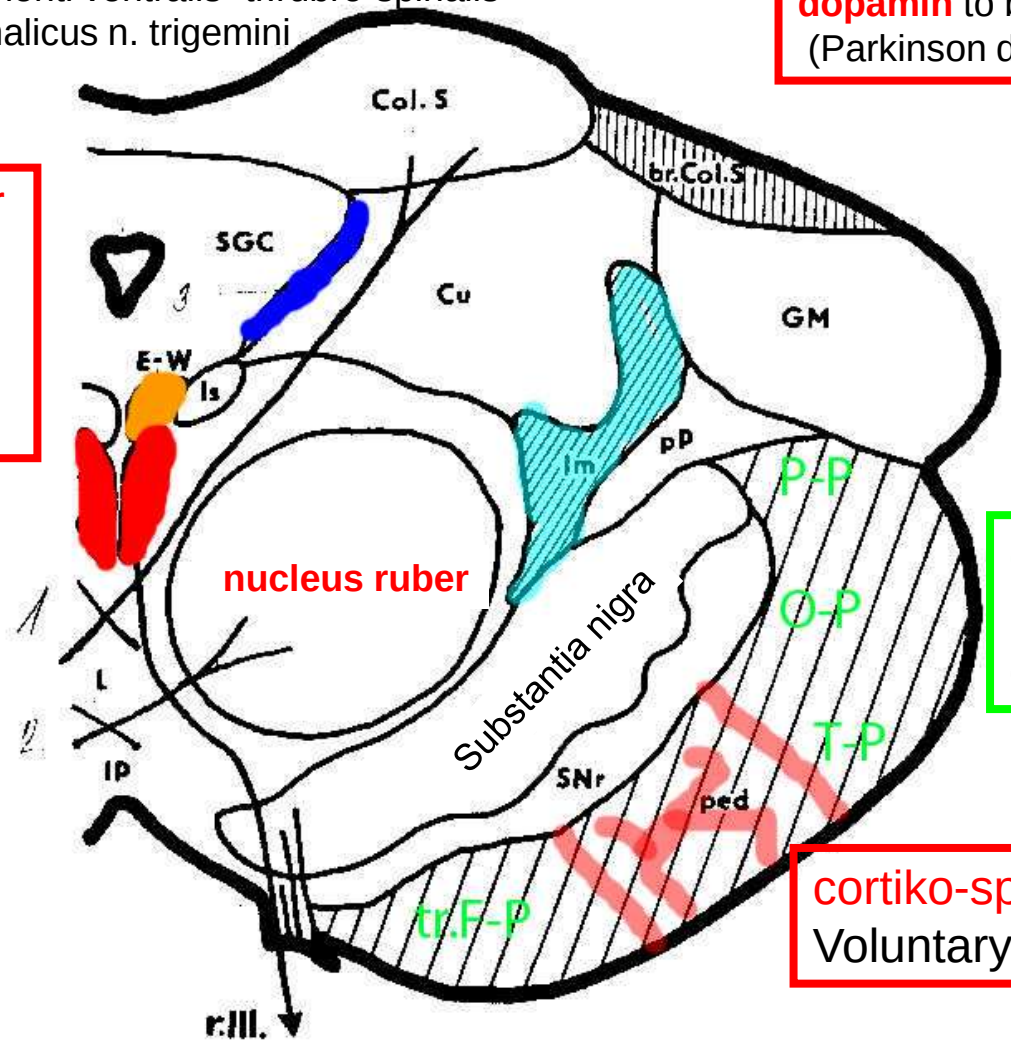

cortico-pontine tracts
Part of the main cerebellar circuit

cortiko-spinal tract
Voluntary movement

Colliculus superior connection

mesencephalic visual center (superficial layers)
and motor center (deep layers)
unconscious reaction to visual and acoustic stimuli – tecto-spinal tract

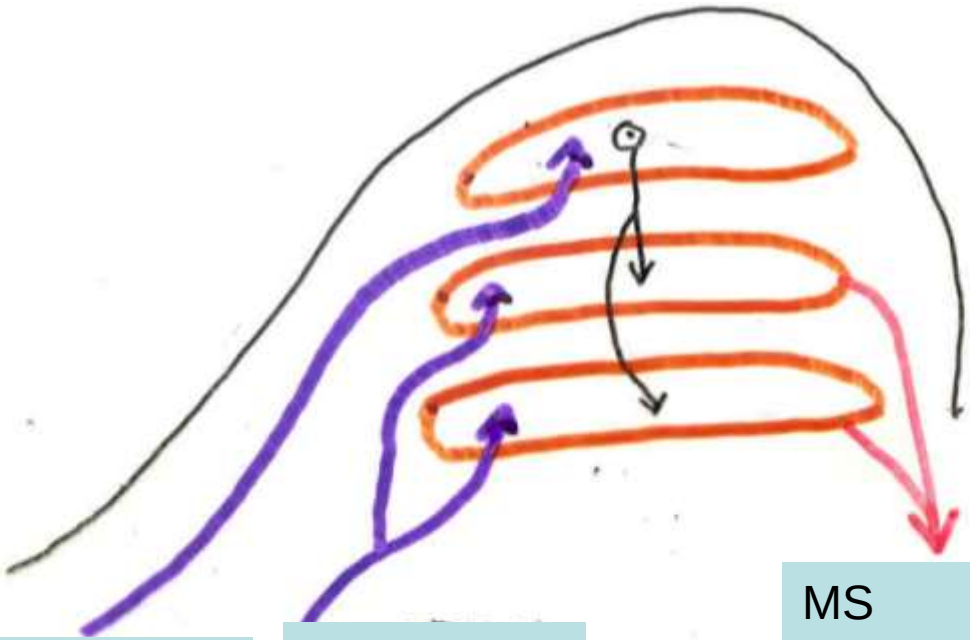

Tractus opticus

Cortex

Cortex

SNret + BG

Crbl

n.V.

MS

MS

RF

n.III., IV., VI.

Crbl

OI

Darkš. + Cajal

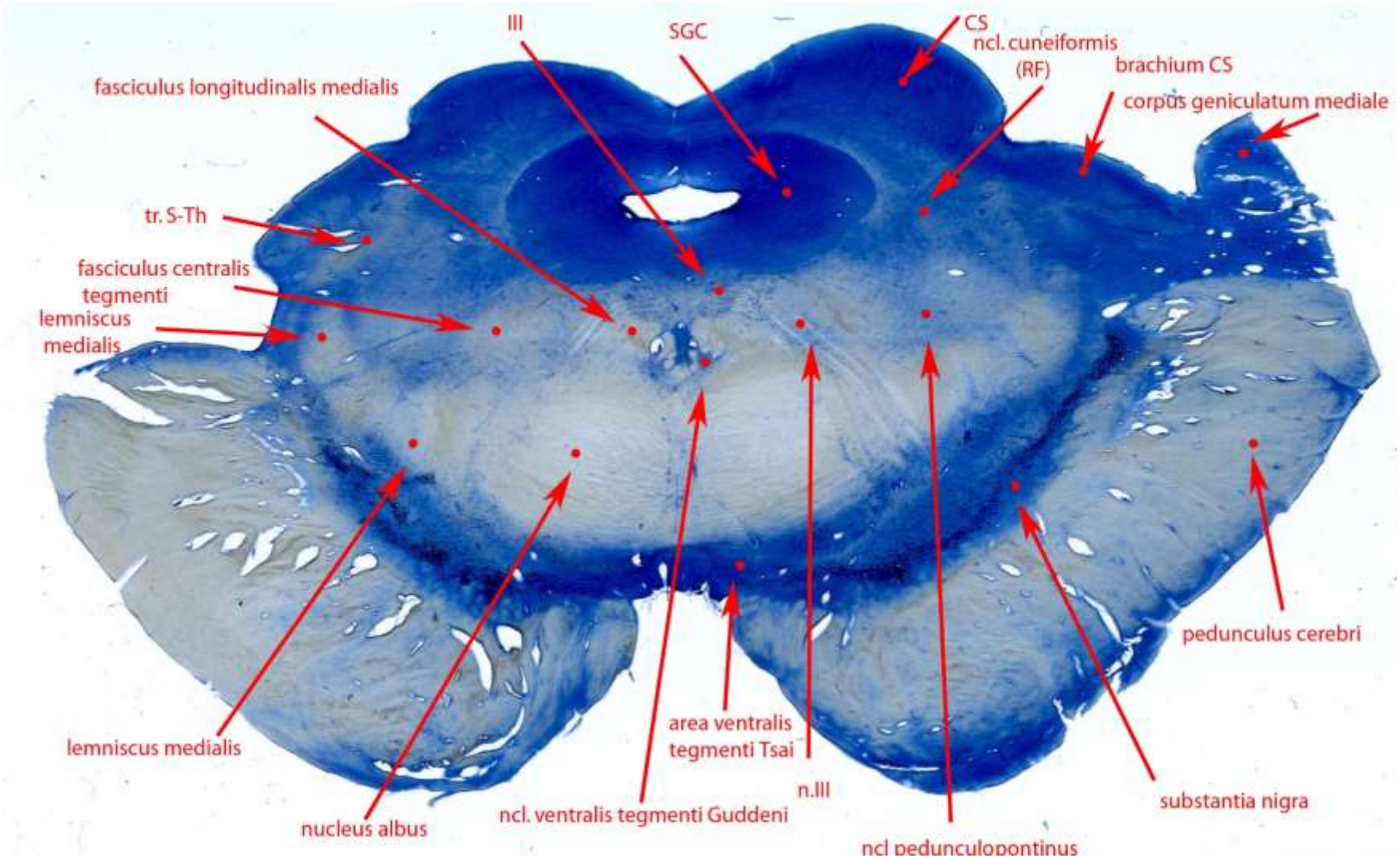

UPPER MESENCEPHALON

Brainstem functions

- 1) Cranial nerve nuclei III.-XII.
- 2) Reticular formation activates (ascending and descendending parts), or inhibits
- 3) Reticular formation nuclei make centers of important vital functions, e.g vasomotor, pneumotactic, micture centrum
- 4) Reticular formation is involved in pain conduction tr. spino-retikulo-thalamicus and pain controll CGM
- 4) Reflex centers - succing, swallowing, corneal, cough and vomit
- 5) Sensory and motor tracts
- 6) Bilateral connection with cerebellum

Vascular lesions in the brain stem – motor and sensory defects

Hemiplegia alternans inferior

Hemiplegia alternans media

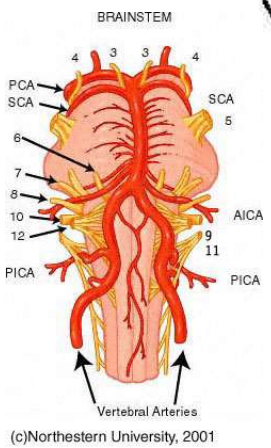

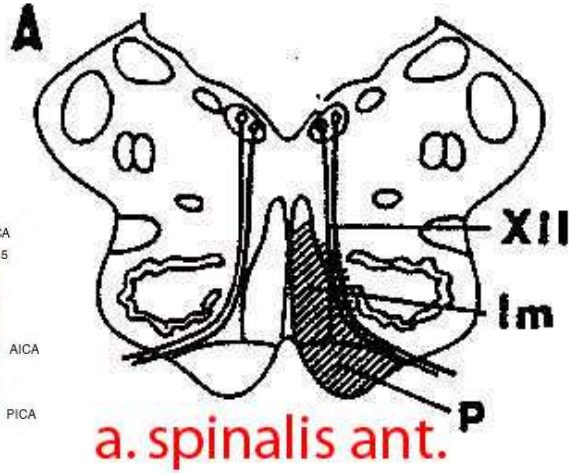

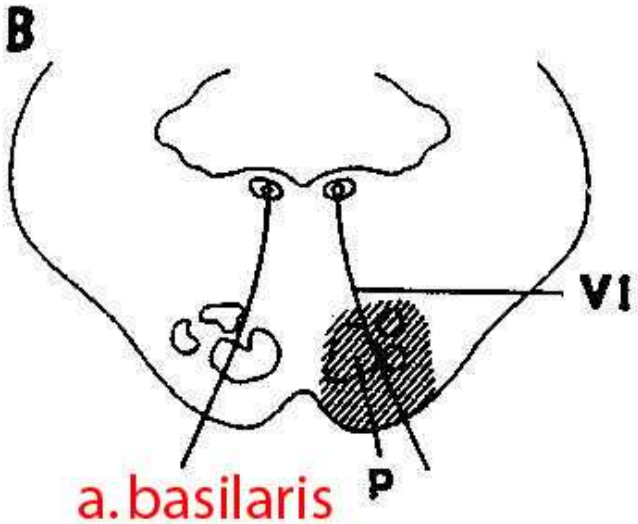

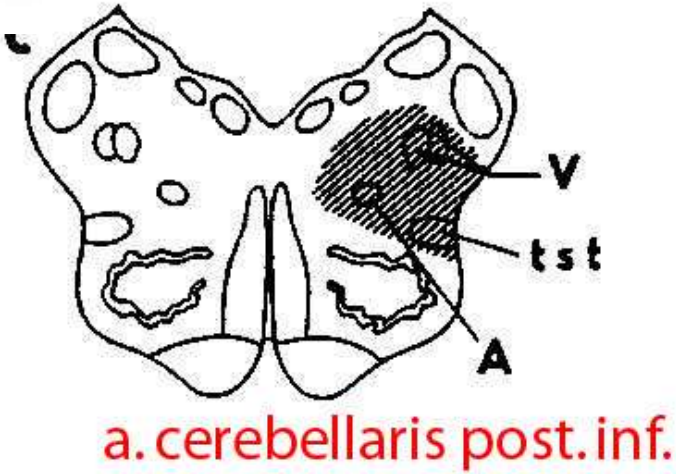

Wallenberg´s sy of lateral medulla oblongate

Hemiplegia alternans superior

Wallenberg´s sy of lateral oblongate
(e.g occlusion of a. cerebellaris post. inf.

Face: Ipsilaterally loss of pain and temperature sensation

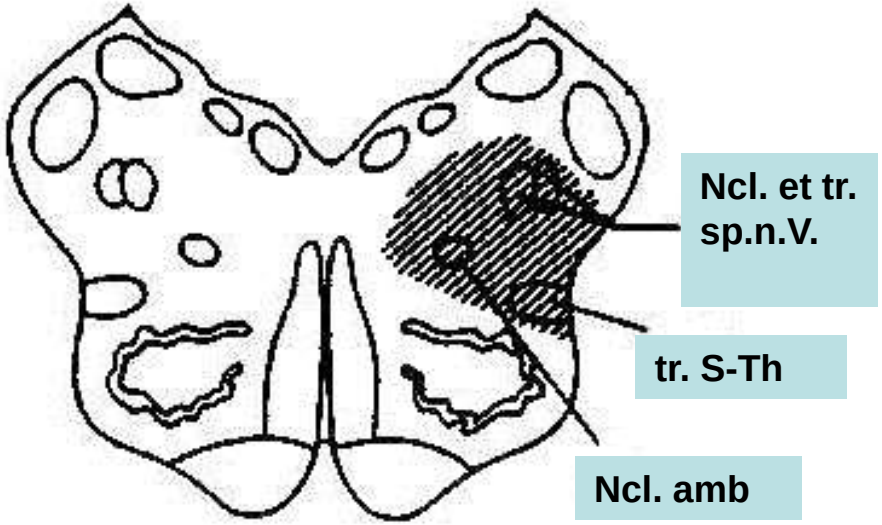

Body Contralaterally loss of pain and temperature sensation

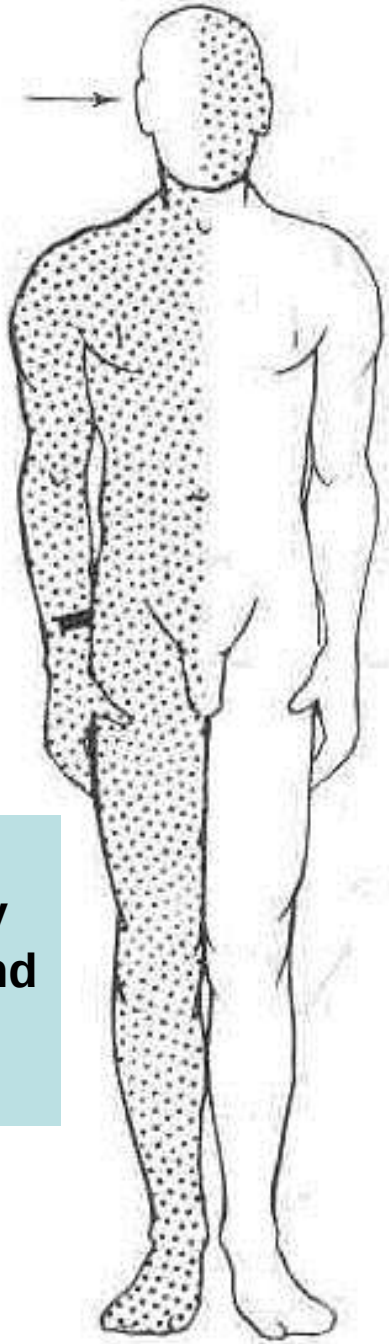

Syndrom of lateral medulla oblongata

Vertebral artery branches – a. cerebellaris inferior posterior (PICA)
Wallenbergův sy

Sy medial medulla oblongata

Paramedian and circumferential branches of a. spinalis anterior
Hemiplegia alternans inferior

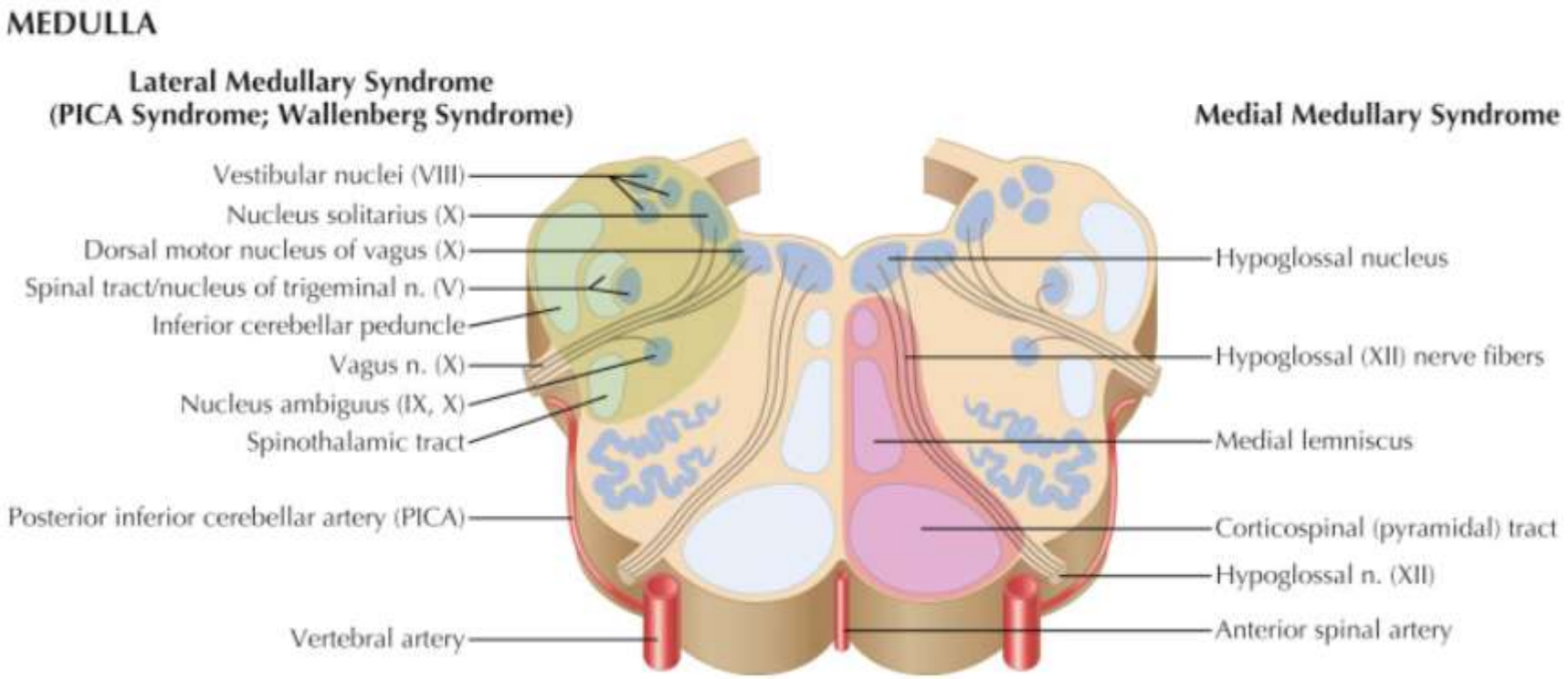

(1) loss of pain and temperature sensation on the ipsilateral side of the face (descending nucleus and tract of V) **and the contralateral side of the body** (spinothalamic/spinoreticular system);
(2) dysphagia and dysarthria (paralysis of ipsilateral pharyngeal and laryngeal muscles resulting from damage to the ipsilateral nucleus ambiguus);
(3) ataxia of the limbs and falling to the ipsilateral side (inferior cerebellar peduncle and its afferent tracts);
(4) vertigo with nausea, vomiting, and nystagmus (vestibular nuclei); and
(5) ipsilateral Horner's syndrome, with ptosis, miosis, and anhidrosis (descending axons from the hypothalamus to the T1–T2 intermediolateral cell column of the spinal cord).

Lateral pontine sy
a.cerebelaris inferior anterior (AICA)

Medial pontine syndrome
a. basilaris

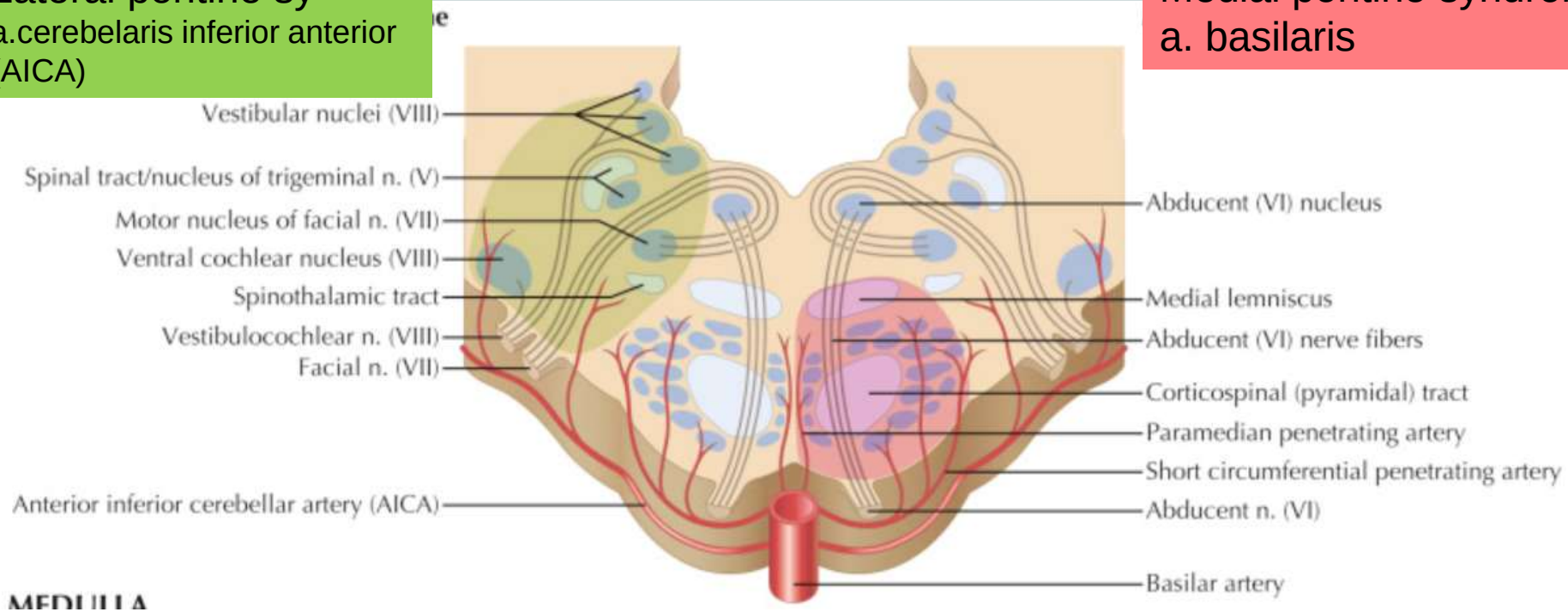

Hemiplegia alternans media

Weber´s sy

Hemiplegia alternans superior
Contralateral limb palsy
+ ipsilateral III.n palsy

Benedikt´s sy

Contralateral sensory loss
Ipsilateral III.n palsy
Tremor, loss of balance

Hemiplegia alternans superior

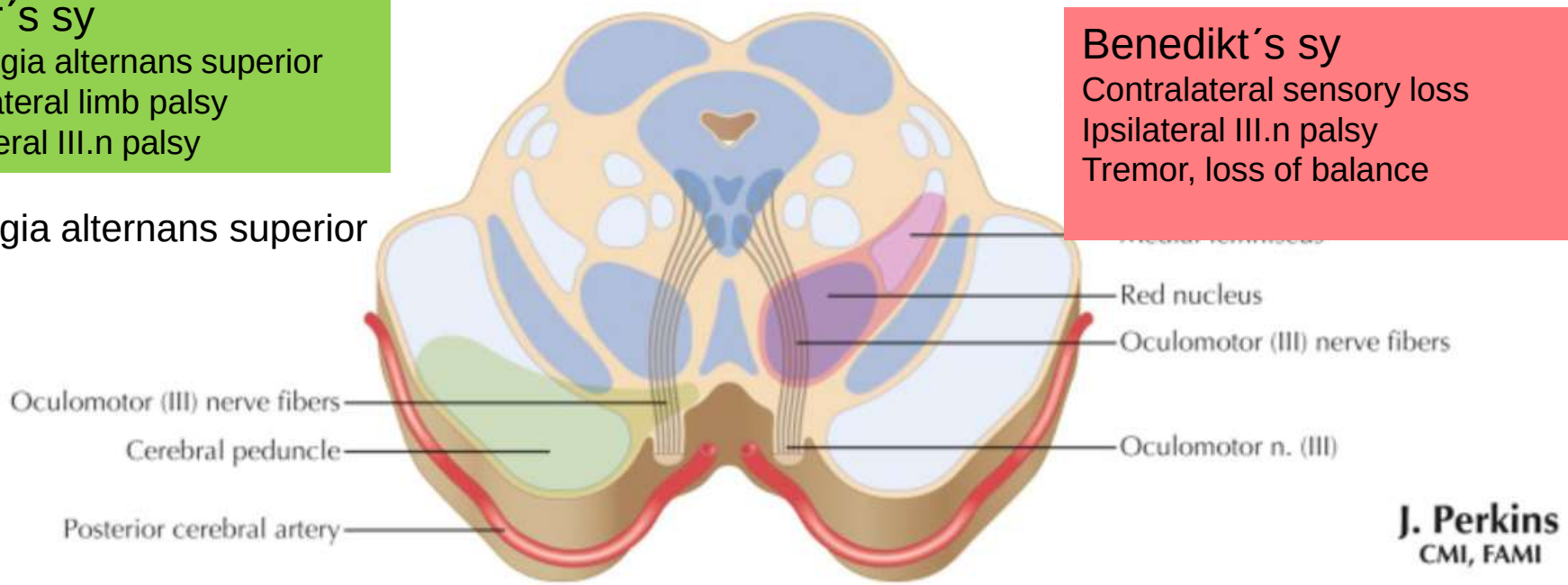

Branches of a. cerebri post. and ramus comm. post.

Repetition

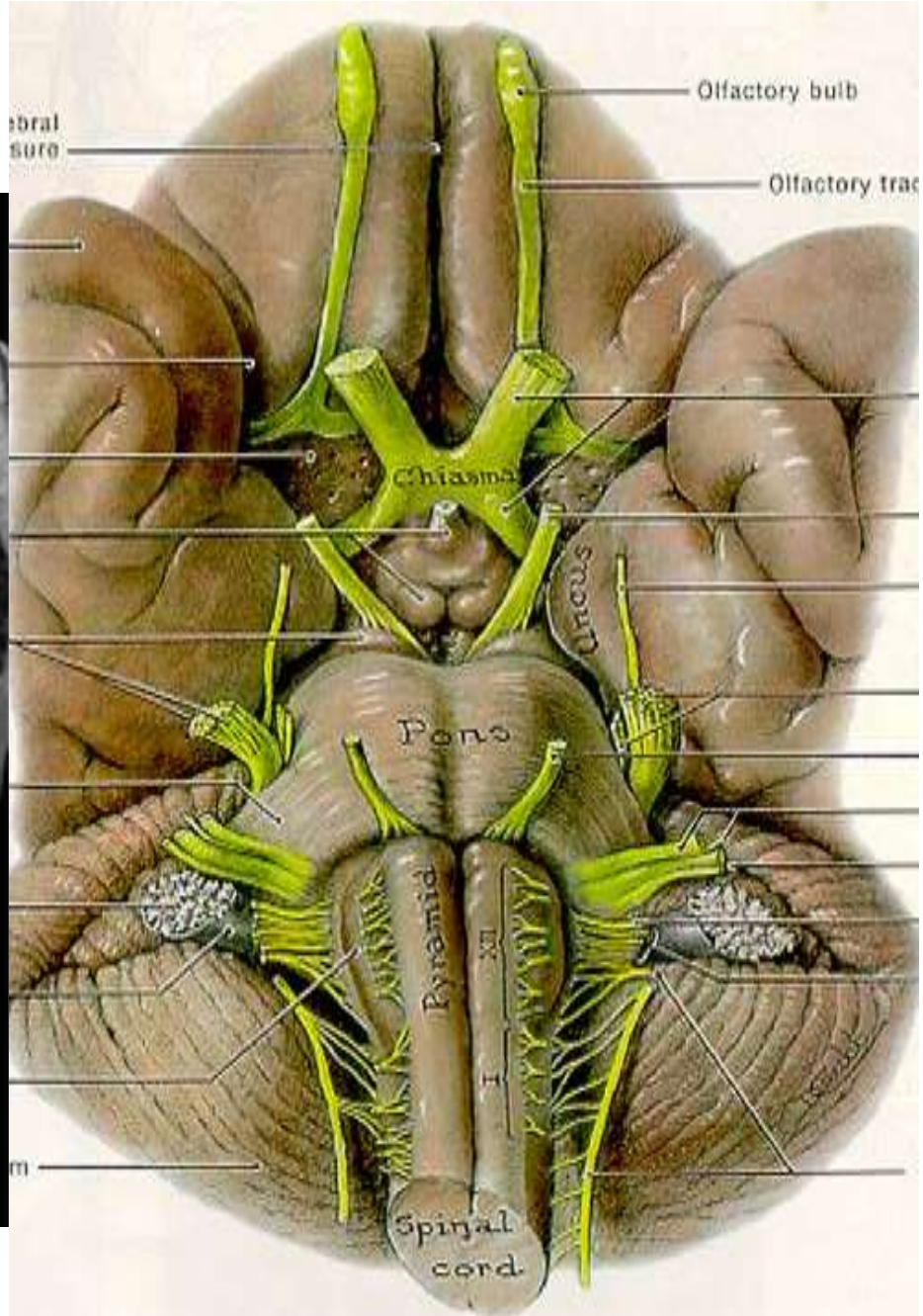
Olfactory bulb
Olfactory trac
Chiasma
Uncus
Pons
Pyramid
XI
H
Spinal
cord