Spinal cord

Veronika Němcová

řezy mozkem

Pavel Petrovický, Jiří Brabec

TRITON

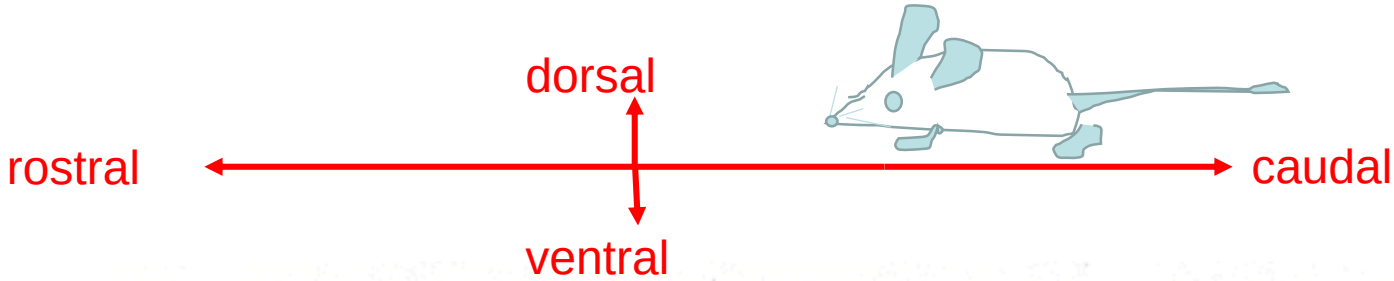
dorsal
rostral
caudal
ventral

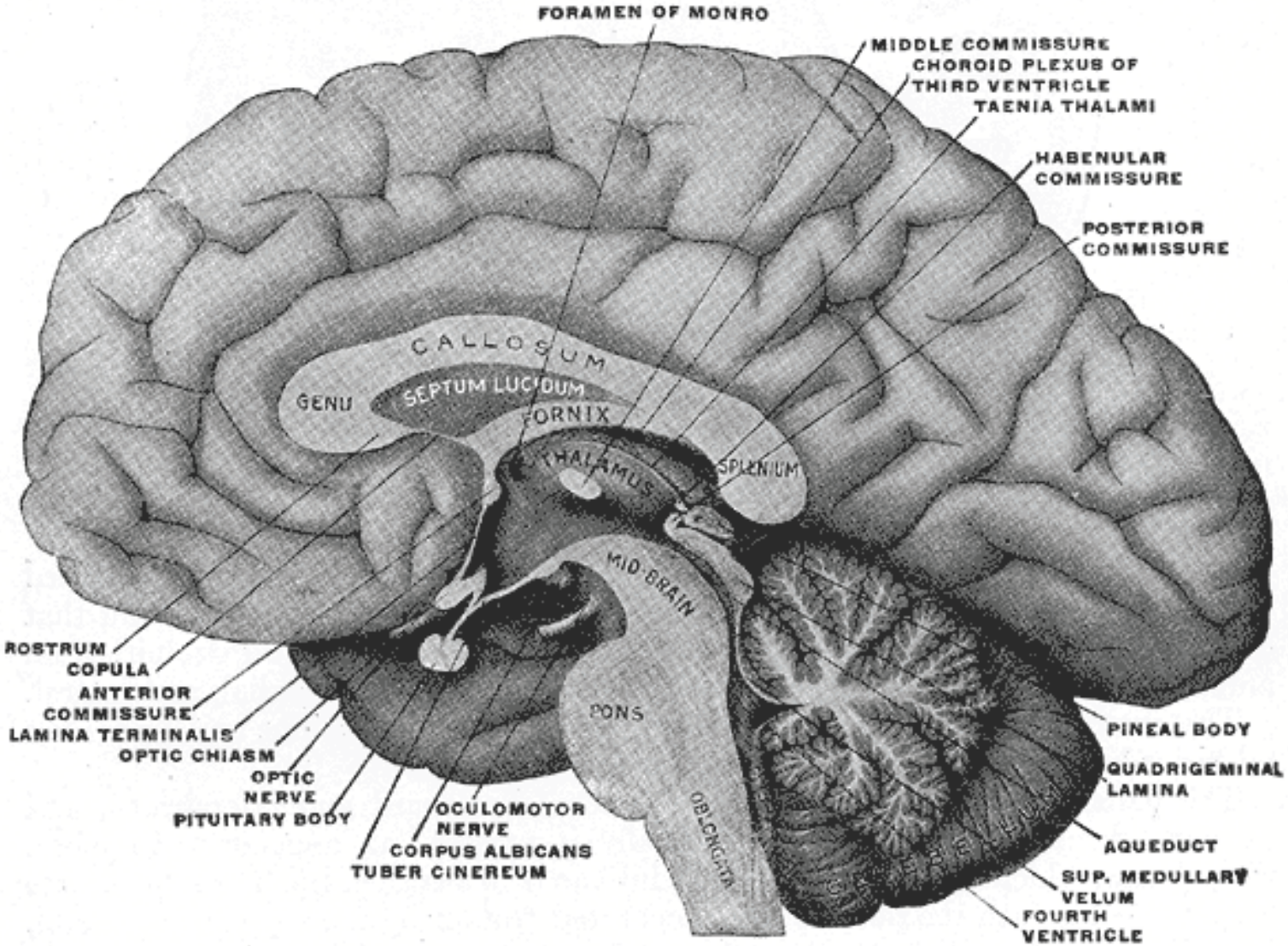
FORAMEN OF MONRO
MIDDLE COMMISSURE
CHOROID PLEXUS OF THIRD VENTRICLE
TAENIA THALAMI
HABENULAR COMMISSURE
POSTERIOR COMMISSURE
CALLOSUM
GENU
SEPTUM LUCIDUM
FORNIX
THALAMUS
SPLENIUM
MID-BRAIN
PONS
OBLONGATA
ROSTRUM
COPULA
ANTERIOR COMMISSURE
LAMINA TERMINALIS
OPTIC CHIASM
OPTIC NERVE
PITUITARY BODY
OCULOMOTOR NERVE
CORPUS ALBICANS
TUBER CINEREUM
PINEAL BODY
QUADRIGEMINAL LAMINA
AQUEDUCT
SUP. MEDULLARY VELUM
FOURTH VENTRICLE

Basic unit of NS

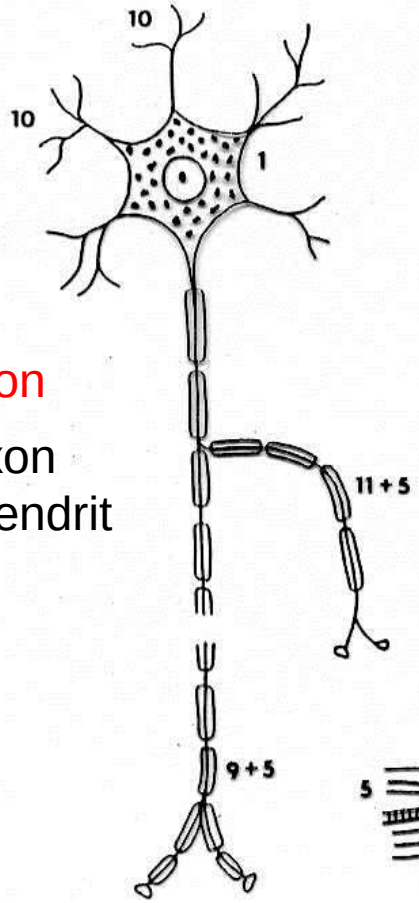

neuron

9- axon
10-dendrit

synapse

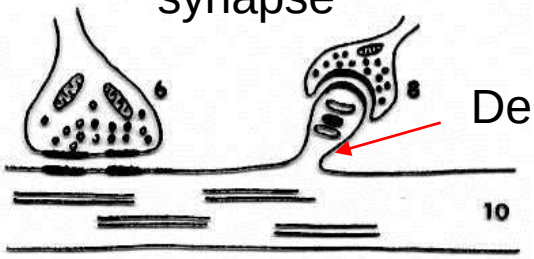

Dendritic spine

pia mater

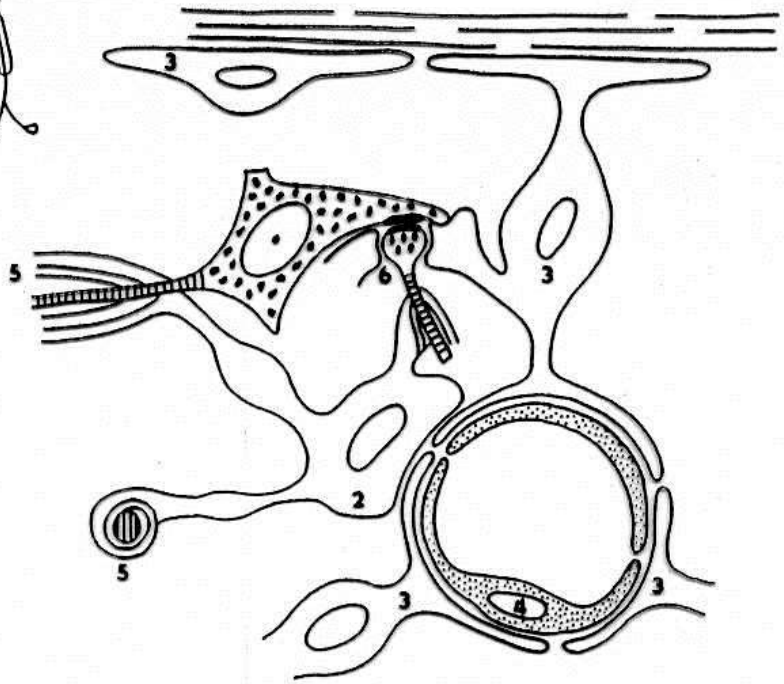

2 - oligodendroglie
3 - astrocytes
4 – capillary
5 – myelin sheat
11 – axon collateral

Obr. 1.:

ependyme – in ventricles

microglia -imunity

astrocyte

neuron

microglie

astrocyte –

pia mater

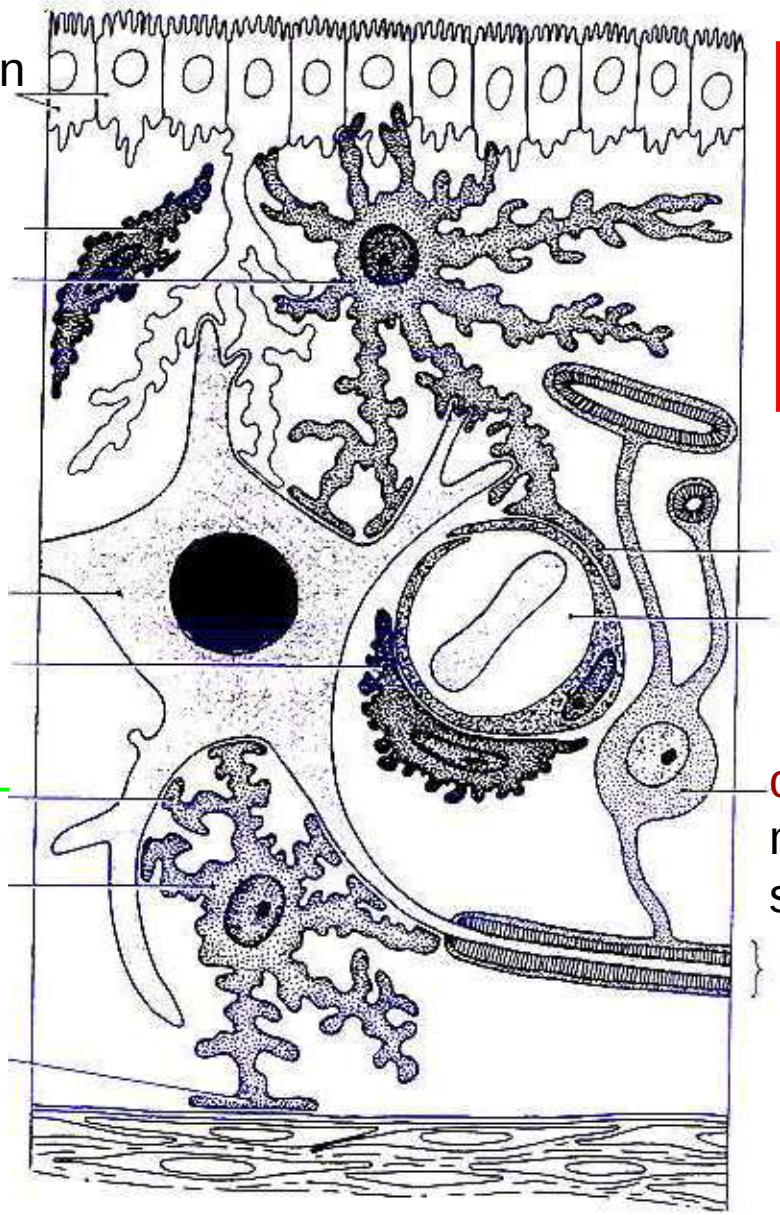

capillary

oligodendrocyte makes a myelin sheath

Axon with myelin sheath

1) Neurony
2) Glia – supporting cells
   astrocyty
   oligodendrocyty
   microglia
3) Ependyme

Neuron:glie
1:10?
1:1!

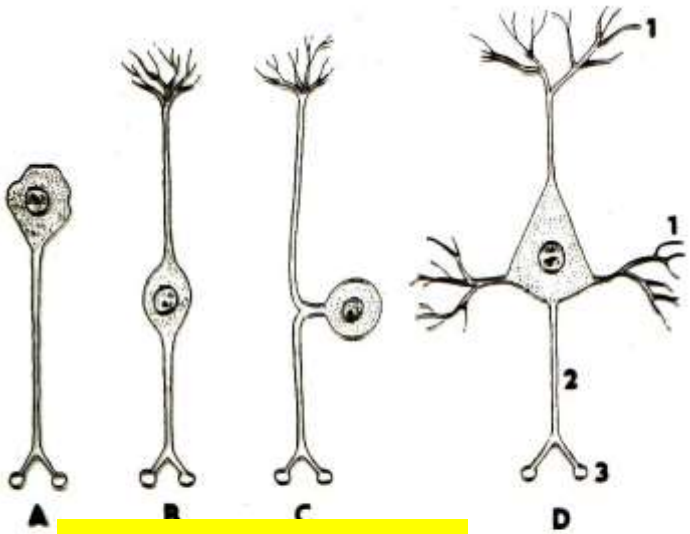

Types of neurons

A – unipolární,
B – bipolární,
C – pseudounipolární,
D – multipolární.

1 – dendrit,
2 – axon,
3 – axonální zakončení (bouton).

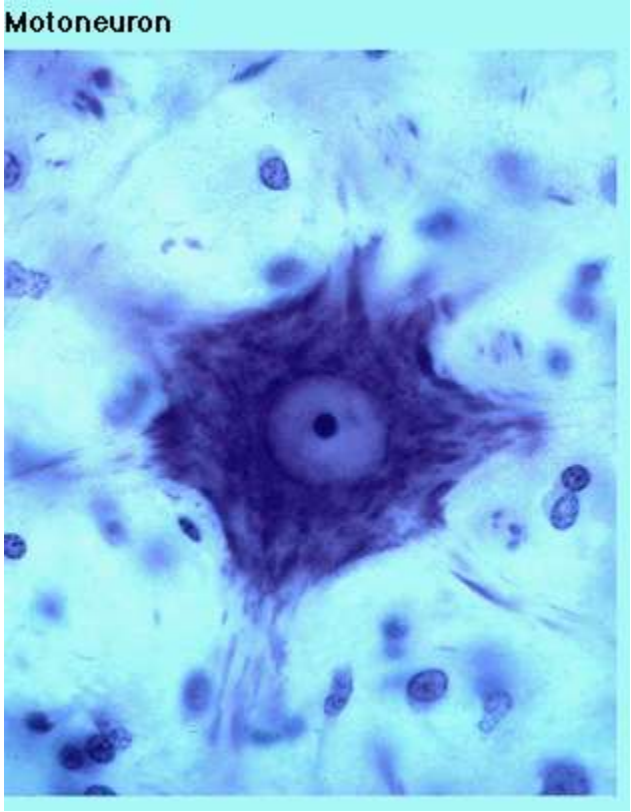

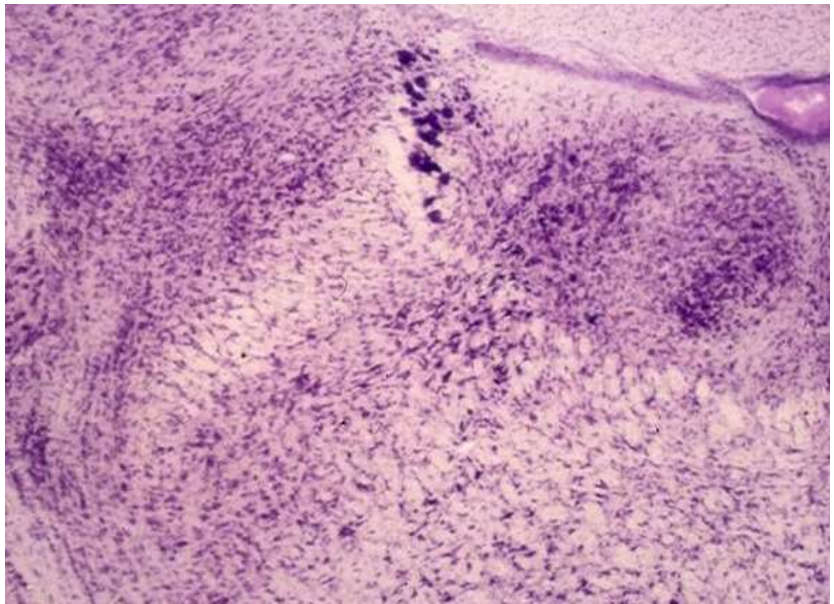

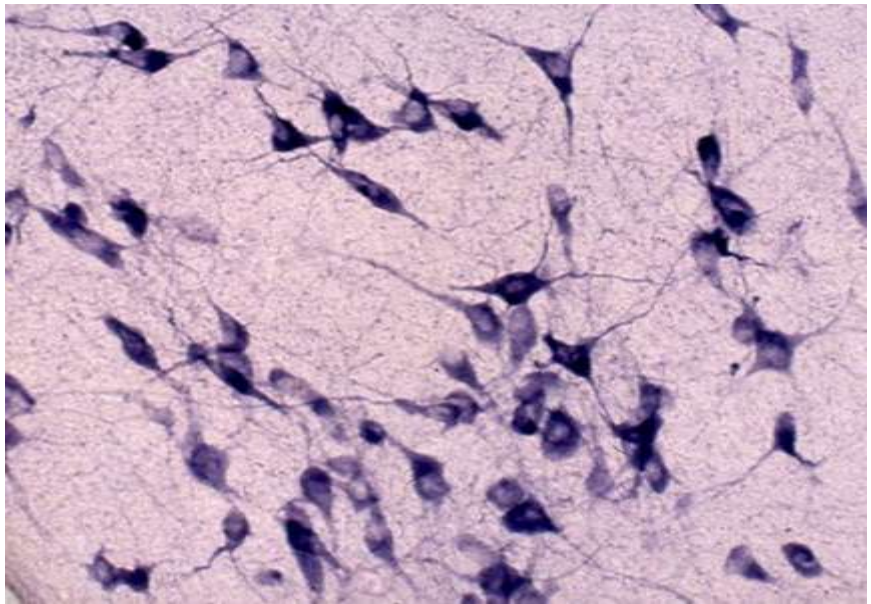

Nissl staining- cresylviolet rough ER

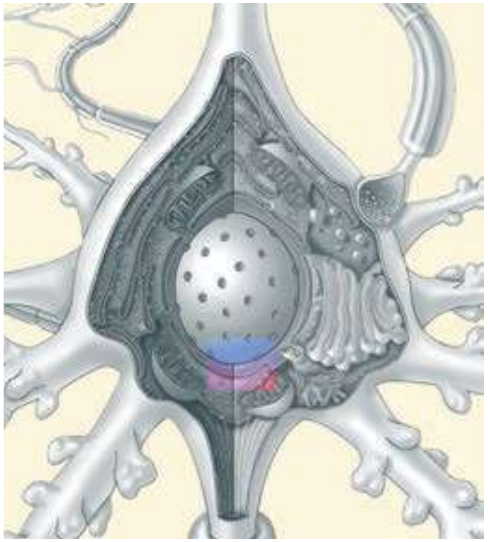

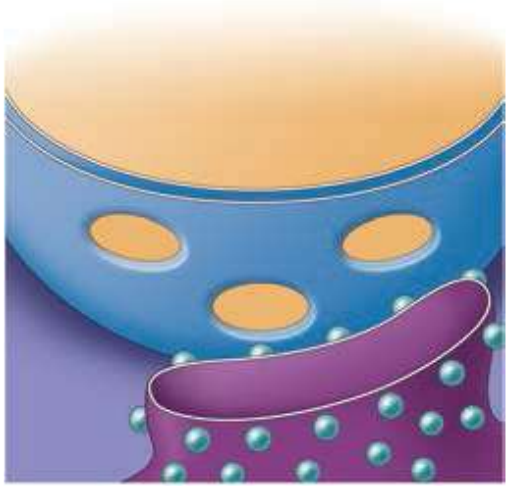

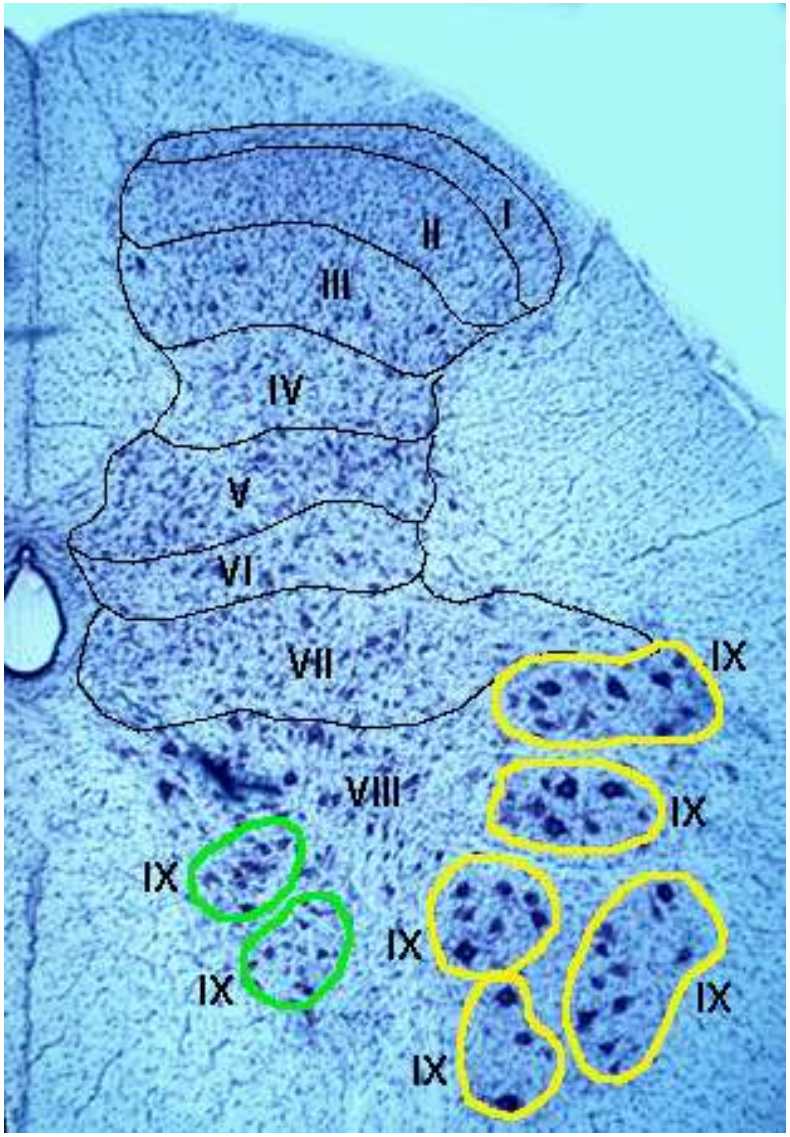

Grey matter of spinal cord

Dendrites

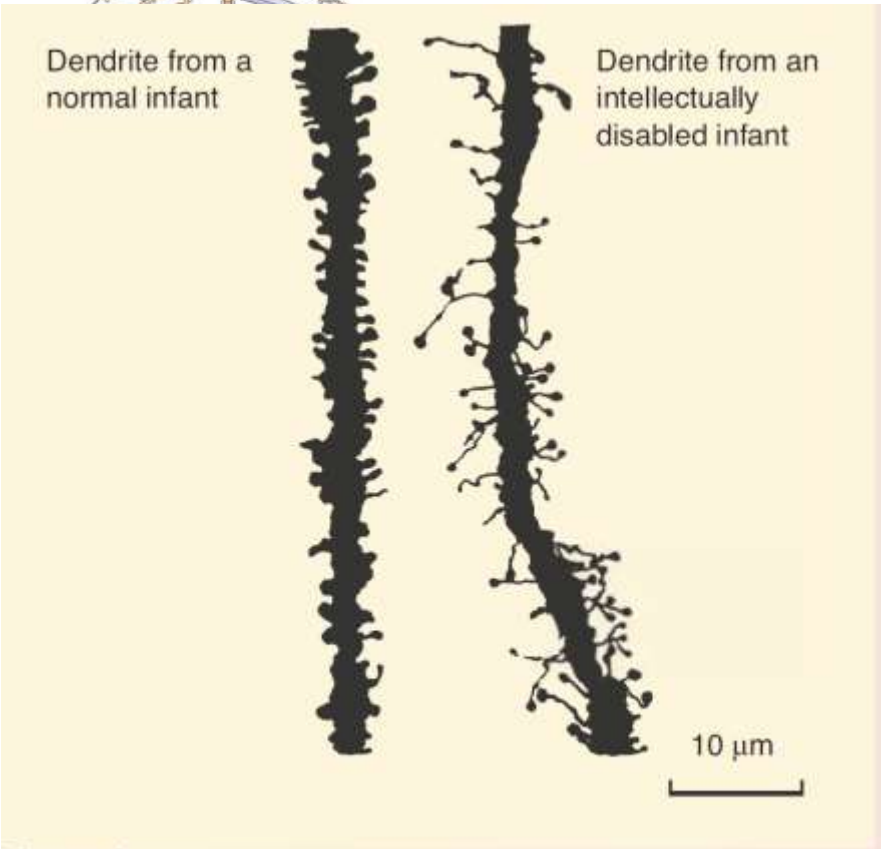

Figure A
Normal and abnormal dendrites. (Source: Purpura, 1974, Fig. 2A.)

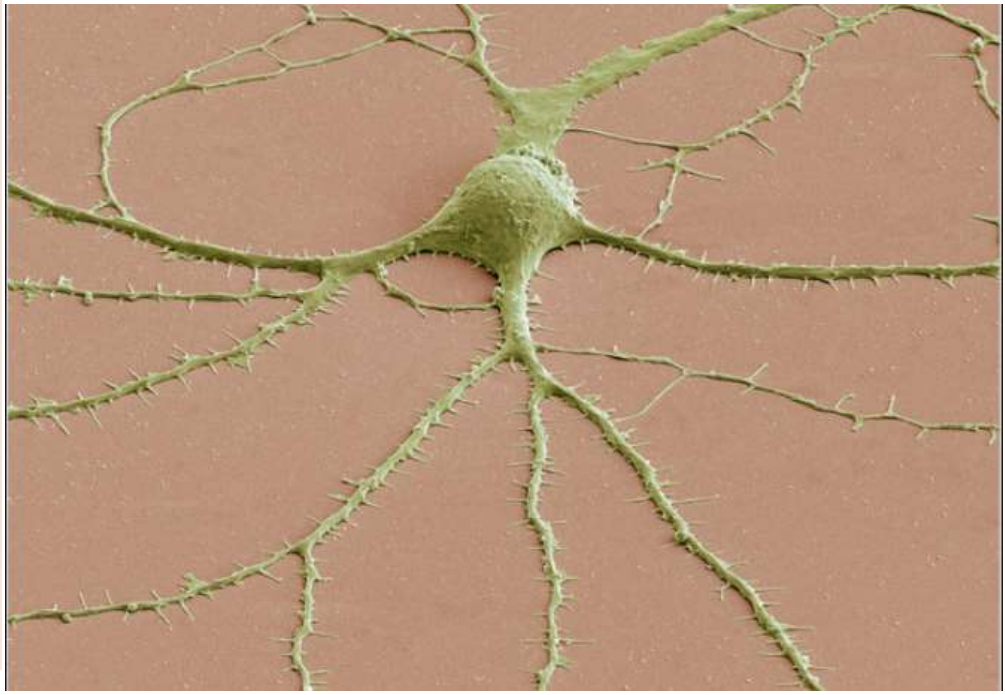

Axon

no ER

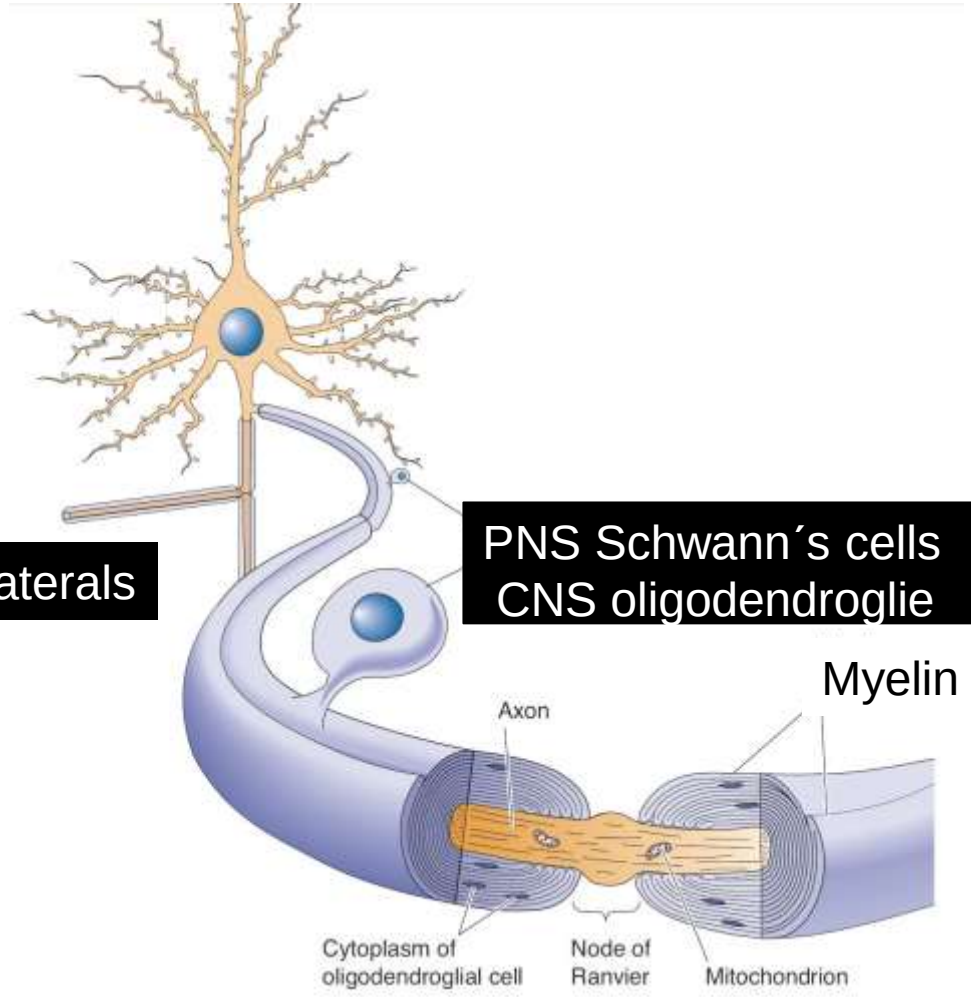
collaterals
PNS Schwann´s cells
CNS oligodendroglie
Myelin sheath
Axon
Cytoplasm of
oligodendroglial cell
Node of
Ranvier
Mitochondrion

Myelinized and nonmyelinized fibers

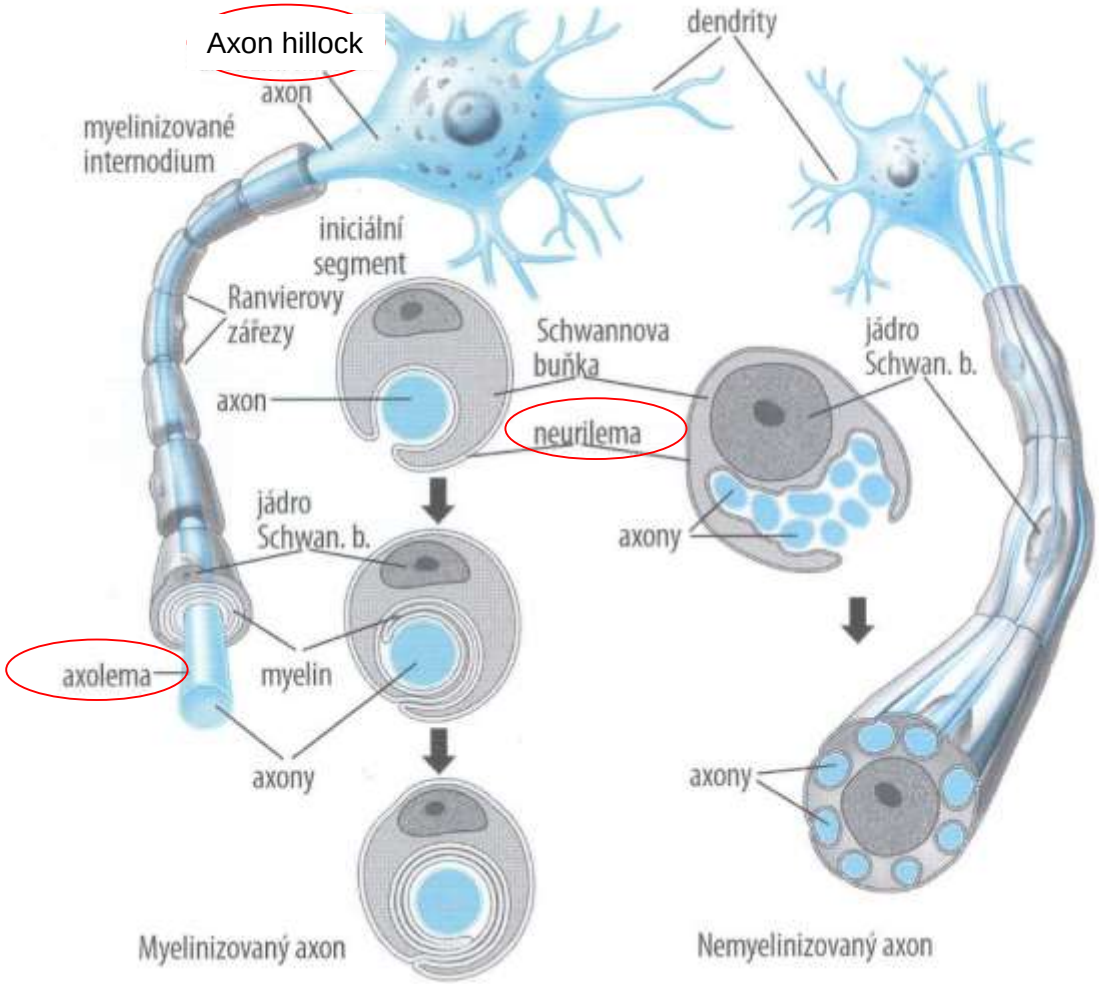

fast slow

Cytoskelet

shape and transport

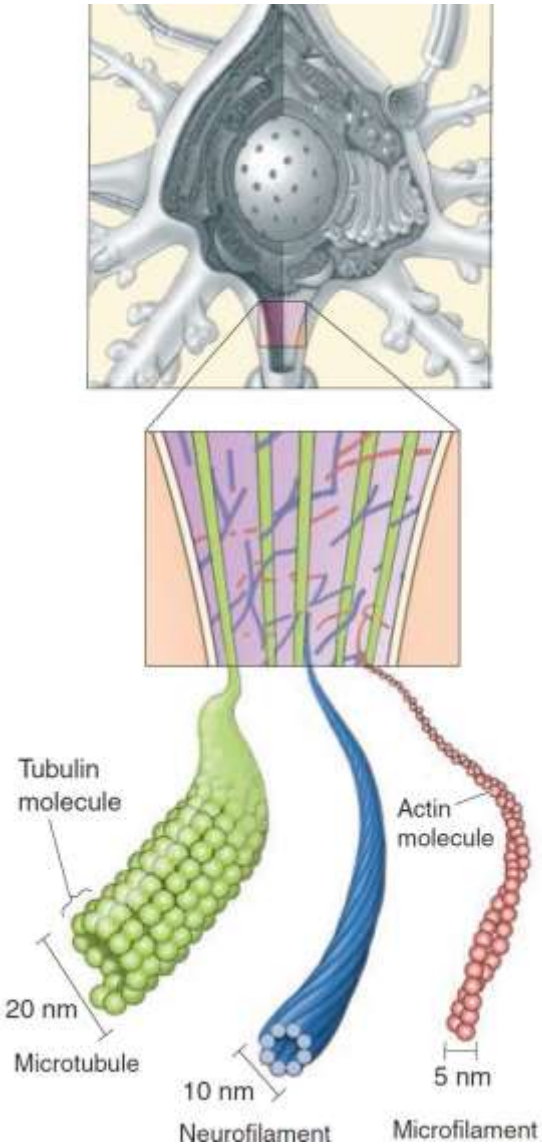

Axonal transport

Anterograde – kinesin
Retrograde -dynein

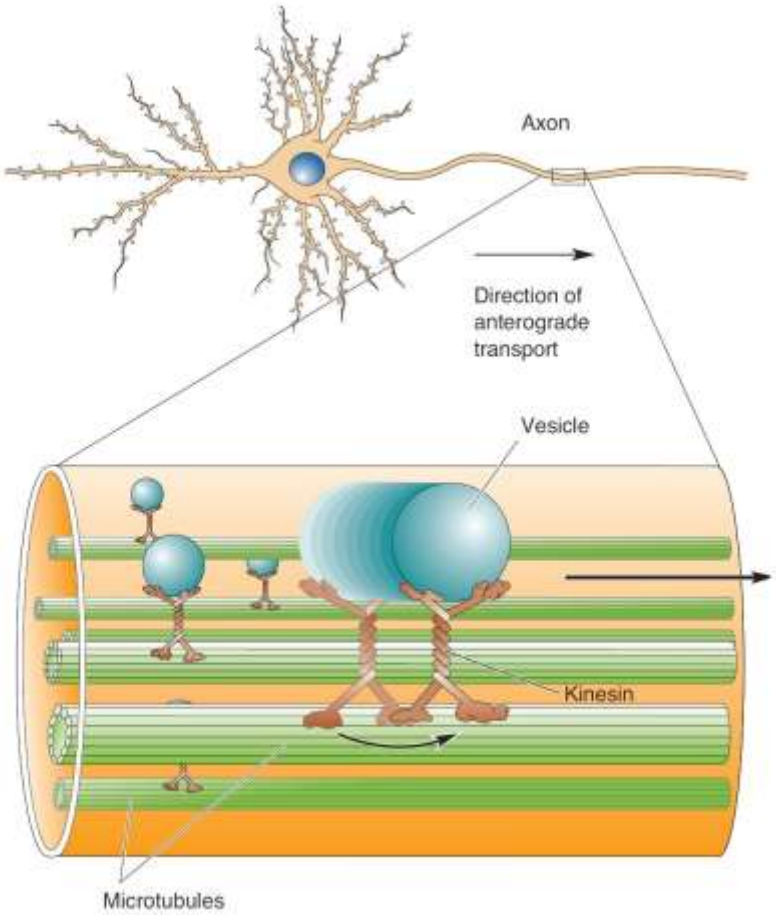

Axonal transport on microtubules

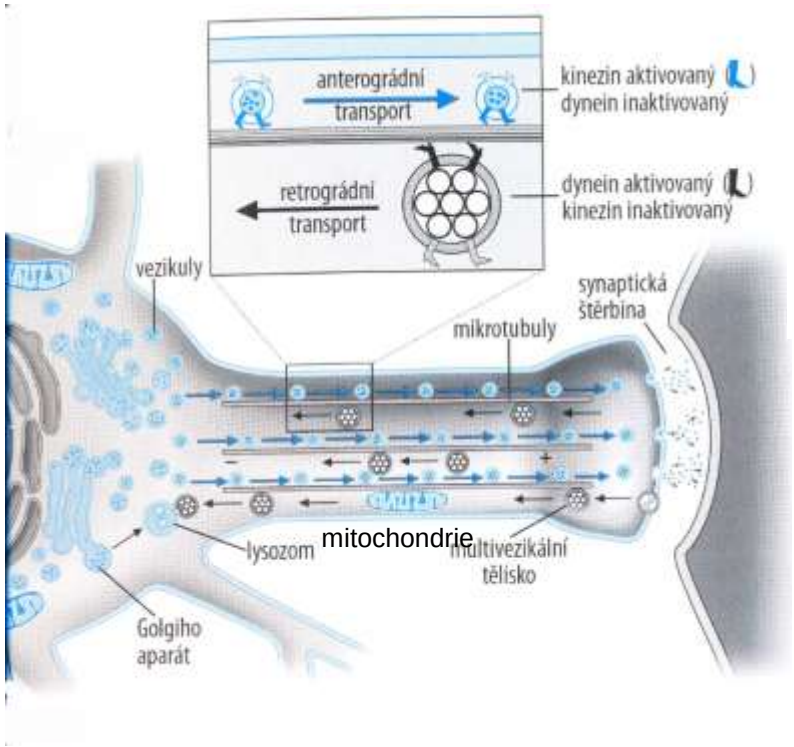

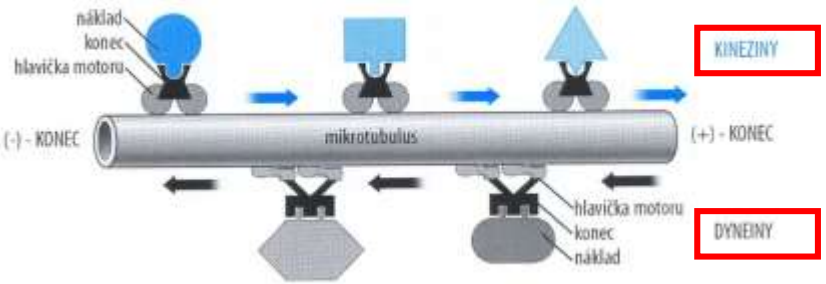

Slow anterograde 1mm/day – building proteins
Fast anterograde 300mm/day – enzymes and neurotransmitters
Retrograde 200mm/day – chemicals from synaptic cleft, NFG
(Nerve Growth Factor)

Tract tracing studies

Retrograde labelling

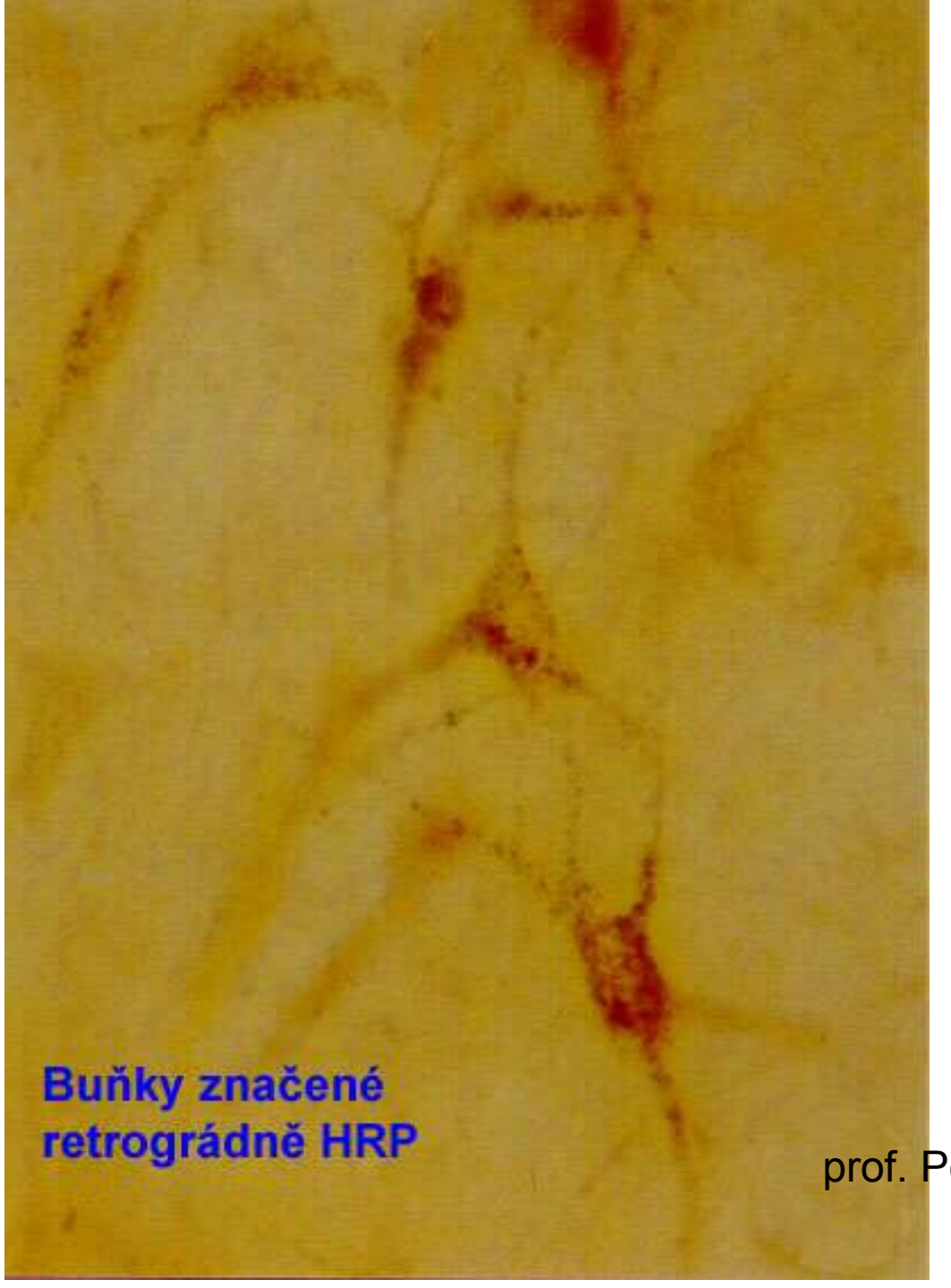

prof. Petrovický

Buňka značená retrográdně dextranferem

Retrograde labelling

prof. Petrovický

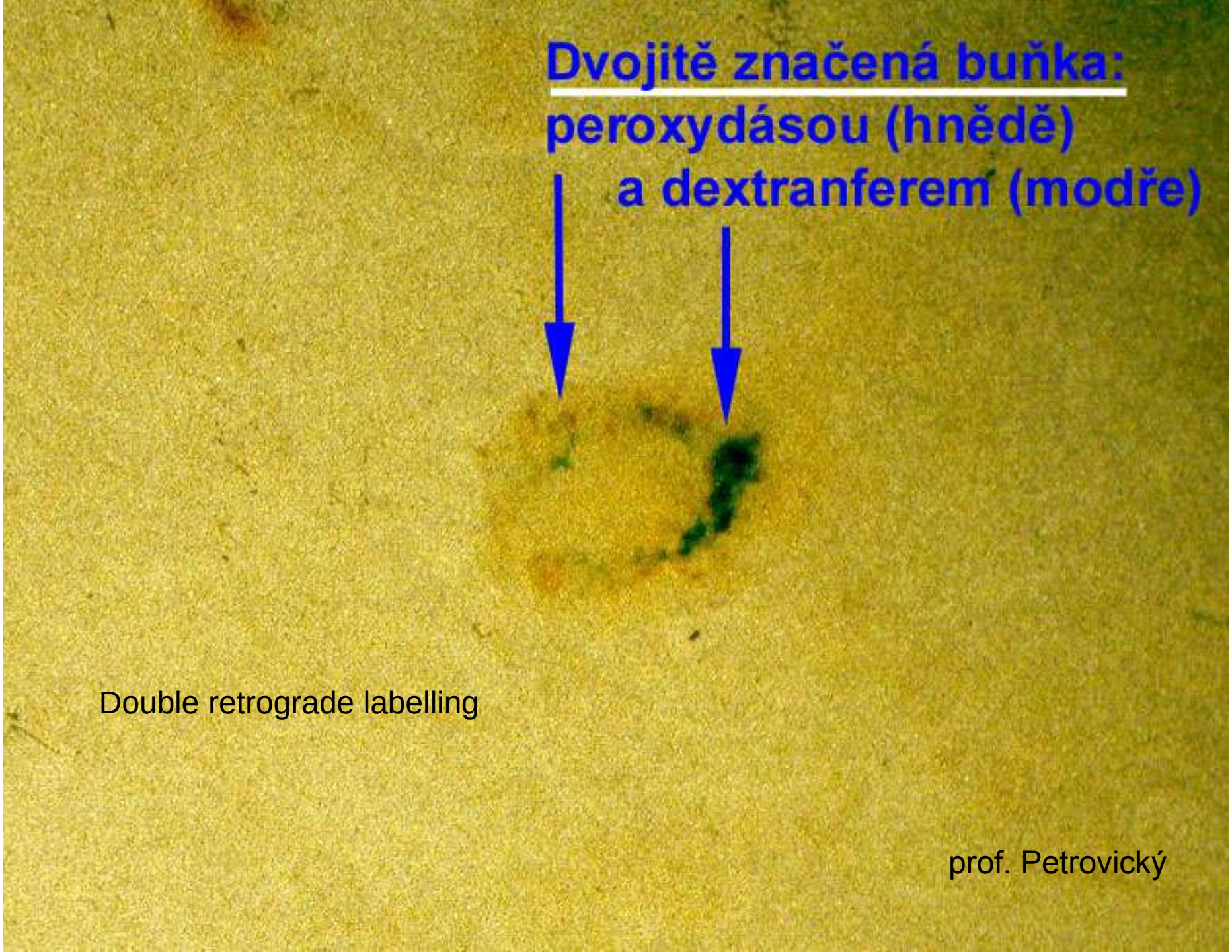

Double retrograde labelling

prof. Petrovický

7000 synapses on 1 neuron

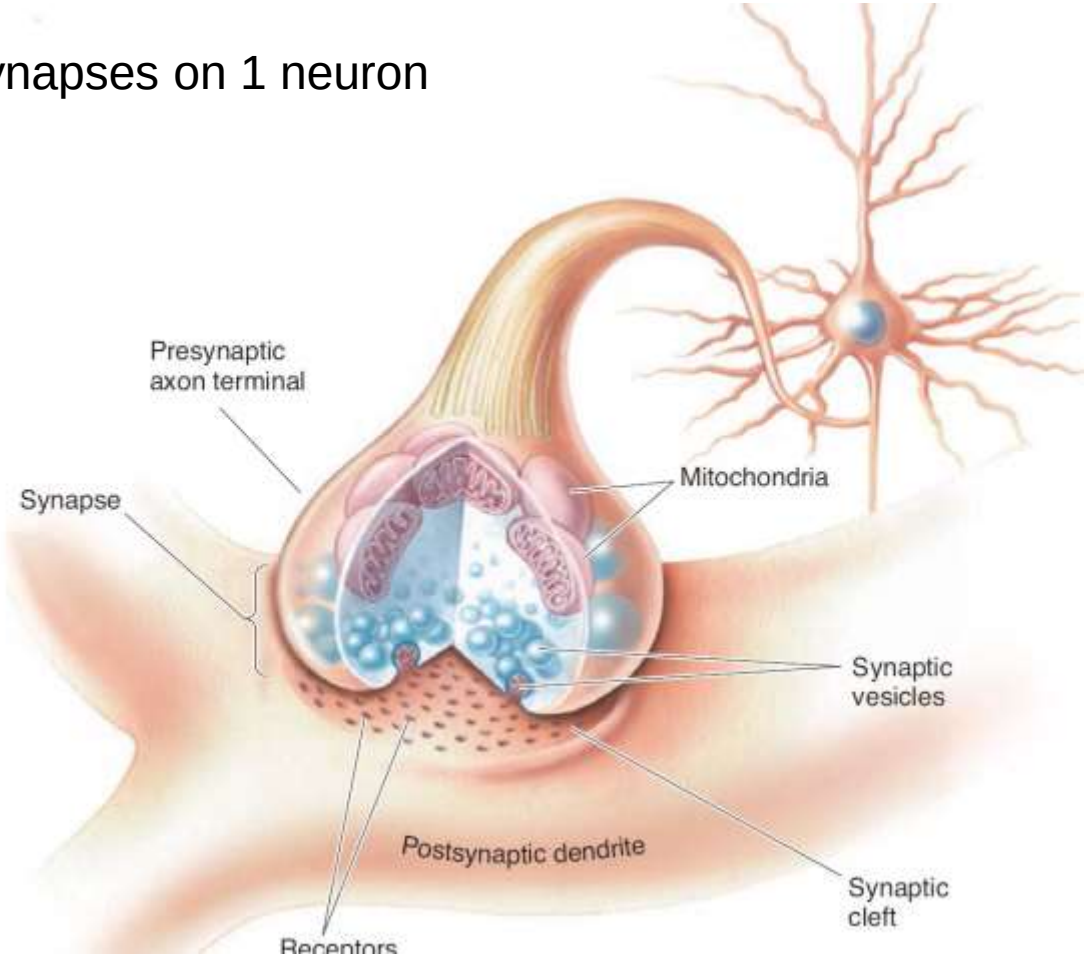

Neurotransmiters

Biogennic amines

Adrenaline, noradrenaline, dopamine

Serotonine

Acetylcholine

Histamine

Aminoacids

Glutamate, aspartate– excitatory (e.g. in spinal ganglion)

GABA, glycin – inhibitory (e.g Renshaw´s cells – spinal cord interneurons

Nukleotides

Adenosine

Neuropeptides

Substance P, VIP, somatostatin, cholecystokinin

Gas - NO, CO

Dopamine
Noradrenaline
Adrenaline

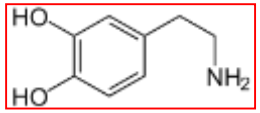

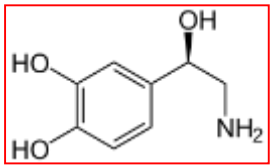

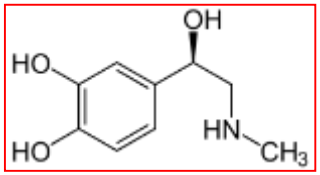

Serotonine

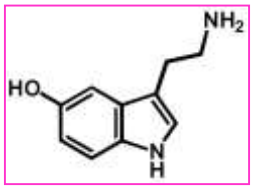

NEUROTRANSMITTERS

Acetylcholine

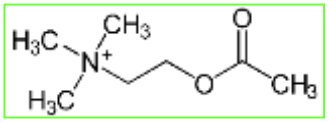

Histamine

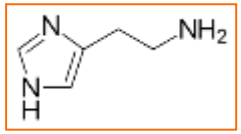

GABA

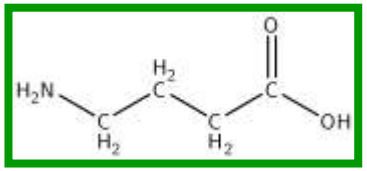

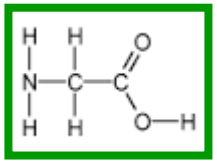

Glycine

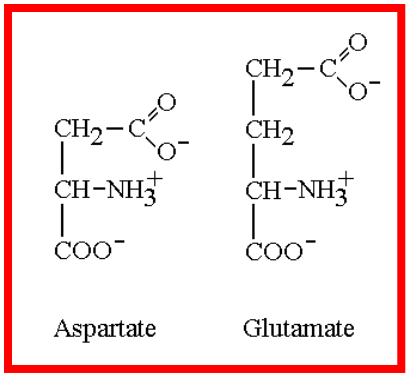

Adenosine

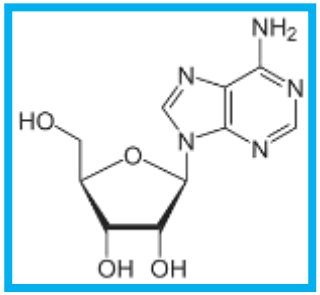

coffein- block of receptors for adenosine

Neural tube and neural crest formation - 3.-4. week

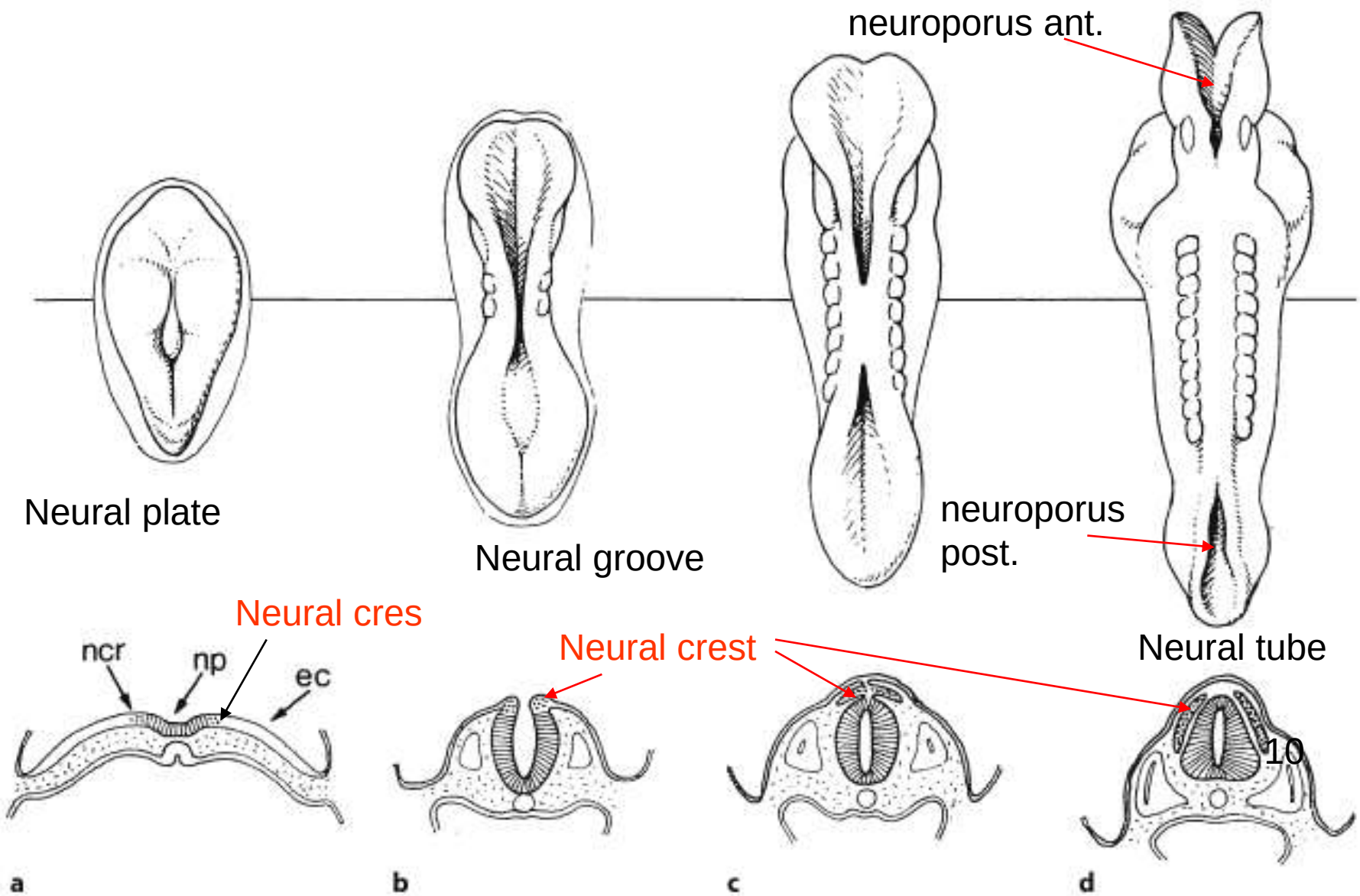

Neural tube and neural crest formation

Neural plate
3. week

Neural groove

Neural crest

Nerval tube

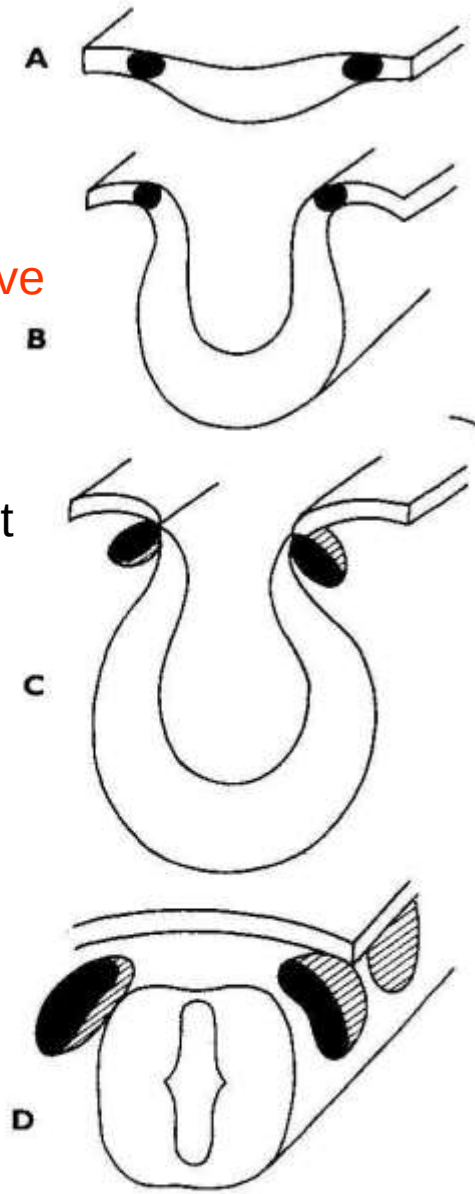

Sensory ganglia

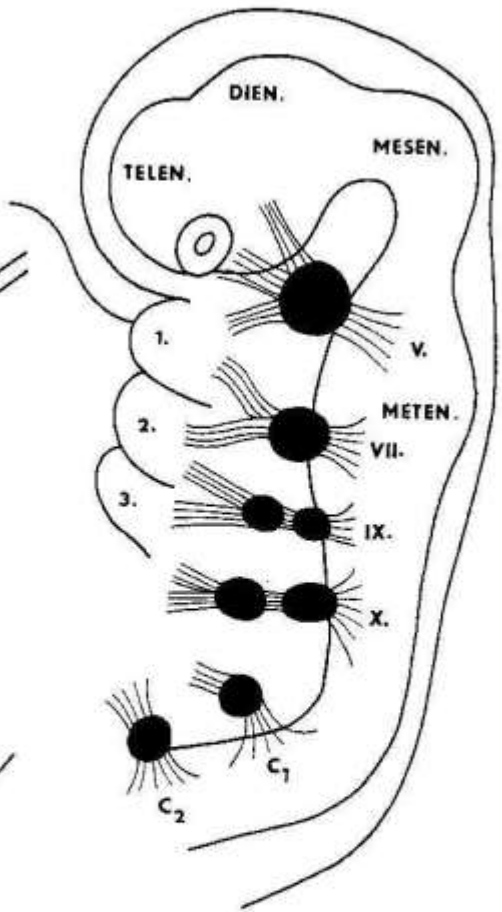

Brain development

Primary

1) prosencephalon
   mesencephalon
   rhombencephalon

Secondary

2) telencephalon
   diencephalon
   mesencephalon
   metencephalon
   myelencephalon

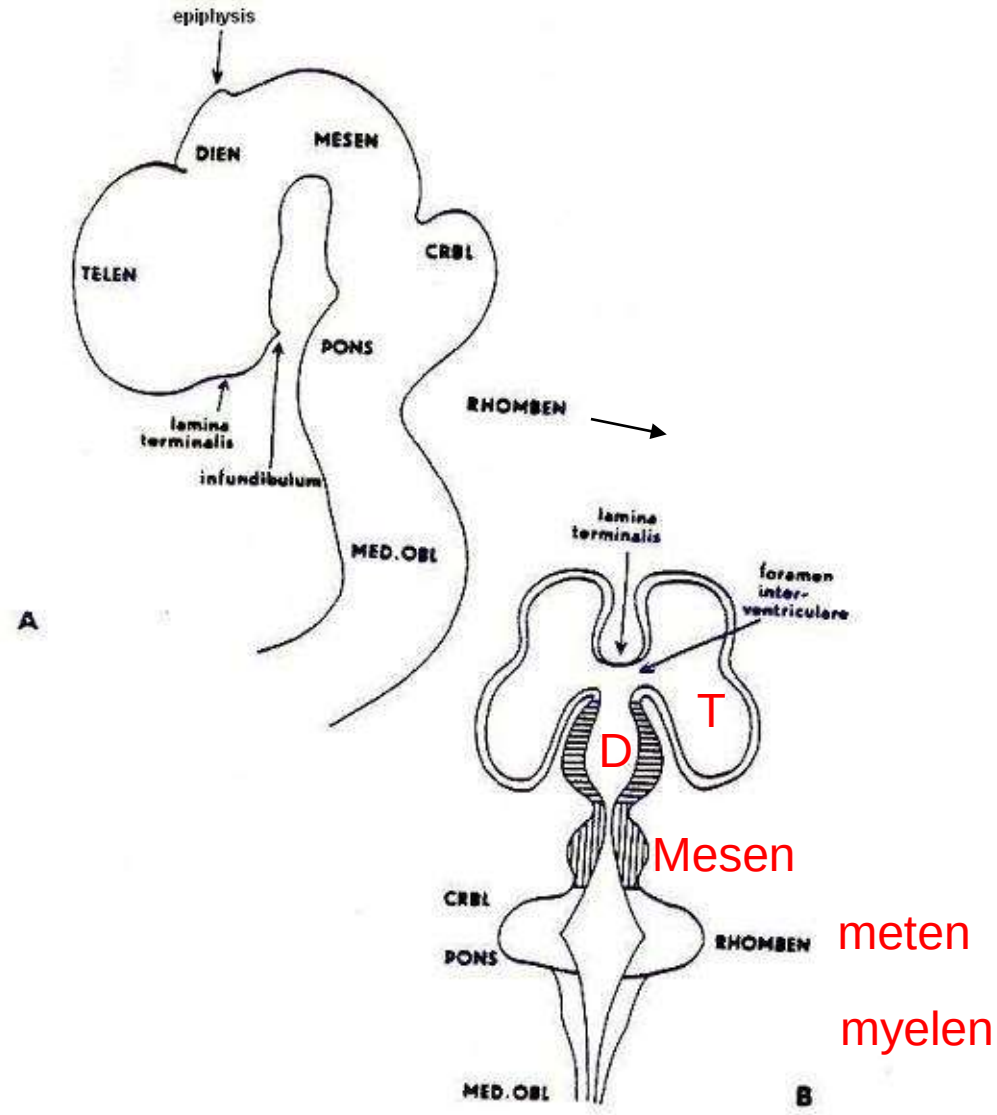

Obr. 13.: Sagitální řez mozkem embrya délky 7 mm (A) a schema rozdělení embryonálního mozku v horizontálním řezu (B). V obr. B je příčně šrafován diencephalon, vertikálně mesencephalon.

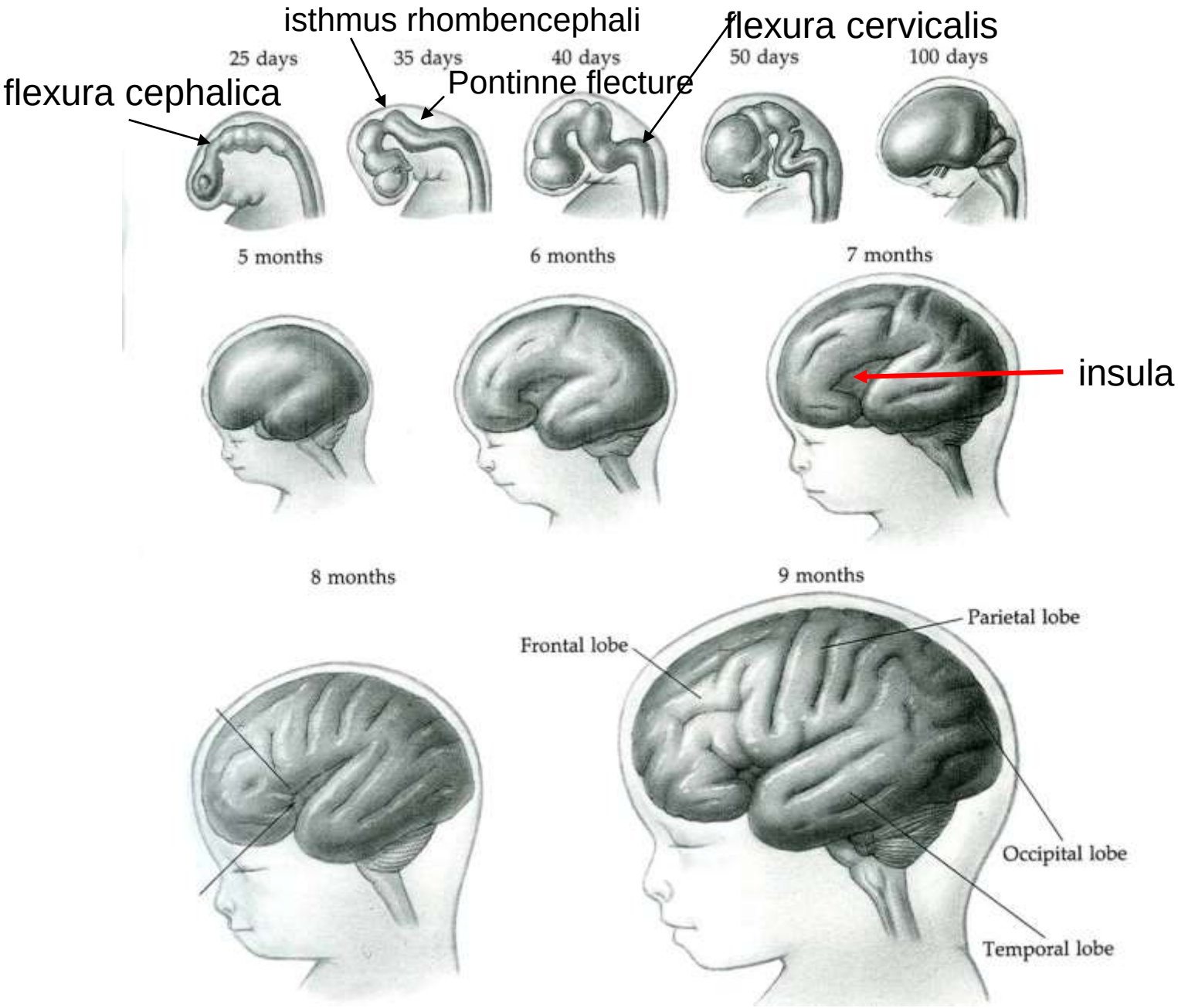
isthmus rhombencephali
flexura cervicalis
flexura cephalica
Pontinne flecture
25 days
35 days
40 days
50 days
100 days
5 months
6 months
7 months
insula
8 months
9 months
Parietal lobe
Frontal lobe
Occipital lobe
Temporal lobe

Brain development

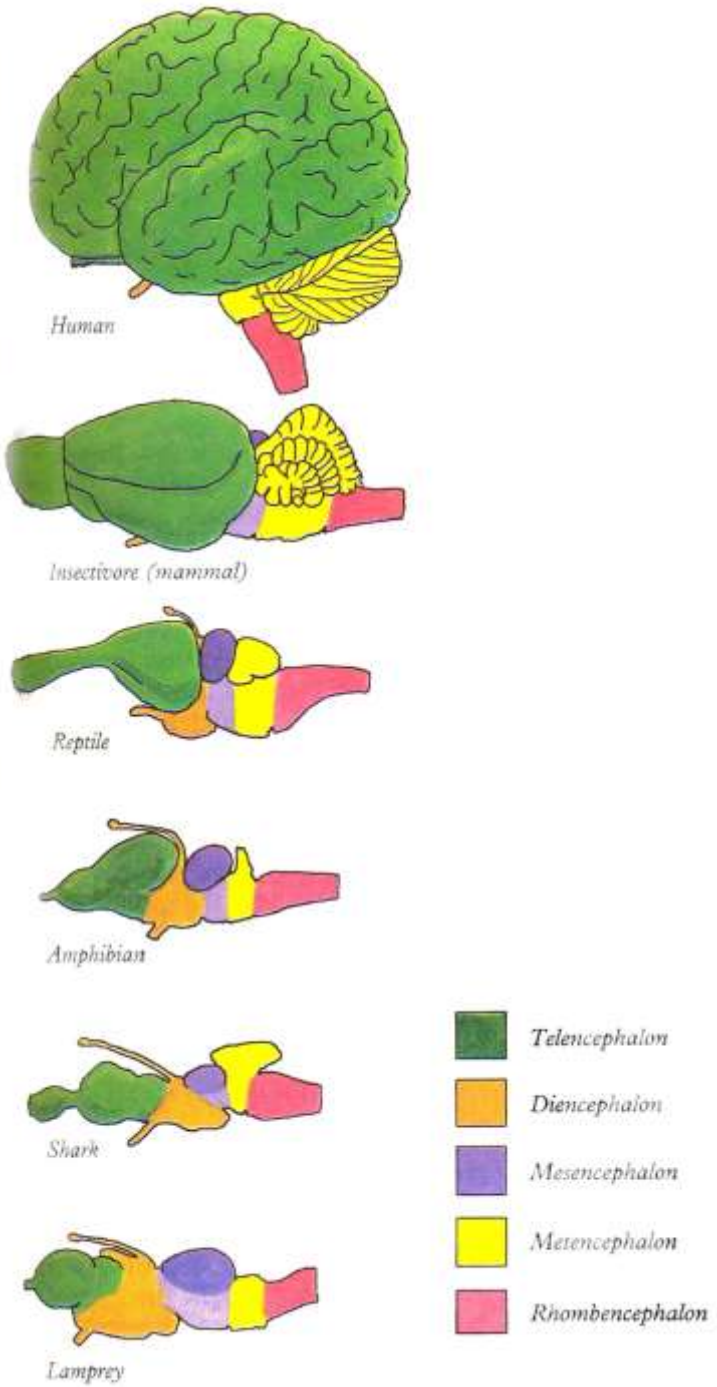

A

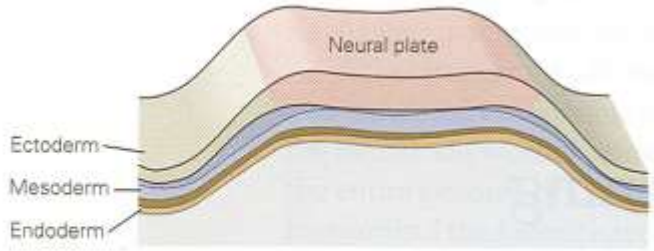
Neural plate
Ectoderm
Mesoderm
Endoderm

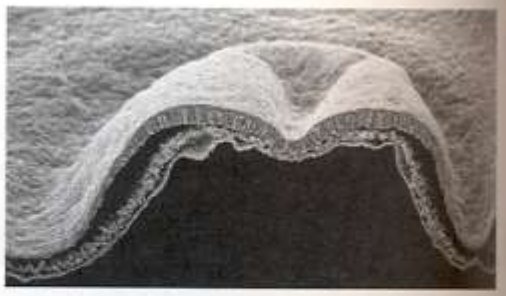

B

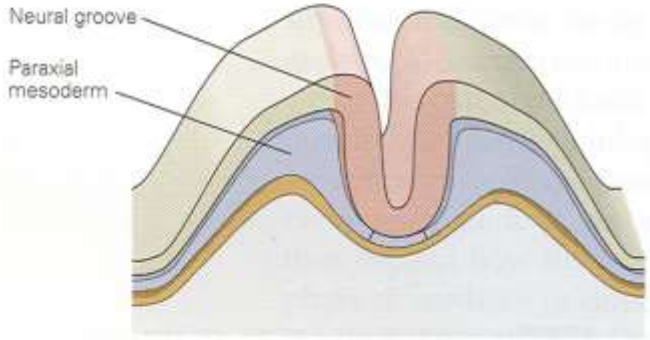
Neural groove
Paraxial mesoderm

C

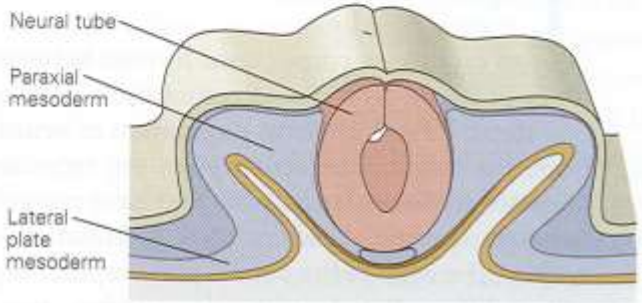
Neural tube
Paraxial mesoderm
Lateral plate mesoderm

D

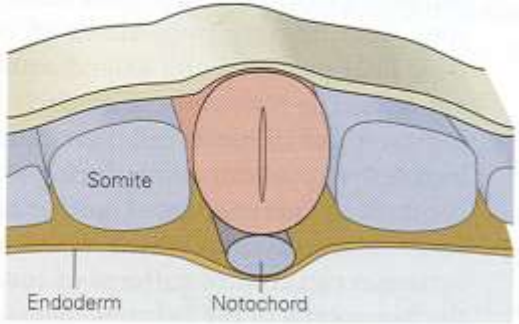
Somite
Endoderm
Notochord

Factors influencing the formation of dorsal (**bone morphogenetic proteins, *BMPs)*** and ventral (**sonic hedgehog, *SHH***) parts of spinal cord

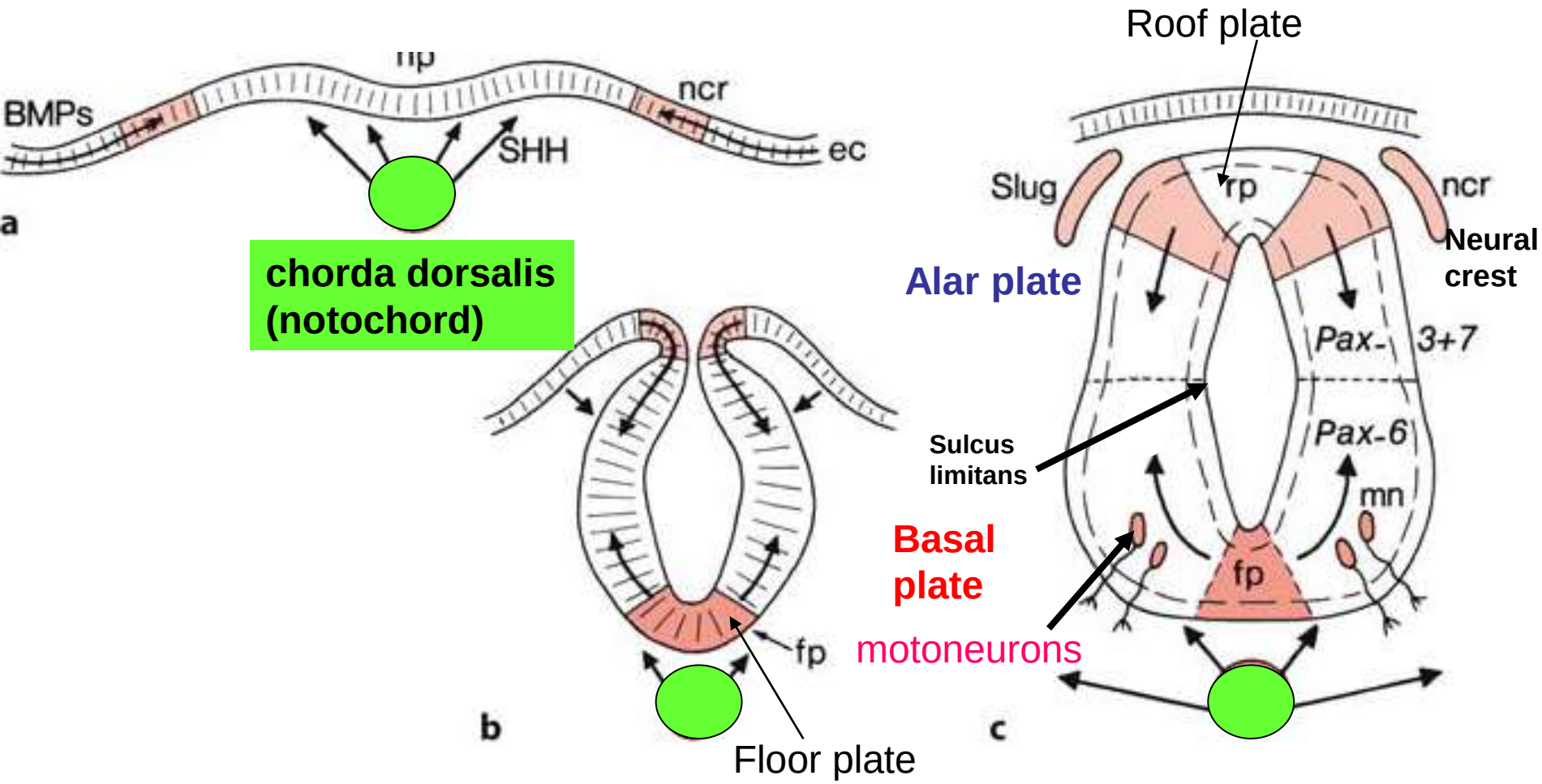

Basal and alar plate development in spinal cord

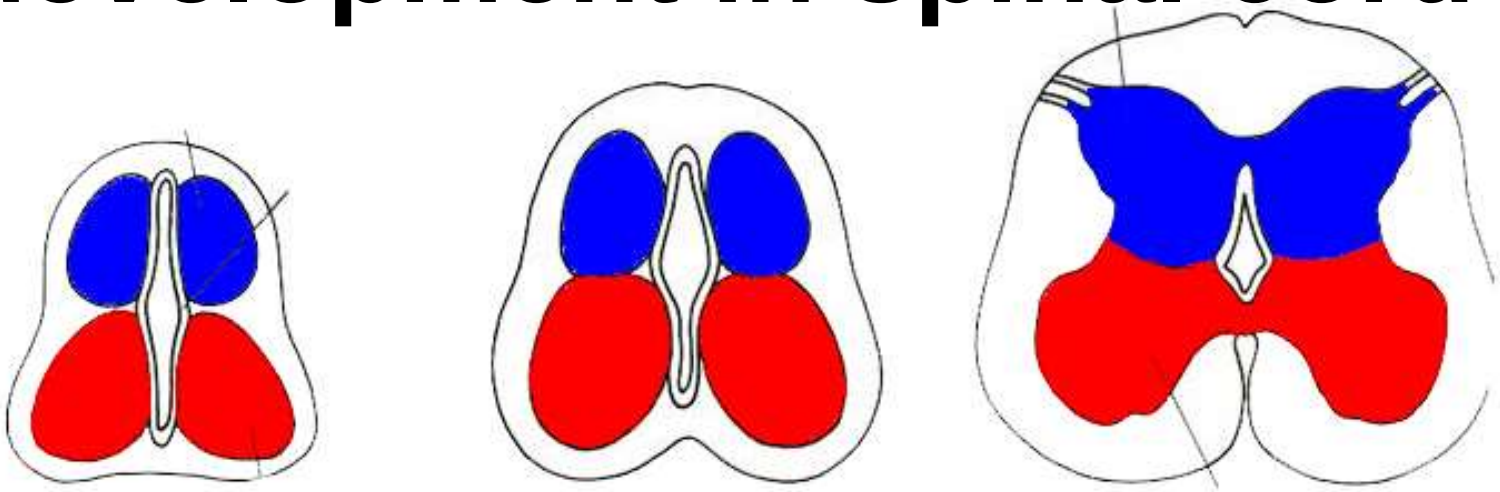

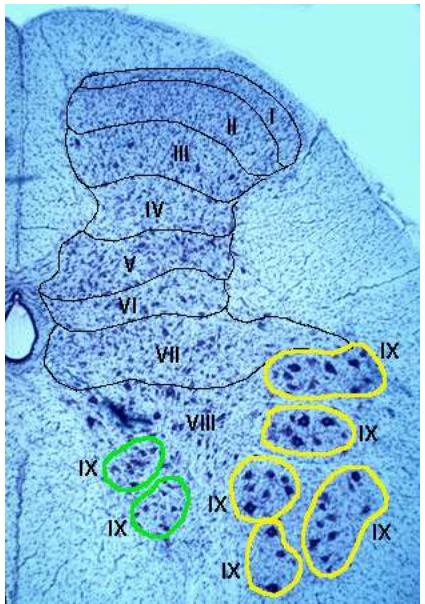

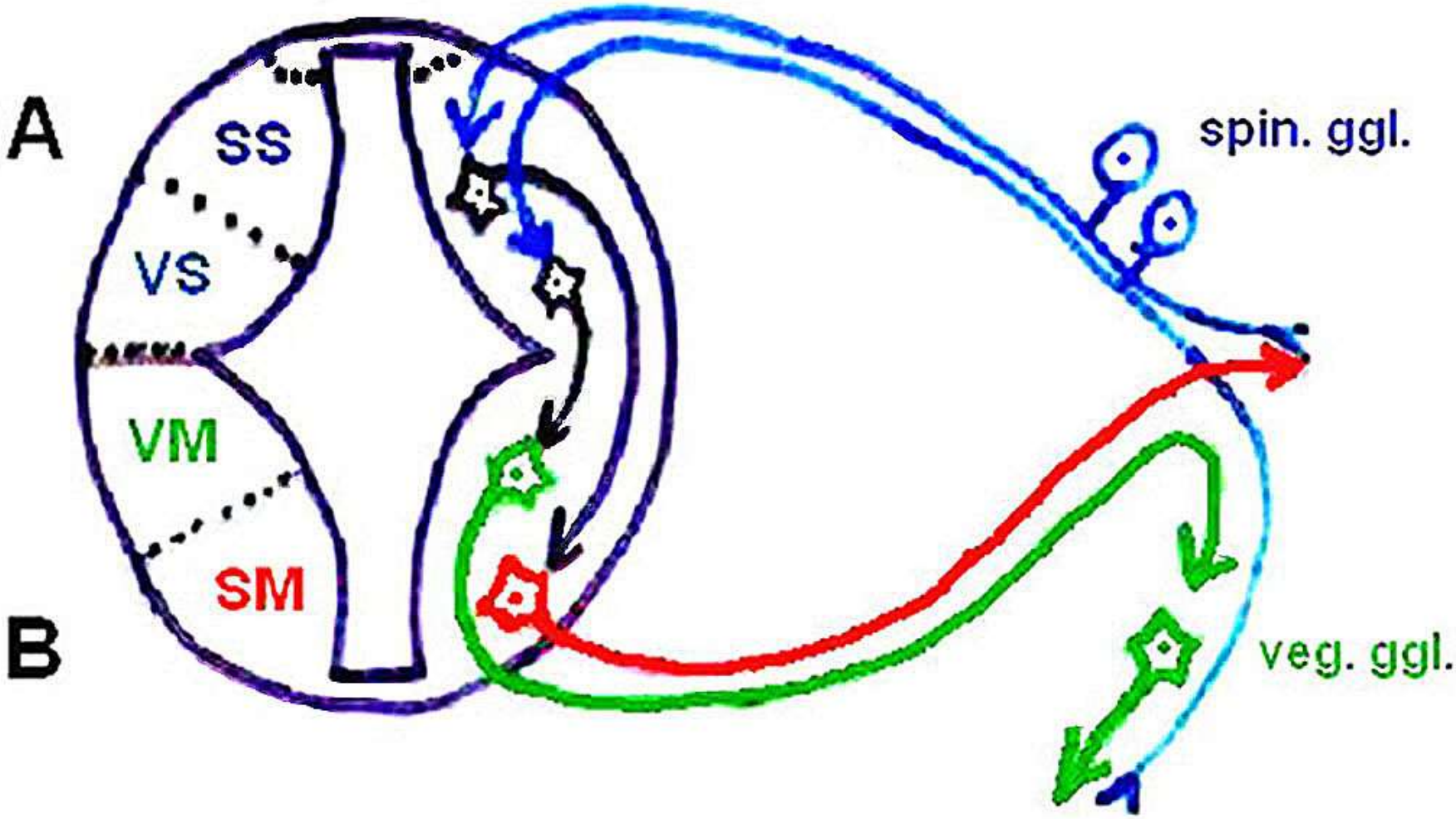
A
SS
VS
VM
SM
B
spin. ggl.
veg. ggl.

Sagittal section through th vertebral canal

foramen magnum
hiatus sacralis

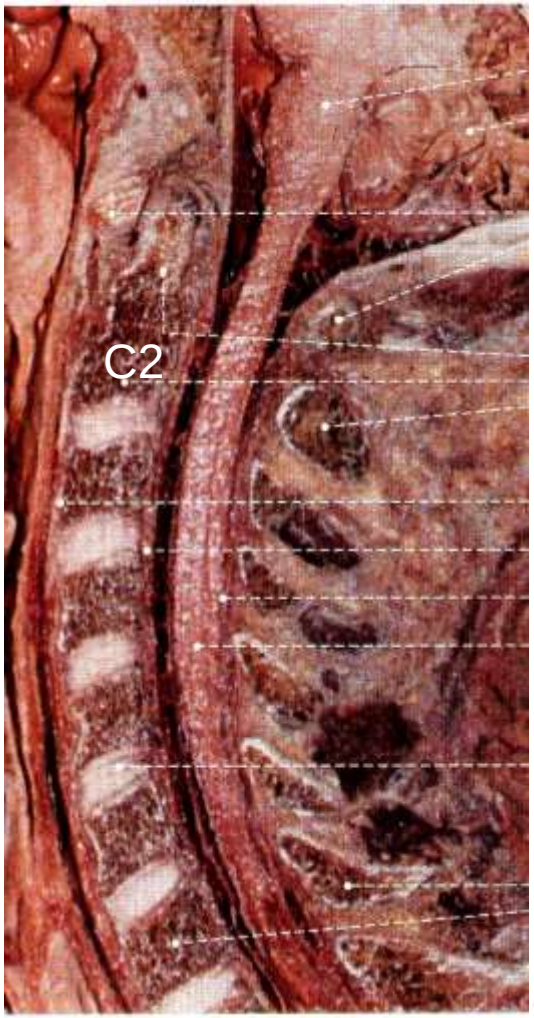

Borders of vertebral canal

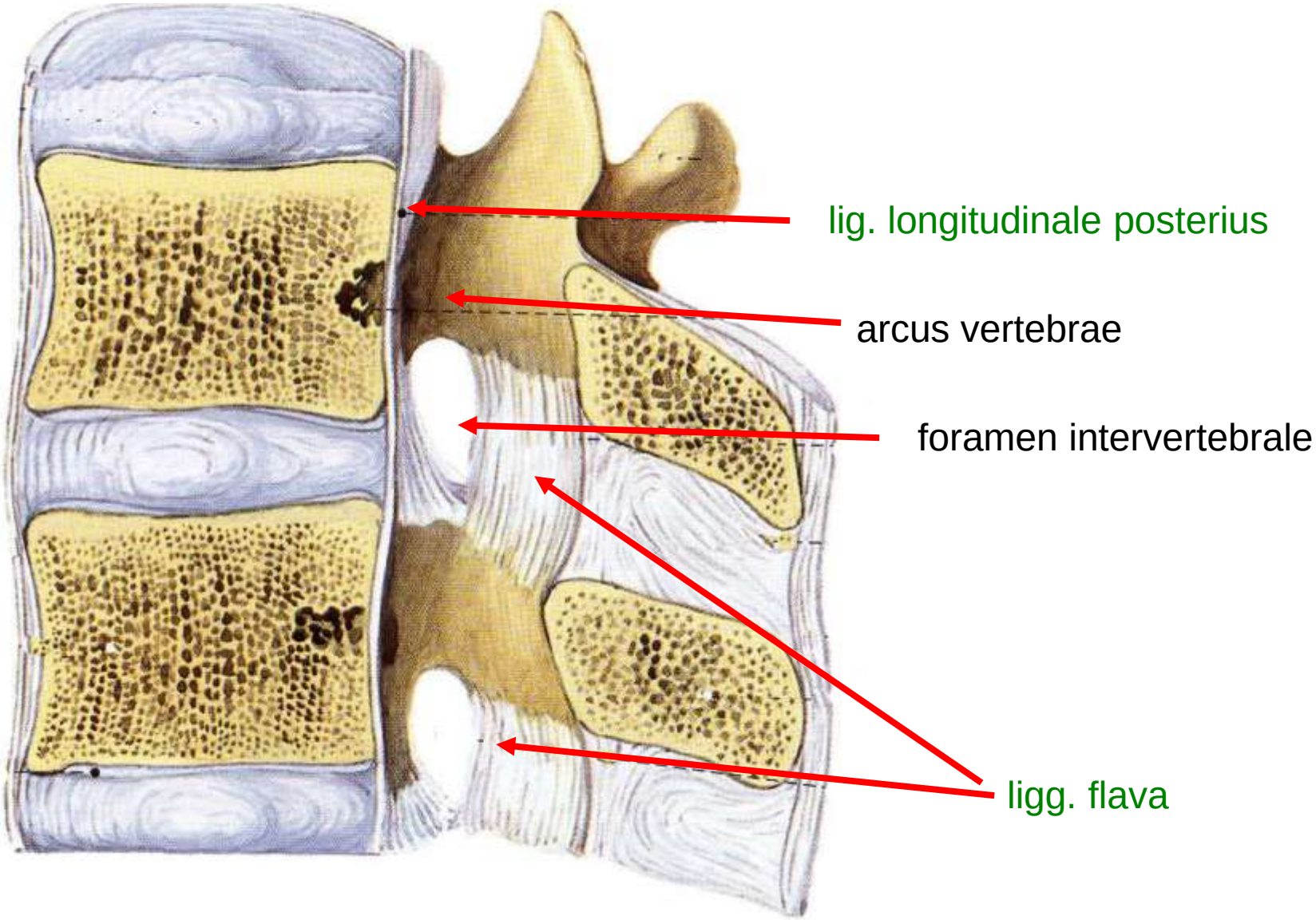

Spinal nerve and vertebral canal

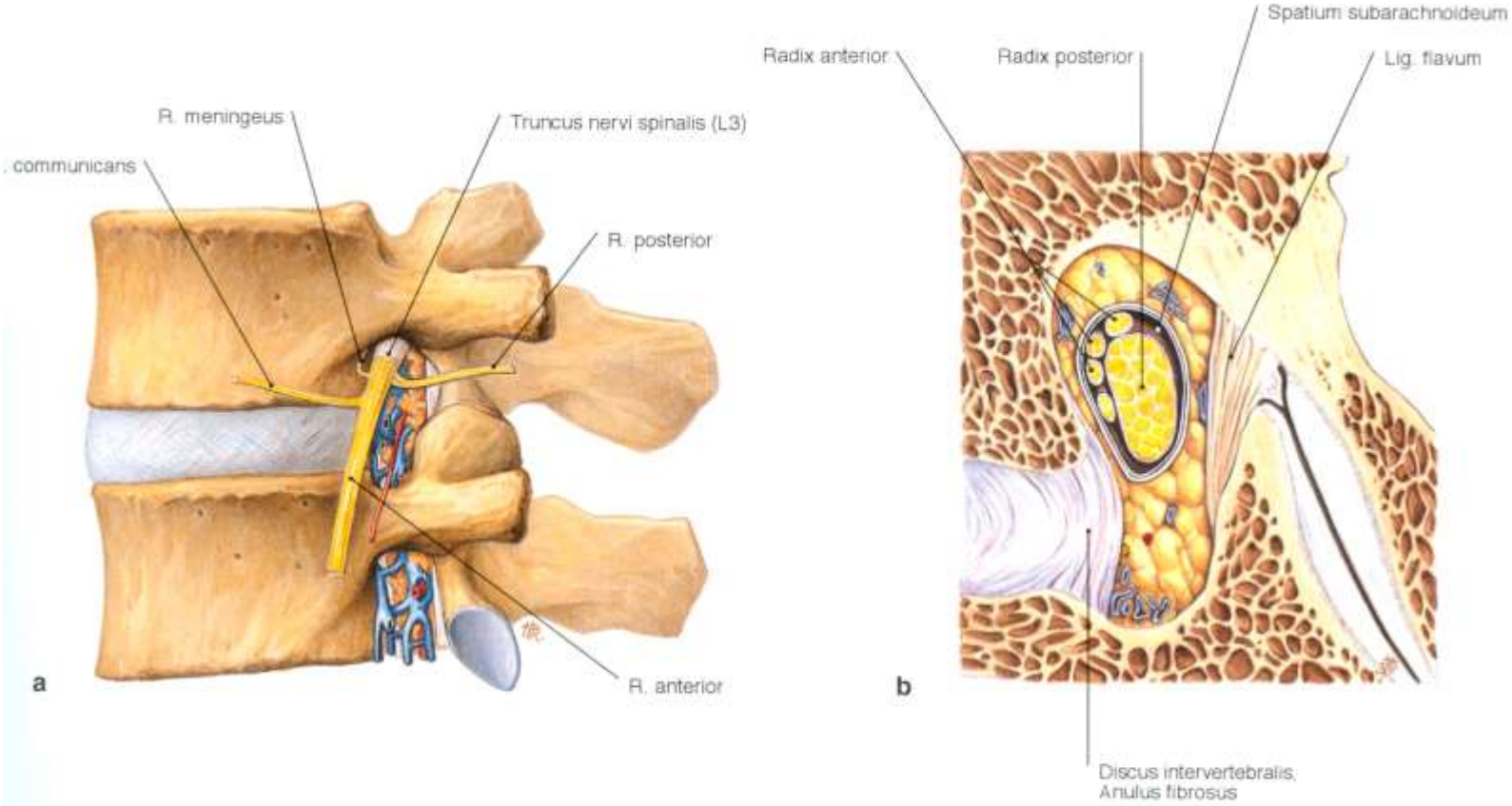

Obr. 827 a, b Foramina intervertebralia; lumbální páteř.

a z laterální strany
b sagitální řez

Meninges of spinal cord

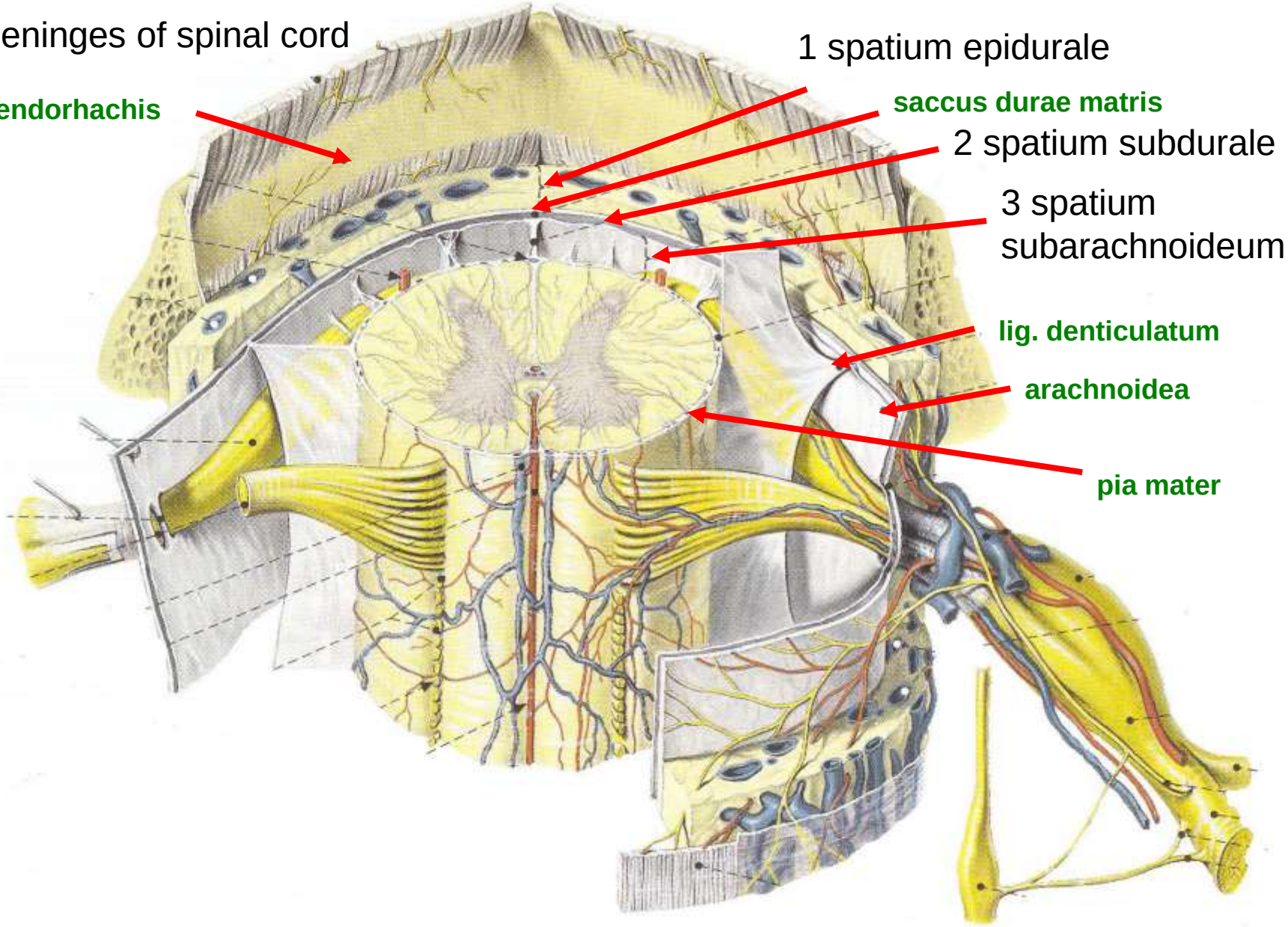

A- saccus durae matris sleeves cover roots of spinal nerves

B- dura mater is cut transparent arachnoid covers spinal cord and nerves roots

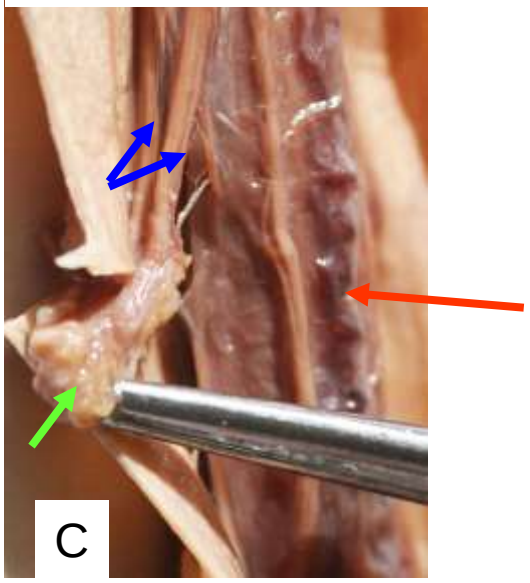

C → posterior root ganglion (spinal ganglion)

→ Vessels in pia mater

→ Nerve roots

Cervical intumescence

A- pia mater removed 5-fasciculus cuneatus, 6-fasciculus gracilis
B-pia mater with vessels covers posterior column 7- fila radicularia (rootlets)
C-1-dura mater, 2-anterior root, 3-posterior root, 4-denticulate lig.



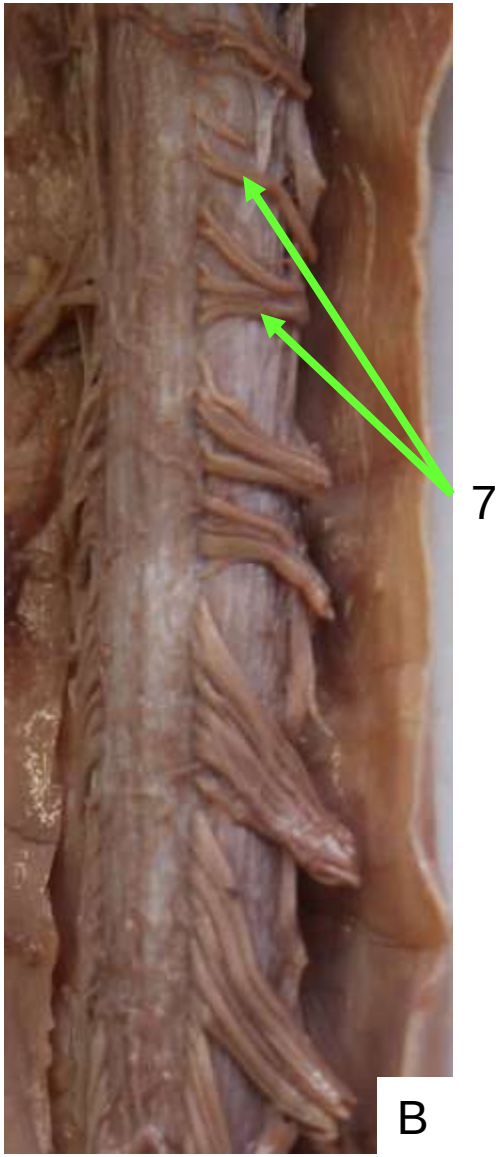

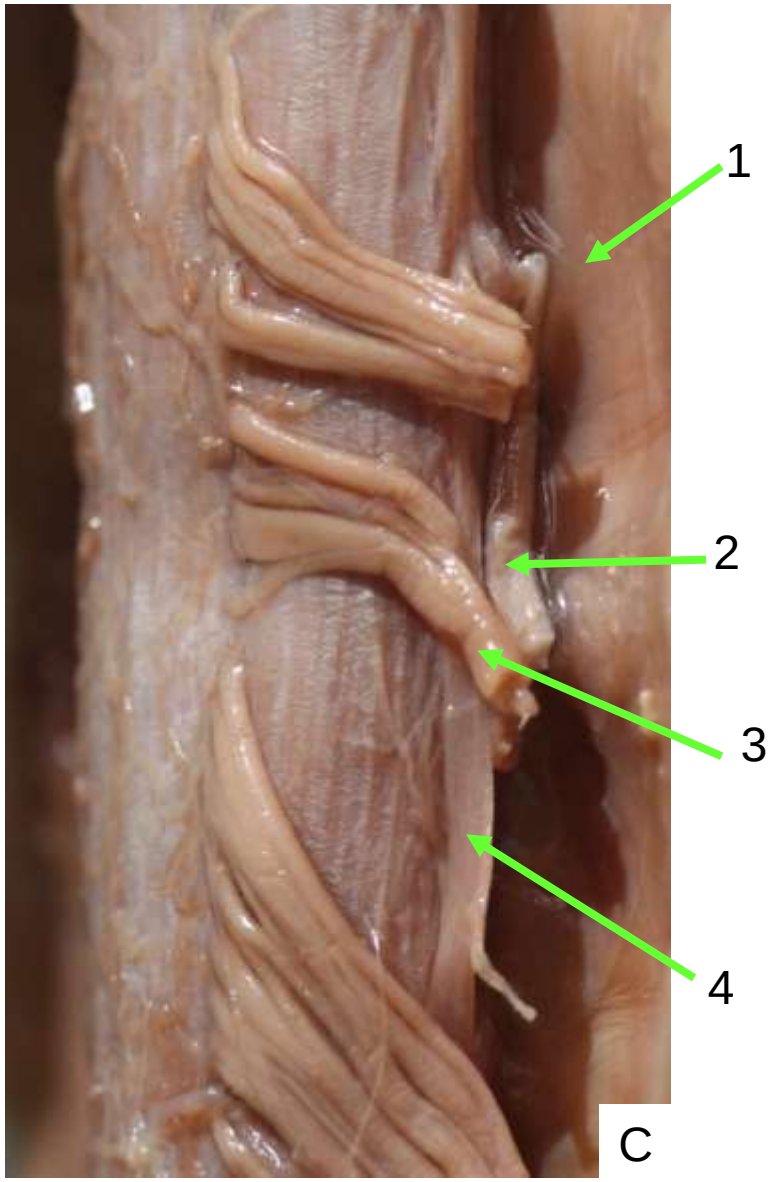

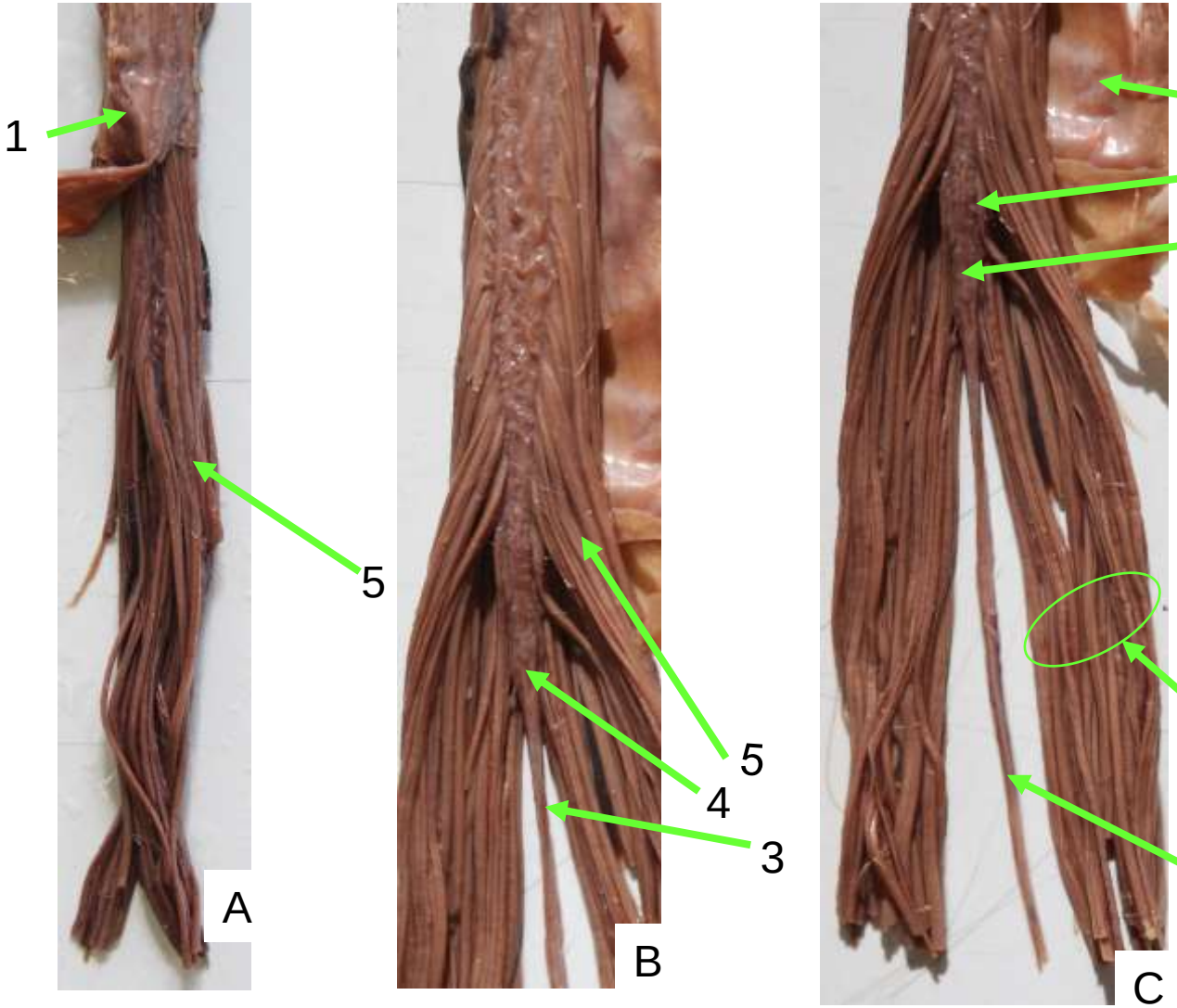

A- cauda equina
B-intumestentia lumbosacra
C-cauda equina
1-dura mater
2-pia mater with vessels
3-filum terminale
4-Conus medullaris
5- roots of sacral and lumba

Cervical spinal cord dorsal aspect

C1

C2

C3

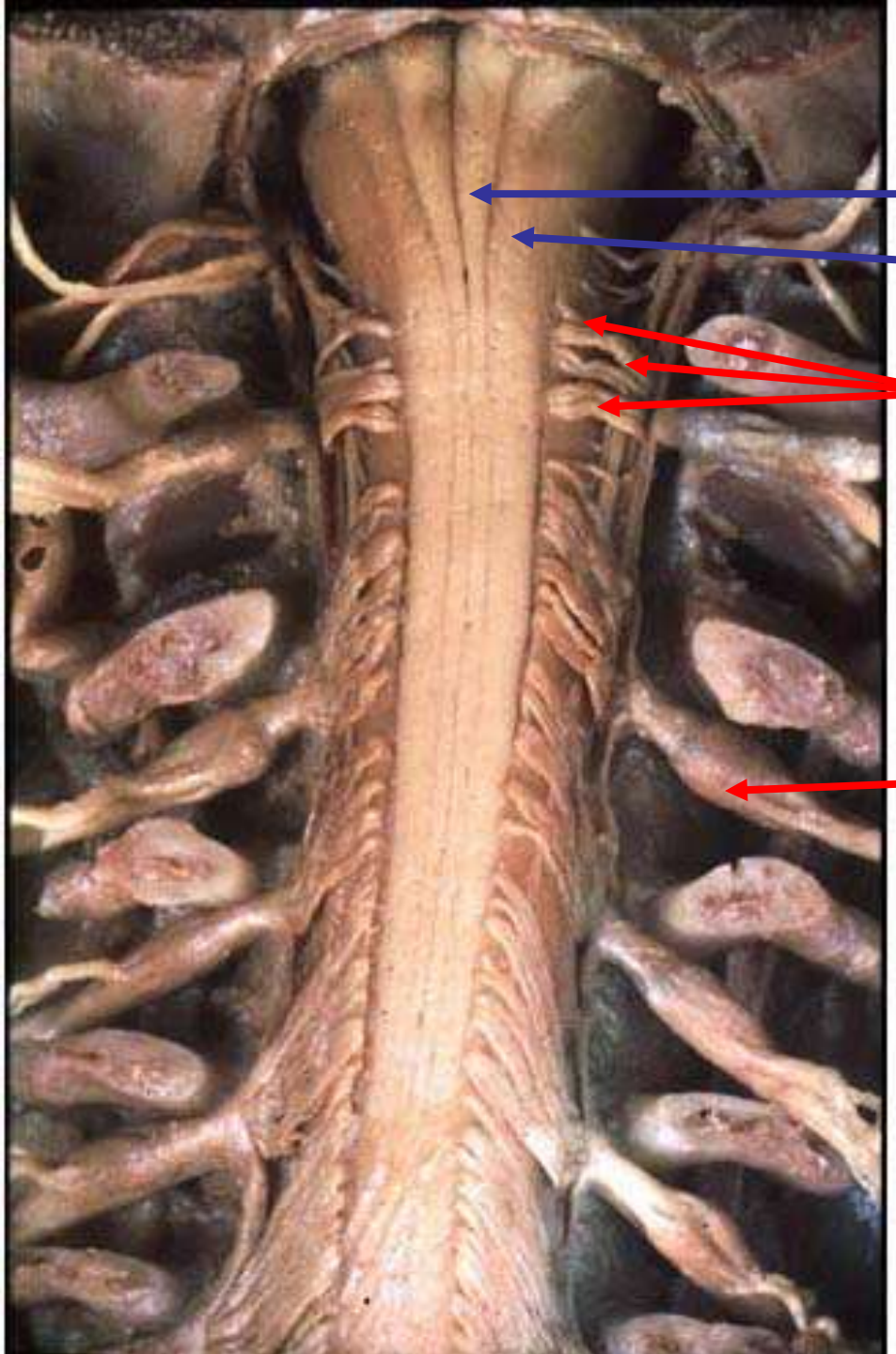

Thoracic spinal cord



lig. denticulatum (ara

saccus durae matris

Thoracic spinal cord

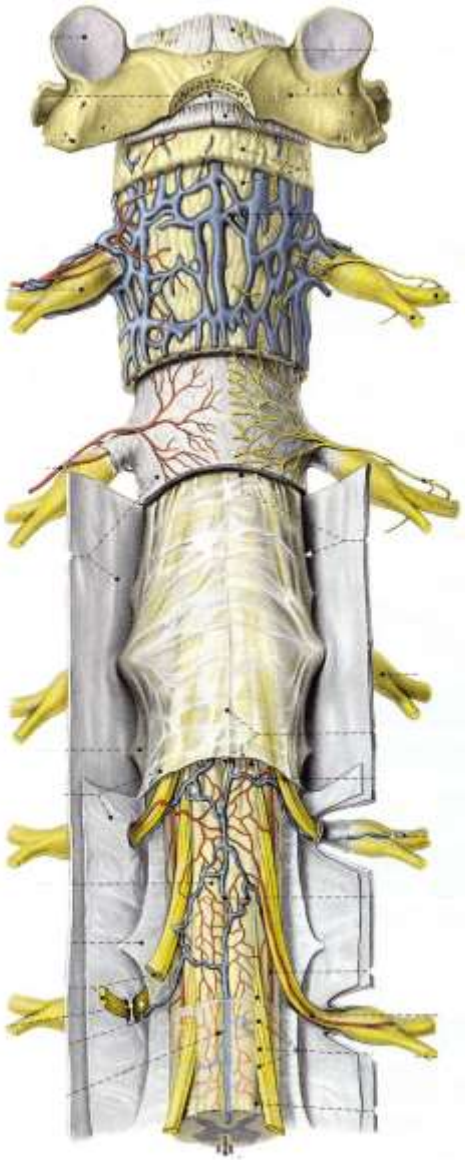

Conus medullaris
+ cauda equina

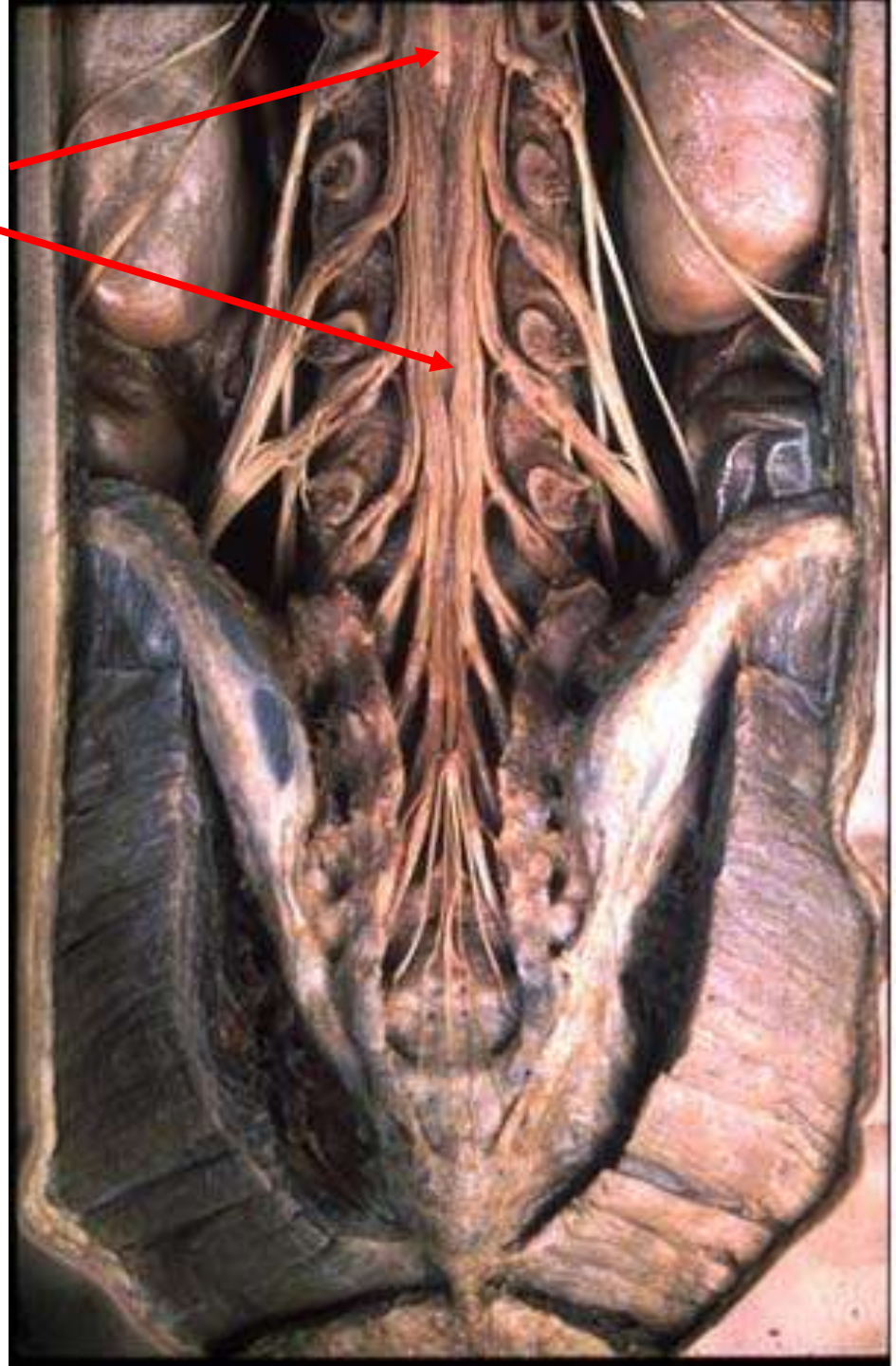

Vertebral canal posterior aspect

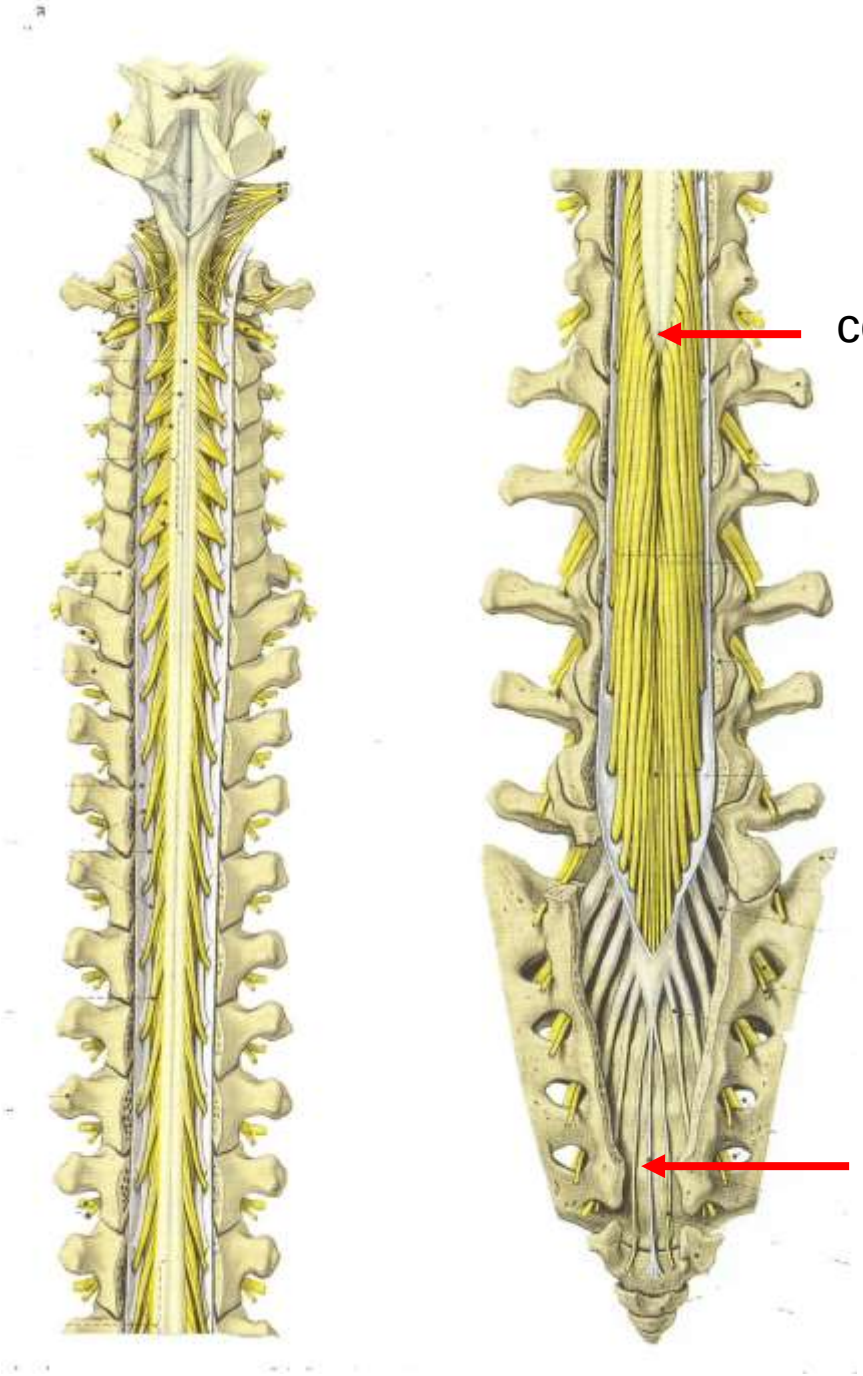

Saccus durae matris content bellow L1

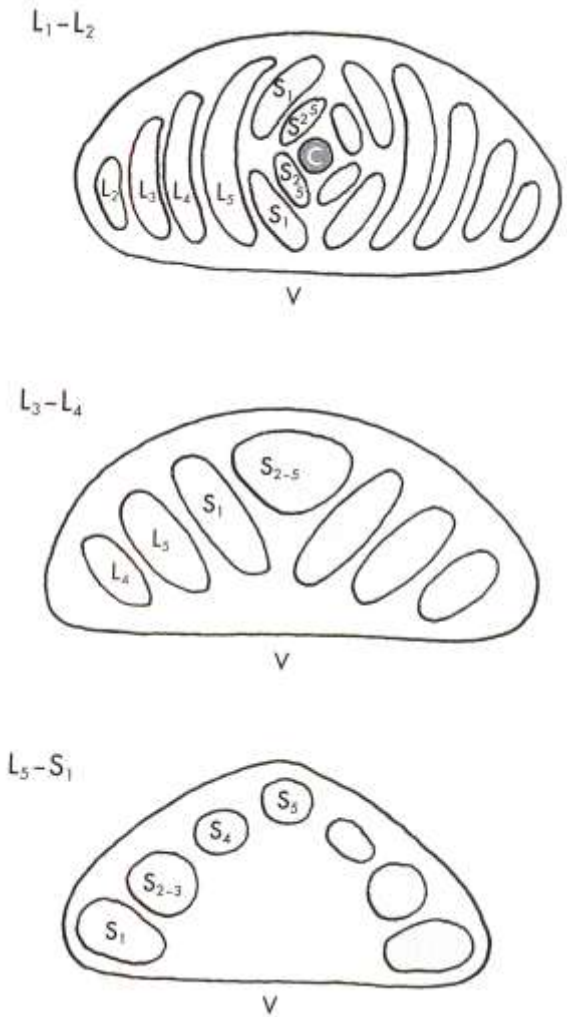

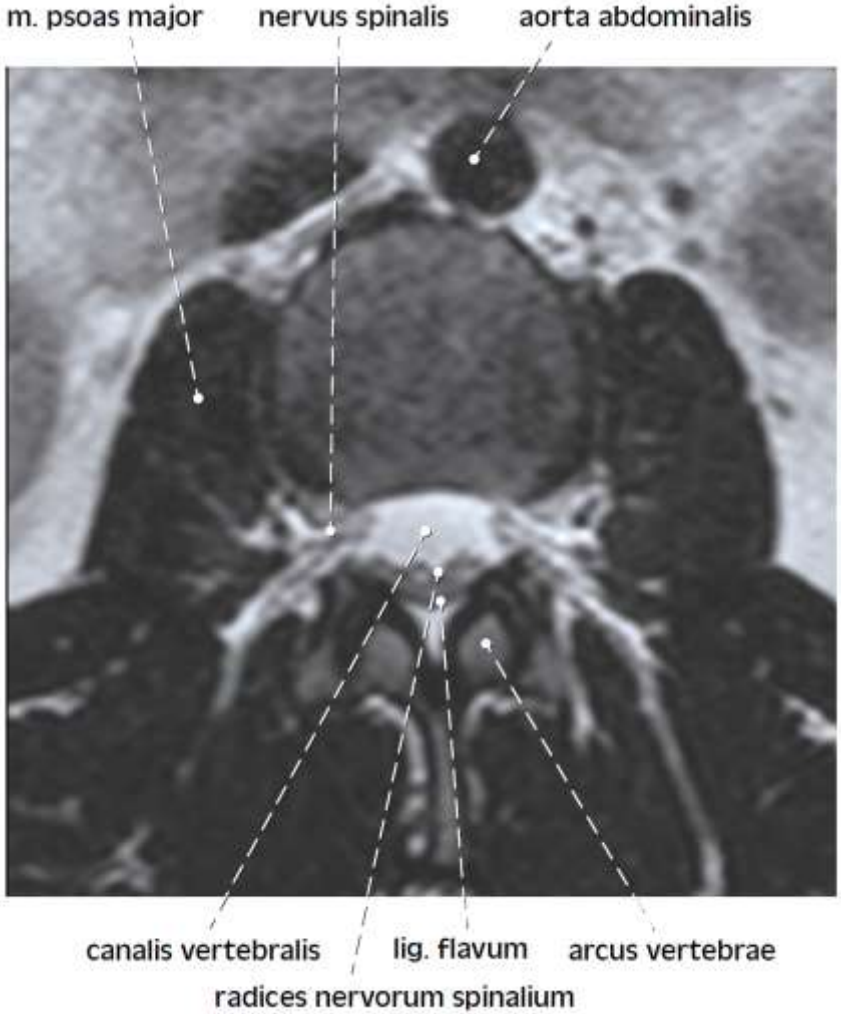

Vertebral canal and its arrangement in MRI L3 level

Vertebral canal sagittal section

1-discus intervertebralis
2-corpus vertebrae
3-saccus durae matris
4-spatium epidurale
5-spinal cord
6-spatium subdurale

MRI cervical spinal cord

MRI vertebral canal
LS region

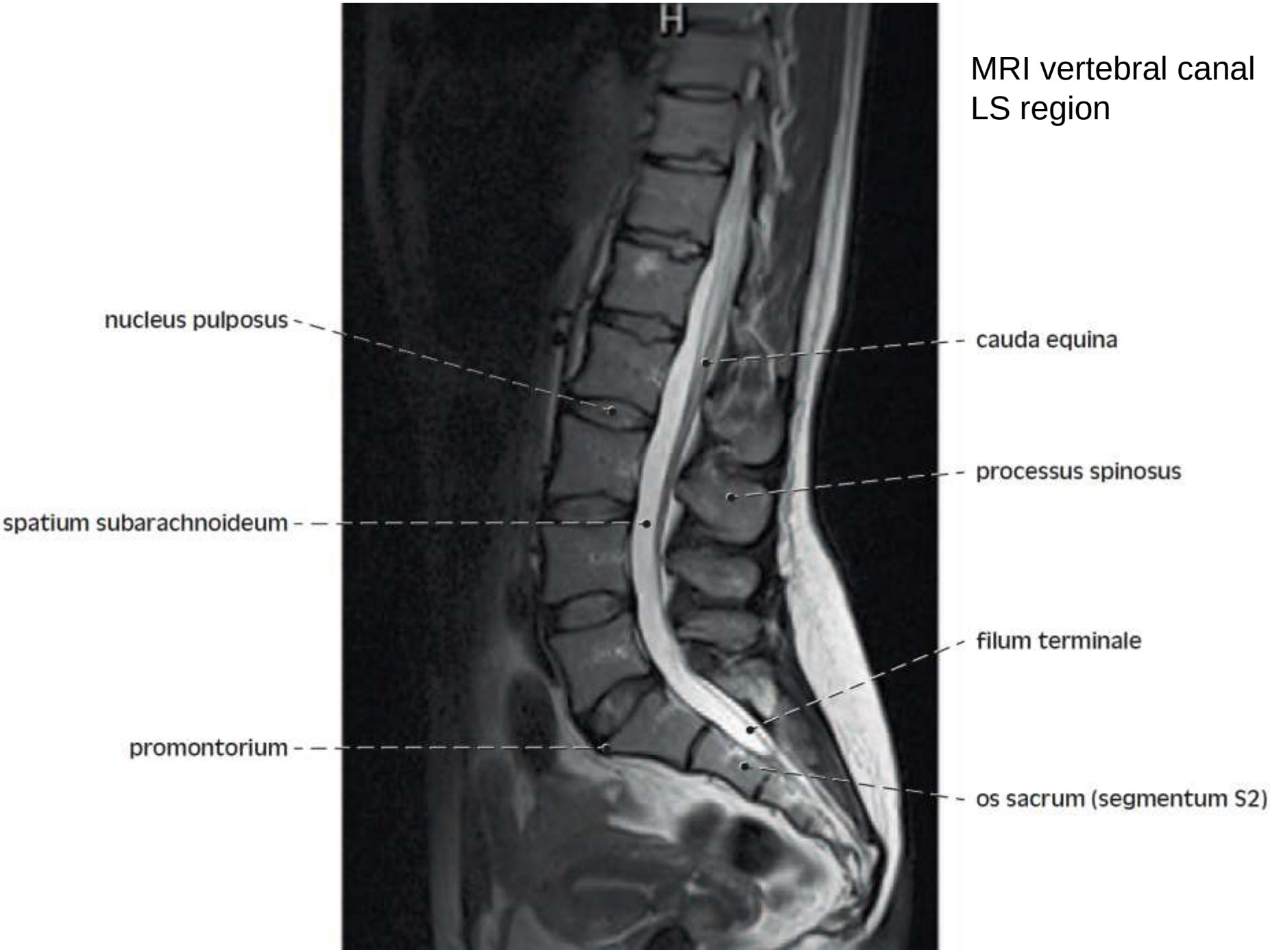

Cervical part of vertebral canal

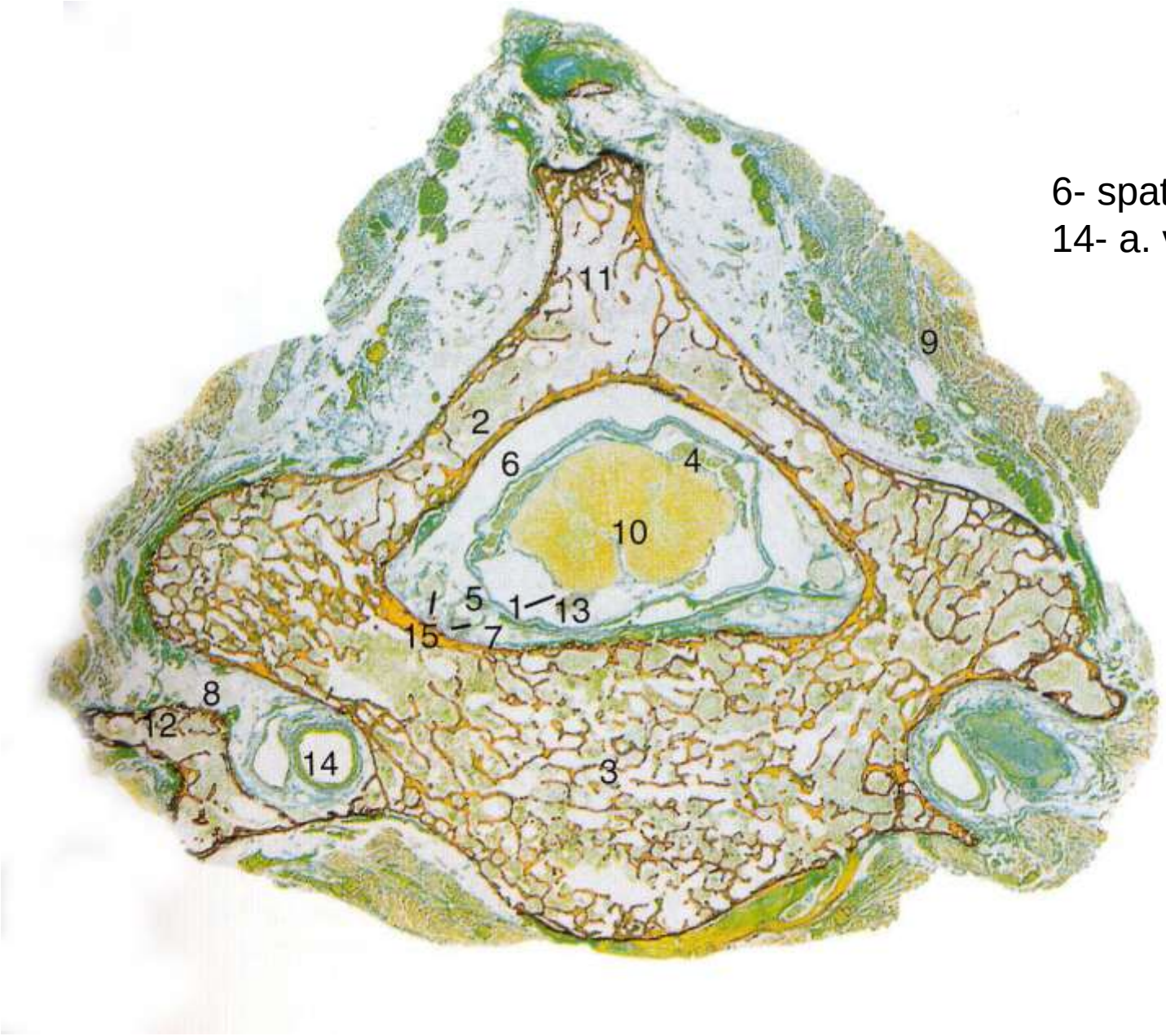

6- spatium epidurale
14- a. vertebralis

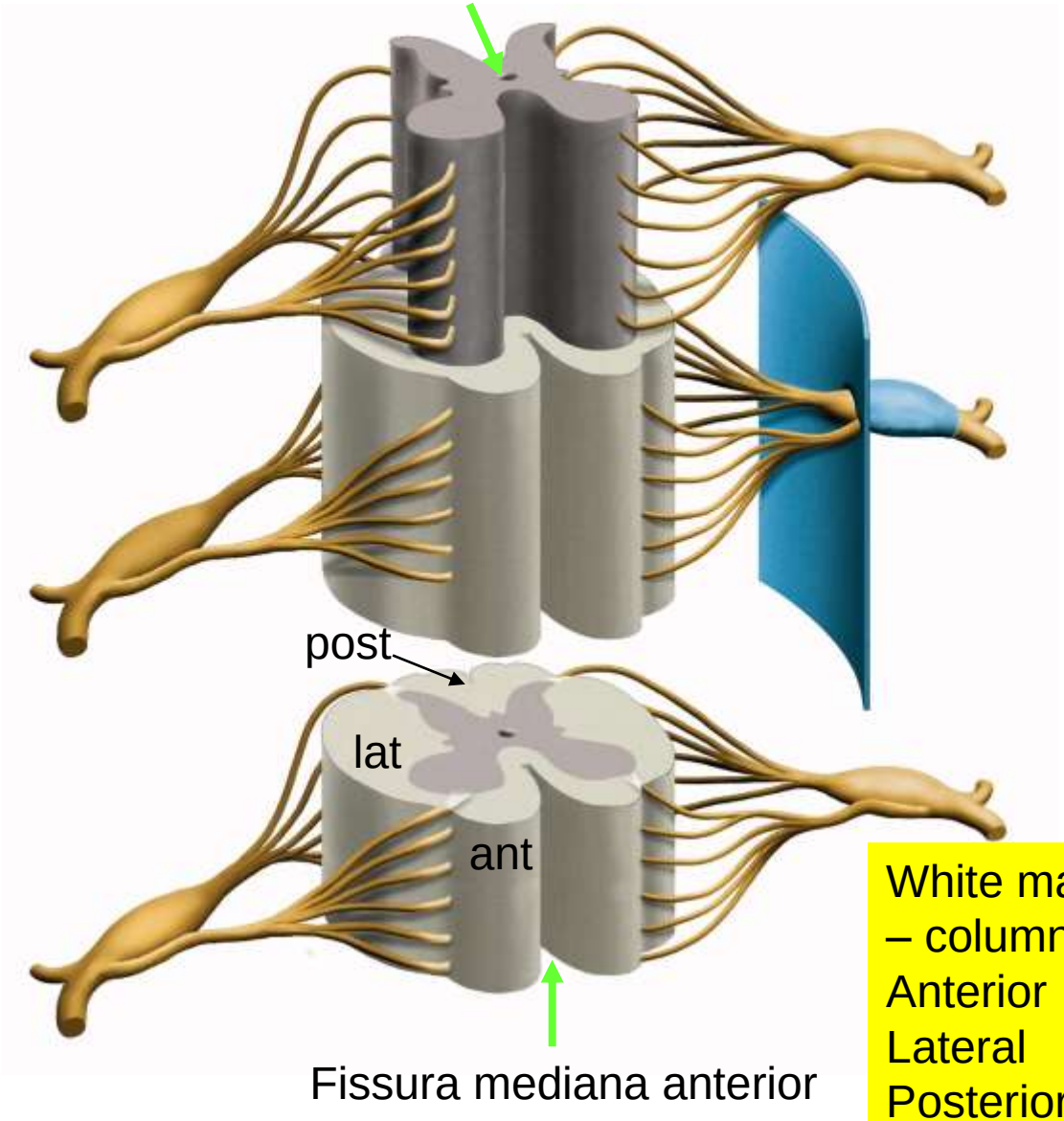

Gray matter inside
Anterior horns – motor
Posterior horns – sensory
Lateral - visceromotoneurons

White matter outside - tracts
– columns – funiculi
Anterior
Lateral
Posterior – fasciculus gracilis Goli
- fasciculus cuneatus Burdachi

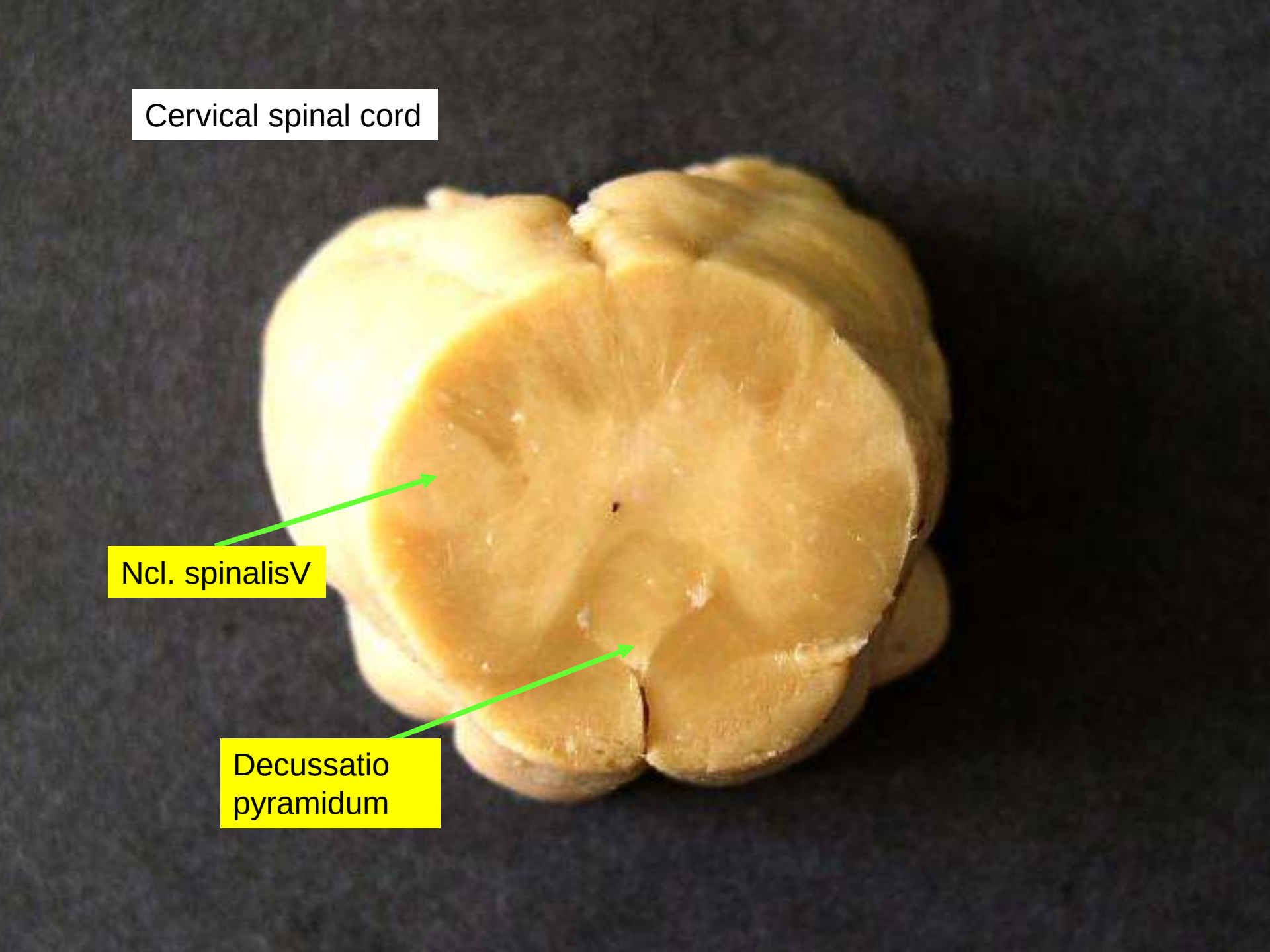
Cervical spinal cord
Ncl. spinalisV
Decussatio pyramidum

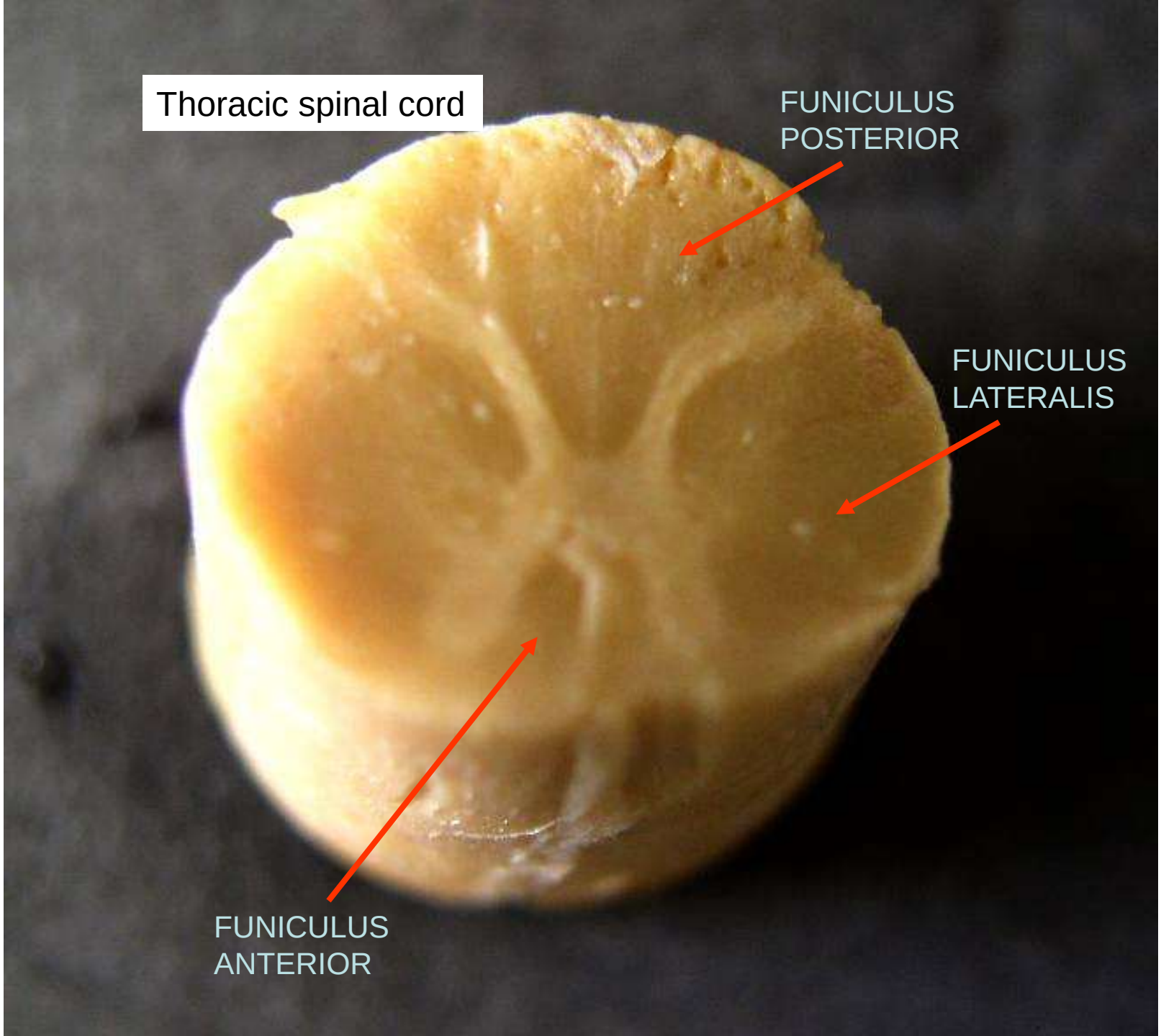
Thoracic spinal cord
FUNICULUS POSTERIOR
FUNICULUS LATERALIS
FUNICULUS ANTERIOR

Spinal cord

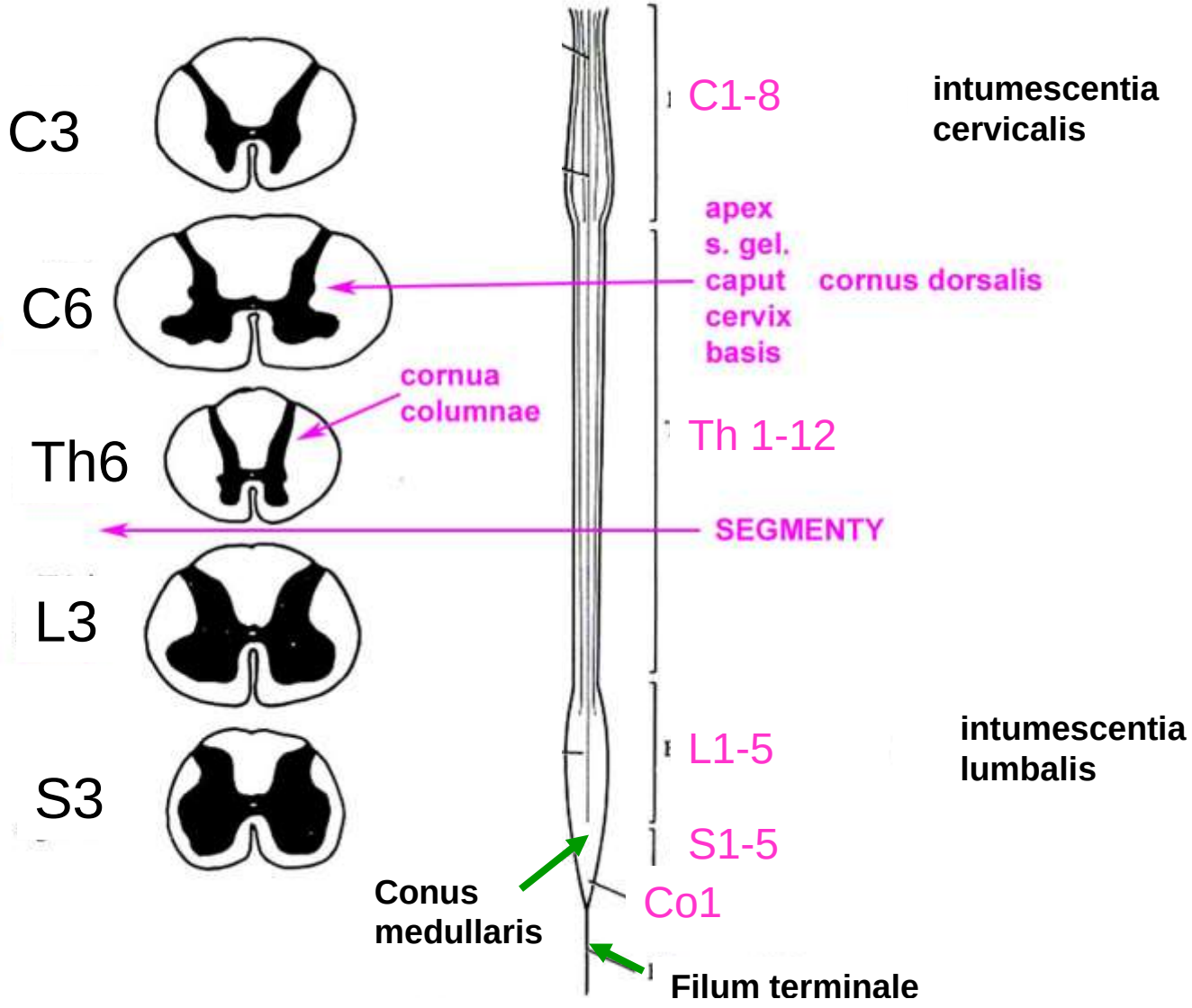
C3
C6
Th6
L3
S3
C1-8
intumescentia cervicalis
apex
s. gel.
caput
cervix
basis
cornus dorsalis
cornua columnae
Th 1-12
SEGMENTY
L1-5
intumescentia lumbalis
S1-5
Co1
Conus medullaris
Filum terminale

Cervical spinal cord- silver impregnation according Weigert

11-fasciculus gracilis
12-fascuculus cuneatus

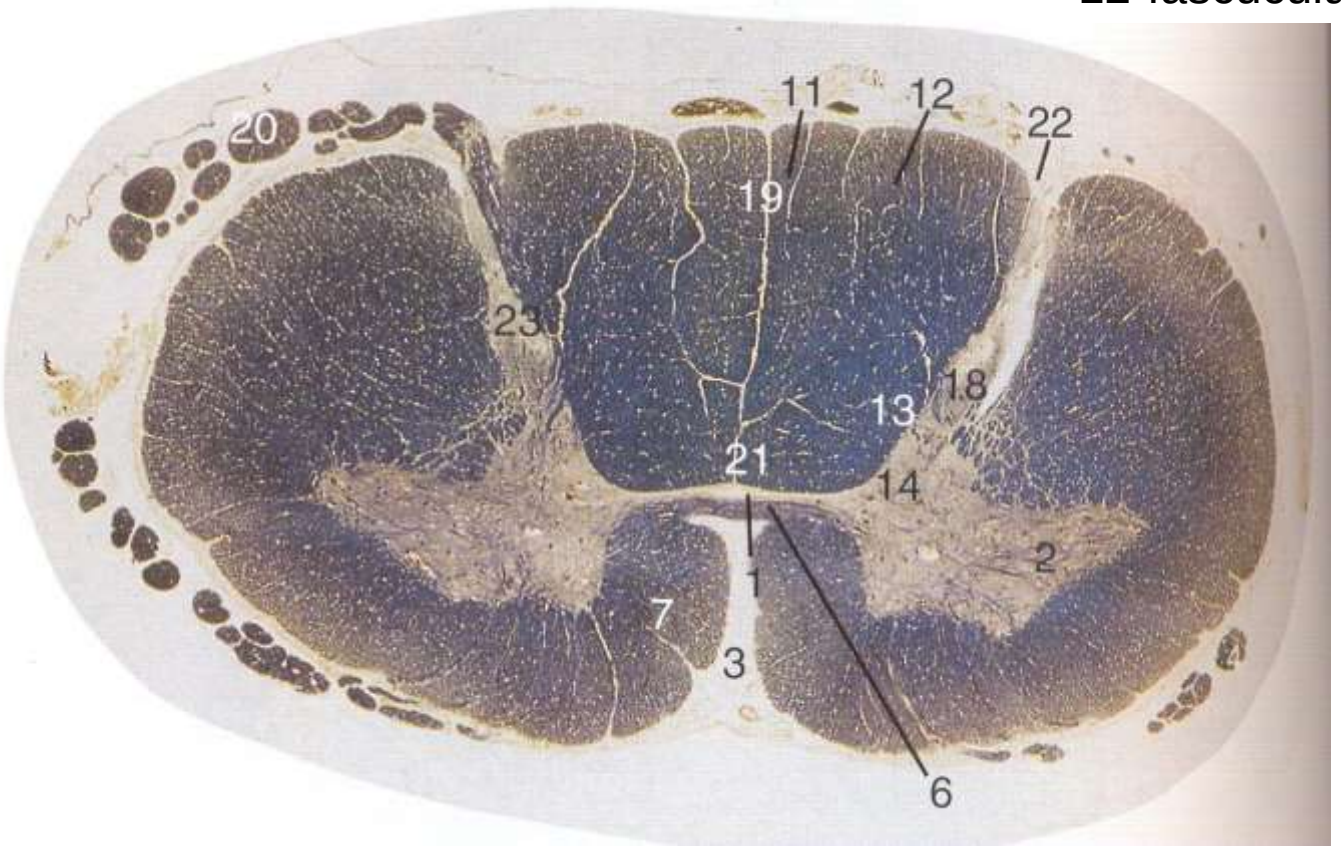

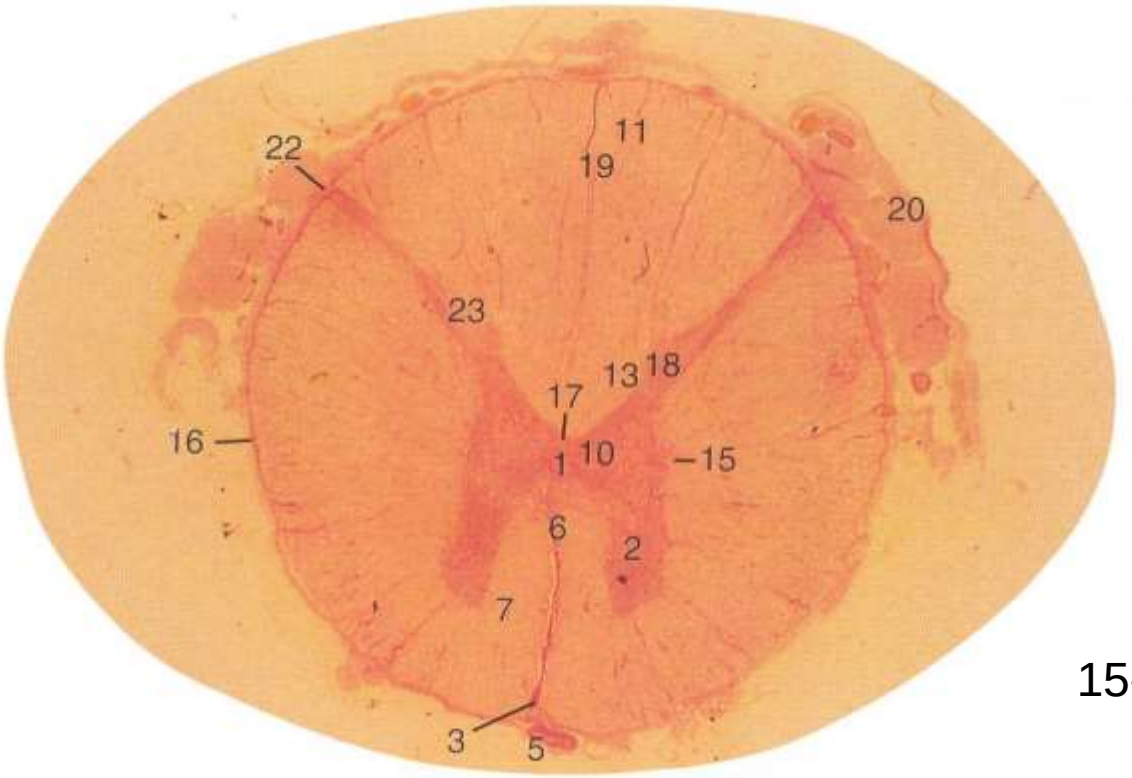

15- lateral horn

Thoracic spinal cord - Van Gieson´s staining

11-fasciculus gracilis

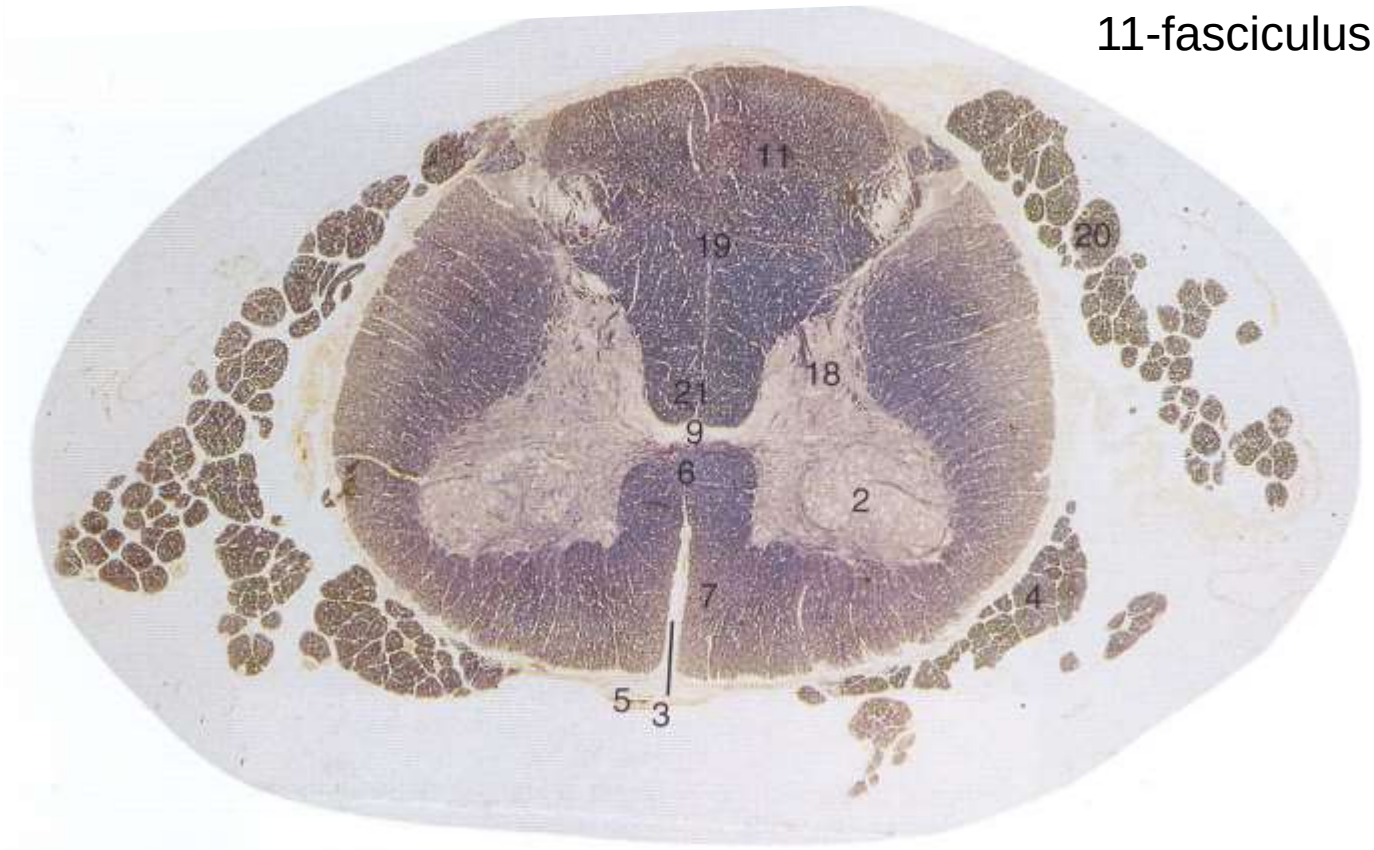

Lumbar spinal cord – Weigert´s staining

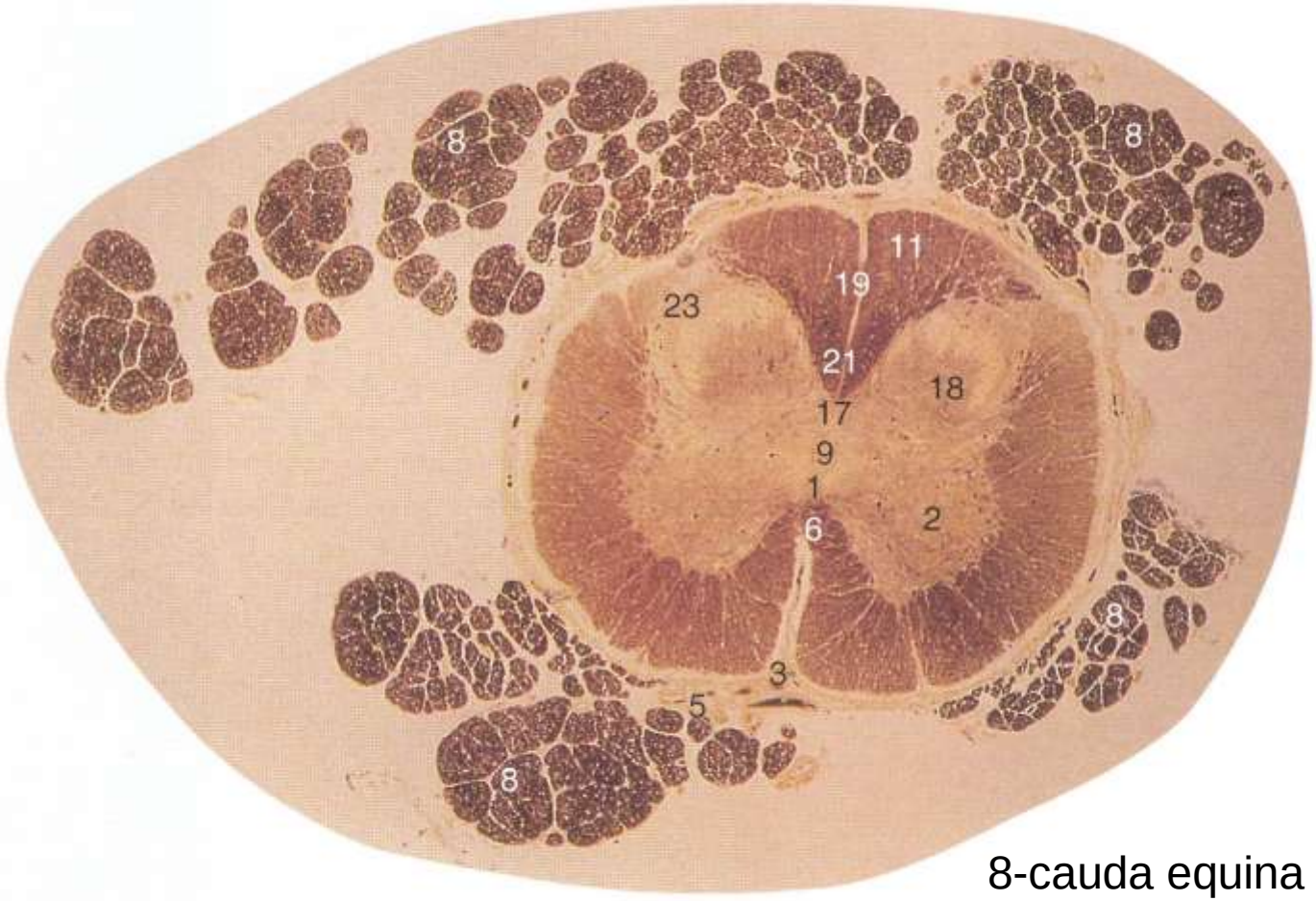

8-cauda equina
11- fasciculus gracilis

Sacral spinal cord

Vertebro-medular topography
vertebral bodies related to spinal cord segments

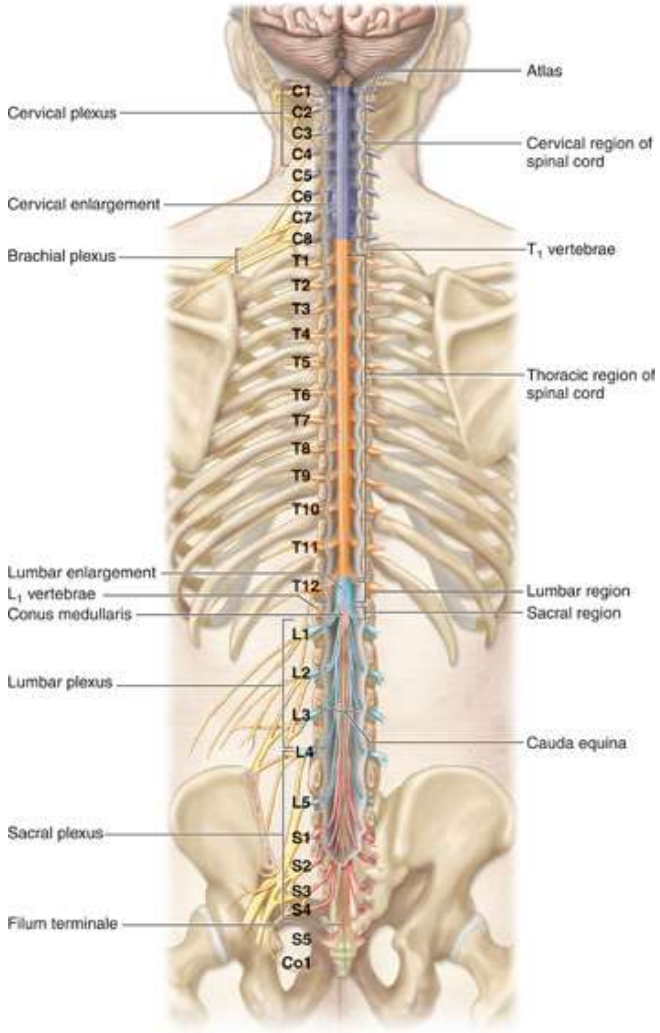

(a) Posterior view

Bone notch at the base of the neck is C7.

The spinal cord ends approximately between L1 & L2.

Sacral cord segments (S1-S5 "Cauda Equina") are level with T12-L1 Vertebrae.

The sacral vertebrae are fused to make up the sacrum.

The coccygeal vertebrae are fused to make the coccyx or "tail bone".

C1 Cervical spinal nerve roots C1 - C7 correspond with upper aspects of vertebral bodies.

C8 Sensation of C7 nerve is for the middle finger.

T1 C8 and lower spinal nerve roots leave below the corresponding vertebral body.

T4 Sensation of T4 spinal nerve is approximately level with the nipple line.

T6 Sensation of T6 spinal nerve root is approximately level with the bottom of the sternum.

T10 Sensation of T10 spinal nerve root is approximately level with the abdomen.

T12 Sensation of T12 spinal nerve root is approximately level with the pubic bone.

L1 The sensations of lumbar nerves are over the legs.

L5

S1

S3 Sensation of S3,S4 & S5 nerves is the Perineal (genital) area.

S5

Vertebro-medular topography - vertebral bodies related to spinal cord segments

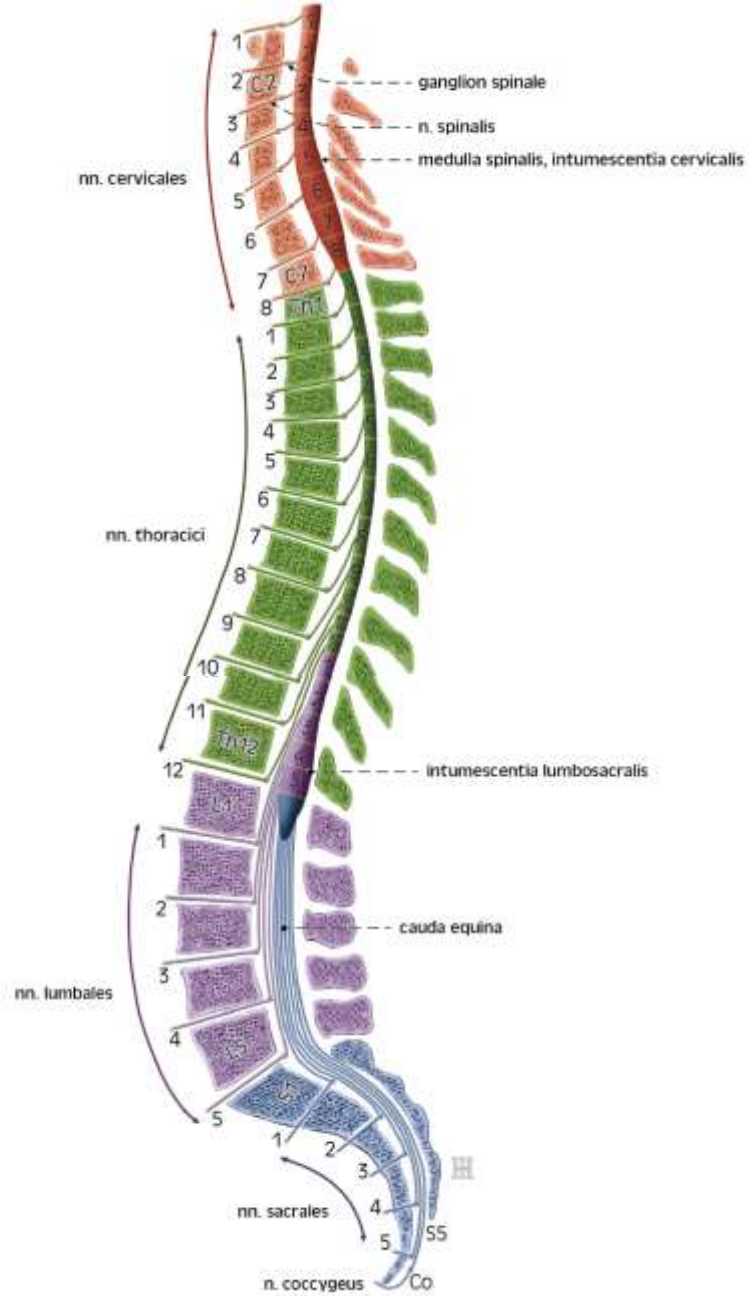

Segment = vertebra

Segment = vertebra +1

+2

Th12-L1 = Th 11 body

L2-L5 = Th12 body

all sacral segments = L1 body

Dermatoms

parts of skin supplied from one spinal cord segment

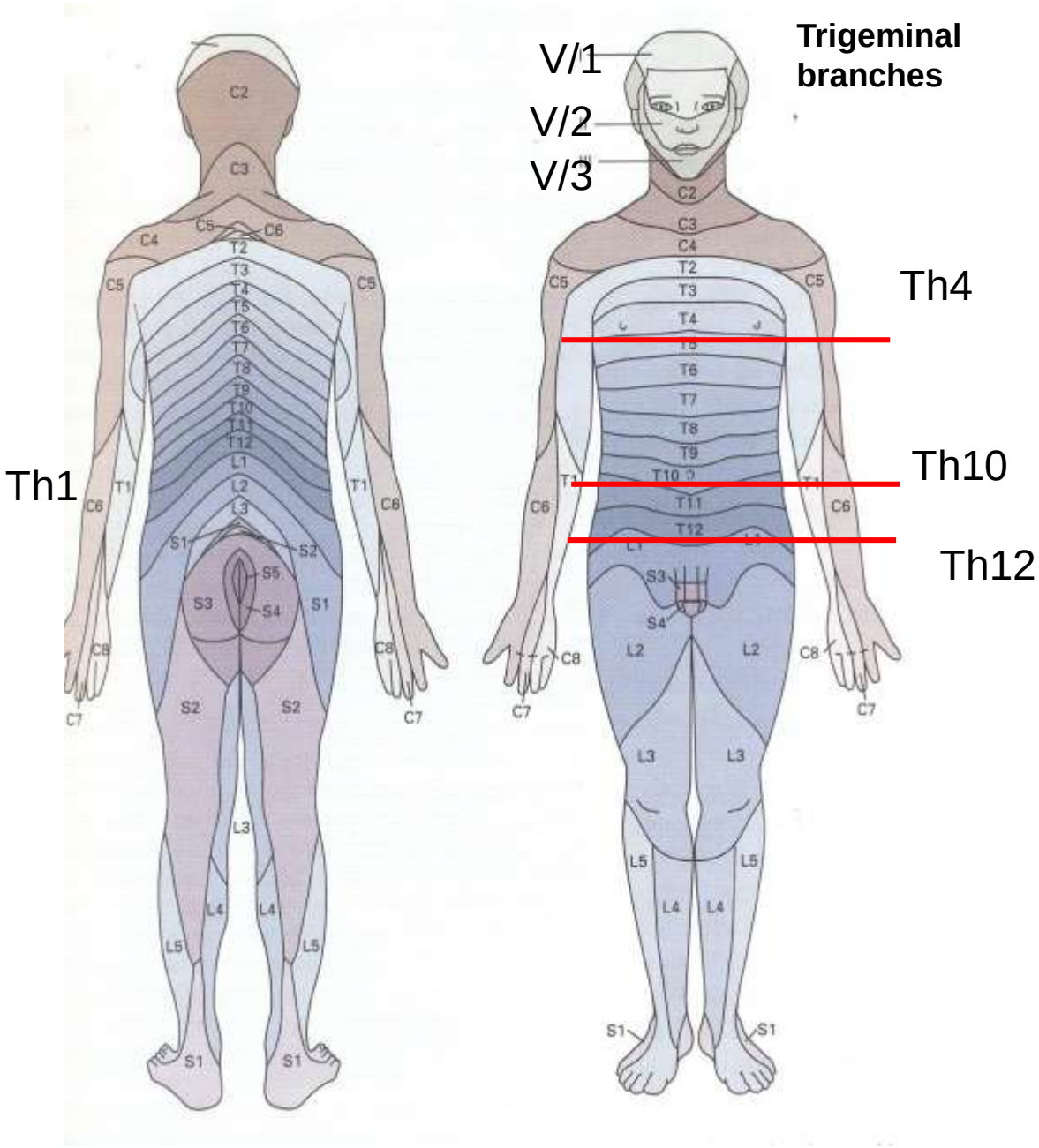

Dermatomes

Th 1 on upper limb

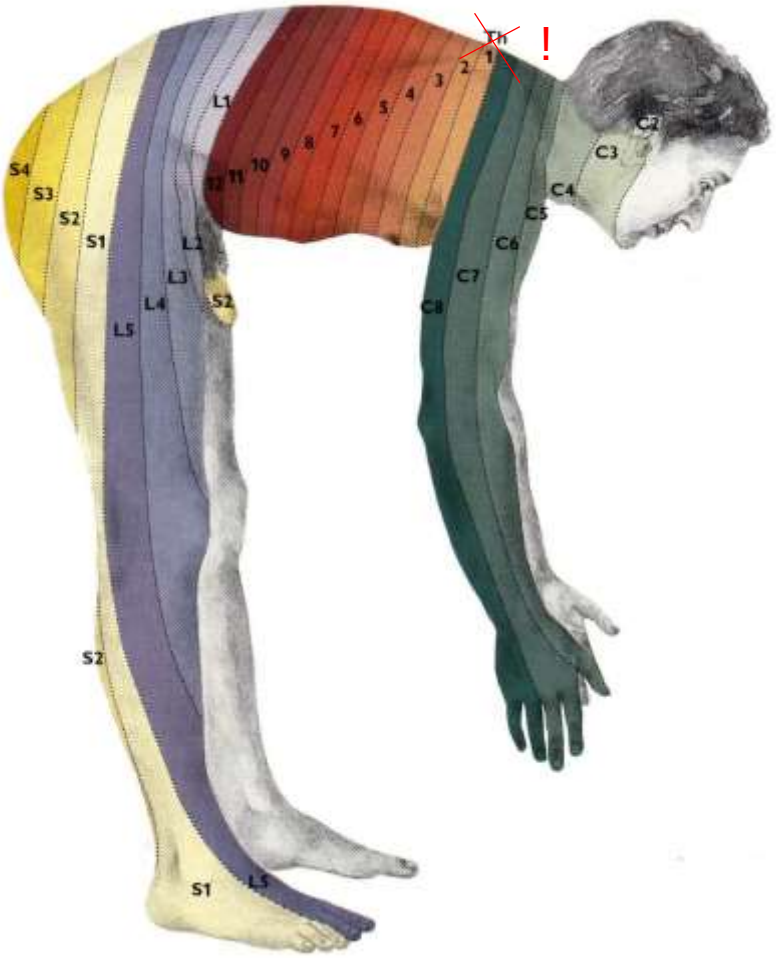

Arteries of spinal cord

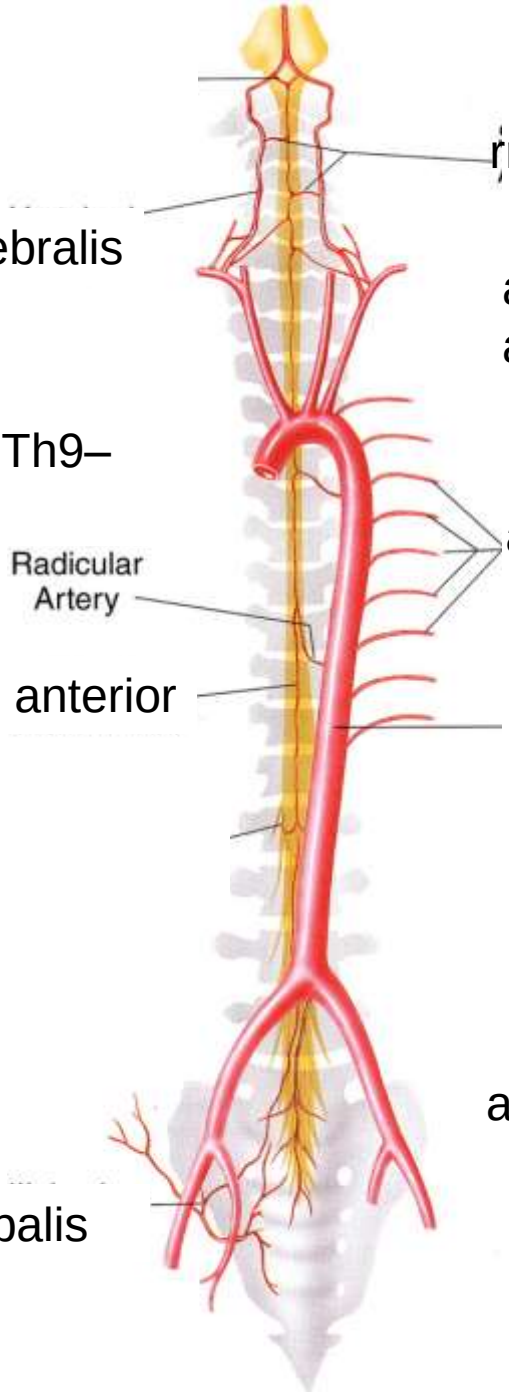

rr. spinales (radicular arteries)

a. vertebralis

a. cervicalis ascendens
a. cervicalis profunda

Adamkiewicz´s artery
(a.spinalis magna) from a. intercostalis post. At the level Th9–L1 (Th7-L2)

aa. Intercostales posteriores

a.spinalis anterior

aa. lumbales

aa. sacrales laterales

a. iliolumbalis

Yoshioka K et al. Radiographics 2003;23:1215-1225

Cervical spinal cord supplying

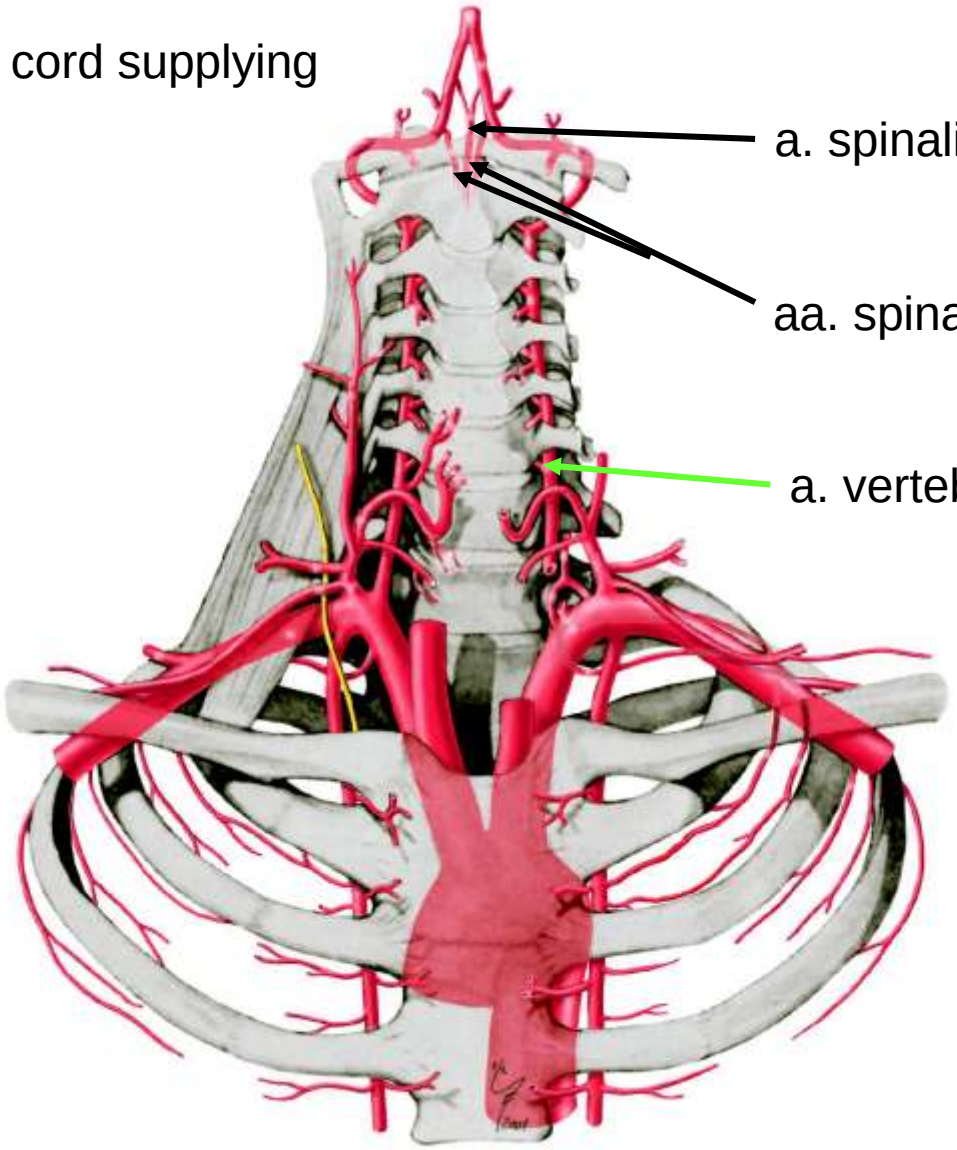

Thoracic spinal cord supplying

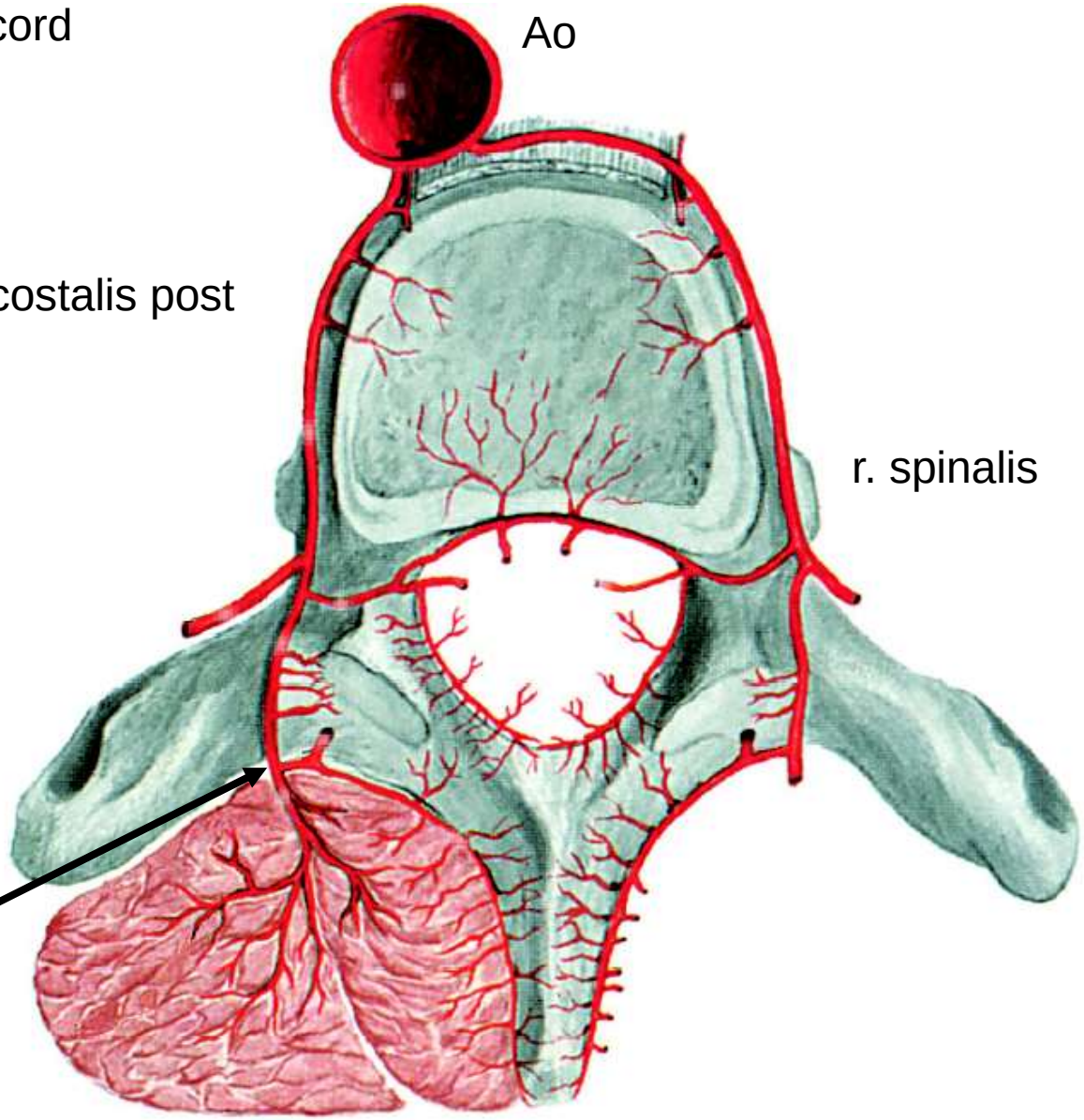

Vertebral canal supplying in sacral region

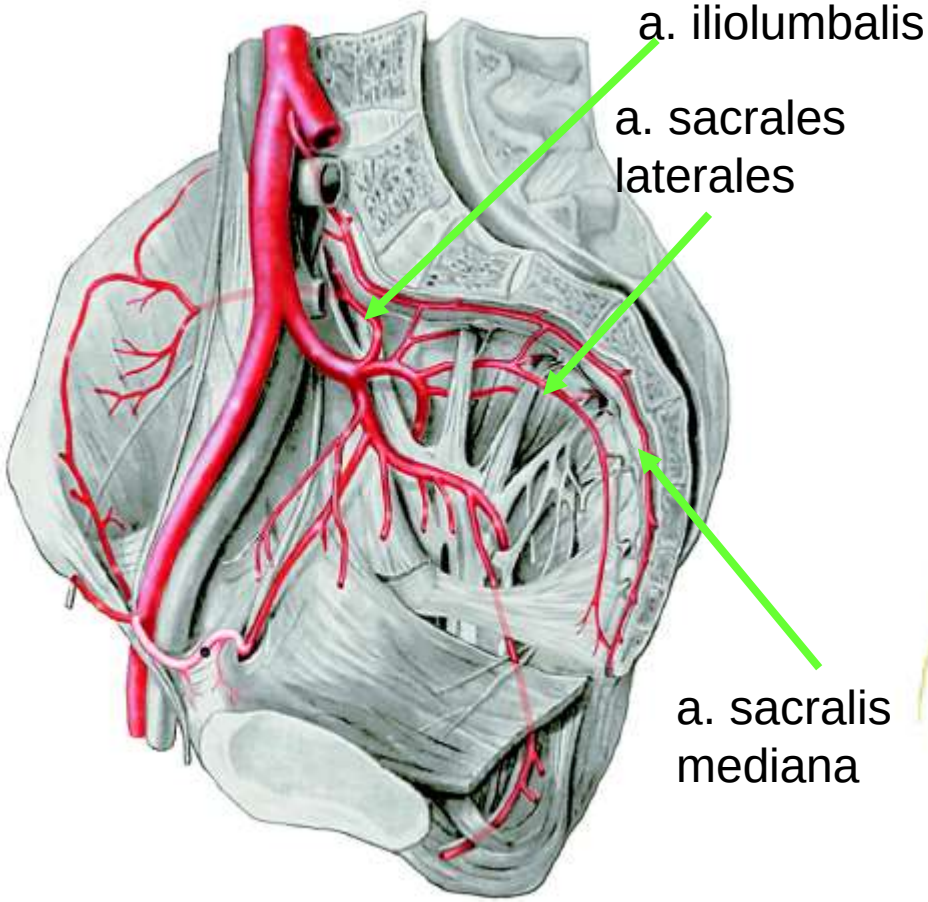

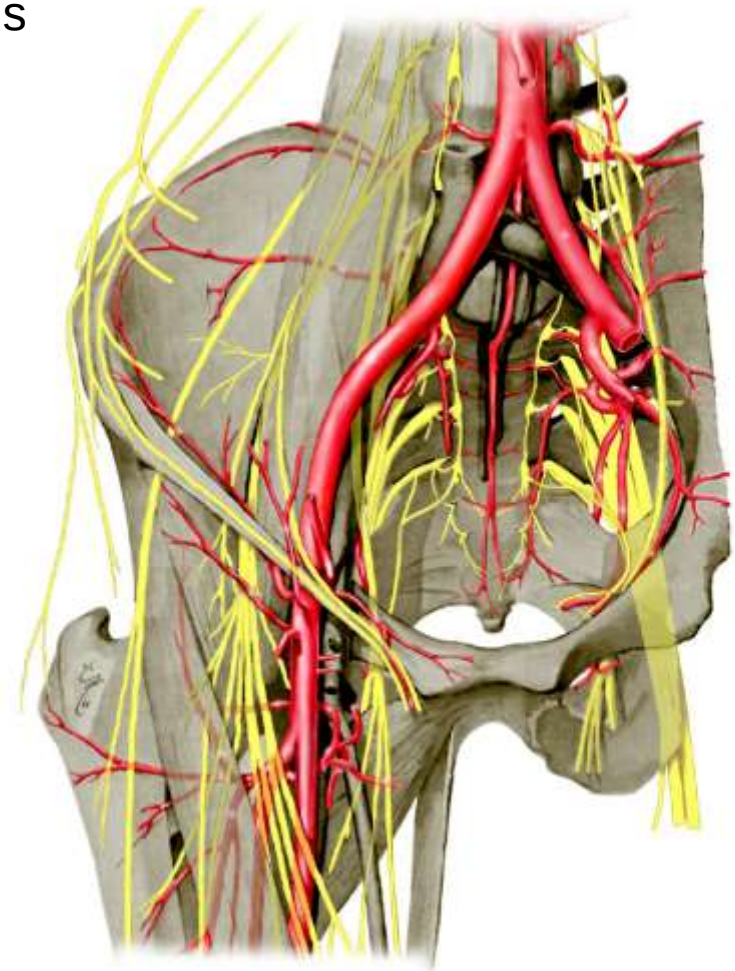

Spinal cord arteries

5 longitudinal truncs

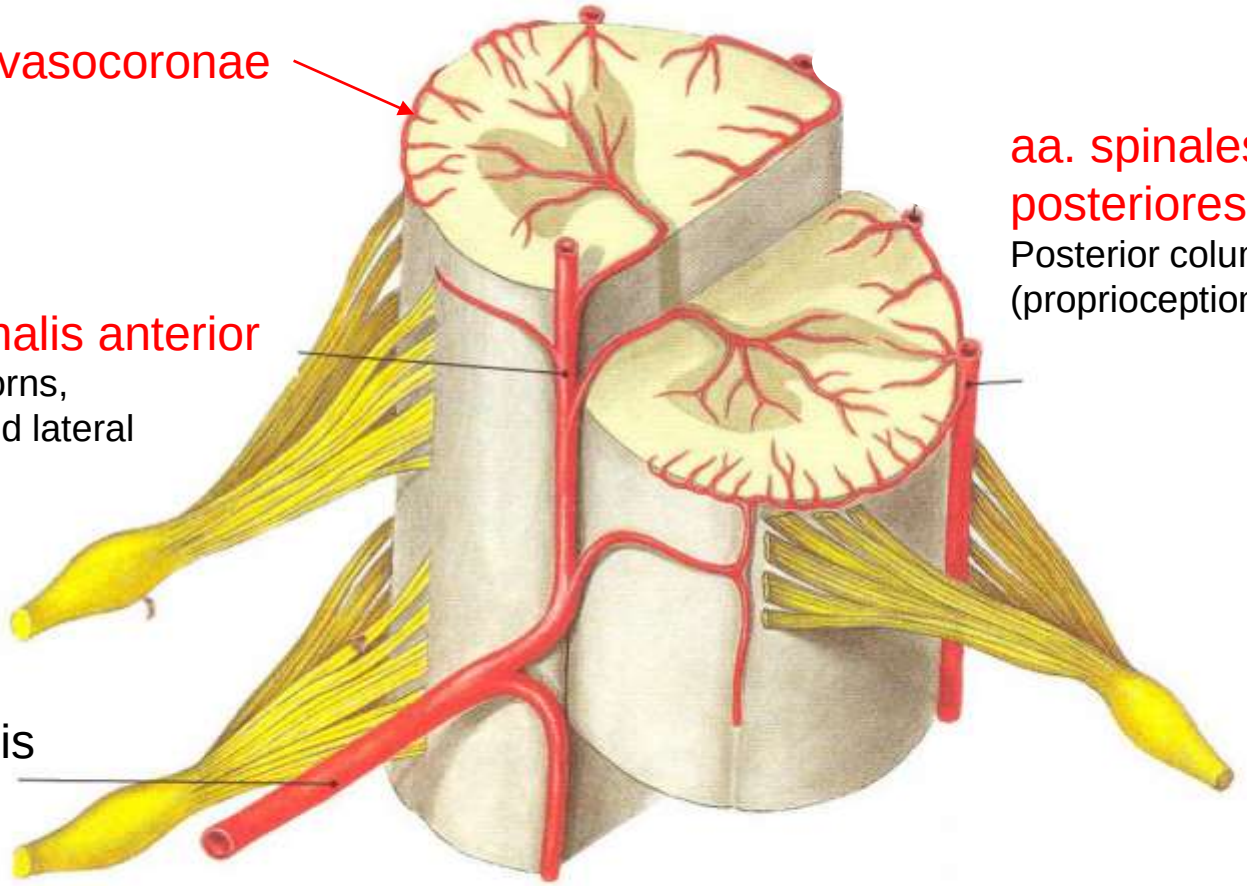

Venous plexuses

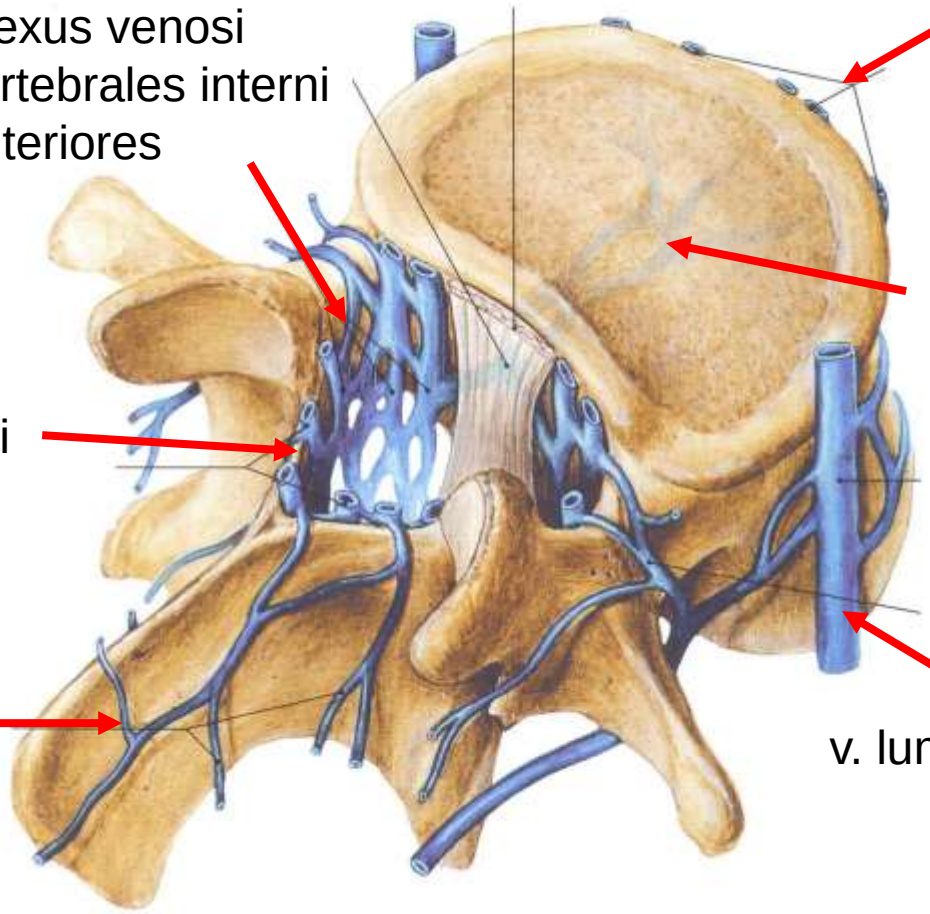

Vertebral venous plexuses

- No valves (cancer and infection spreading), anastomoses (between externi and interni)
- Anastamoses with venous plexuses of pelvis
- Placed: 1) inside canal in epidural space (plexus venosi vertebrales interni)
- 2) outside the spine (plexus venosi vertebrales externi)
- 3) in bodies of vertebrae (venae basivertebrales)

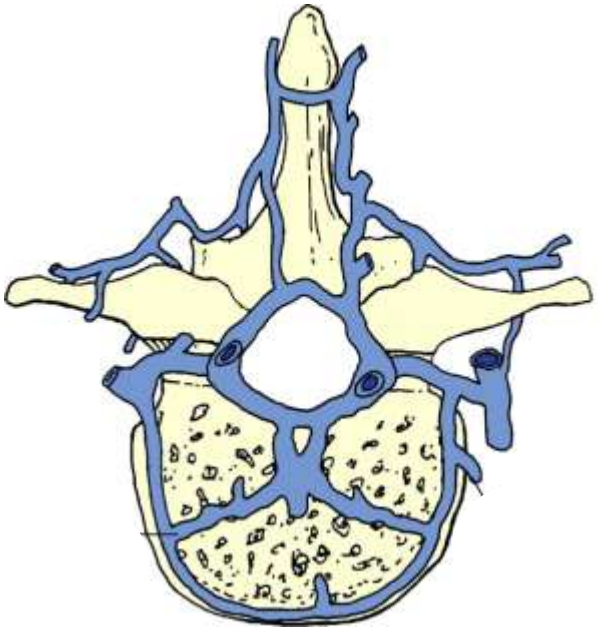

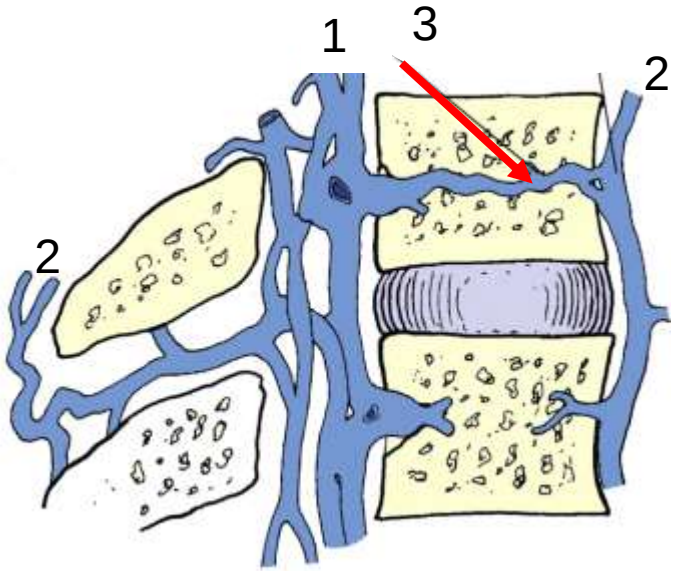

Rexed´s laminae (zones)

I – ncl apicalis
II, III – subst. gelatinosa Rolandi
IV,V – ncl proprius
VI – ncl. Stilling-Clark
VII – interneurons
VIII,IX - motoneurons

Dorsal column tracts

Propriospinal tracts crosshatched
Visceromotor nucleus
Sensory tracts
Motor tracts
Cerebellar tracts

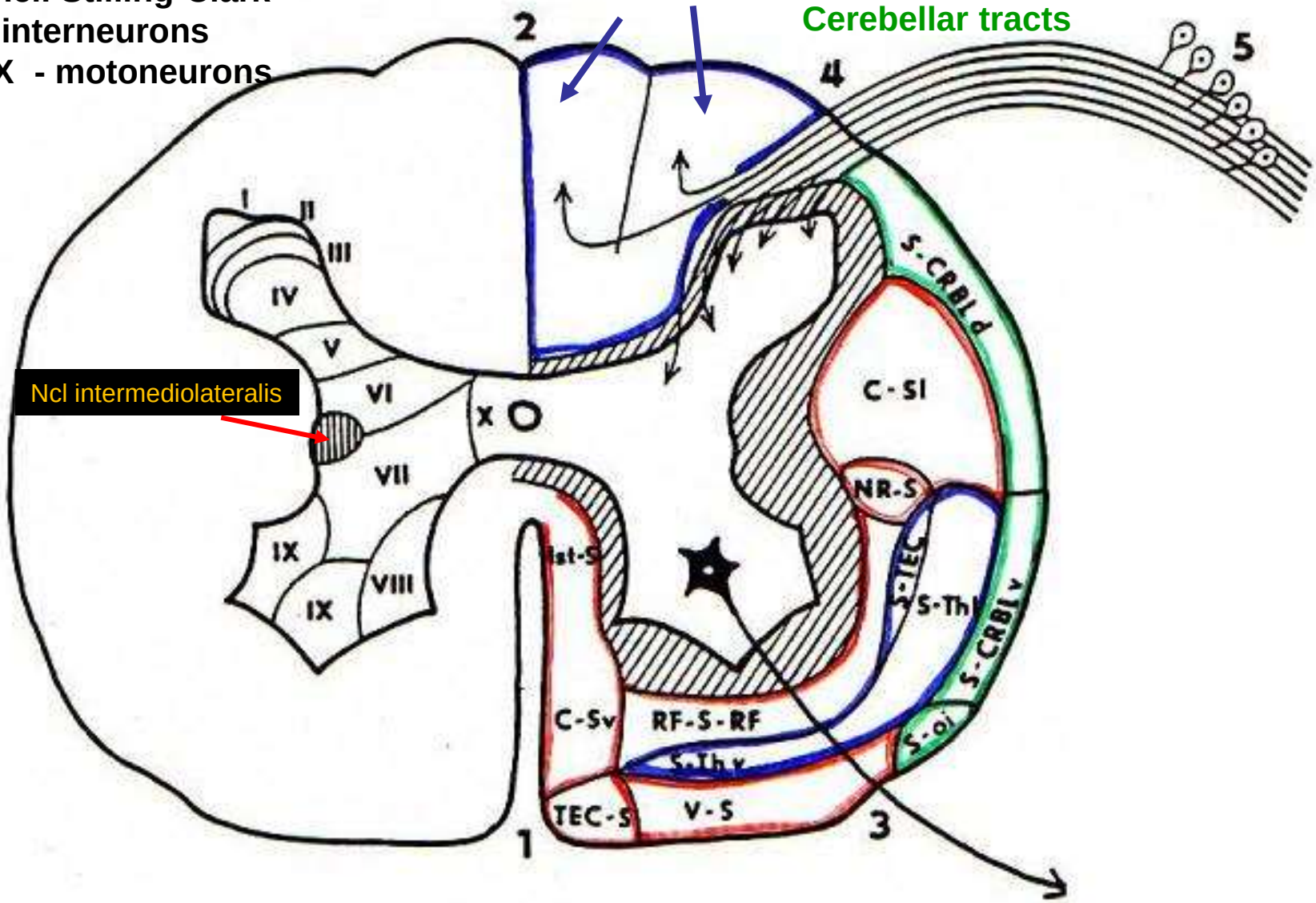

Rexed´s zones – Nissl staining

Bror Rexed

I – ncl apicalis
II, III – subst. gelatinosa Rolandi
IV,V – ncl proprius
VI – ncl. Stilling-Clark
VII – interneurons
VIII,IX - motoneurons

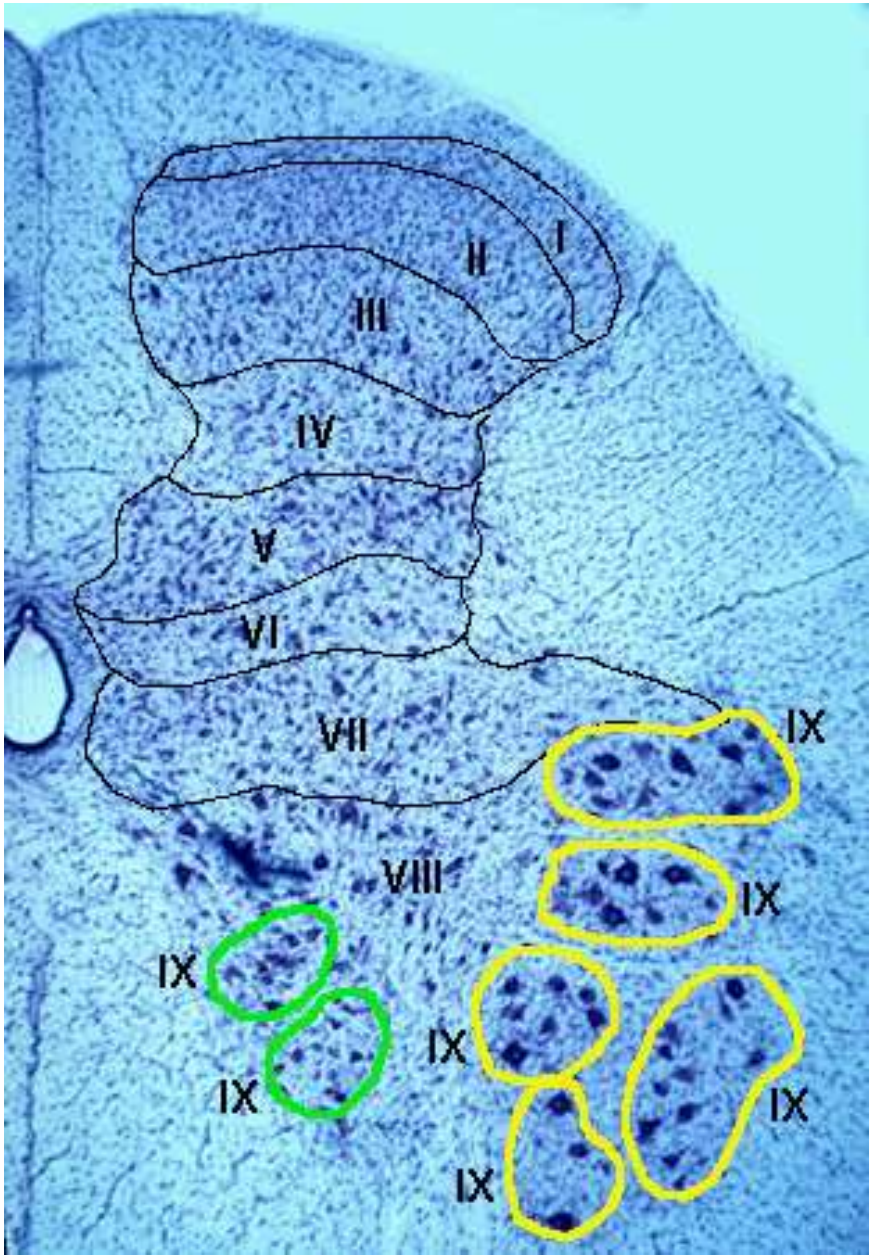

Comparison of classic and Rexed nomenclature

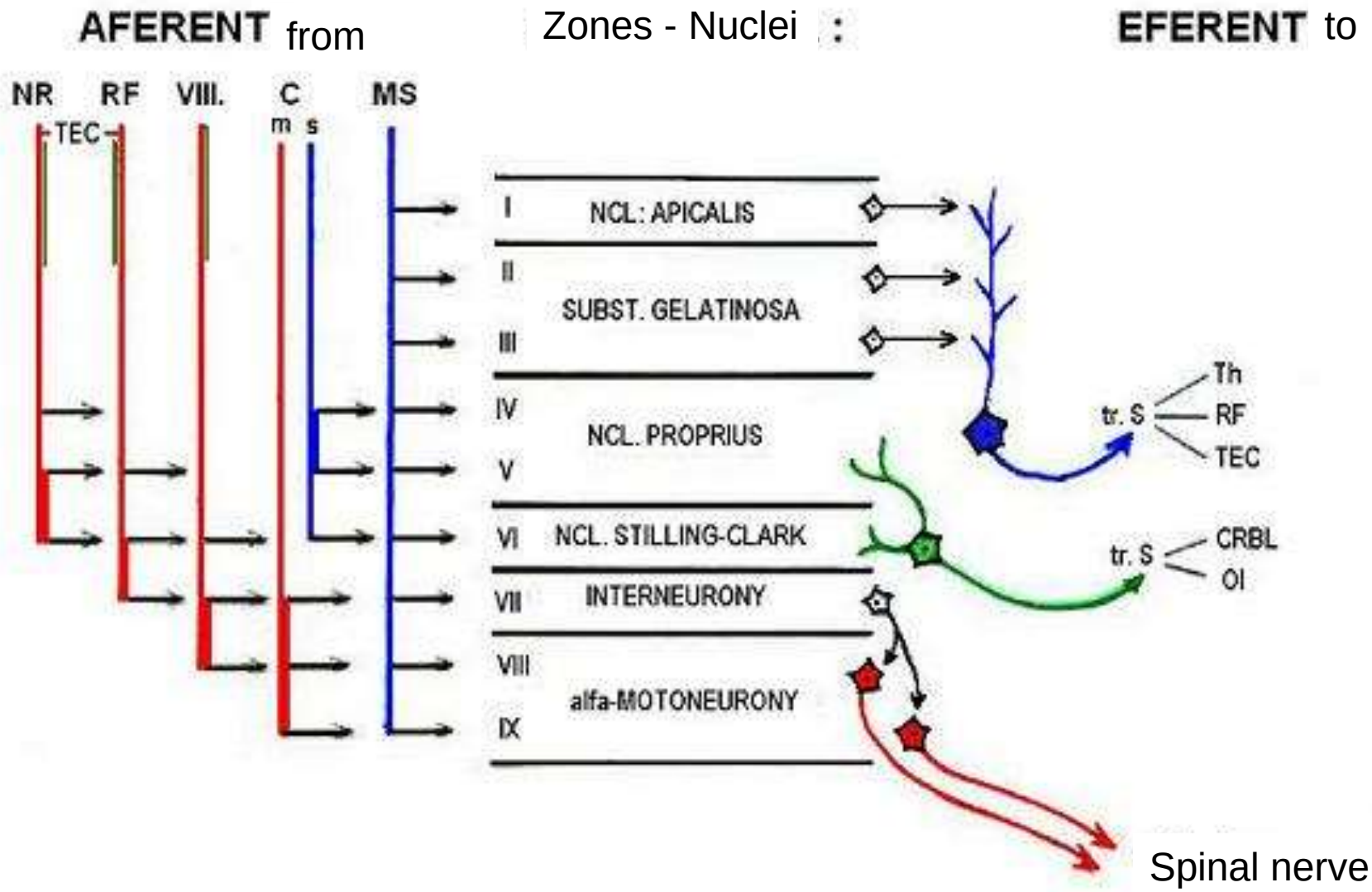

Somatotopic arrangement of motoneurons in ventral horns

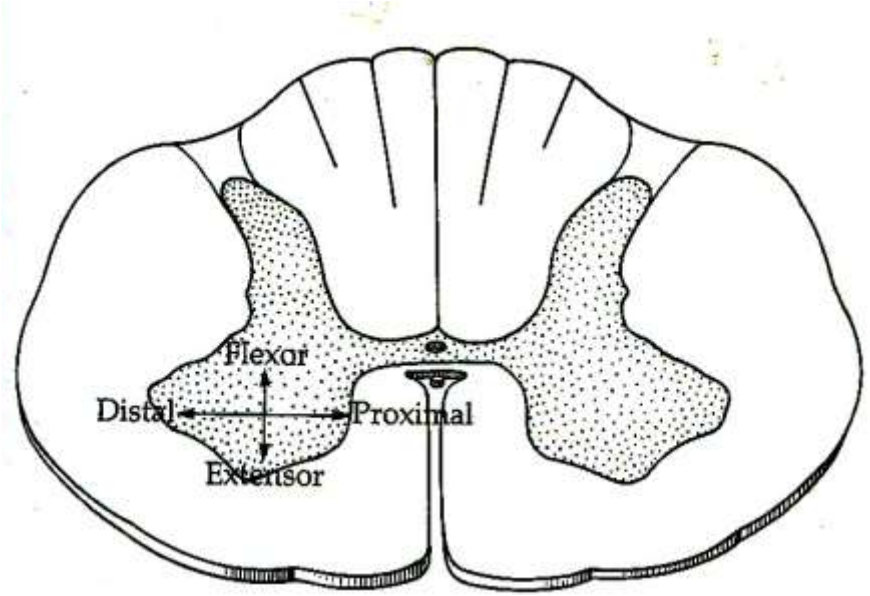

„columns“ of motoneurons for limbs, (distal muscles more caudally)
C3-C5 ncl. frenicus
S2-S3 Onuf´s nucleus – n.pudendus
C1-5 –ncl spinalis n.XI.

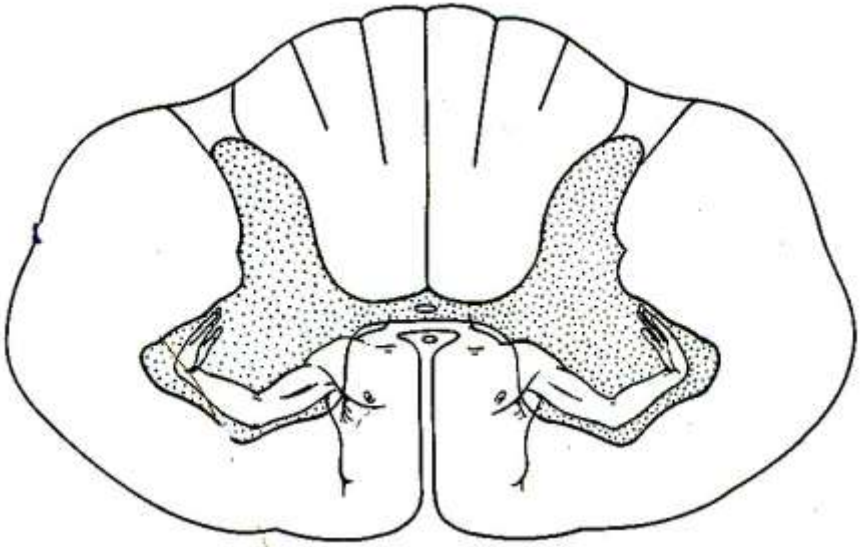

MOTOR unit

One motor unit

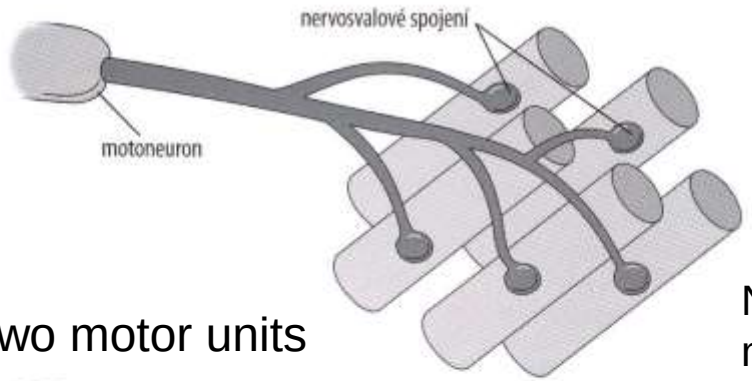

ALFA MOTONEURON
+ ALL MUSCLE FIBER
SUPPLIED BY IT

Number of fibers in unit
m. gastrocnemius (1750) x mm. lumbricales (108)

Two motor units

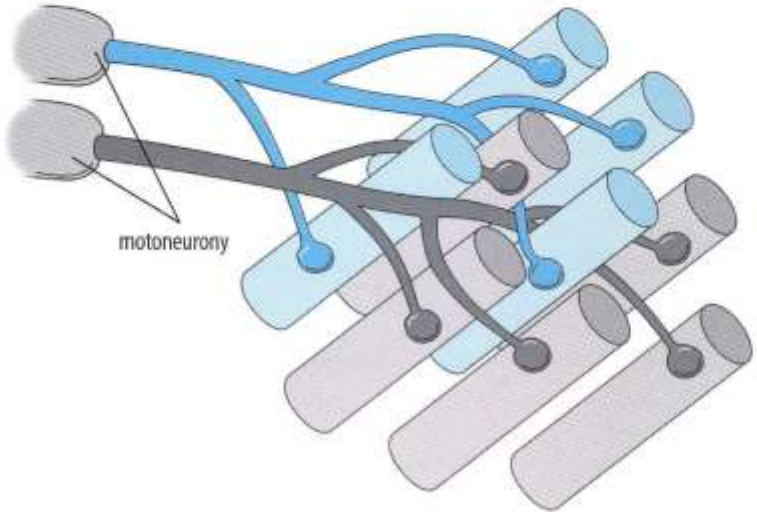

Number of units in muscle
Např. m. abduktor policis longus 400

Neurotransmitter: ACh

(gamma motoneurons – muscle spindle supplying)

Dorsal root fibers

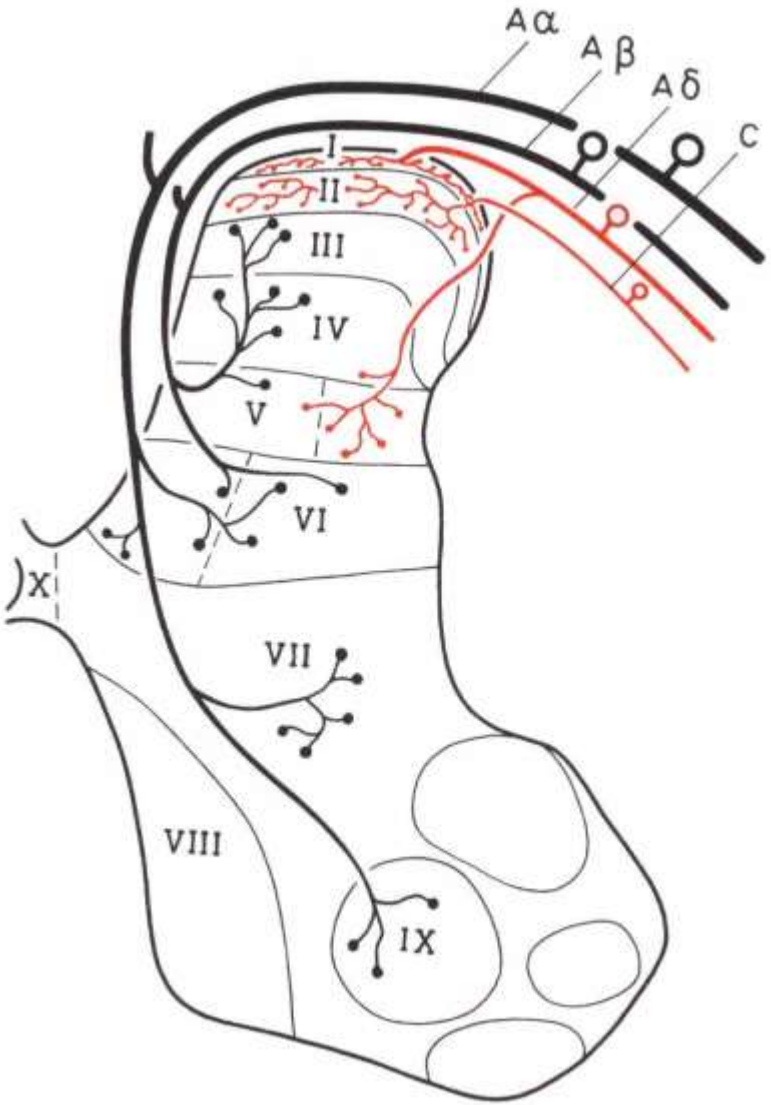

A alfa , A beta fibers– myelinized, fast conducting proprioception, touch

A delta fibers– poorly myelinized, C fibers– nonmyelinized, slow conducting fibers from nociceptors and thermoreceptors

Neurotransmitters: glutamate + substance P, VIP, cholecystokinin

White matter–propriospinal, ascendent, descendent and cerebellar tracts

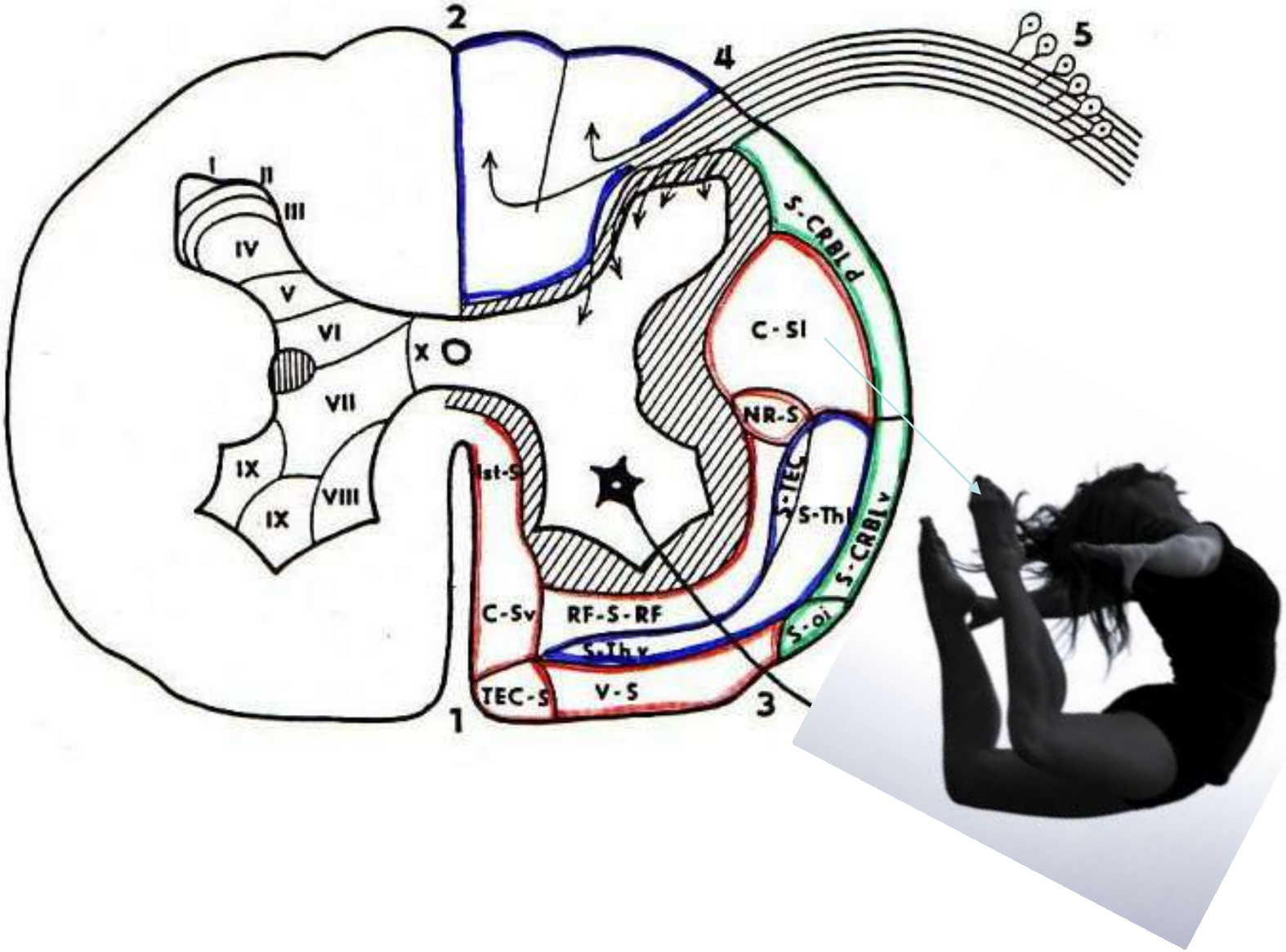

Motor pathways

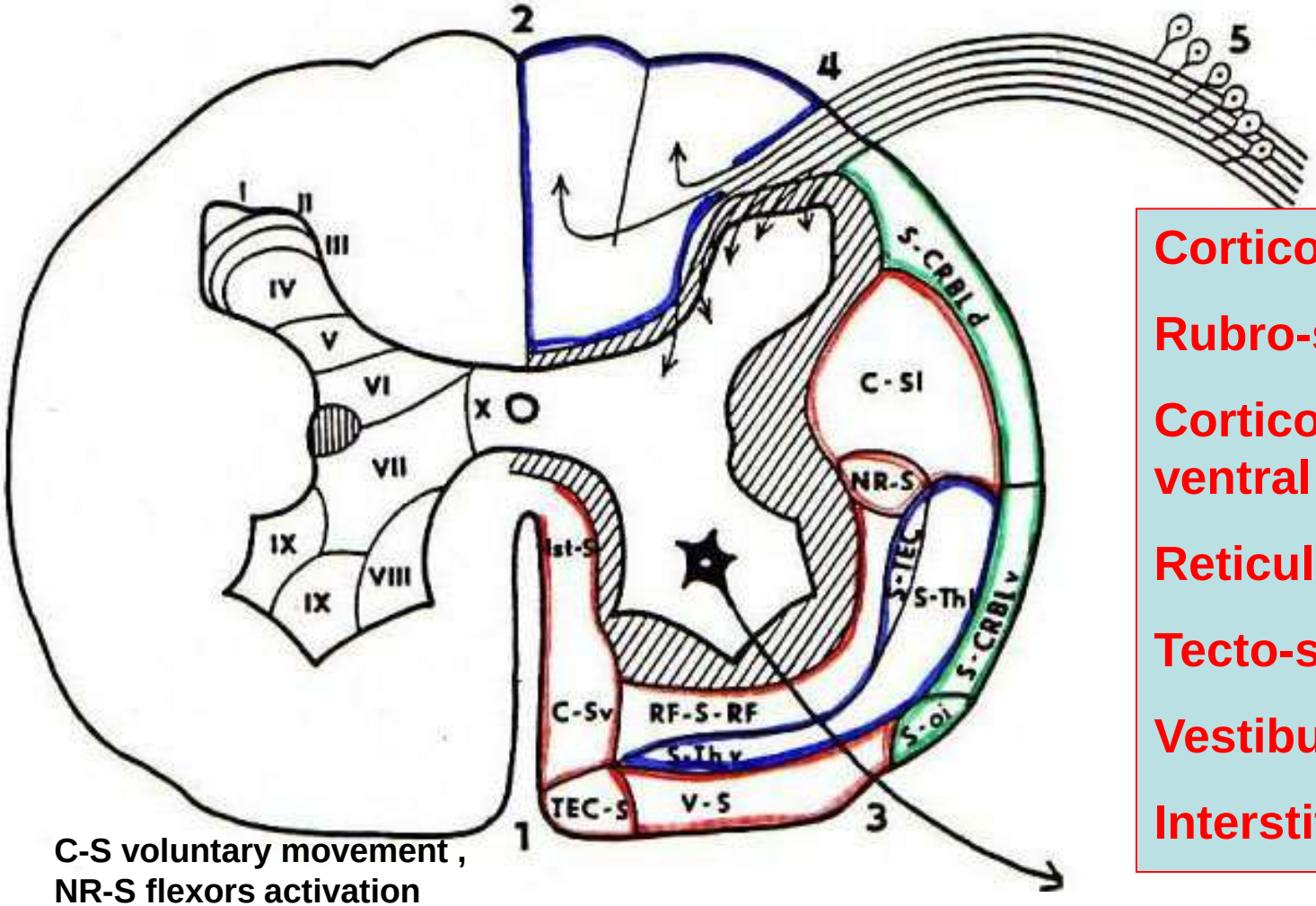

Cortico-spinal lateral

Rubro-spinal

Cortico-spinal ventral

Reticulo-spinal

Tecto-spinal

Vestibulo-spinal

Interstitio-spinal

C-S voluntary movement ,
NR-S flexors activation
Ret-S muscle tone and a „supraspinal“ movement
Te-S reaction to visual and acoustic stimuli
Ve-S extensors activation
Ist-S TV watching in laying position

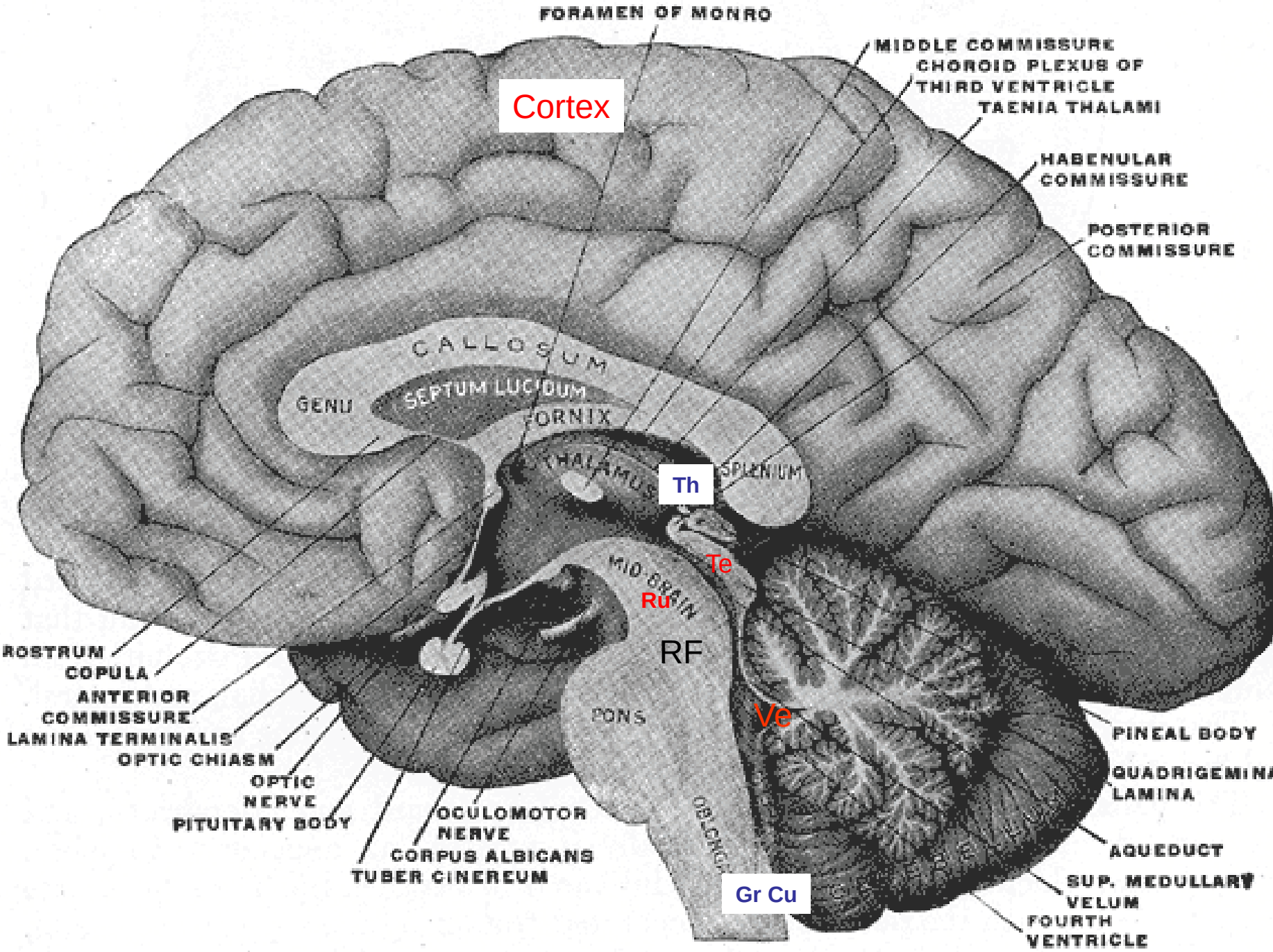
FORAMEN OF MONRO
MIDDLE COMMISSURE
CHOROID PLEXUS OF THIRD VENTRICLE
TAENIA THALAMI
HABENULAR COMMISSURE
POSTERIOR COMMISSURE
Cortex
CALLOSUM
GENU
SEPTUM LUCIDUM
FORNIX
THALAMUS
Th
SPLENIUM
Te
MID-BRAIN
Ru
RF
PONS
Ve
OBLONG
Gr Cu
ROSTRUM
COPULA
ANTERIOR COMMISSURE
LAMINA TERMINALIS
OPTIC CHIASM
OPTIC NERVE
PITUITARY BODY
OCULOMOTOR NERVE
CORPUS ALBICANS
TUBER CINEREUM
PINEAL BODY
QUADRIGEMINA LAMINA
AQUEDUCT
SUP. MEDULLARY VELUM
FOURTH VENTRICLE

Tractus cortico-spinalis (pyramidal tract)

voluntary movement

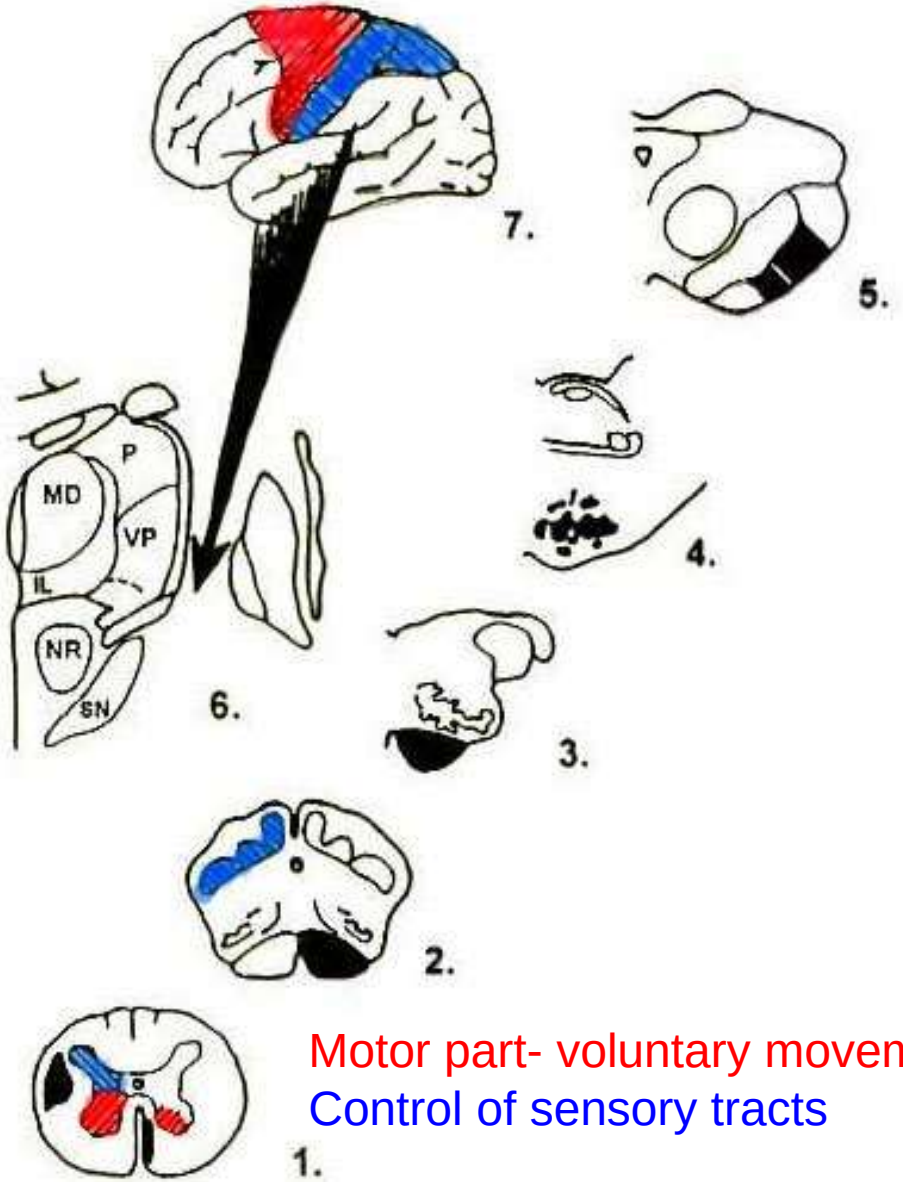

Motor part- voluntary movement

Control of sensory tracts

Lesions of motor neurons

Lesions of motor neurons, results in loss of motor function paralysis

Full paralysis – plegia

Partial paralysis – paresis

Hemiplegia – both ipsilateral extremities are affected

Paraplegia – either both upper or lower extremities are affected

Quadruplegia – all 4 extremities are affected

Basic signs of motor activity disorders

Lower motor neuron lesions *(poliomyelitis or nerve lesion)*

Muscle tone and stretch and tendon reflexes are reduced or absent (flaccid paralysis)

Progressive atrophy of muscles occurs

EMG detects fibrillation potentials caused by isolated contrations of denervated muscles

In partially denervated muscles, the inervation is being renewed

- **Upper motor neuron lesions *(bleeding in capsula interna or transected spinal cord)***
- **Muscle tone and stretch and tendon reflexes are increased (spastic paralysis)**
- **Superficial reflexes (abdominal and cremasteric ones) are extinct**
- **An abnormal plantar Babinski reflex occurs**
- **Voluntary movements are reduced or absent**

wireless electronic connection between the brain and spinal cord restored movement in two monkeys that were each paralysed in one leg as a result of a spinal-cord injury.

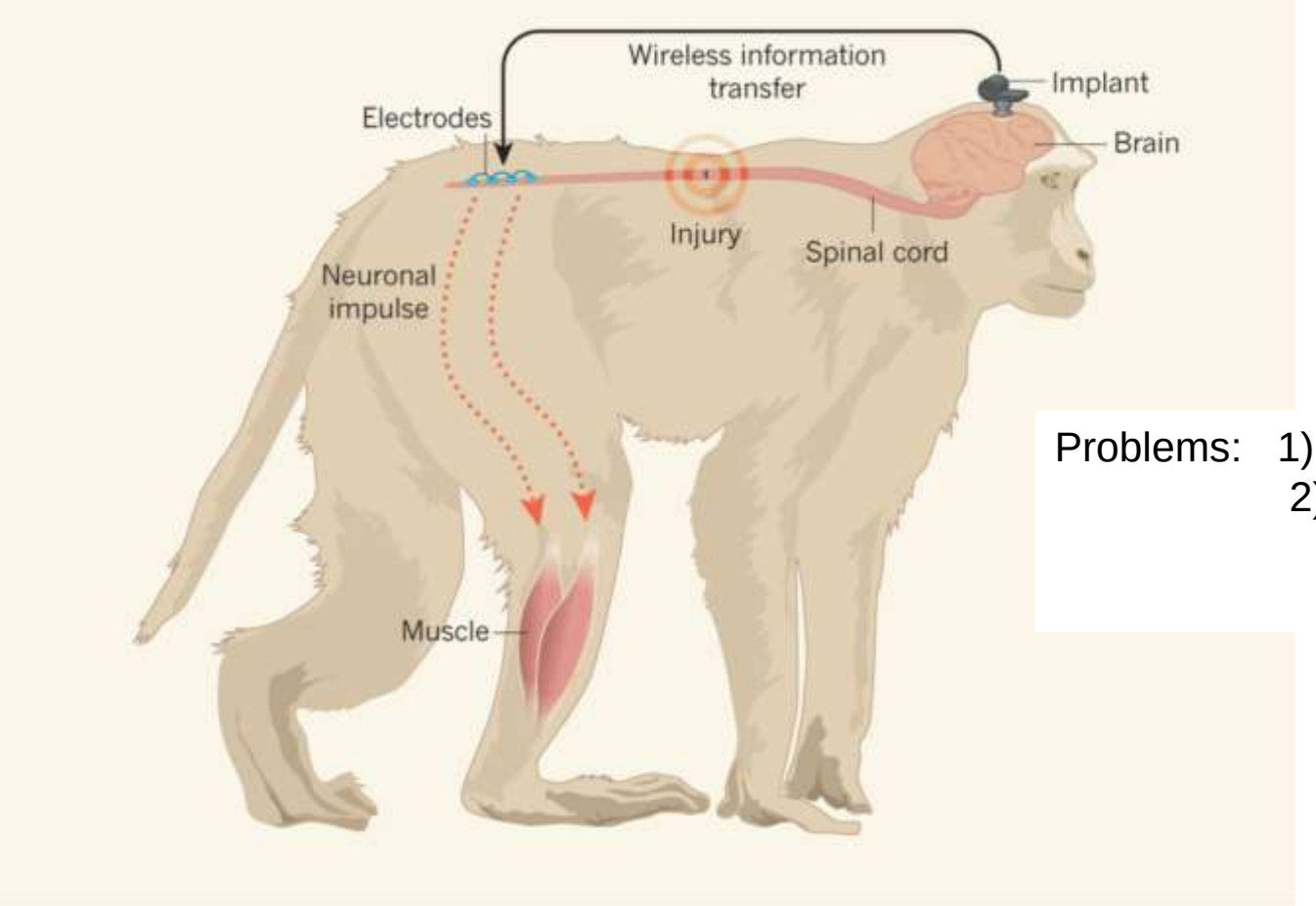

Capogrosso *et al.*[1] established a neural-interface system that enabled communication between the brain and spinal cord in monkeys subjected to a spinal-cord injury that paralysed one leg. An implant in the brain recorded neural activity related to leg movements, and transmitted this information to electrodes at the base of the spinal cord via a wireless link. These electrodes triggered neuronal impulses that generated movement in the leg muscle, allowing the monkeys to walk freely, despite their injury. (Adapted from Fig. 1 of ref. 1.)

Bipedal walking?

Problems: 1) maintain balance
2) targeting the movement

Spinal-cord injury: Neural interfaces take another step forward
Andrew Jackson, Nature 539,2016

1) tractus interstitiospinalis
2) tractus vestibulospinalis

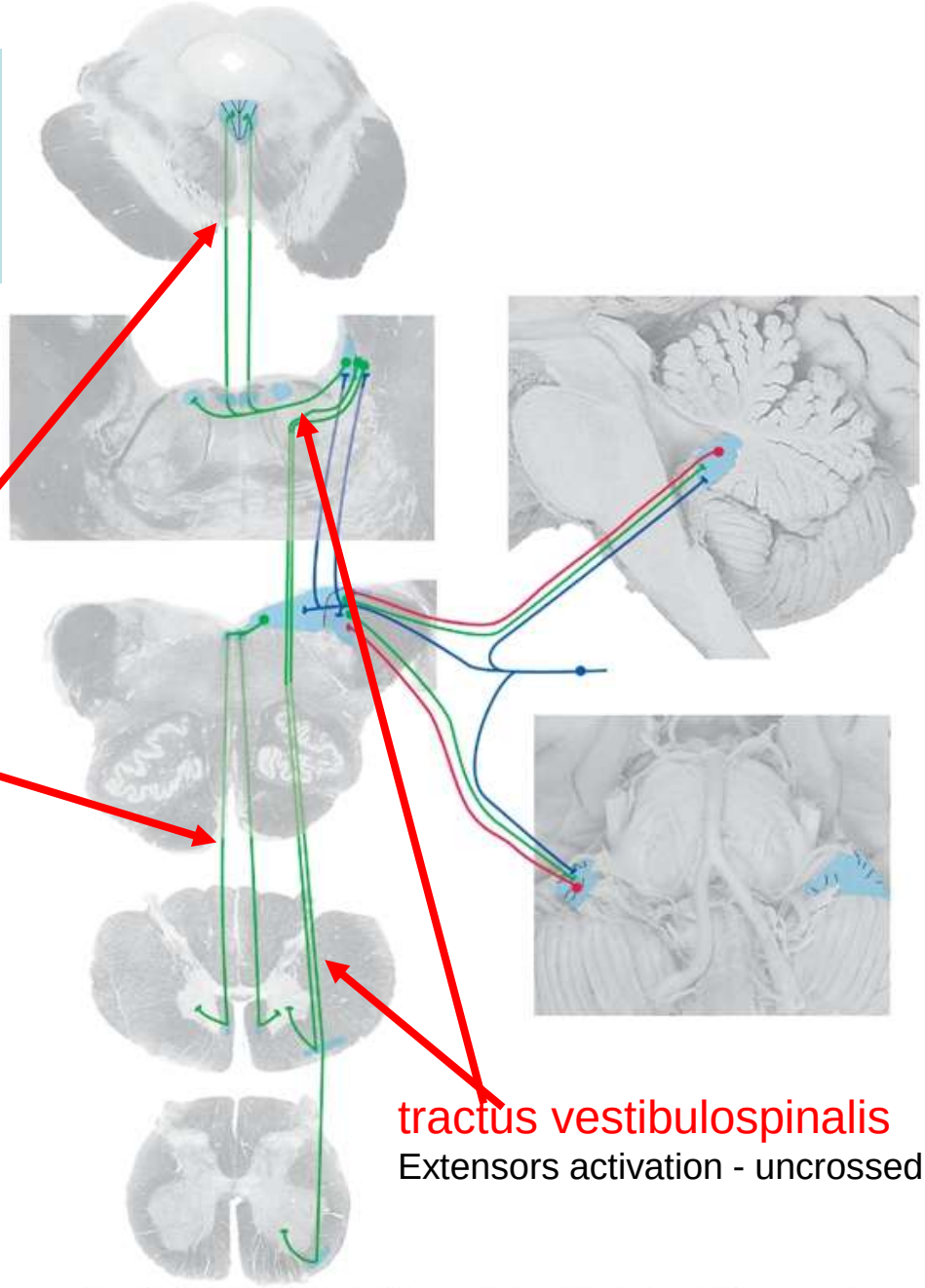

tractus interstitiospinalis

PART OF medial longitudinal fascicle
Coordination of neck and oculomotor muscles in change of head position

tractus vestibulospinalis

Extensors activation - uncrossed

Sensory tracts 1) dorsal column lemniscal tract – proprioception, vibration, touch
2) anterolateral systém pain, touch, activation

DK

Fasciculus gracilis Golli

HK

Fasciculus cuneatus Burdachi

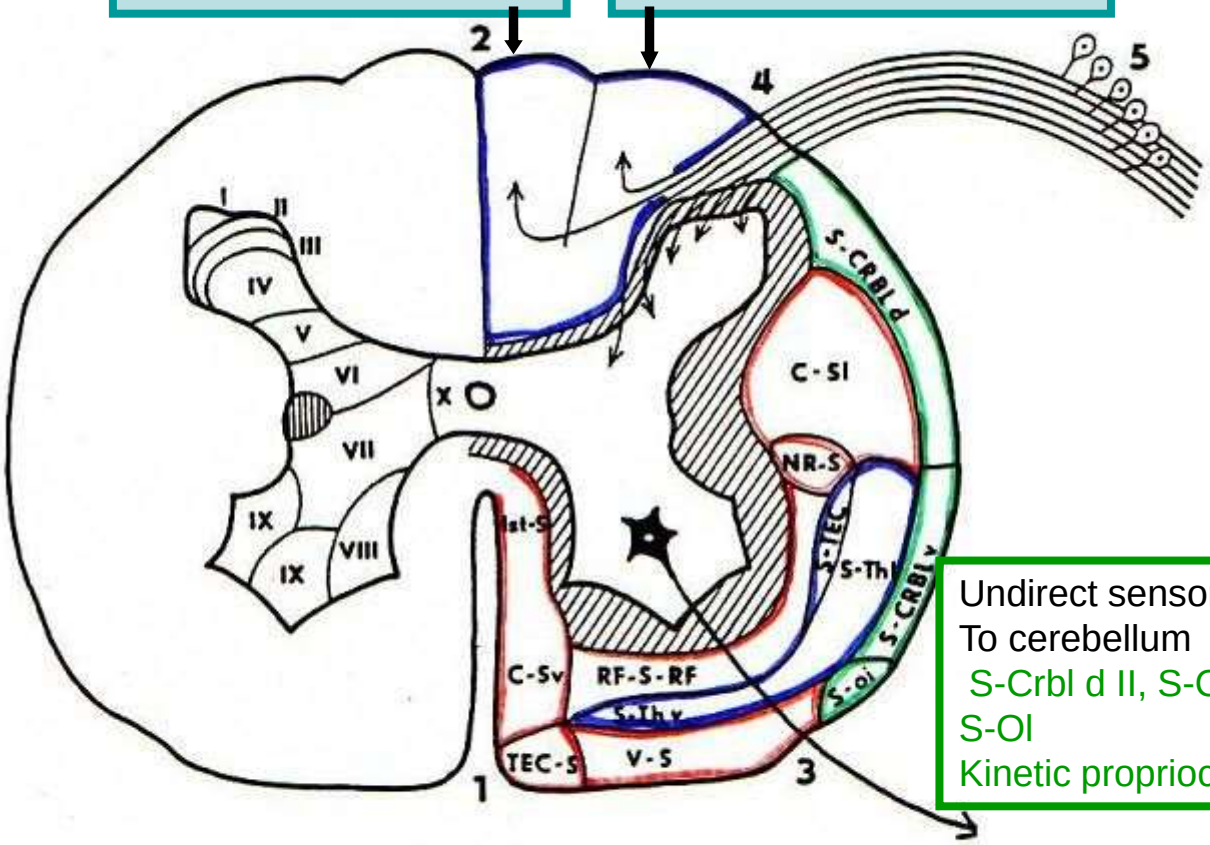

Undirect sensory tracts
To cerebellum
S-Crbl d II, S-Crbl v X
S-Ol
Kinetic proprioception from lower limbs

Anterolateral system

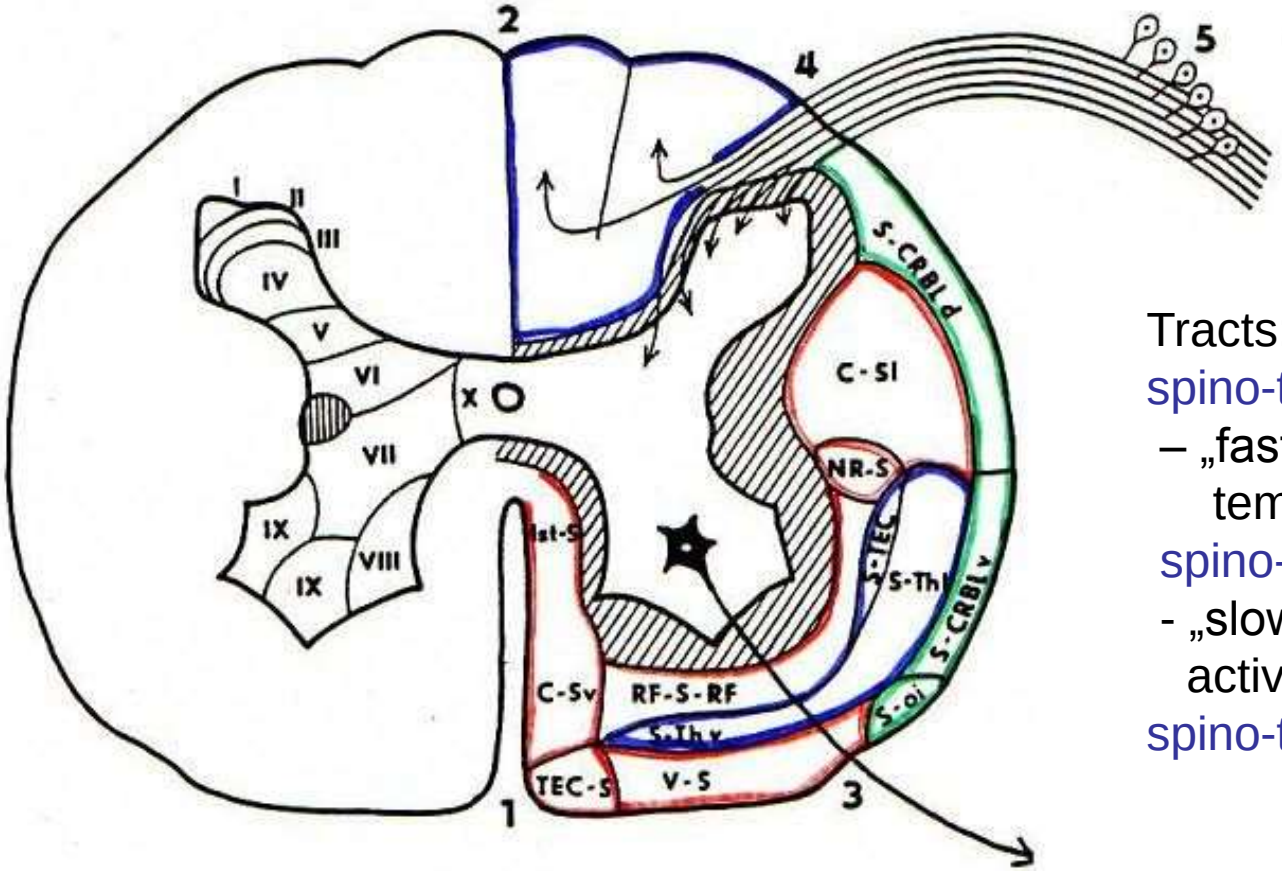

Tracts:

spino-thalamic X

– „fast“ pain, temperature, touch

spino-reticularis X, II

- „slow“ pain activation

spino-tectal X

Spinal cord – center of reflexes

Patelar (knee jerk) reflex L2-L4

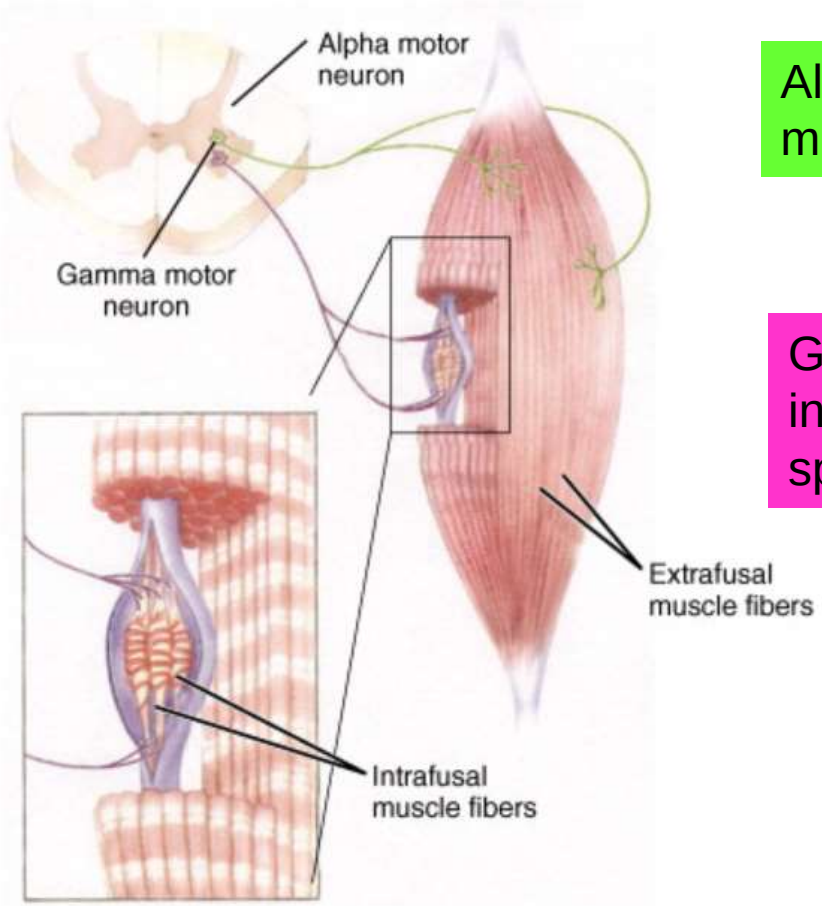

Alfa motoneuron – striated muscle – extrafusal fibers

Gamma motoneuron – intrafusal fibers of mucle spindle

Figure 15-4.
The parallel organization of the alpha and gamma lower motor neurons. The alpha motor neuron innervates extrafusal skeletal muscle; the gamma motor neuron innervates the intrafusal muscle fibers to ensure proper sensory feedback from the muscle spindle. The activity of both motor neurons is modulated by multiple segmental and suprasegmental inputs.
(From Bear MF, Connors BW, Paradiso MA: Neuroscience, Exploring the Brain, 2nd ed. Baltimore, Lippincott Williams & Wilkins, 2001.)

Williams & Wilkins

Muscle spindle –stretch gated receptor

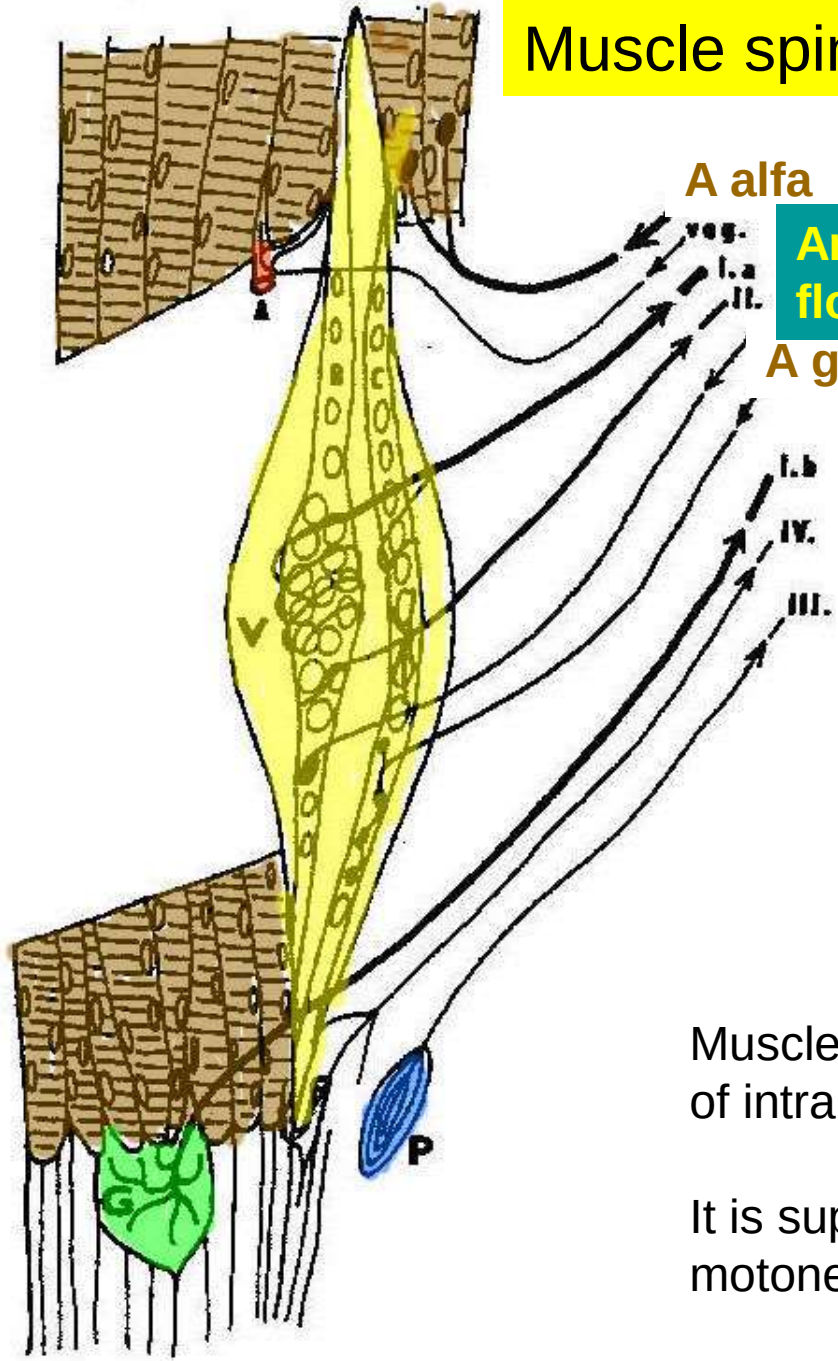

A alfa

Anulospiral ending, flower spray ending

A gamma

Golgi tendon organ – tension gaited receptor

Pain, temperature

Vibration, pressure

Muscle spindle compares the length of intra and extrafusal fibers

It is supplied from gamma motoneurons

Gamma loop mechanism

Gamma motoneuron – sensory neuron-alfa motoneuron

For muscle tone controle

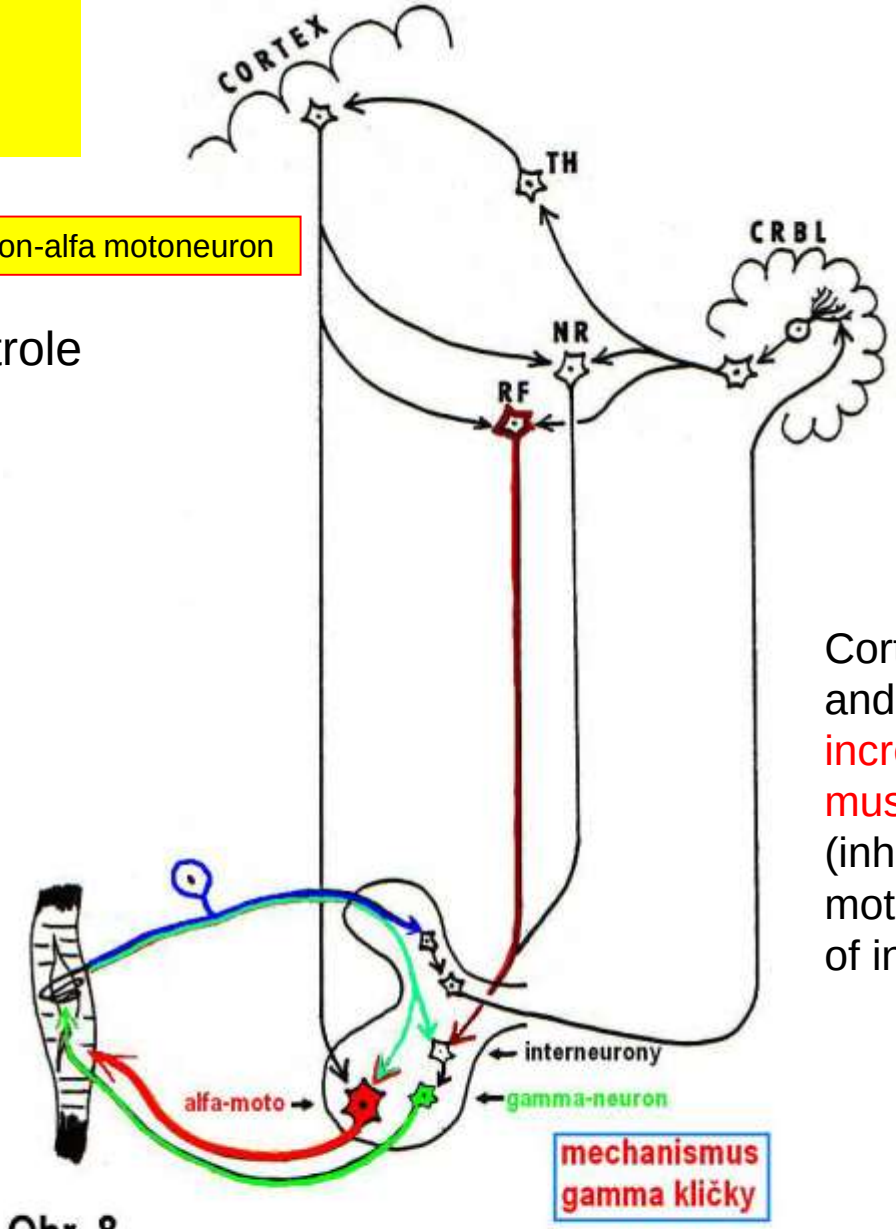

Cortex, reticular formation and red nucleus can increase (or decrease) the muscle tone by activation (inhibition) of gamma motoneurons (contraction of intrafusal fibers)

Obr. 8

Gamma motoneurones and muscle tone

a – alfa-motoneuron,
CRBL – cerebellum,
g – gamma-motoneuron,
i – interneuron,
NR – ncl. ruber,
RF – retikulární formace,
Th – thalamus

Proprioceptive reflexes

Muscle spindle

Tendon body

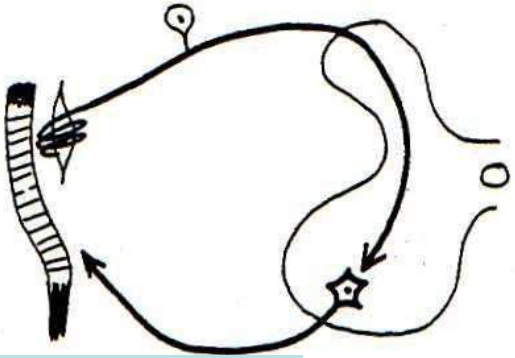

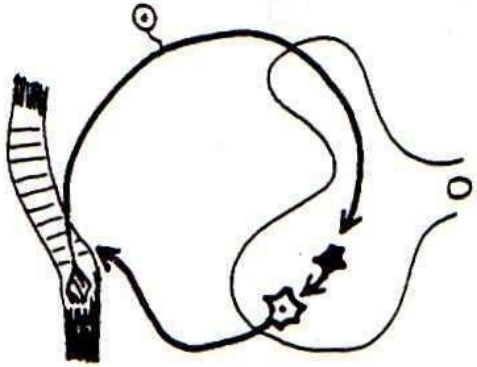

Knee jerk reflex
elongation of muscle -
contraction

B

Inhibits contraction

reciprocity

Relax of antagonist

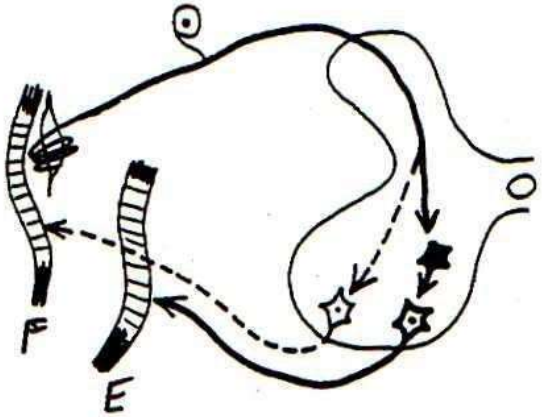

C

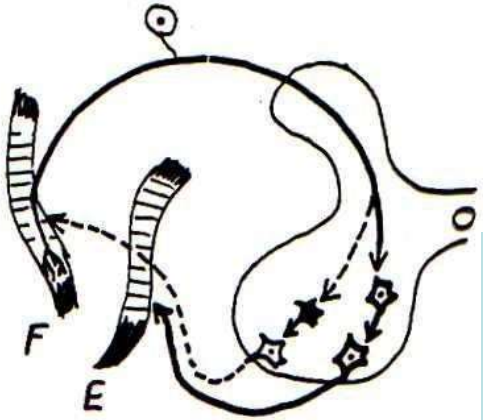

D

Contraction of antagonist

Proprioceptive reflexes circuits

Renshaw

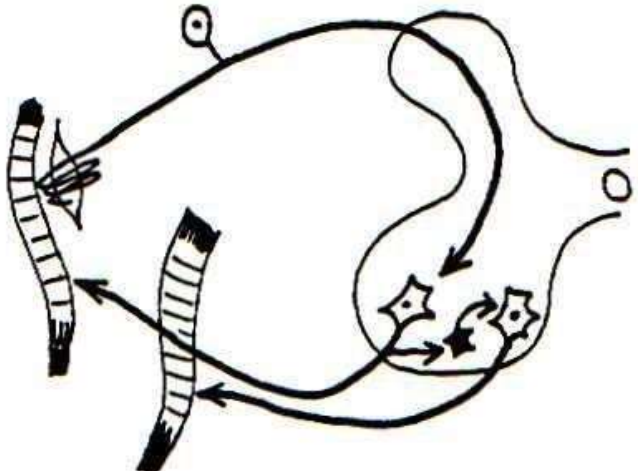

A „supraspinální“ pohyb

polysynapt. segmentální

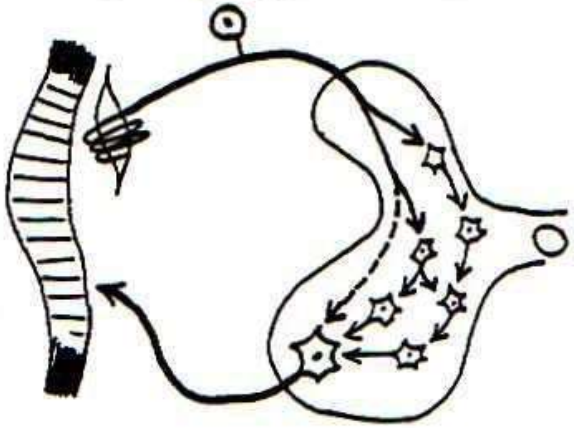

B Gravity

Polysynaptic
polysegmentál

Neck reflexes

Head dorsiflexion (extensors in action) – upper limb (HK) extension and lower limb (DK) flexion

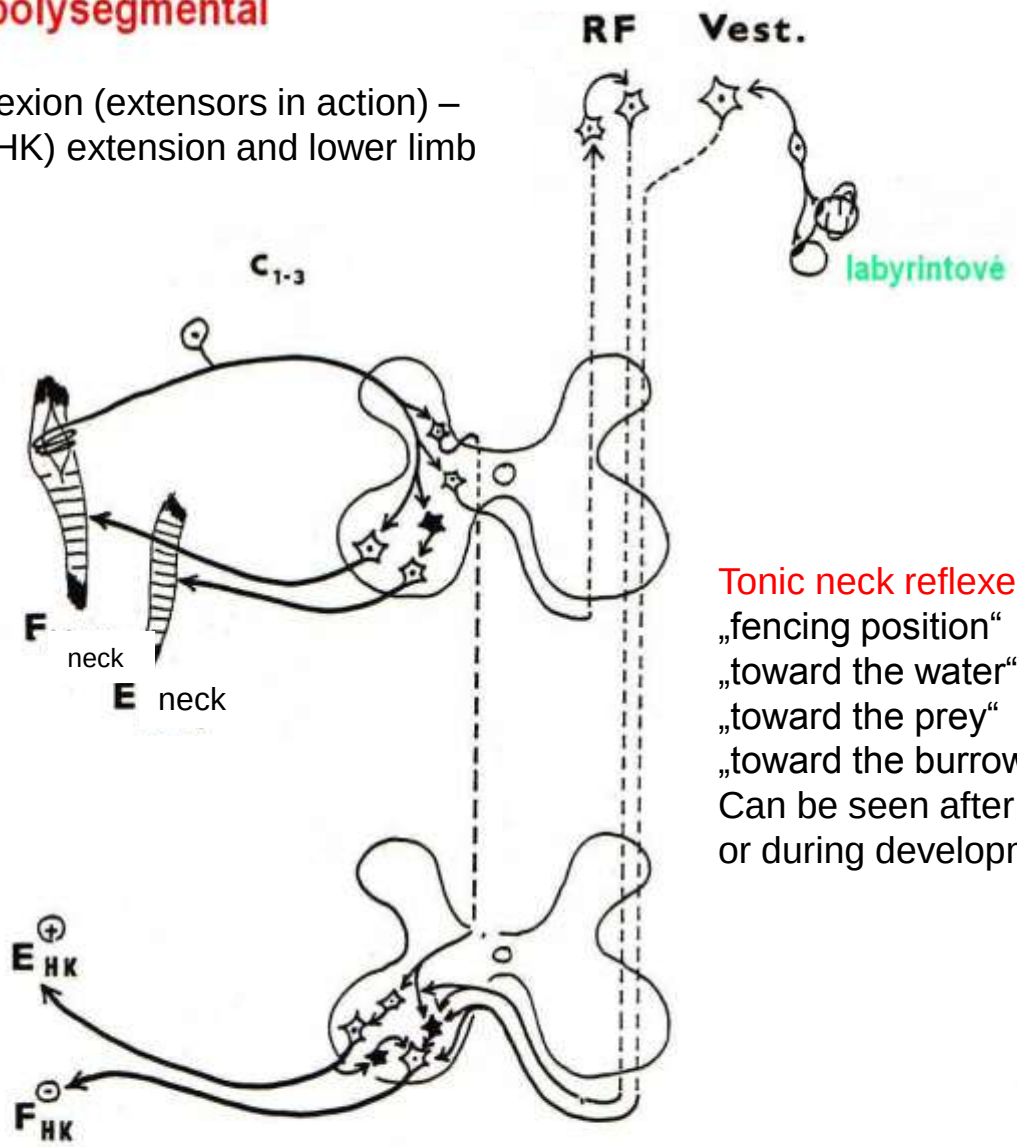

Tonic neck reflexes
„fencing position“
„toward the water“
„toward the prey“
„toward the burrow“
Can be seen after bilateral labyrintectomy or during development

Obr. 5: **Proprioceptivní reflexní dráhy: Dráhy polysynaptického réflexu polysegmentálního na příkladu drah šíjových reflexů.**

E – svalové extensoři,
F – svalové flexoři,
HK – horní končetina,
RF – retikulární formace,
Vest – vestibulární jádra
Inhibiční buňky černě.

Retikulo-spinální a vestibulo-spinální dráhy jsou z technických důvodů zakresleny zkřížené v míšním segmentu.

Tonic neck reflex – fencing posture

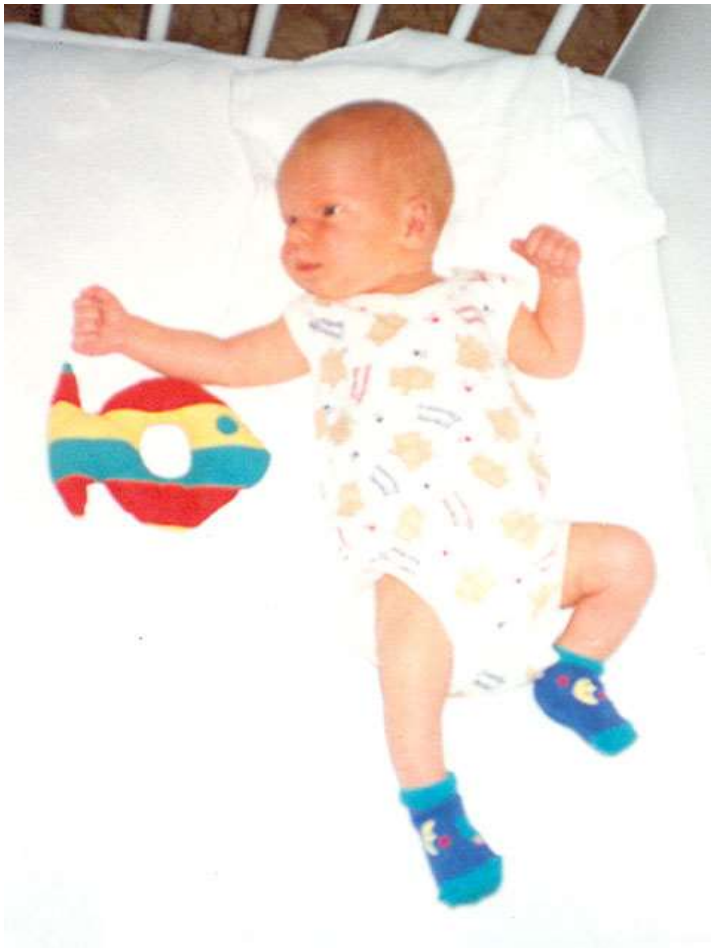

Sensory loss

Posterolateral sclerosis

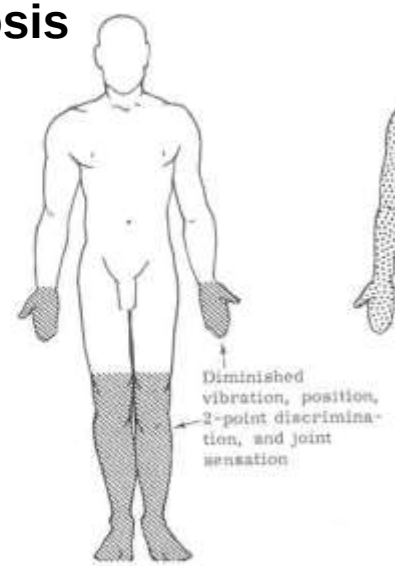

Syringomyely

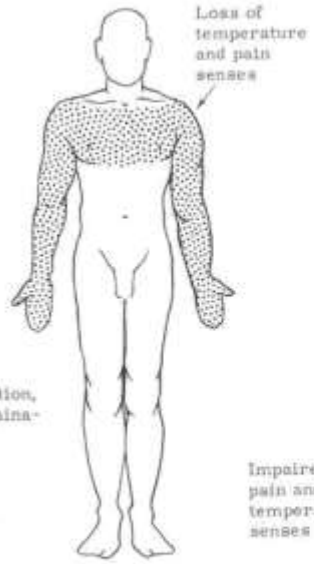

Brown-Sequard syndrome

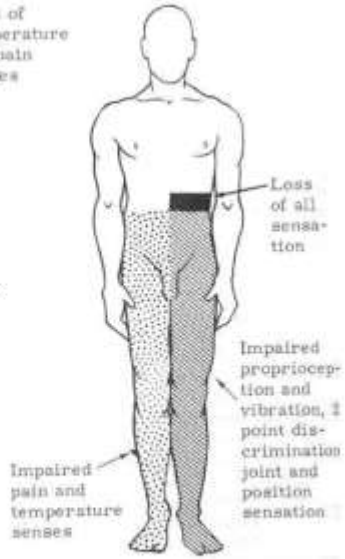

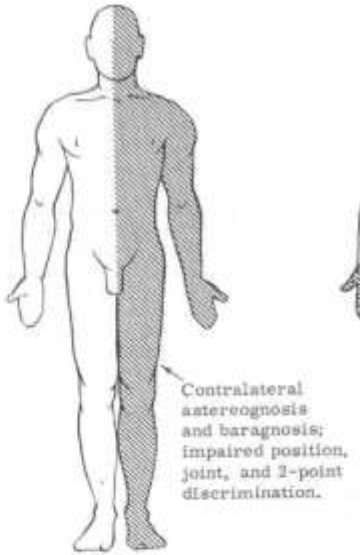

Parietal cortex lesion

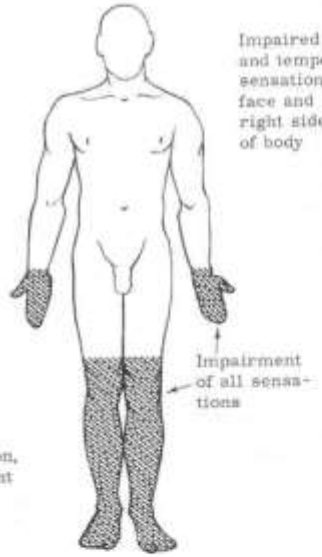

Polyneuritis

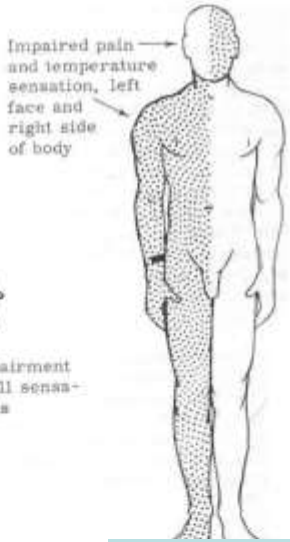

Left posterior inferior cerbellar art. occlusion

Postero-lateral sclerosis

Syringomyelie

Brown-Sequard sy

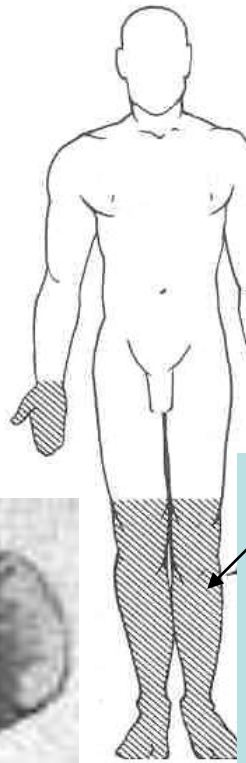

Deminished vibration, position, 2-point discrimination and joint sensation

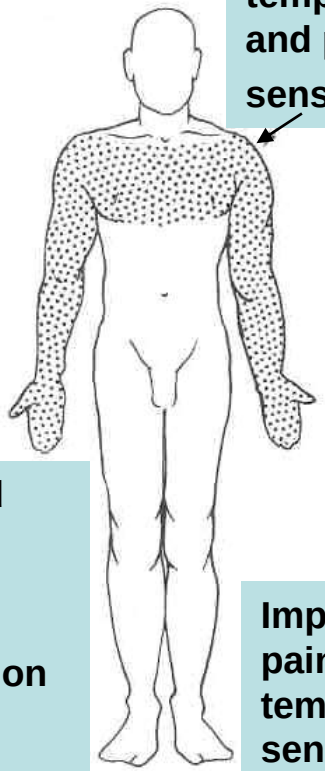

Loss of temperature and pain senses

Impaired pain and temperature sensation

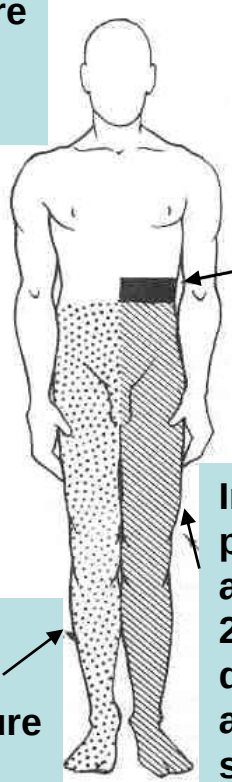

Loss of all sensationes

Impaired proprioception and vibration, 2-point discrimination and position sensation

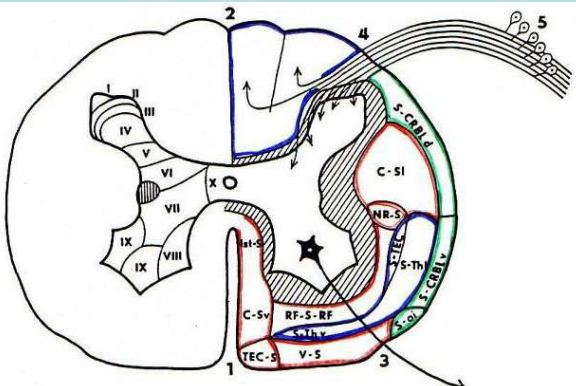

Syringomyelia

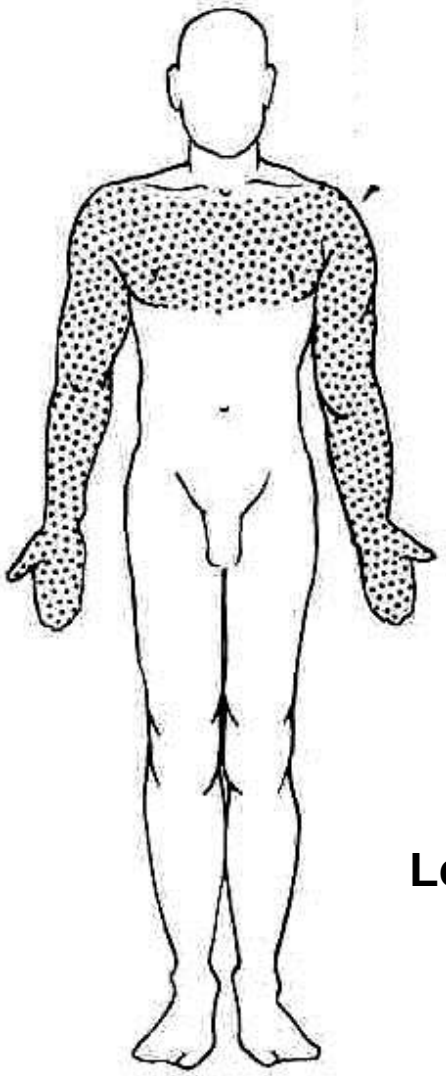

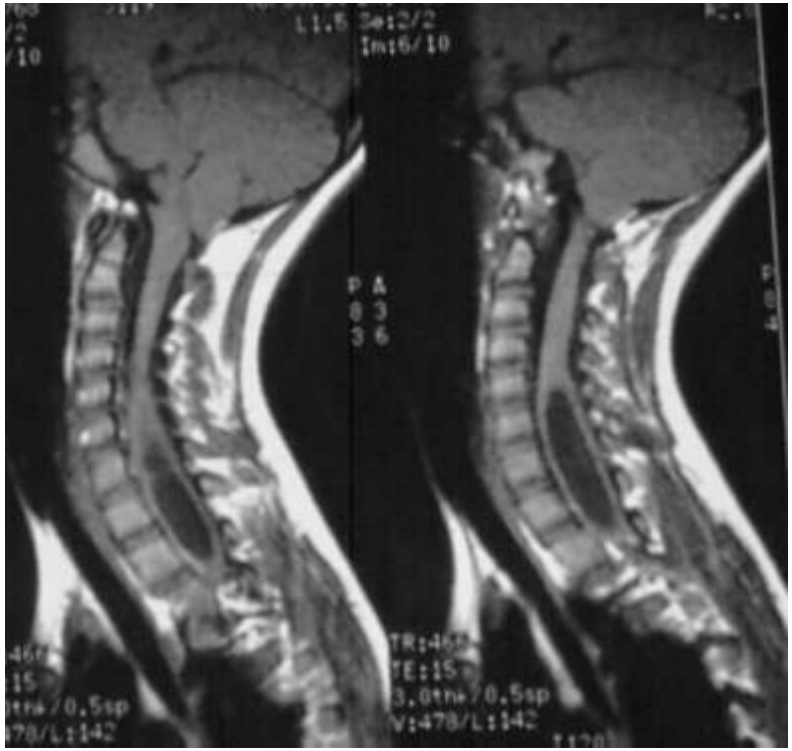

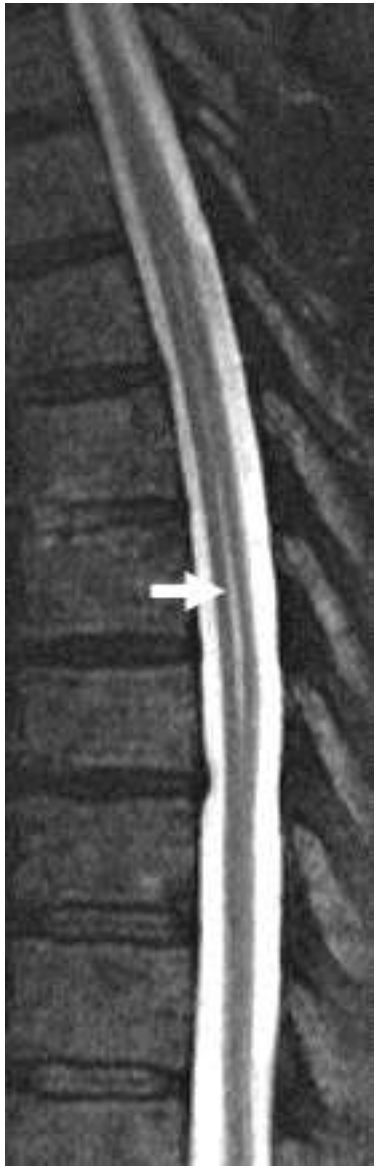

Loss of temperature and pain senses

Lateral medullary syndrome (left posterior inferior cerebellar artery occlusion)

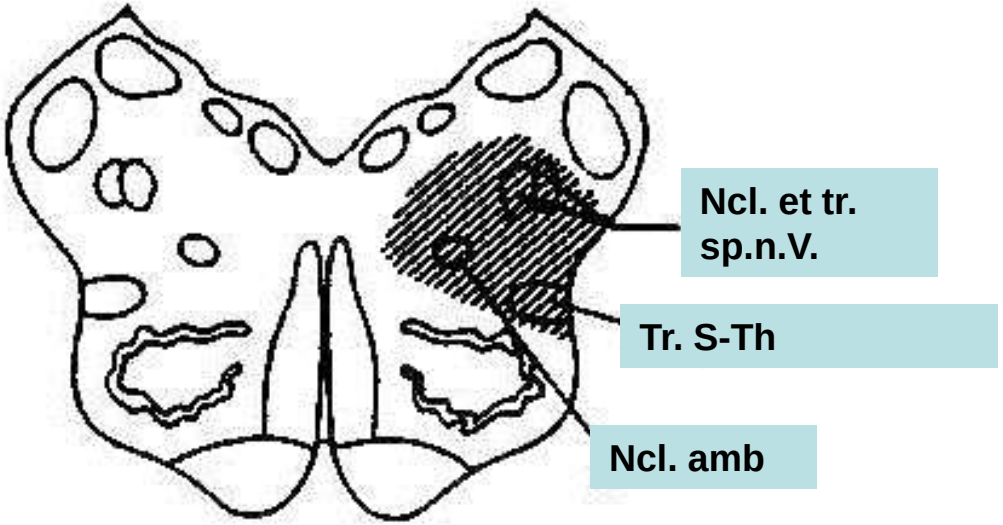

Impaired pain and temperature sensation left face and right side of body

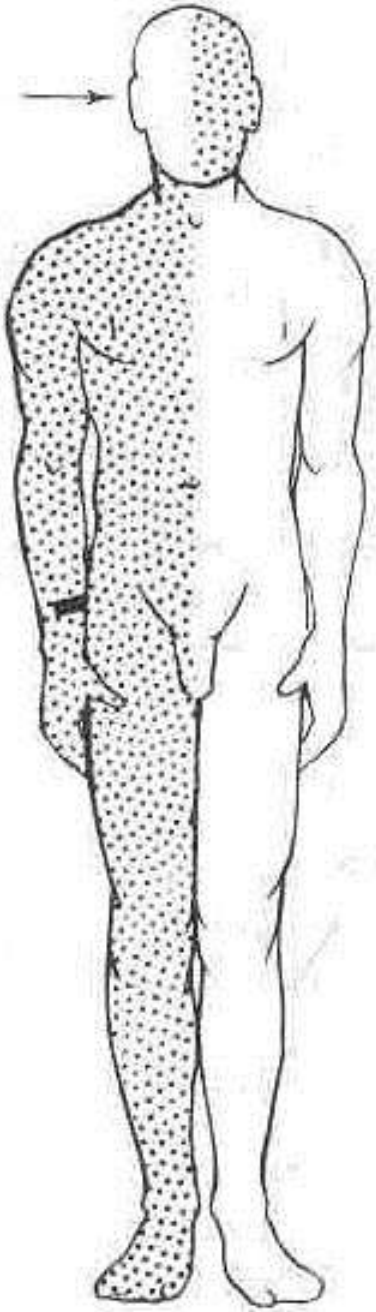

Spinal cord lesion

1) Motor defects– paresis, plegie .

central (spastic), periferal (flaccid), mixed

2) Sensory defects

a) **Radicular syndrome**(dermatomes) e.g. disc prolaps

hypestesia, anestesia, parestesia, hyperestesia

b) **Syringomyelic dissociation** – Loss of temperature and pain senses

c) **Brown Séquardům syndrom** (např. intramedular expansion)

bellow the lesion is ipsilateral deep sensory loss (dorsal column tract) and motor defect (cortico-spinal tract), kontralateral pain and temperature sensory loss)

d) **Dorsal column syndrom**(e.g. neuranemic syndrom, tabes dorsalis)

loss of proprioception

3) Medullary epiconus syndrome (lesioned segments L4-S2) lower limbs paraparesis. Not affected hip adduction and hip flection, knee extension, loss of sensation bellow the knee and posterior upper tight, automatic bladder, lesioned erection and ejaculation

4) Medullary conus syndrome (lesioned segments S3-S5) loss of sphincters control, automatic bladder, saddle like sensory loss

5) Cauda syndrome(lesion of spinal nerve root bellow L2)

low back pain, sciatica (unilateral or, usually, bilateral), saddle sensory disturbances, bladder and bowel dysfunction, and variable lower extremity motor and sensory loss

Spinal cord problems

1) Developmental malformation (neural tube closure defects, syringomyelie)
2) tumors (intramedullar, extramedullar)
3) Trauma (comotion, contusion)
4) Vascular disease (ischemie, hemorhagie)
5) Degenerative disease (ALS,)
6) Degenerative vertebral disease

Neurosurgery can solve

- 1) Anterior spinal artery syndrome (e.g. in vertebral body fracture and compression in vertebral canal) – plegia, loss of pain and temperature sensation, remains only proprioception (vibration)
- 2) Posterior spinal artery syndrome (e.g. in epidural expansion, stab wound) – loss od proprioception and lesiond motor aktivity of distal parts of limbs
- 3) Brown Sequard rare
- 4) Central gray matter syndrome– hyperintensity on MR,
- Affected cortico-spinal tracts, paresis on distal parts of upper limbs
- 5)Compressive spinal cord syndrome – tumor, abscess, tuberculosis
- 6) Syringomyelia.
-

Transverse spinal cord lesion

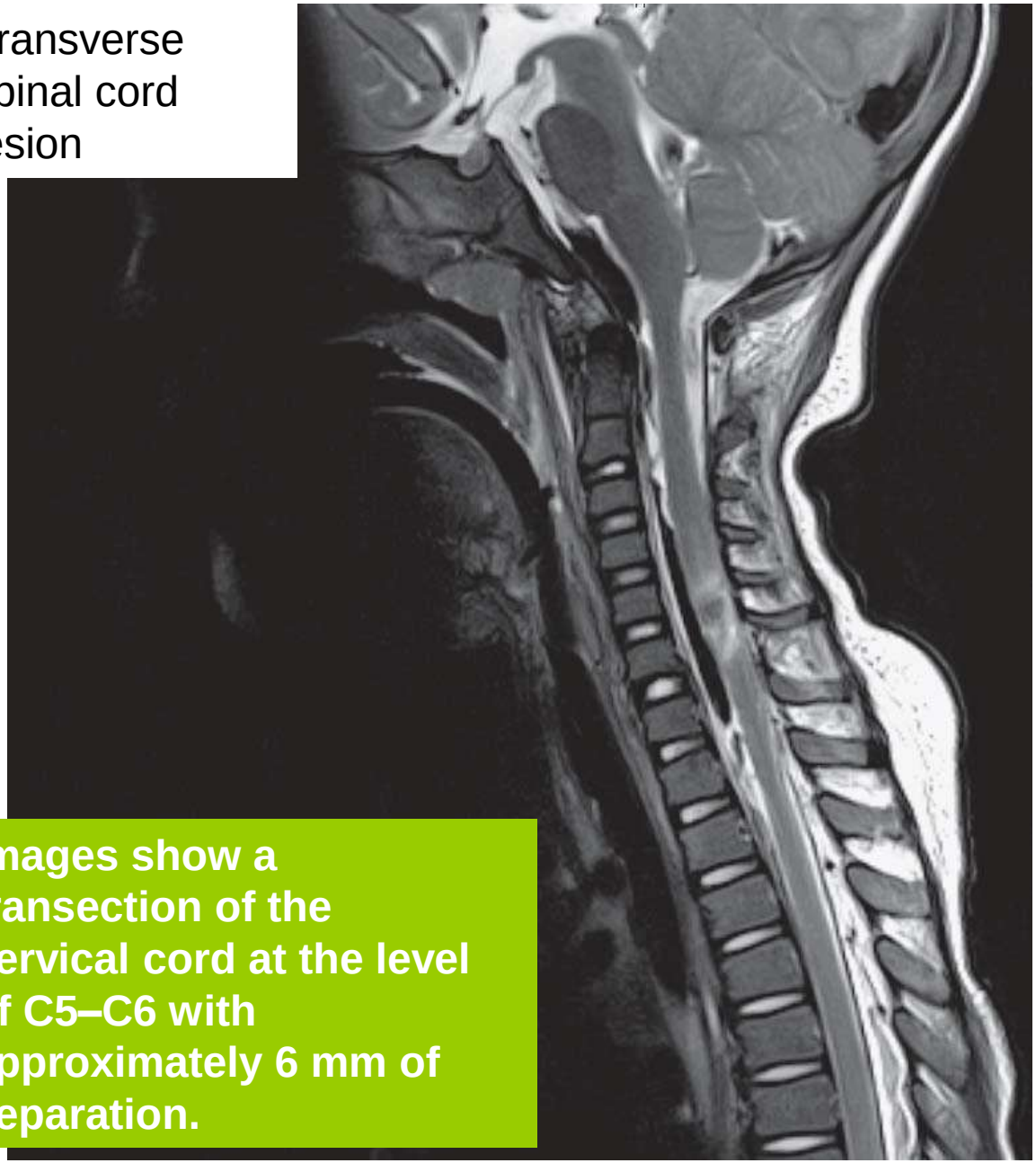

Images show a transection of the cervical cord at the level of C5–C6 with approximately 6 mm of separation.

Patient history

4-year-old female patient was involved in a high-speed vehicle accident. At the scene the girl was distressed, bradycardic and not moving limbs. She was transferred to the Pediatric Trauma Centre and MR imaging requested for prognostic information regarding treatment

The sagittal T2-weighted Turbo Spin Echo image demonstrates a traumatic transection of the spinal cord at the level of C5–C6.

24-year-old man involved in high speed motor vehicle accident

MR -marked anterior subluxation of C6 on C7, transection of the spinal cord (black arrow), edema and hemorrhage in the prevertebral soft tissues (red arrows) and spinal cord edema extending from C4 to T1 (yellow arrows).

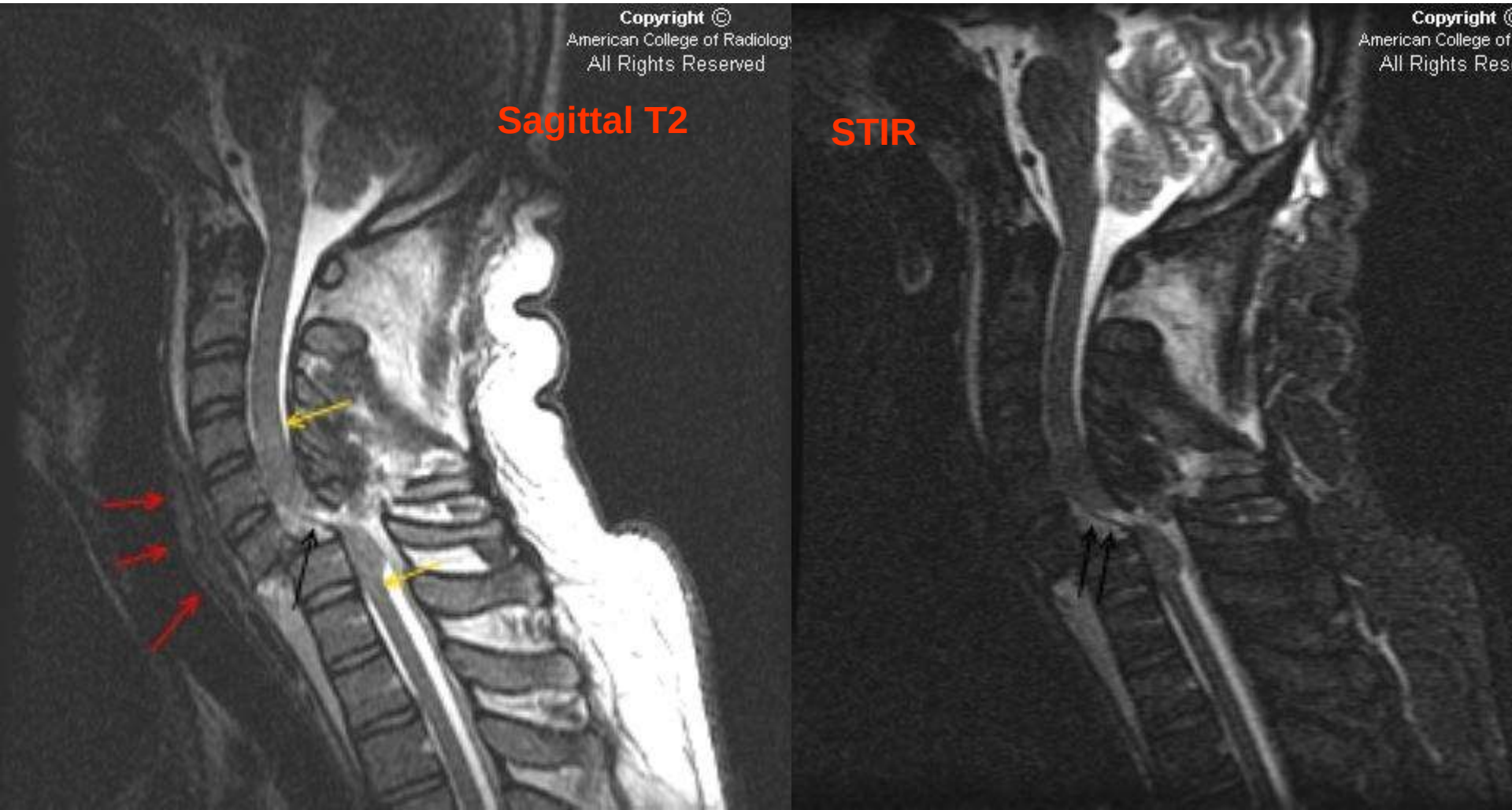

- Sagittal image shows marked subluxation of C6 on C7 (black arrows) with marked narrowing of the spinal canal.

Sagittal images of the right facets and left facets. The bilateral jumped facets are seen (black arrows).

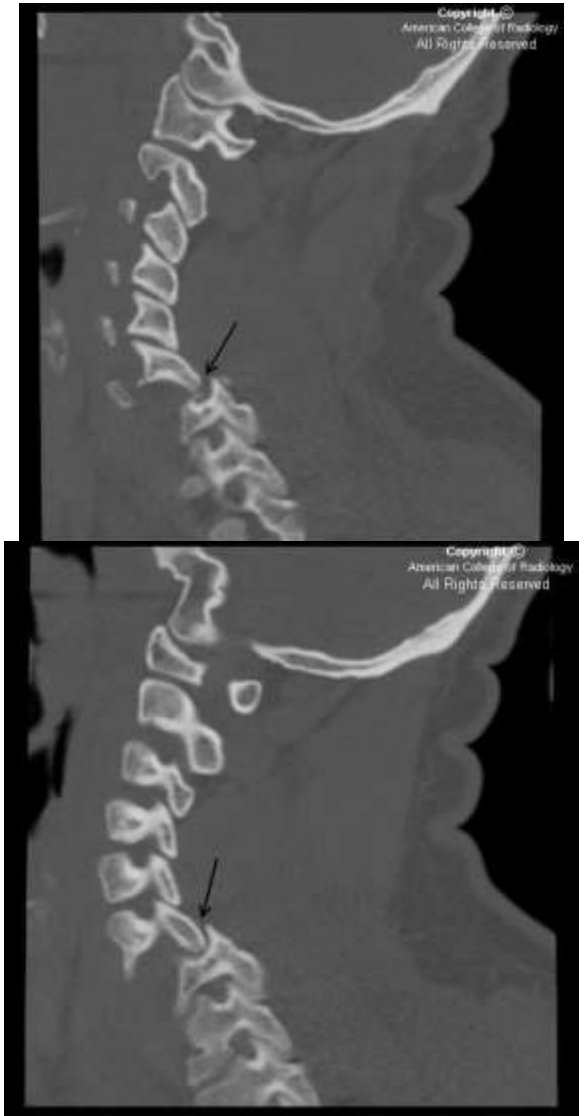

MR T1 - Syringomyelia – cavity inside the cervical spinal cord

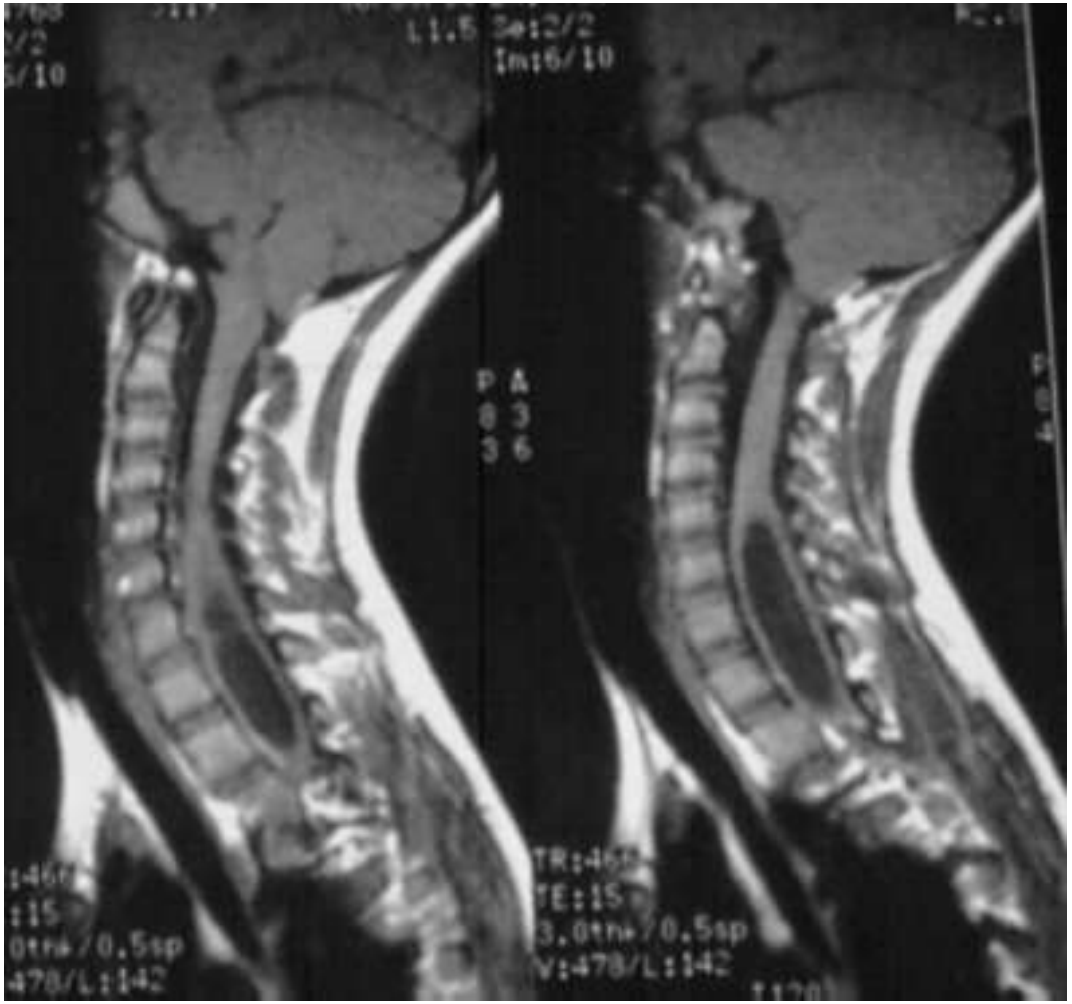

MR T2 syringomyelia
thoracic spinal cord

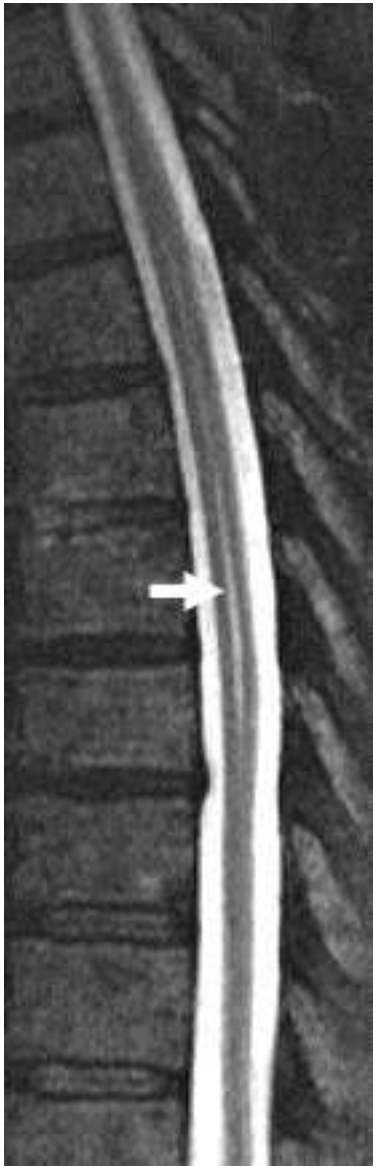

Syndrom syringomyelie

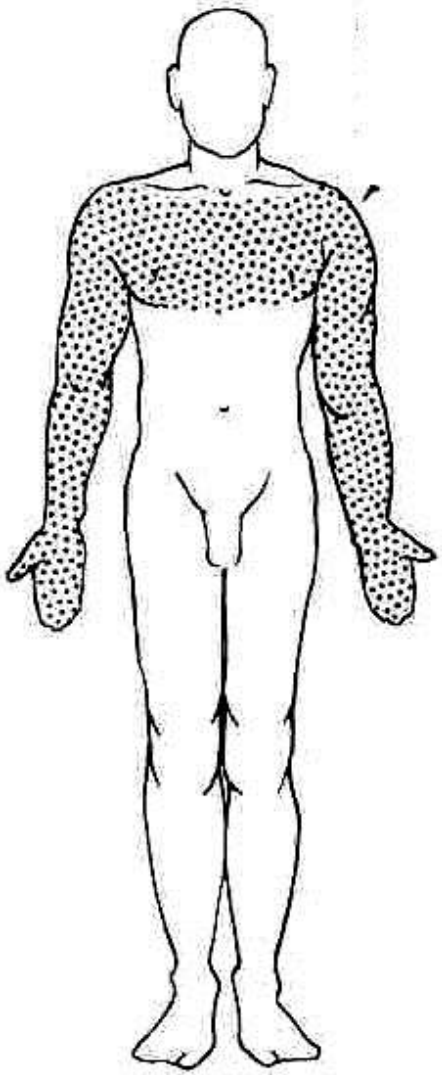

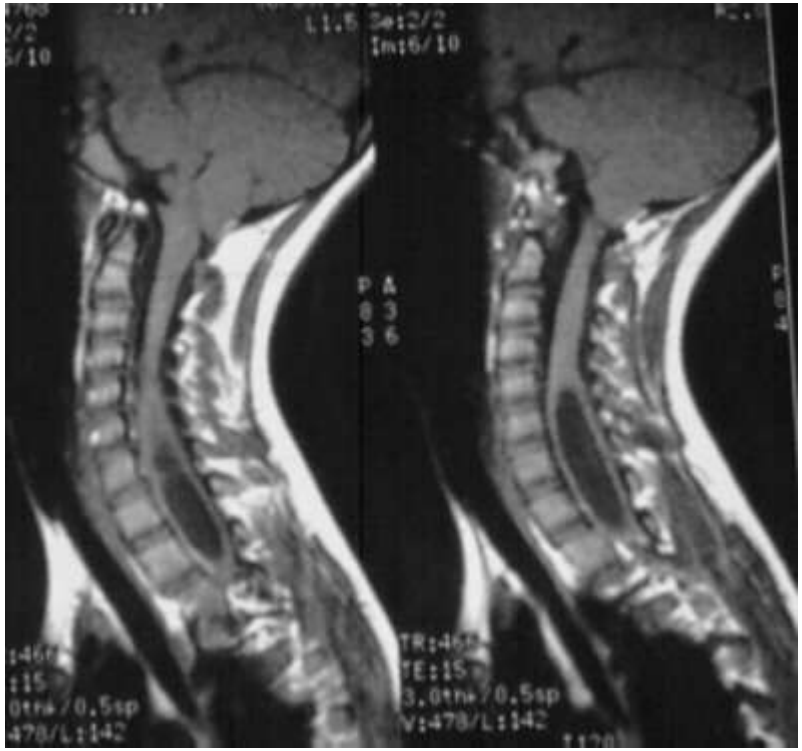

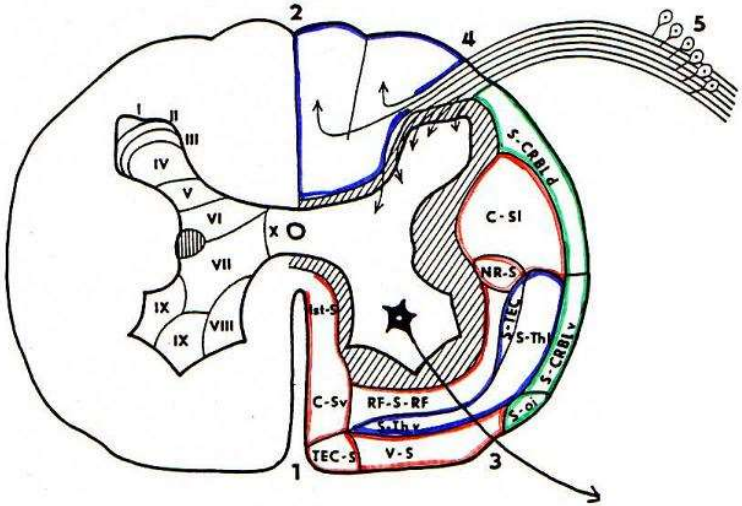

Meningomyelokéle

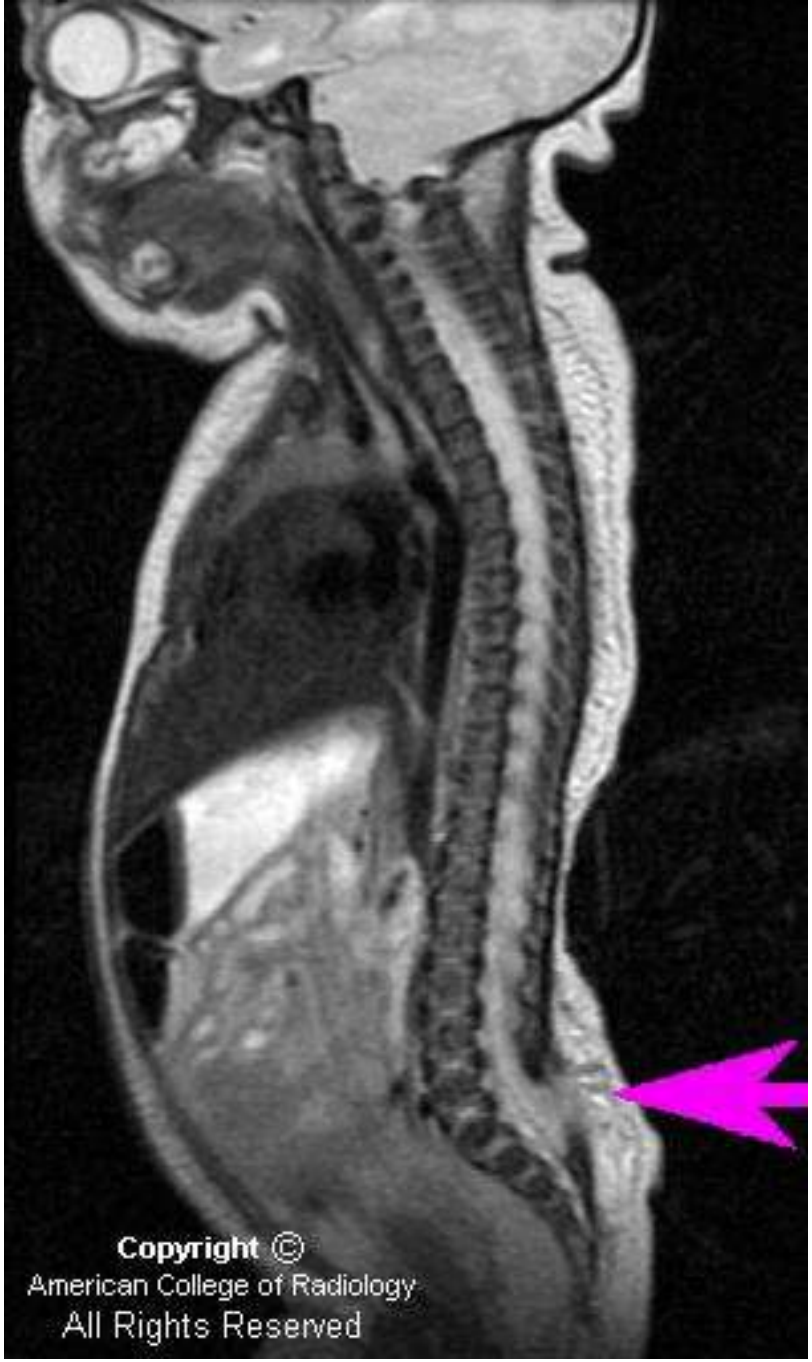

Amyotrophic lateral sclerosis

Pathological Features of ALS from Other Cases (Luxol Fast Blue–Hematoxylin and Eosin).

- **Bunini body in motoneuron of anterior horn,** ALS (Panel A, arrow) (photomicrograph courtesy of Dr. David Louis).
- Panel B selective **degeneration of cortico-spinal tracts** (arrows). Posterior columns are normally myelinizated (arrowheads).
- In anterior root is loss of myelinizated fibers and gliosis (Panel C, right) posterior horn is normal (Panel C, left).

affected central and peripheral neuron

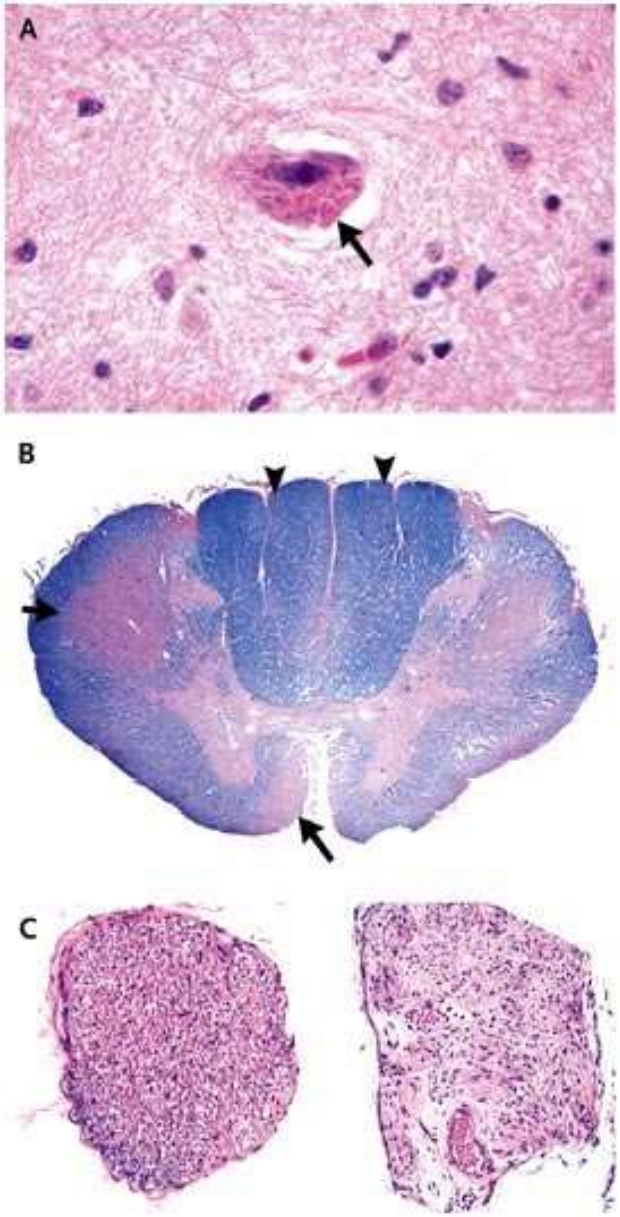

Living - 3-5 years from the diagnosis,
20% die in 1.year – respiratory insuficience

Rexed´s laminae (zones)

I – ncl apicalis
II, III – subst. gelatinosa Rolandi
IV,V – ncl proprius
VI – ncl. Stilling-Clark
VII – interneurons
VIII,IX - motoneurons

Dorsal column tracts

Propriospinal tracts crosshatched
Visceromotor nucleus
Sensory tracts
Motor tracts
Cerebellar tracts

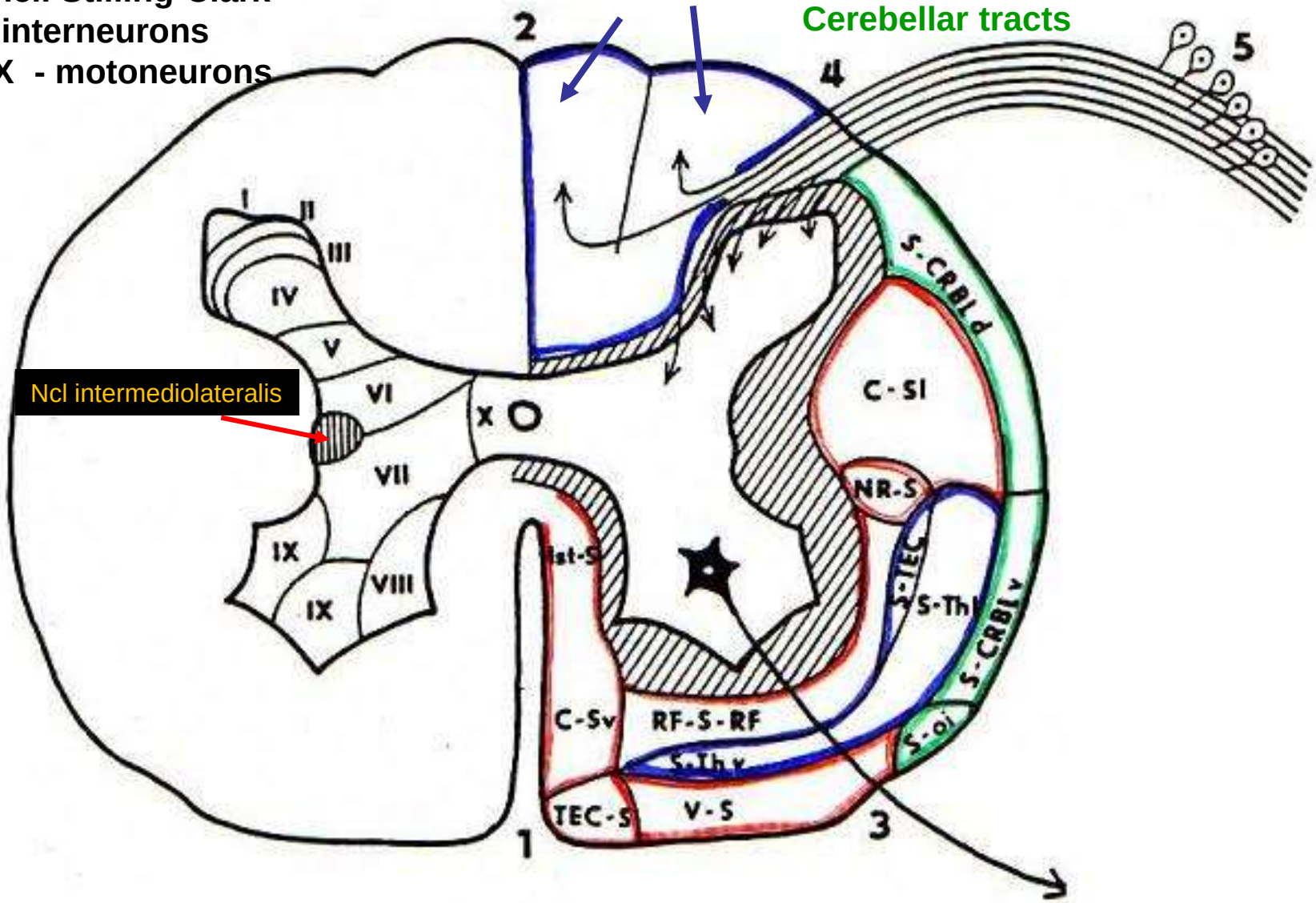

Sources

- Petrovický, Anatomie III
- Grim, Nanka, Helekal Anatomický Atlas
- Rohen Yokochi, Anatomie člověka, fotografický atlas
- Köpf Maier, Atlas of Human anatomy
- Sobotta, Atlas anatomie člověka
- Batson OV: The function of the vertebral veins and their role in the spread of metastases. Ann Surg 1940; 112: 138–149.
- *Chhabra A et al.* Spinal Epidural Space:
  Anatomy, Normal variations, and Pathological Lesions
  on MR Imaging
- J.M.S. Pearce The Craniospinal Venous System

- M.A. England, J.Wakely, Color atlas of the brain and spinal cord
- Ambler, Poruchy periferních nervů