

Clinical anatomy upper and lower extremity

MUDr. R. Hromádka
MUDr. P. Šnajdr

Clinical anatomy upper and lower extremity

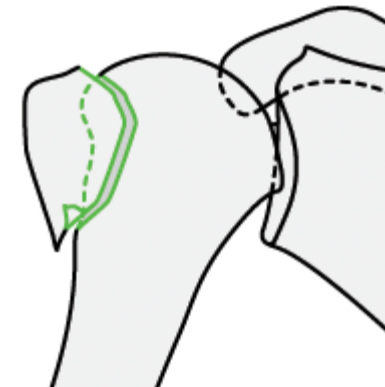
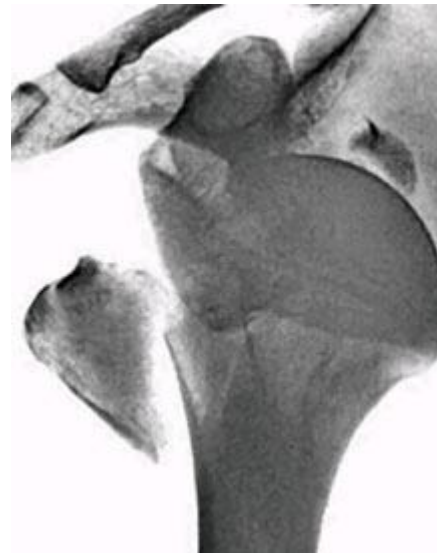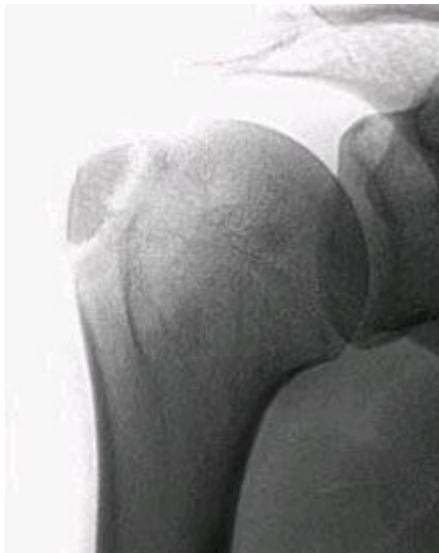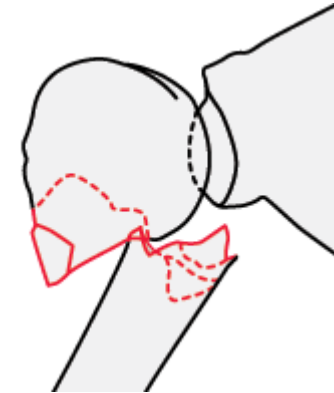
- Acute trauma (disability)
 - Chronic disability
 - Degenerative
 - Congenital
 - developmental
-

Clinical anatomy – acute trauma

- Bones i.e. fractures
 - Ligaments i.e. ruptures
 - Muscles i.e. ruptures muscle tissue or tendons
 - Peripheral nerves
 - Vessels
-

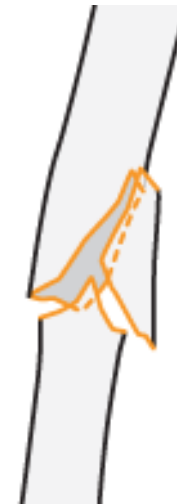Fractures of proximal humerus

1. Greater tubecle (tuberosity)
2. Lesser tubercle (tuberosity)
3. Head of humerus
4. Proximal shaft of humerus



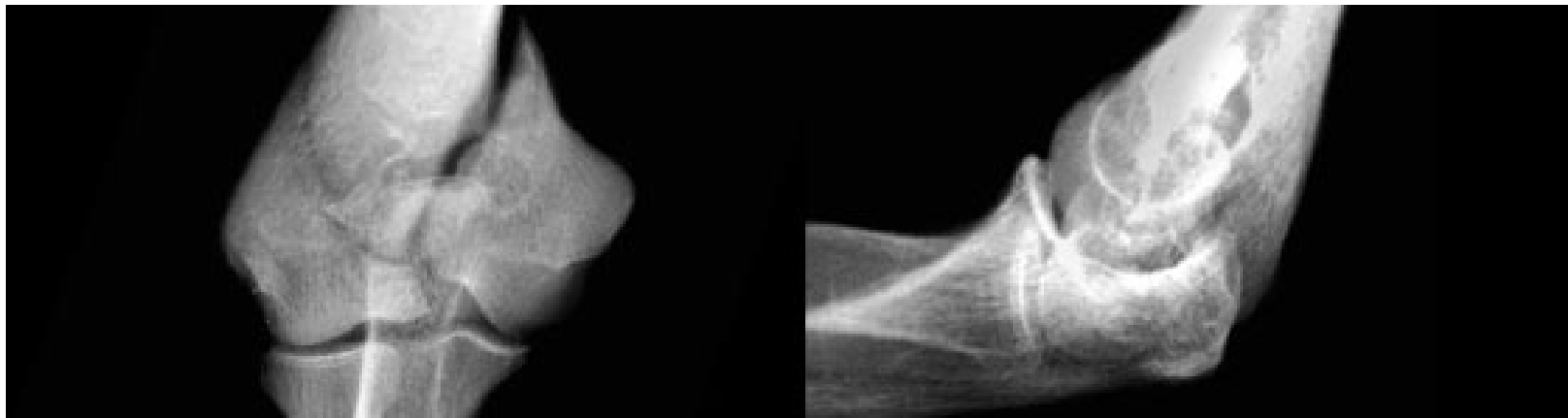
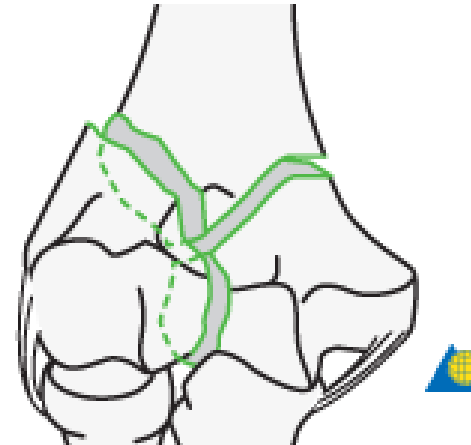
Fractures of humeral diaphysis

- Groove for radial nerve



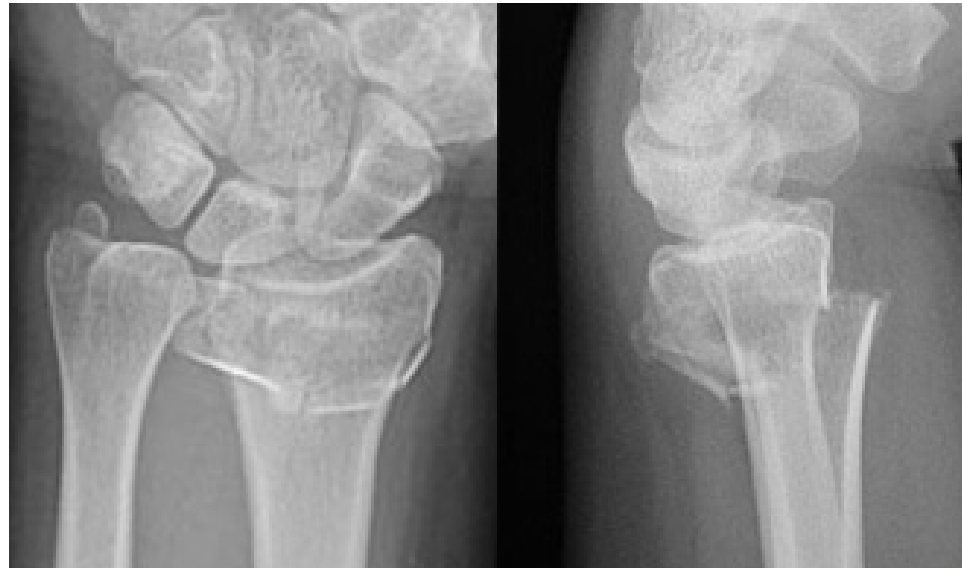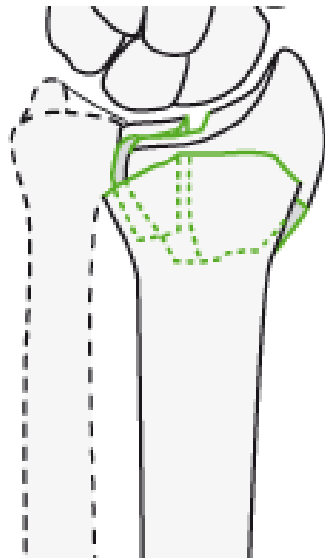
Fractures of distal humerus

- Trochlea of humerus
- Capitulum of humerus
- Groove for ulnar nerv



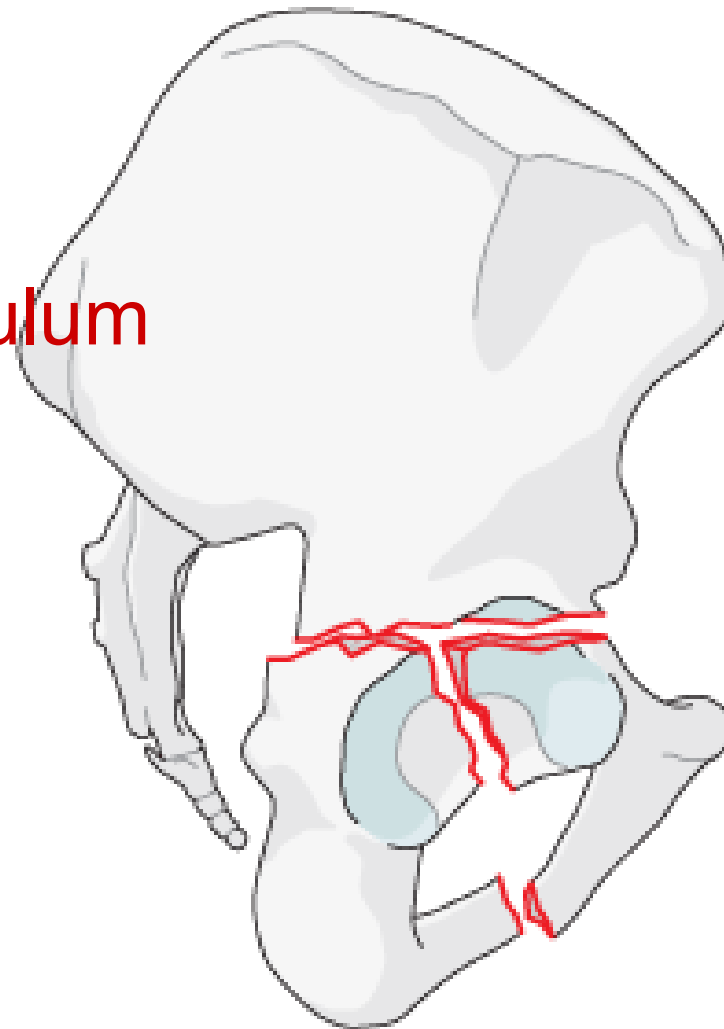
Zlomeniny dolního konce vřetenní kosti

- Facies articularis carpalis radii
- Incisura ulnaris radii
- Processus styloideus radii



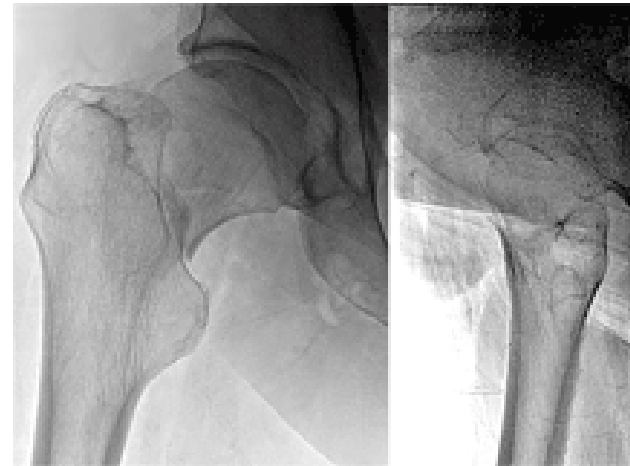
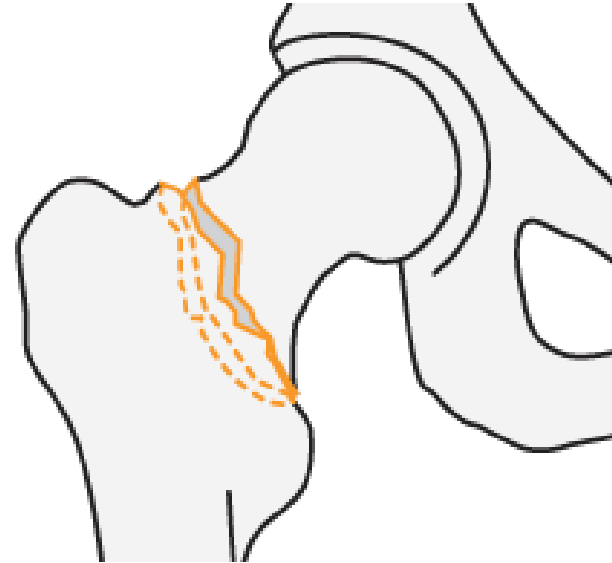
Fractures of acetabulum

- Lunate surface
- Margo of the acetabulum



Fractures of proximal femur

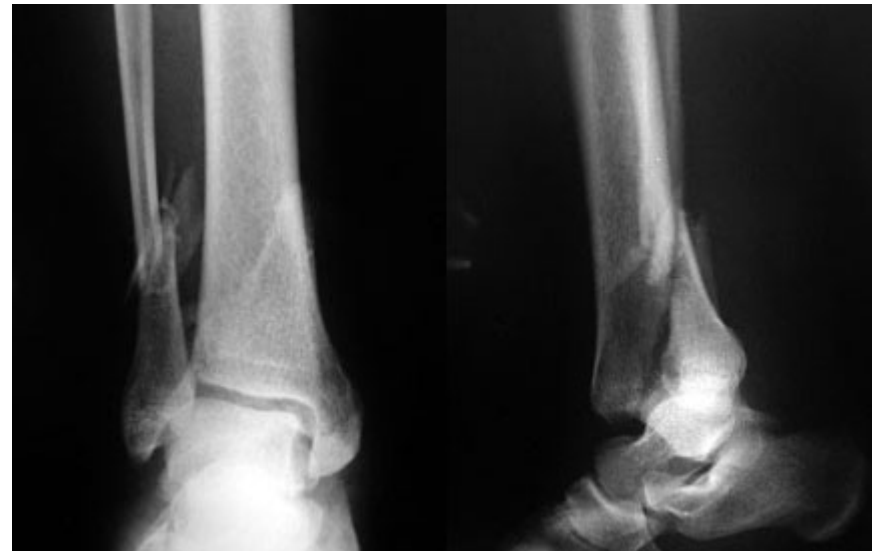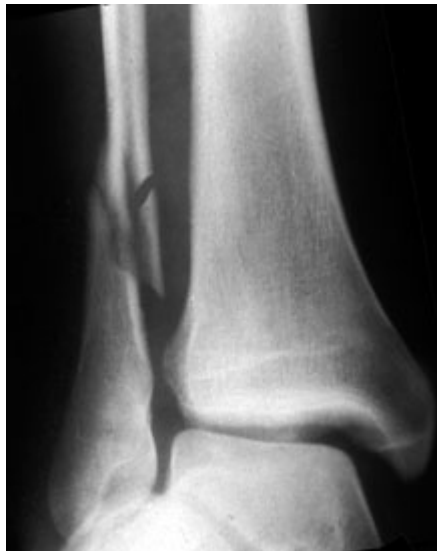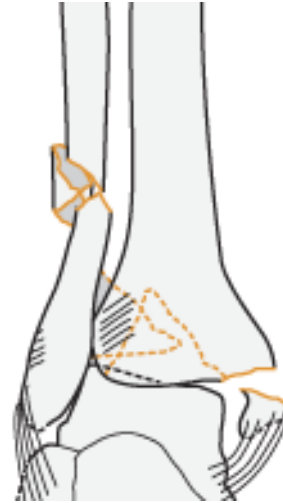
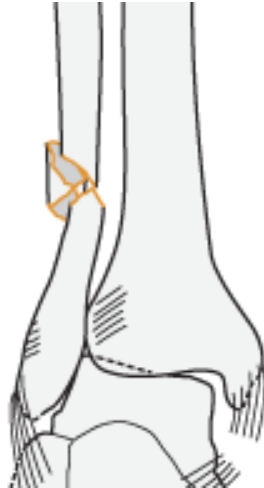
- Head of femur
- Neck of femur
- Greater trochanter
- Lesser trochanter



Fractures around ankle joint

- **Medial ligament**
 - Tibionavicular part
 - Tibiocalcaneal part
 - Anterior tibiotalar part
 - Posterior tibiotalar part
 - Anterior talofibular ligament
 - Posterior talofibular ligament
 - Calcaneofibular ligament
 - Anterior tibiofibular ligament
 - Posterior tibiofibular ligament
-

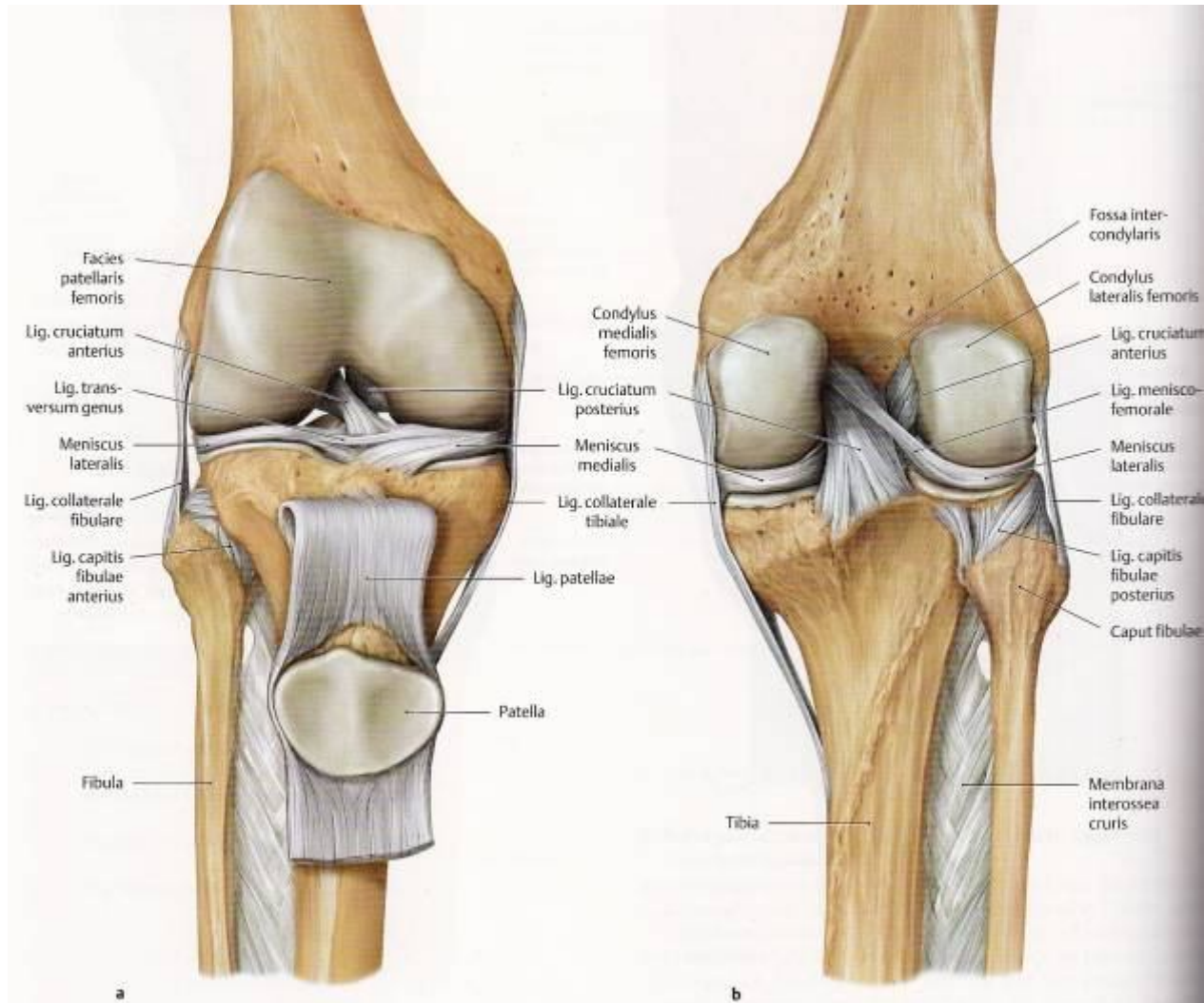
Fractures around ankle joint



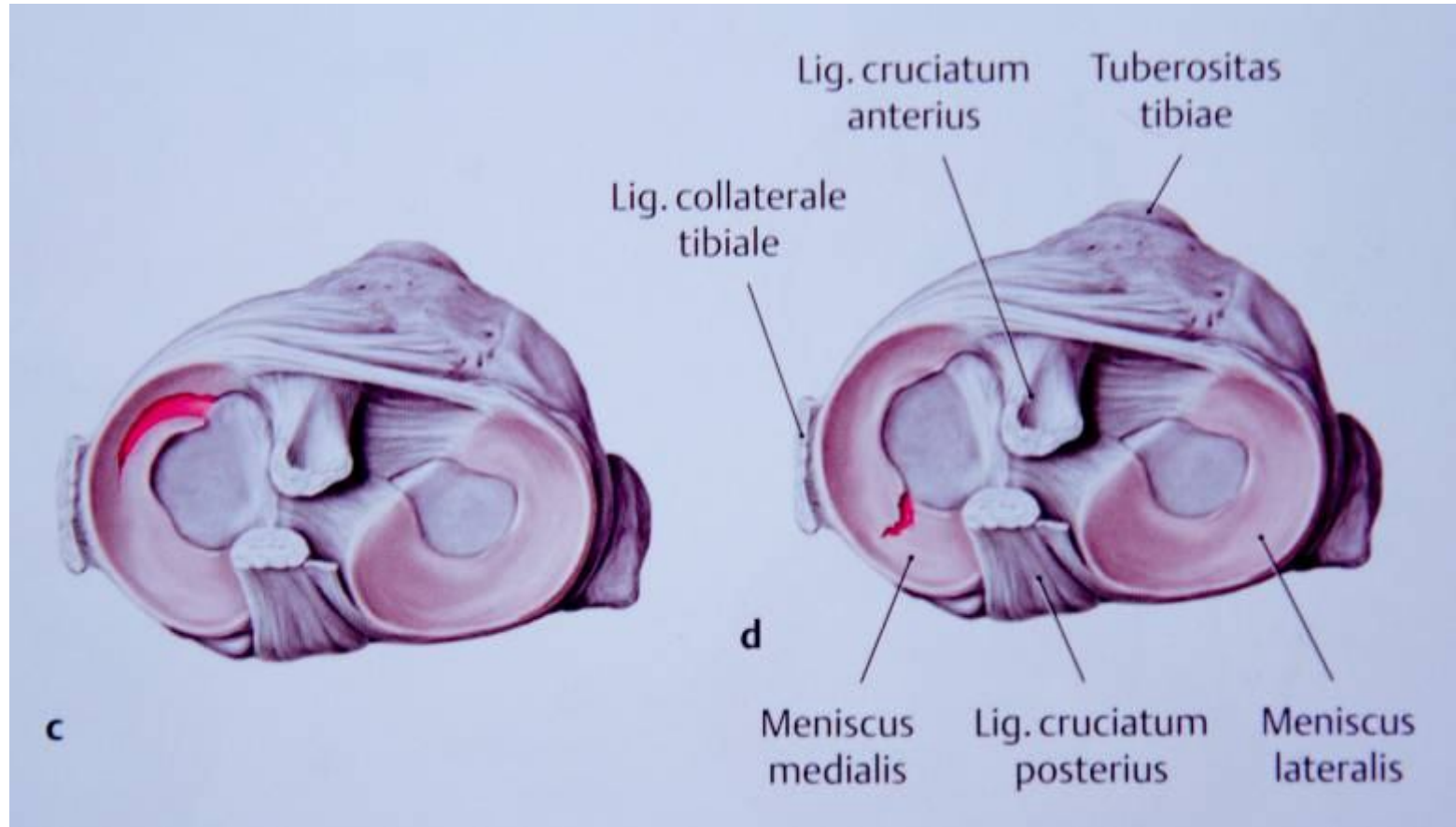
Acute trauma of knee structures

- Medial collateral ligament
 - Medial meniscus
 - Ligamentum cruciatum anterius
 - Ligamentum cruciatum posterius
 - Lateral meniscus
 - Lateral collateral ligament
 - Iliotibial tract
-

Acute trauma of knee structures

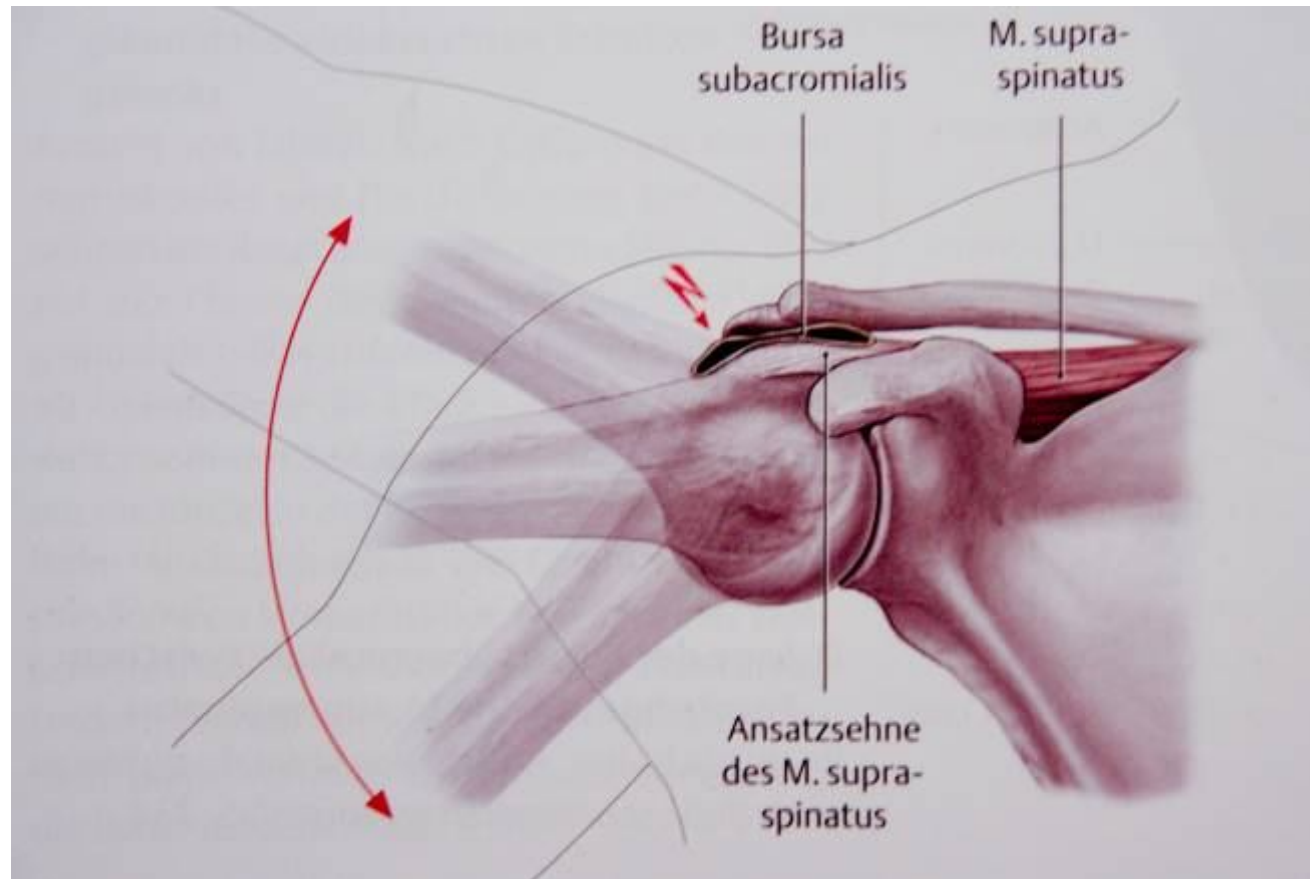


Acute trauma of knee structures



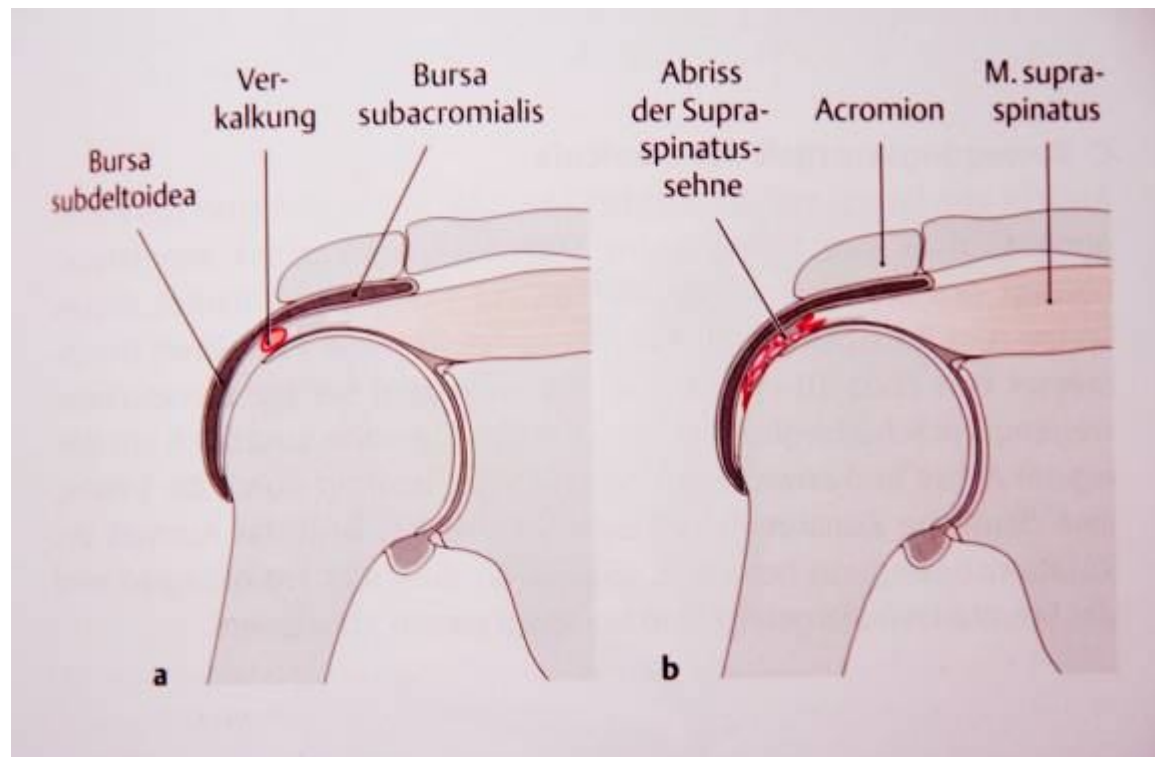
Acute trauma of muscles

Rupture of rotator cuff muscles



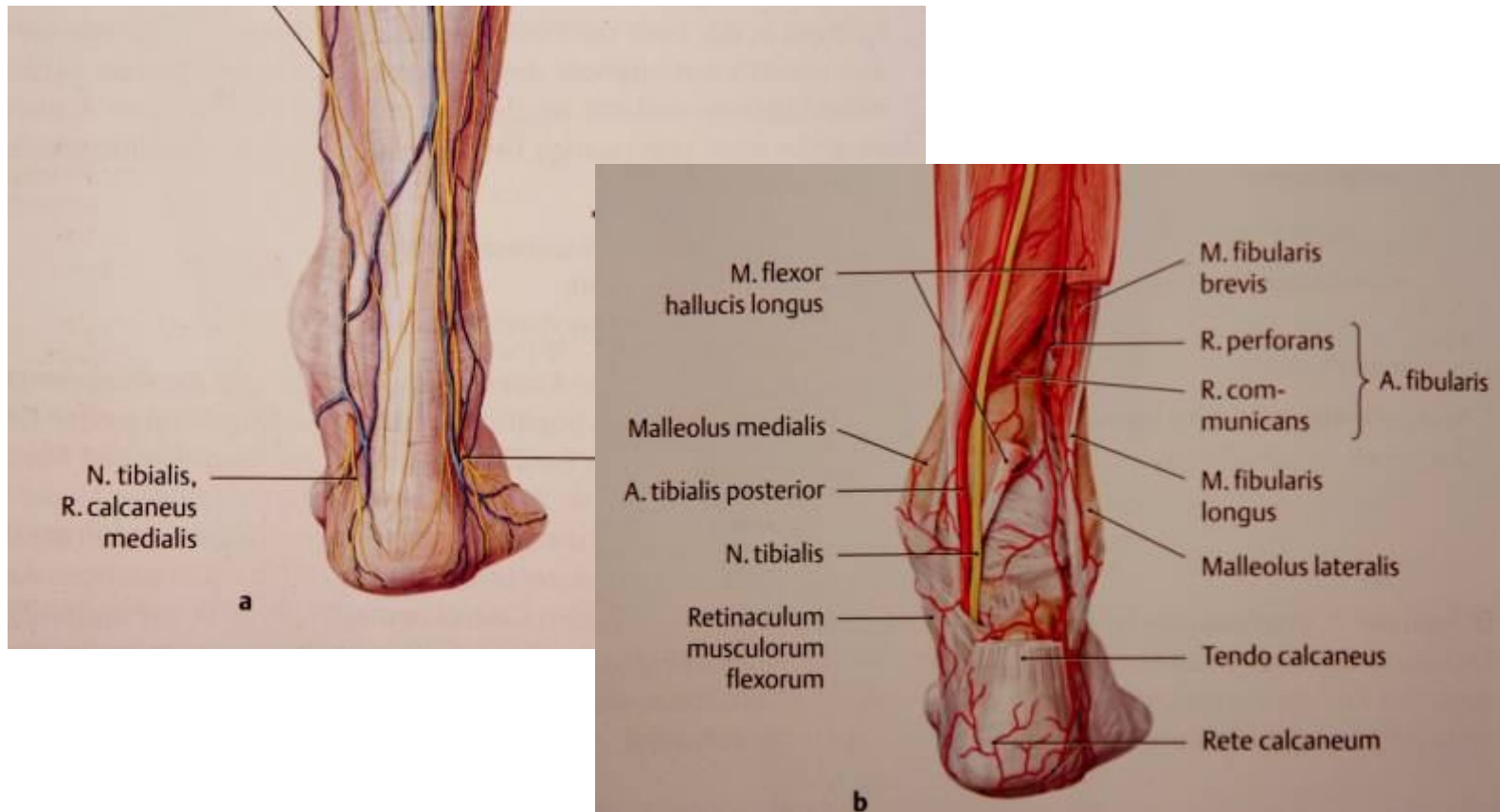Acute trauma of muscles

- Supraspinatus muscle
- Infraspinatus, Teres minor, Subscapularis



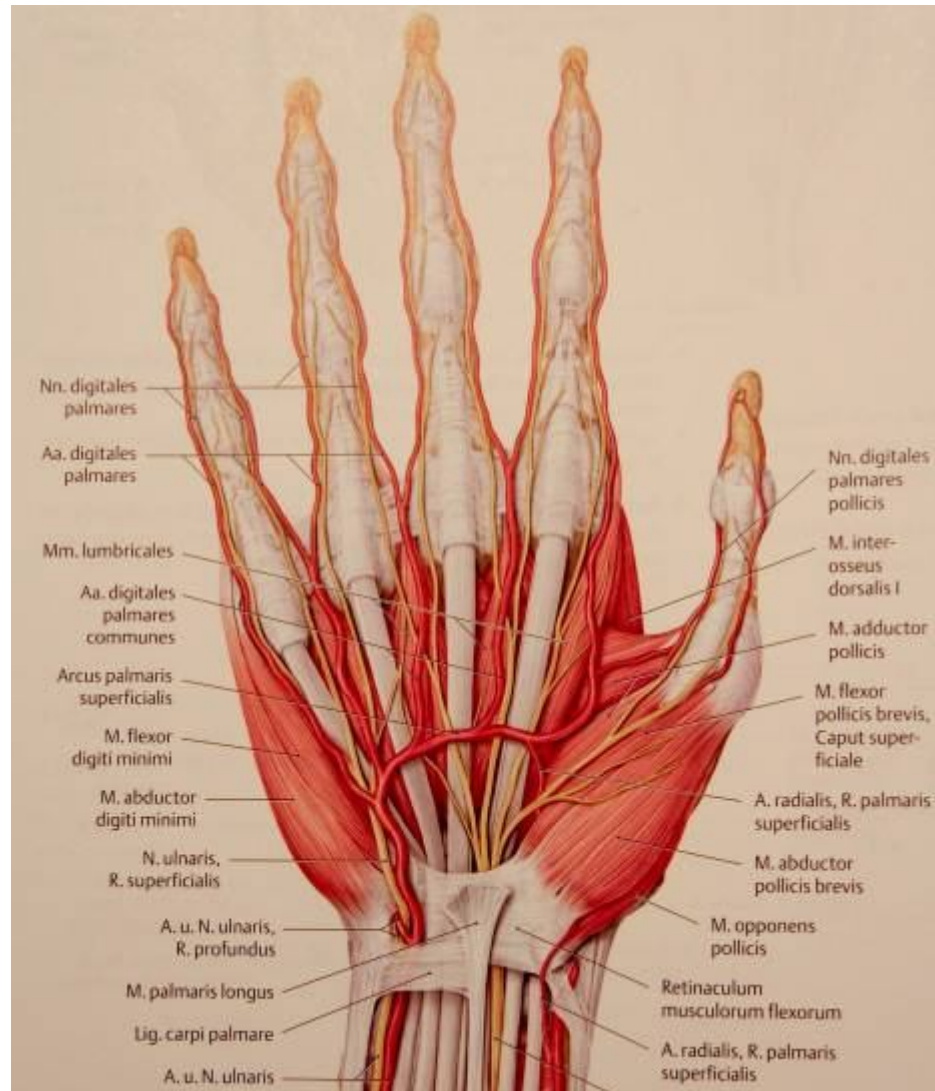
Acute trauma of muscles

Rupture of Achilles tendon



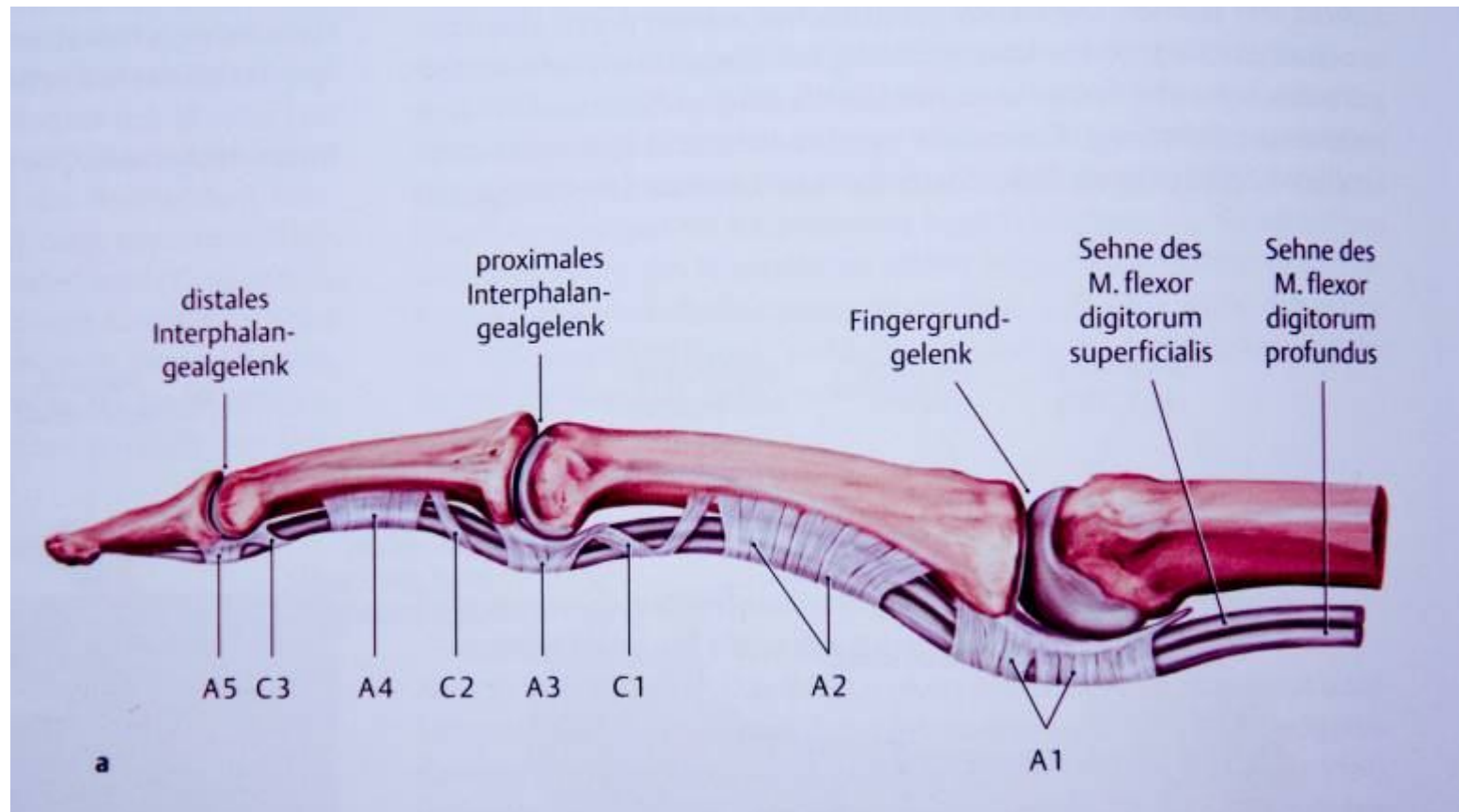
Acute trauma of muscles

Tendons of hand



Acute trauma of muscles

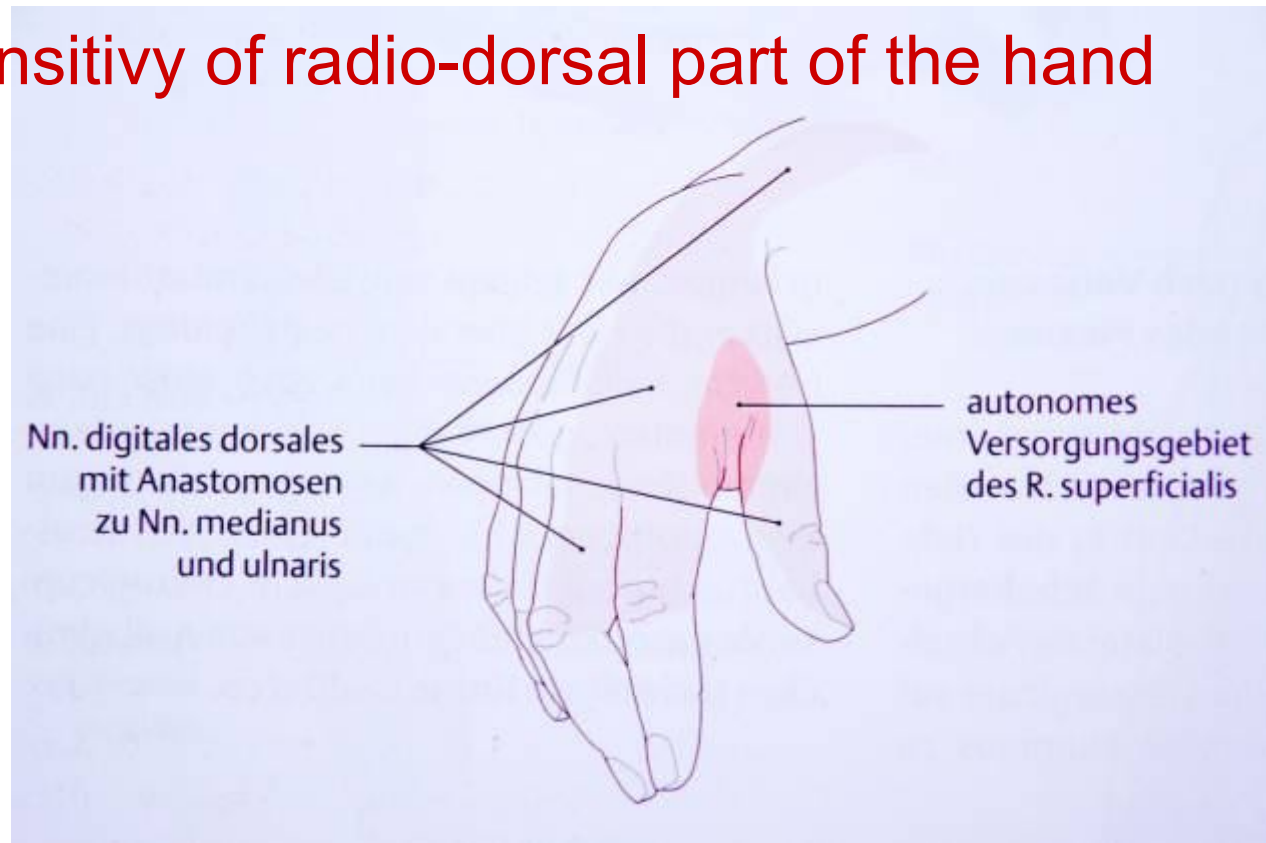
Tendons of hand



Trauma of peripheral nerves

Radial nerve palsy

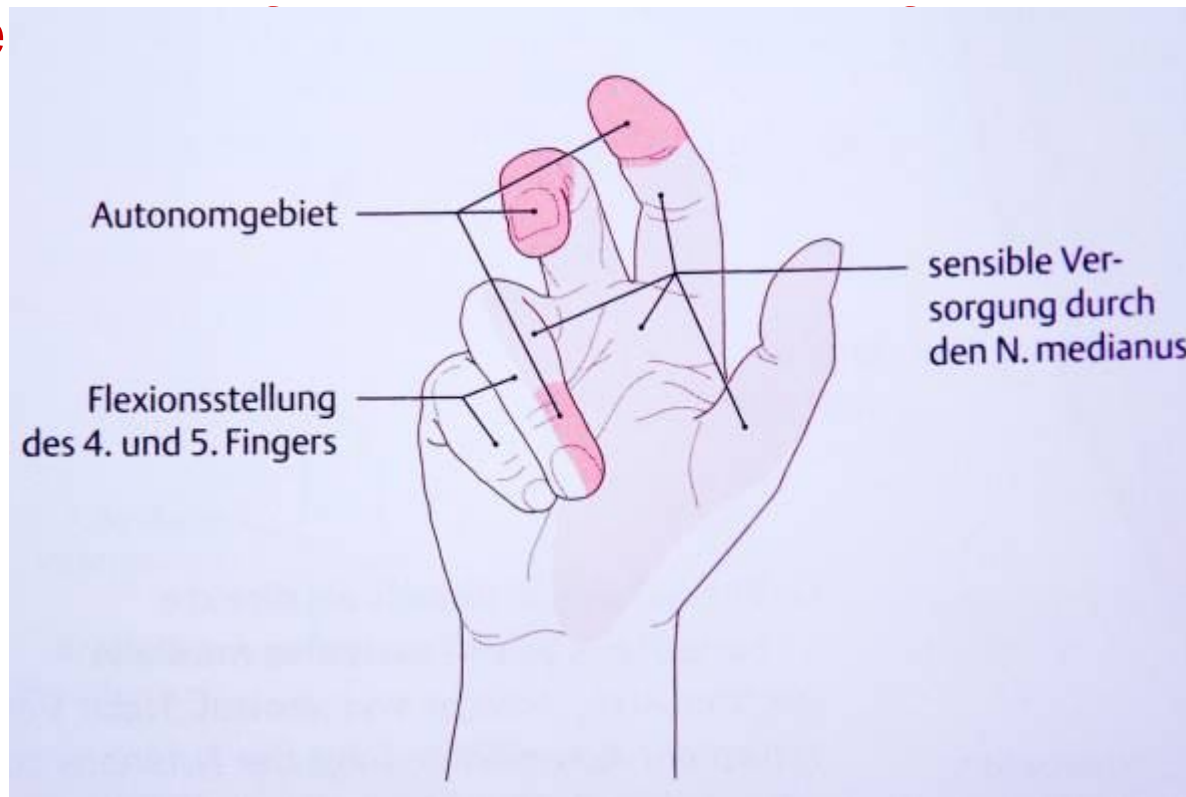
- Extensors of the hand
- Skin sensitivity of radio-dorsal part of the hand



Trauma of peripheral nerves

Median nerve

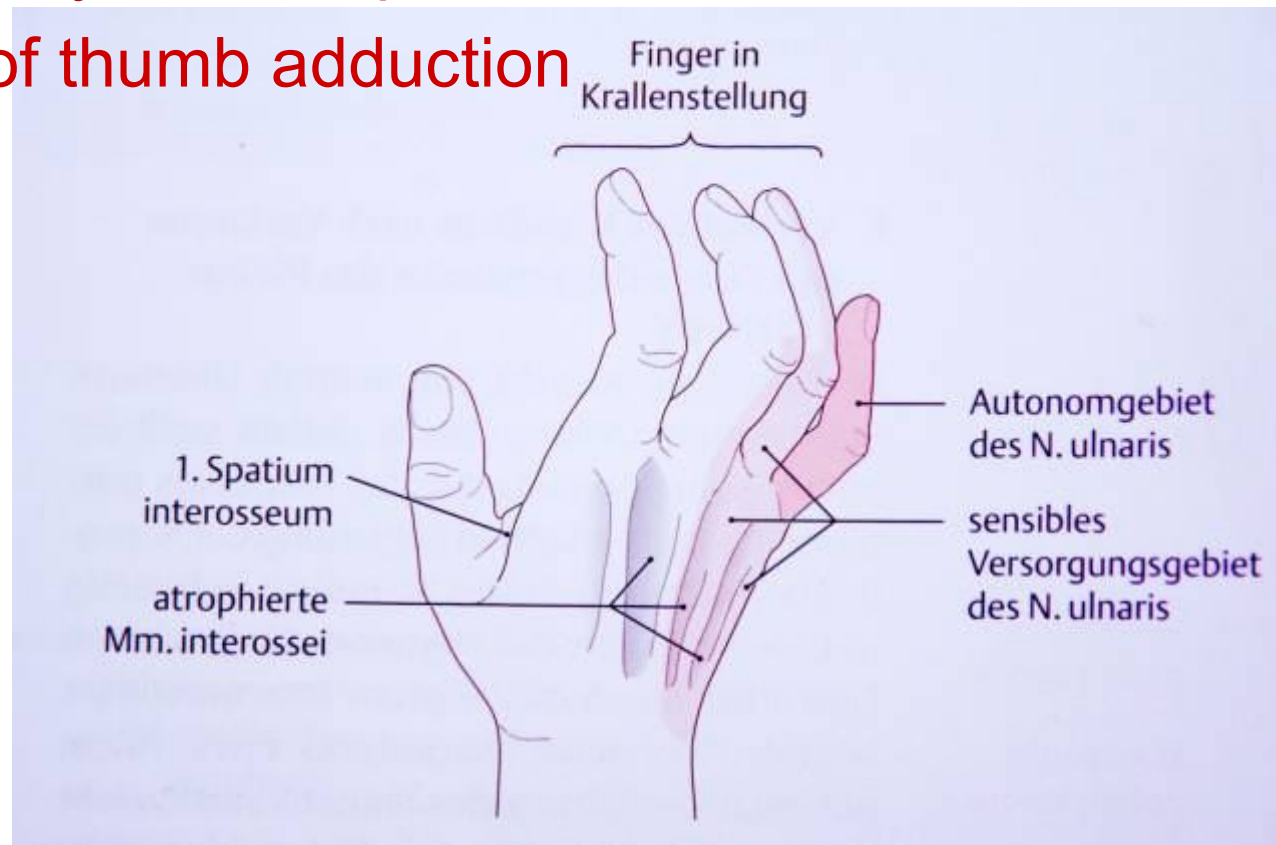
- Disability of thumb muscles
- Skin se



Trauma of peripheral nerves

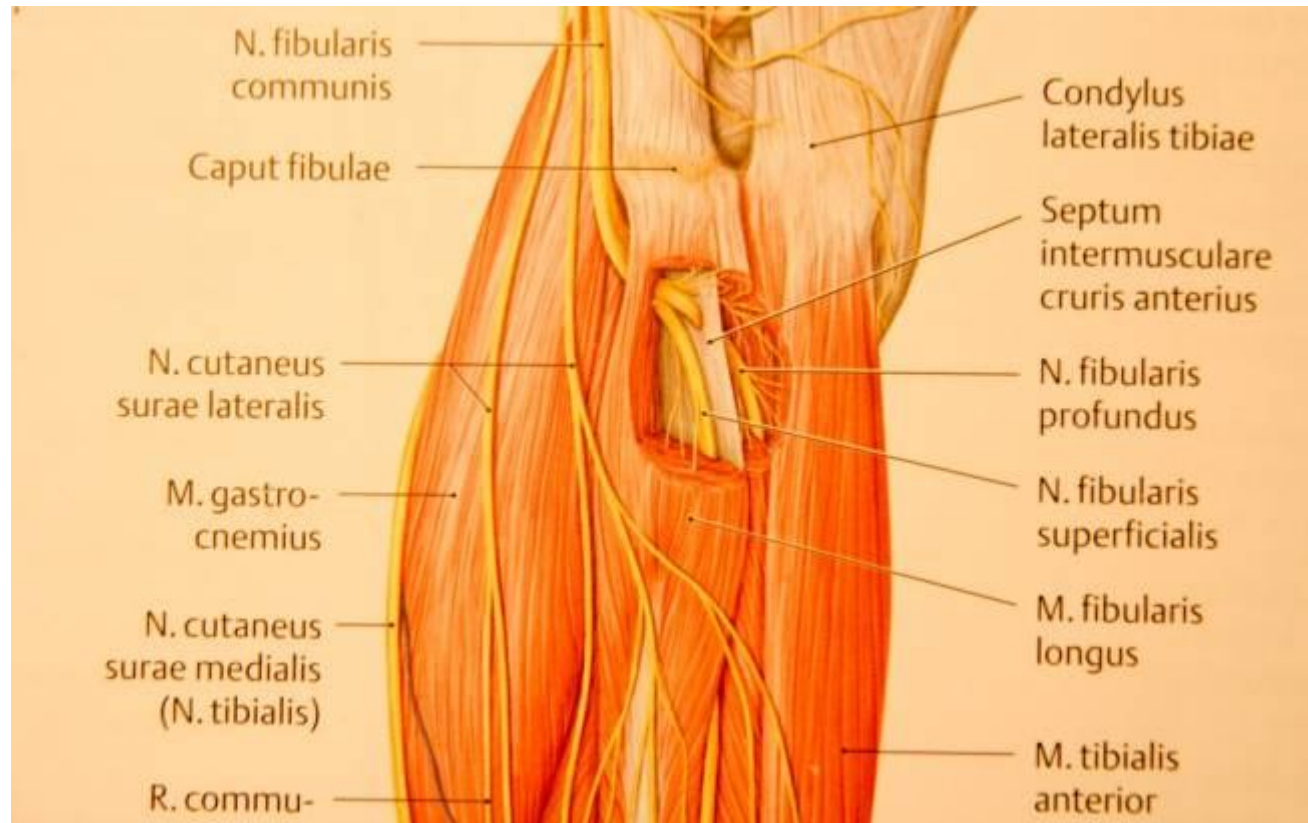
Ulnar nerve

- Skin sensitivity of ulnar part of the hand
- Disability of thumb adduction



Trauma of peripheral nerves

Common fibular nerve



Compartment syndrom

Definition

is an acute medical problem, in which increased pressure within a confined space.

Compartment syndrom

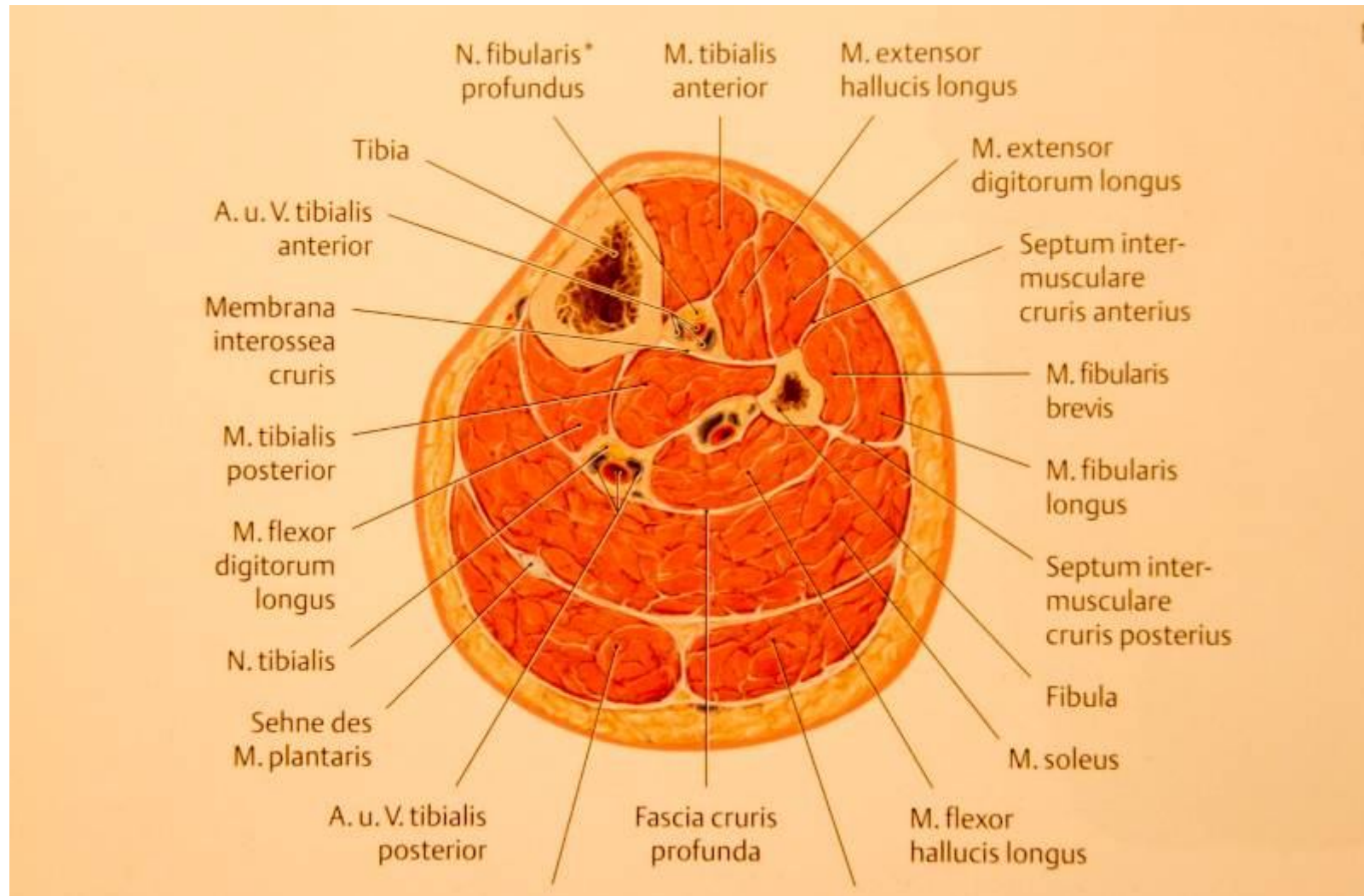
Mechanizmus

- reduce of the space (cast, bandage)
- enlarge of a space content (swelling, bleeding)
- reduction tolerance for pressure (generalised disorders)

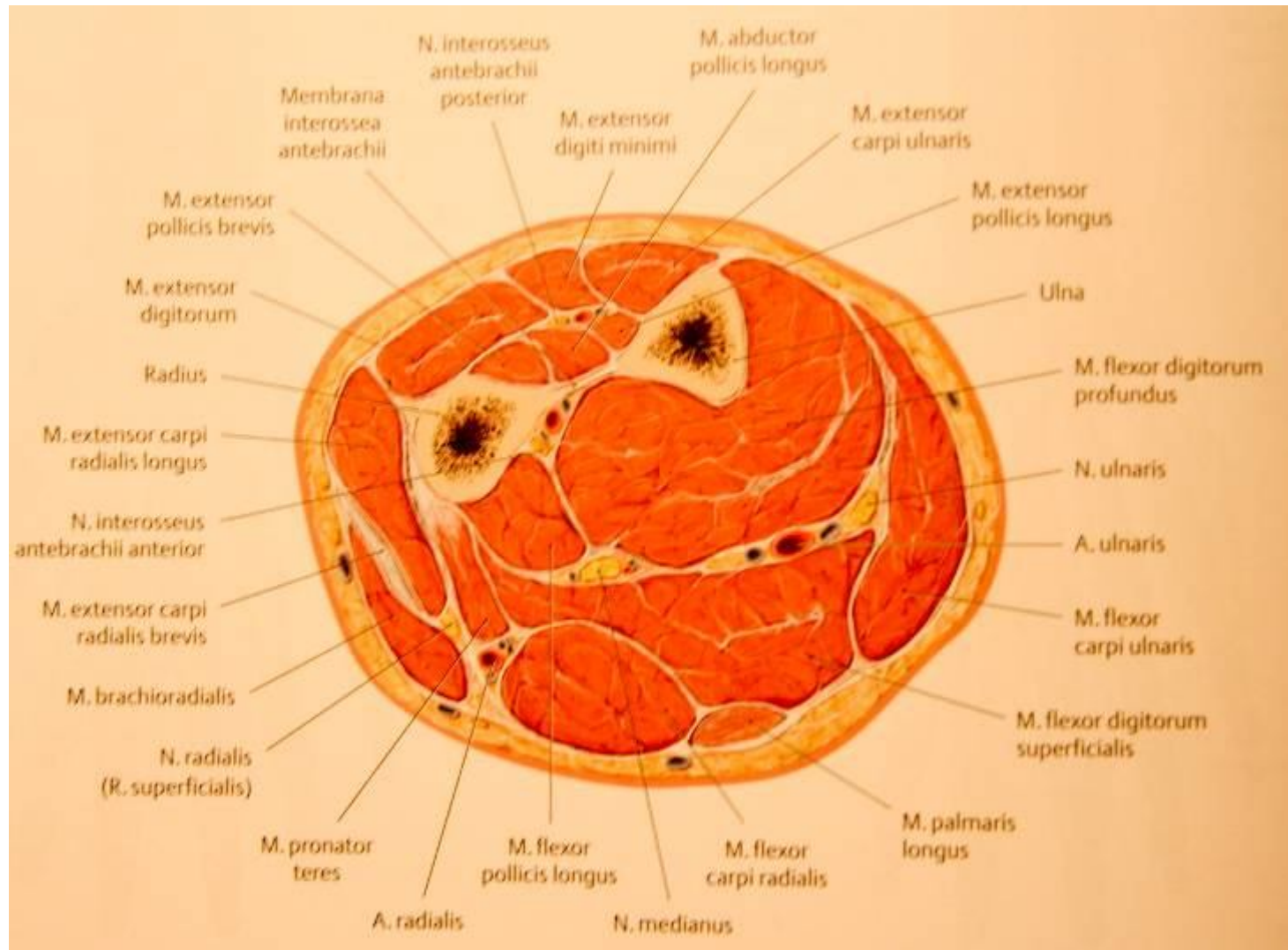
Space pressure

- Physiological pressure less than 30mm Hg
 - threatening compartment sy >40 mm Hg
 - compartment sy >60 mm Hg
-

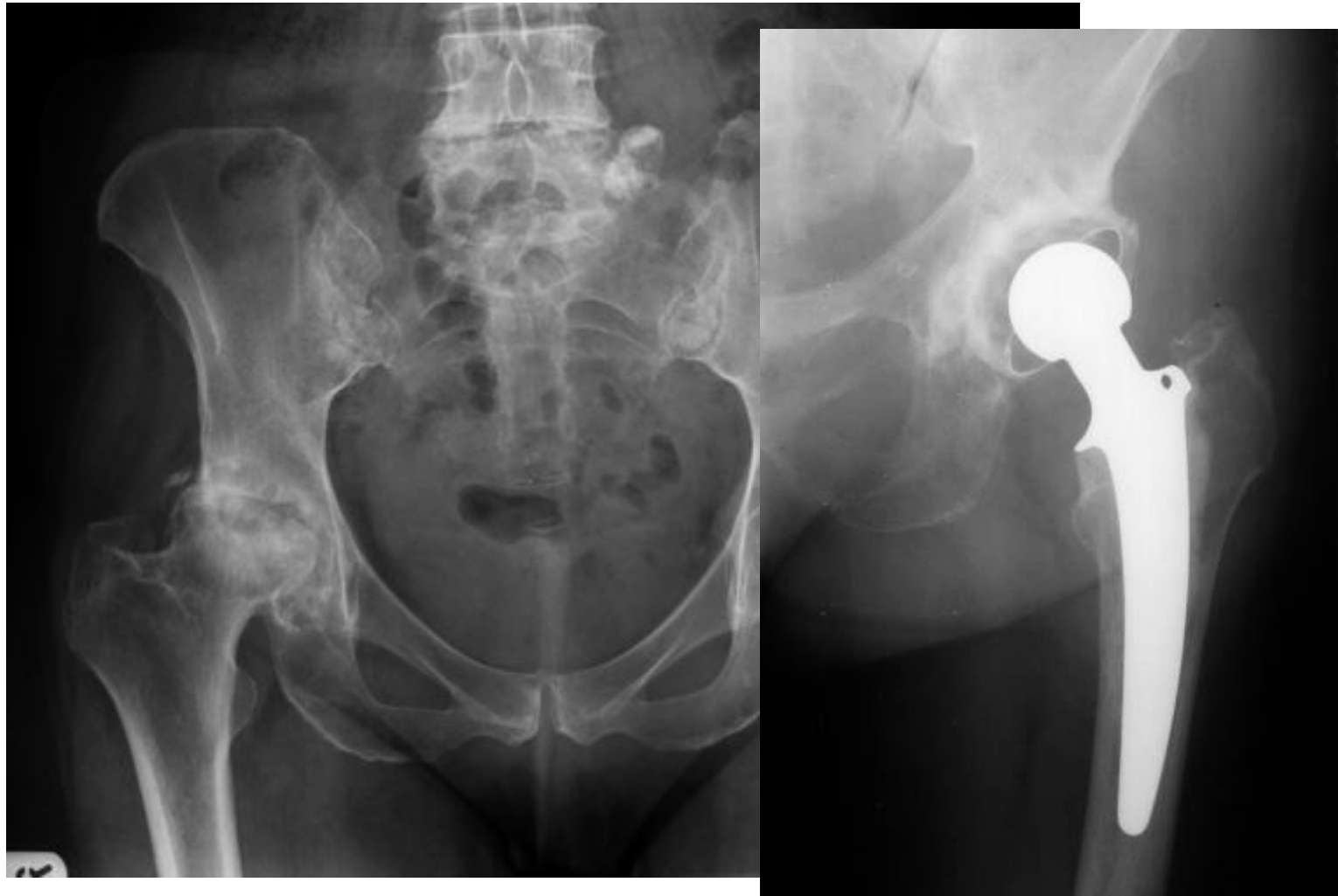
Compartment syndrom



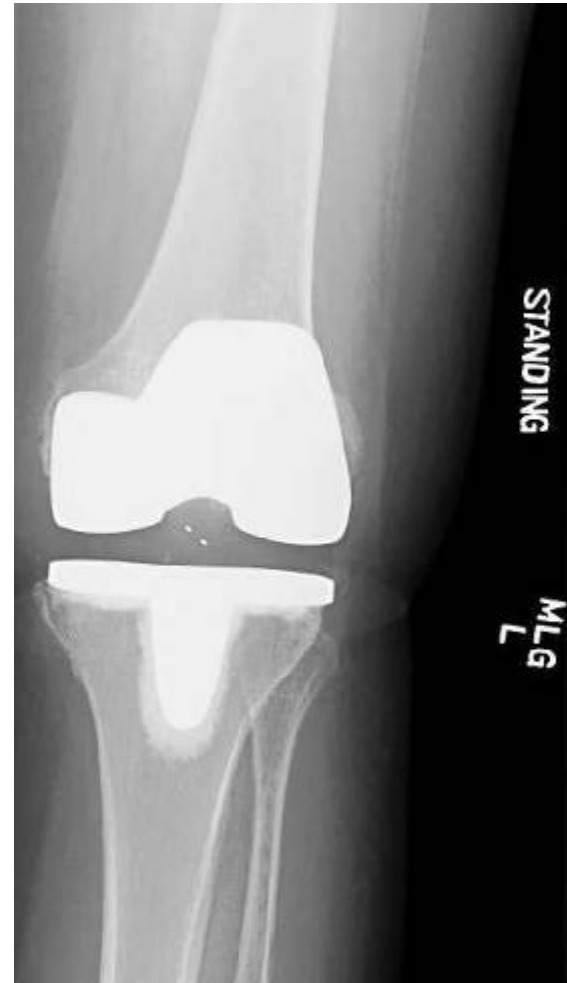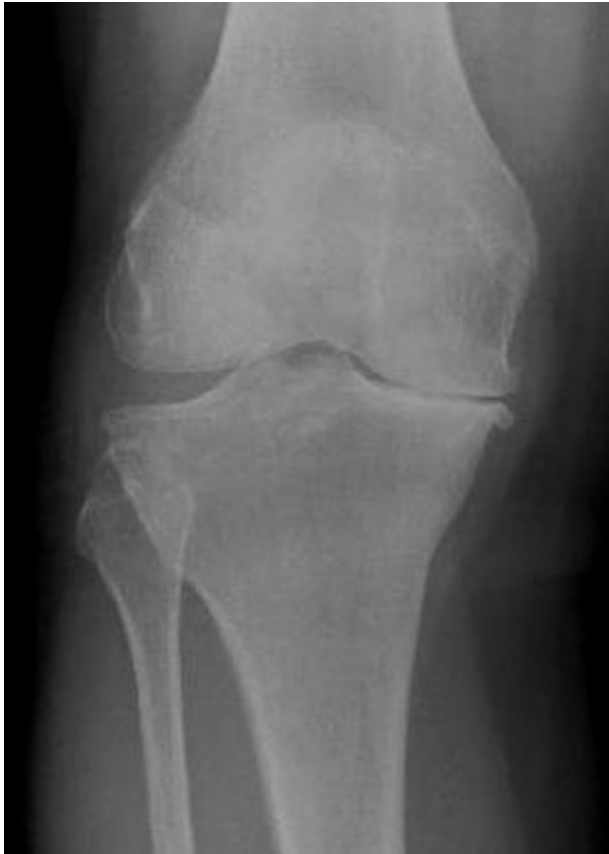Compartment syndrom



Osteoarthritis of hip joint



Osteoarthritis of knee joint



Developmental disease of hip joint (DDH)

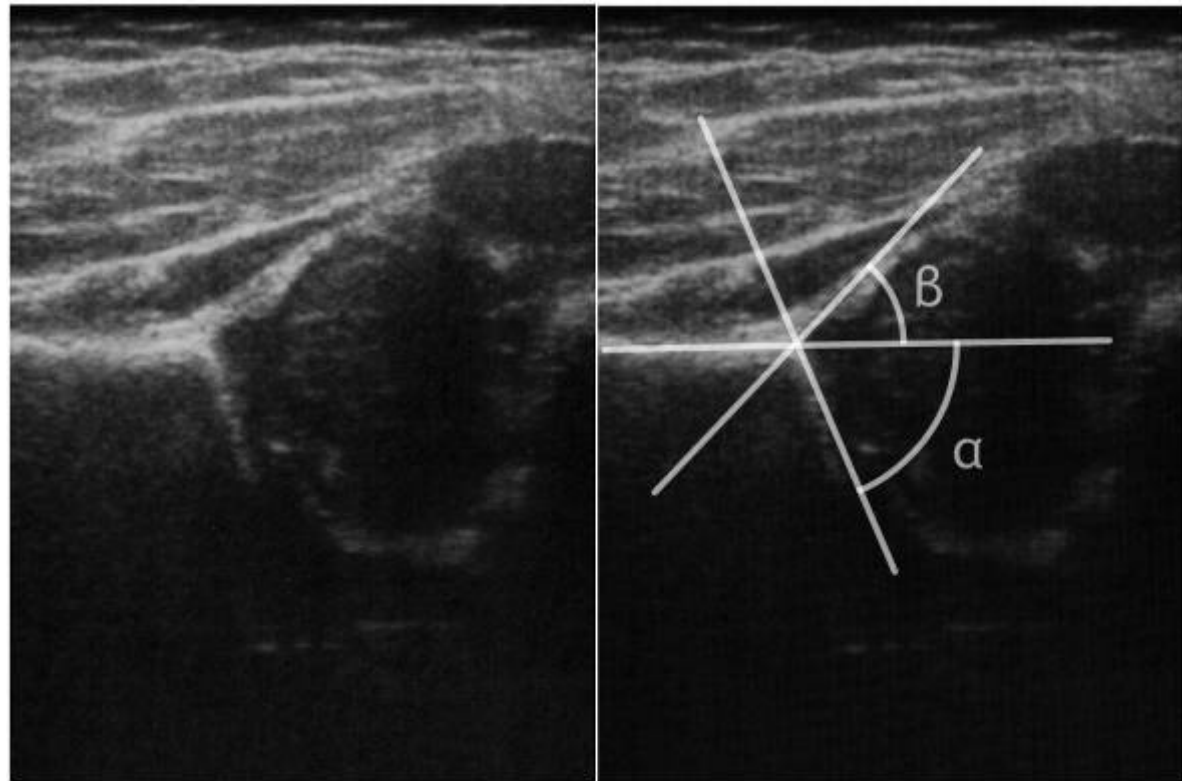
- 5% in Czech population
 - Less than 1% in USA polupation
-
- Congenital disorder of acetabulum
 - Perinatal care
-

Developmental disease of hip joint (DDH)

■ USG of hip joint

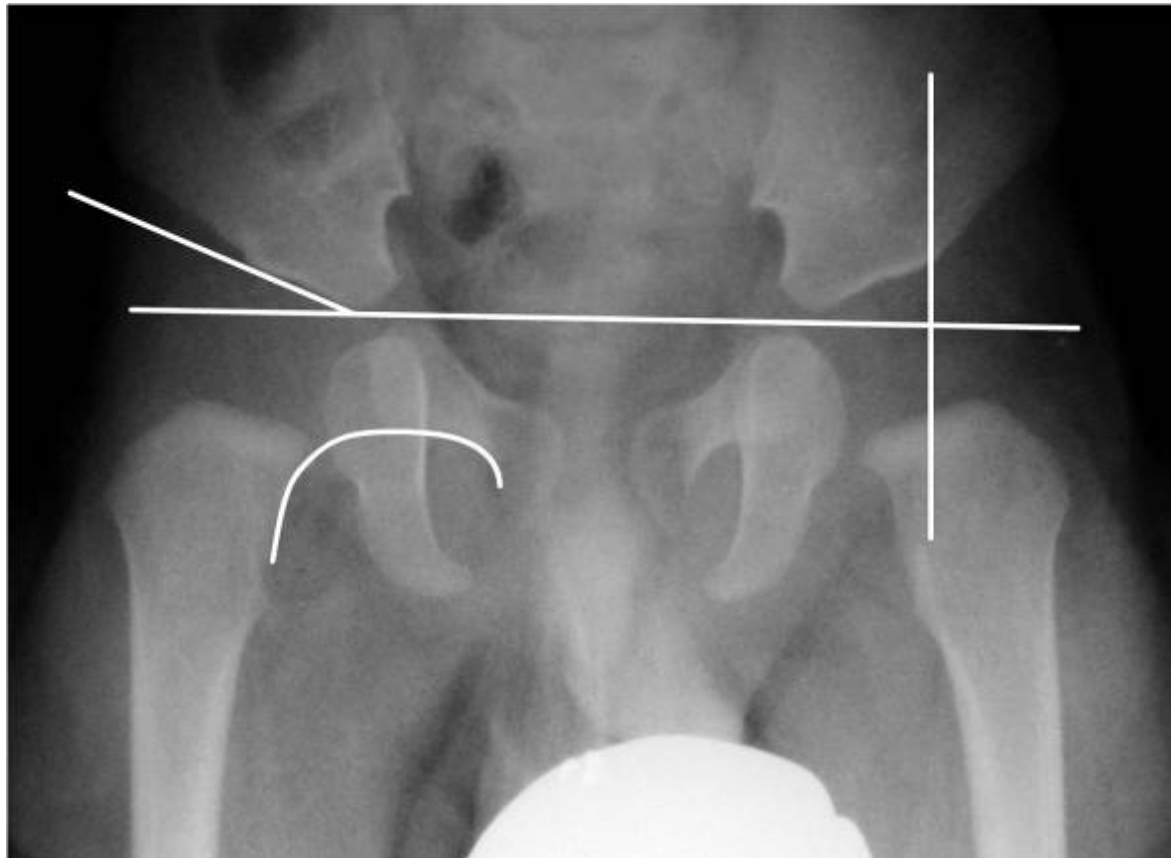- 3rd week
- 6-8 week
- 12-18 week

■ Graf score

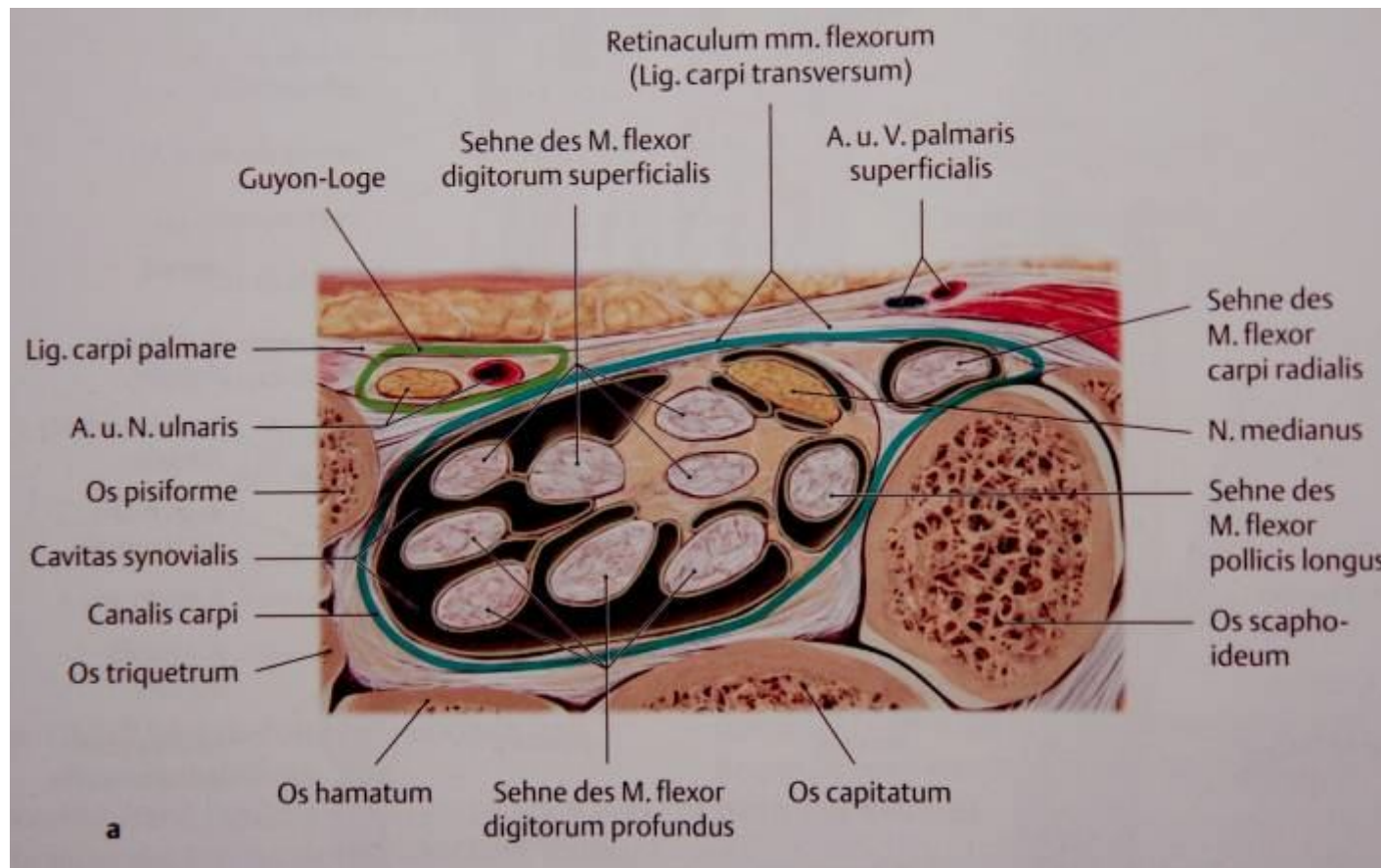


Developmental disease of hip joint (DDH)

- X-ray of hip joint in 3rd month

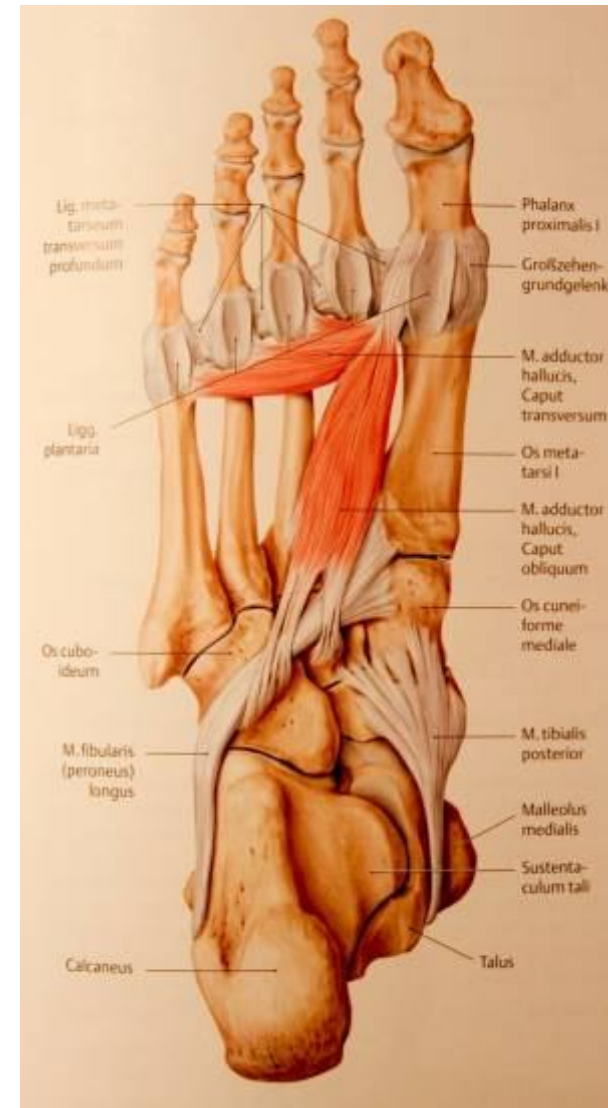

■ Neuropathy of median nerve

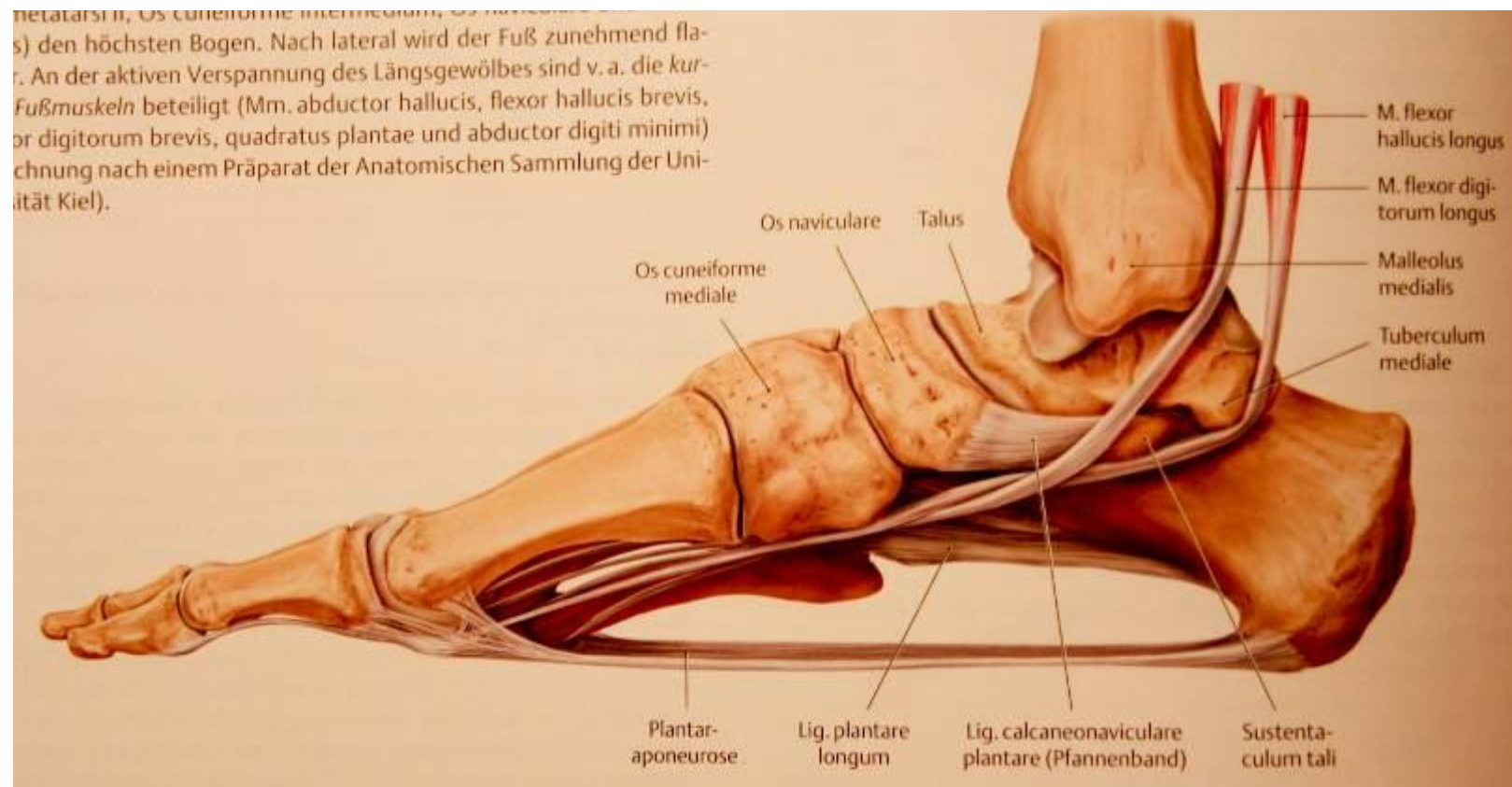


Flat foot

- Plantar calcaneonavicular ligament
- Long plantare ligament
- Plantar aponeurosis
- Tibialis posterior
- Tibialis anterior
- Adductor hallucis
- Peroneus longus
- Foot flexores



Flat foot



Thank you for your attention
